

# ECR 2008

European Congress of Radiology

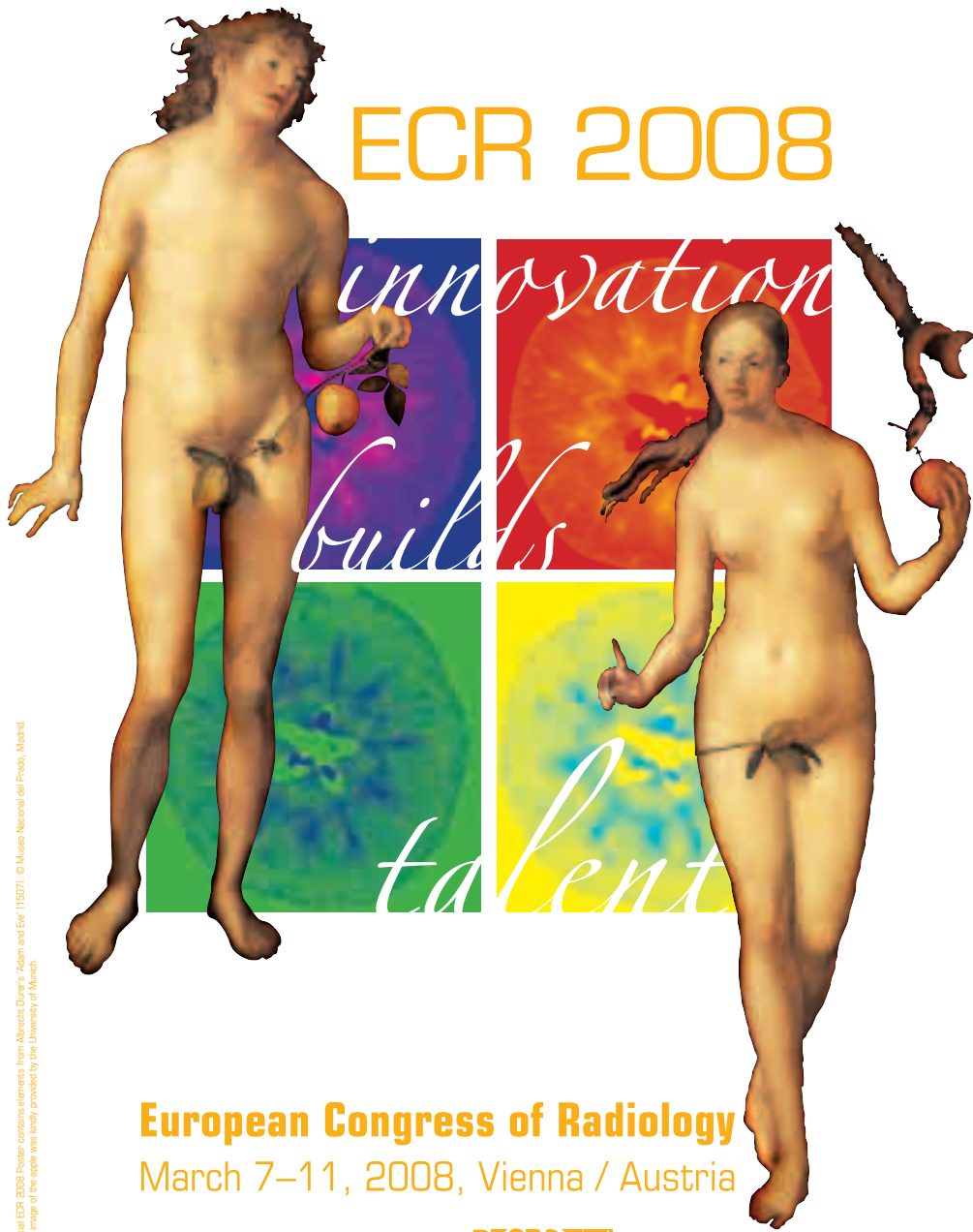
March 7–11, 2008, Vienna / Austria



## Final Programme

Onsite Guide

# ECR 2008



The official ECR 2008 Poster combines elements from Albrecht Dürer's Adam and Eve (1507). © Museo Nacional del Prado, Madrid. The left image of the apple was kindly provided by the University of Munich.

**European Congress of Radiology**  
March 7–11, 2008, Vienna / Austria

The annual meeting of



[myESR.org](http://myESR.org)

08:30 09:00 09:30 10:00

10:30 11:00 11:30 12:00

12:15 13:00 13:30 14:00

14:00 14:30 15:00 15:30

16:00 16:30 17:00 17:30

**Friday, March 7**

**ECR Opening Concert  
Inaugural Lecture  
Lifetime Achievement Award**  
17:45–19:15

New Horizons Session  
**NH 1**  
Special Focus Session  
**SF 1**  
Categorical Courses  
**CC 116, CC 117**  
Mini Courses  
**MC 125, MC 119**  
Refresher Courses  
E<sup>3</sup> Sessions  
**(100)**

1

E<sup>3</sup> Session  
Hands-on Workshops  
Scientific Sessions  
**(200)**

2

**Opening Ceremony**  
  
Presentation of  
Honorary Members  
and  
Gold Medallist

E<sup>3</sup> Session  
Hands-on Workshop  
Scientific Sessions  
**(300)**  
  
**Bayer Schering Pharma Symposium**

3

State-of-the-Art Symposium  
**SA 4**  
Special Focus Session  
**SF 4**  
Categorical Courses  
**CC 417, 418**  
Mini Course  
**MC 425**  
Refresher Courses  
E<sup>3</sup> Sessions  
**(400)**

4

**Saturday, March 8**

New Horizons Session  
**NH 5**  
Special Focus Sessions  
**SF 5a, SF 5b**  
Categorical Courses  
**CC 516, CC 517, CC 518**  
Mini Course  
**MC 519**  
Refresher Courses  
E<sup>3</sup> Sessions  
Hands-on Workshop  
**(500)**

5

**ESR meets Germany**  
E<sup>3</sup> Session  
Hands-on Workshops  
Scientific Sessions  
**(600)**  
EFOMP Workshop  
  
**Hospital Management Symposium  
Bracco Symposium**

6

**Wilhelm Conrad Röntgen  
Honorary Lecture**  
  
E<sup>3</sup> FC Self Assessment Test  
  
**Workstation Face-Off Session  
Hospital Management Symposium  
GE Healthcare Symposium  
Bracco Symposium  
Siemens & Bayer Schering Pharma  
Symposium**

E<sup>3</sup> Session  
Hands-on Workshops  
Scientific Sessions  
**(700)**  
  
**Bayer Schering Pharma Symposium  
Siemens Symposium**

7

**ESR meets General Practitioners**  
Special Focus Sessions  
**SF 8a, SF 8b**  
Categorical Courses  
**CC 816, CC 817**  
Refresher Courses  
E<sup>3</sup> Session  
**(800)**  
RTF Highlighted Lectures

8

**Sunday, March 9**

New Horizons Session  
**NH 9**  
Special Focus Sessions  
**SF 9a, SF 9b, SF 9c**  
Categorical Courses  
**CC 916, CC 917**  
Mini Course  
**MC 919**  
Refresher Courses  
E<sup>3</sup> Sessions  
Hands-on Workshop  
**(900)**

9

**ESR meets Israel**  
E<sup>3</sup> Session  
Hands-on Workshops  
Scientific Sessions  
**(1000)**  
  
**GE Healthcare Symposium  
Carestream Health Symposium**

10

**Josef Lissner  
Honorary Lecture**  
  
**GE Healthcare Symposium  
Hitachi Symposium  
Bracco Symposium  
Philips Healthcare Symposium**

**Image Interpretation Quiz**  
  
Hands-on Workshops  
  
**GE Healthcare Symposium  
Guerbet Symposium  
Hologic Symposium  
Toshiba Symposium  
Philips Healthcare  
Symposium**

11

State-of-the-Art Symposium  
**SA 12**  
Special Focus Session  
**SF 12**  
Professional Challenges Session  
**PC 12**  
Categorical Courses  
**CC 1216, CC 1217, CC 1218**  
Refresher Courses  
E<sup>3</sup> Session  
**(1200)**

12

**Monday, March 10**

Special Focus Session  
**SF 13**  
Professional Challenges Session  
**PC 13**  
Categorical Courses  
**CC 1316, CC 1317**  
Refresher Courses  
E<sup>3</sup> Session  
Hands-on Workshop  
**(1300)**

13

E<sup>3</sup> Session  
Hands-on Workshops  
Scientific Sessions  
**(1400)**

14

**Peter E. Peters  
Honorary Lecture**  
  
**Toshiba Symposium  
Guerbet Symposium**

**ESR meets India**  
State-of-the-Art Symposium  
**SA 15**  
Special Focus Sessions  
**SF 15a, SF 15b**  
Categorical Courses  
**CC 1517, CC 1518**  
Refresher Courses  
E<sup>3</sup> Session  
Hands-on Workshop  
**(1500)**

15

Special Focus Sessions  
**SF 16a, SF 16b**  
Professional Challenges Session  
**PC 16**  
Categorical Courses  
**CC 1616, CC 1618**  
Refresher Courses  
E<sup>3</sup> Session  
Hands-on Workshop  
**(1600)**

16

**Tuesday, March 11**

Special Focus Sessions  
**SF 17a, SF 17b, SF 17c, SF 17d**  
Categorical Courses  
**CC 1716, CC 1718**  
Refresher Courses  
E<sup>3</sup> Session  
**(1700)**


17

E<sup>3</sup> Session  
Scientific Sessions  
**(1800)**

18

**Junior Image Interpretation Quiz**  
  
**Closing Ceremony**

welcomes you  
to its annual meeting,  
the European Congress  
of Radiology 2008



## 20<sup>th</sup> European Congress of Radiology

### Sessions in Joint Sponsorship with

#### **CIRSE**

Cardiovascular and Interventional  
Radiological Society of Europe

#### **EuroPACS**

European Society for the Promotion of  
Picture Archiving and Communication Systems  
in Medicine

#### **EUSOBI**

European Society of Breast Imaging

#### **ESCR**

European Society of Cardiac Radiology

#### **ESGAR**

European Society of Gastrointestinal and  
Abdominal Radiology

#### **ESHNR**

European Society of Head and Neck Radiology

#### **ESSR**

European Society of Musculoskeletal Radiology

#### **ESNR**

European Society of Neuroradiology

#### **ESPR**

European Society of Paediatric Radiology

#### **ESTI**

European Society of Thoracic Imaging

#### **ESUR**

European Society of Urogenital Radiology

#### **EFOMP**

European Federation of Organisations for  
Medical Physics

#### **ISRRT**

International Society of Radiographers and  
Radiological Technologists

*ESR accepts no responsibility for errors  
or misprints.*

### Congress Venue

Austria Center Vienna  
Bruno Kreisky Platz 1  
1220 Vienna, Austria

### Congress Language

English

### Onsite Opening Hours

#### **Registration**

Thursday, March 6  
09:00–19:00

Friday, March 7 to Saturday, March 8  
07:00–19:00

Sunday, March 9 to Monday, March 10  
07:00–18:00

Tuesday, March 11  
07:00–14:00

#### **Preview Centre – EDIPS**

EDIPS – ECR's Digital Preview System  
Thursday, March 6  
12:00–19:00

Friday, March 7 to Monday, March 10  
07:00–19:00

Tuesday, March 11  
07:00–14:00

#### **EPOS™ – Scientific Exhibition**

Friday, March 7 to Monday, March 10  
07:00–19:00

Tuesday, March 11  
07:00–14:00

#### **Technical Exhibition**

Friday, March 7  
14:00–18:00

Saturday, March 8 to Monday, March 10  
10:00–18:00





**Dear delegates and visitors of ECR, dear colleagues!**

With more than 17,000 participants from 94 countries, ECR has gained an outstanding position among radiological meetings worldwide. Since its re-founding in 1991 by Prof. Josef Lissner, who passed away in December 2006, ECR has again and again attracted attention with new ideas and a fresh and stylish design, which set new standards within the congress trade. The highly professional, imaginative and dedicated team at the ESR Office has continued to develop new concepts, together with the respective congress presidents and programme planning committees, with the aim to present science and education in a way to guarantee you, the ECR delegates, the biggest possible success and make every ECR a very special experience.

The increasing attractiveness of ECR is mirrored in the rise of submitted abstracts by almost 20% for this year; with a growing proportion of scientists from the Asian-pacific region, from South, Middle and North America and the Middle East. Although it is still the true European Congress of Radiology, ECR is steadily developing into an event with an international reputation and appeal. Within our 'ESR meets' programme this year, we are happy to welcome Germany, India and Israel. Eminent radiologists from these countries will present highlights and particularly interesting aspects of radiology from their countries.

Abstract submission skyrocketed, and as pleasing as that is, it means that numerous, often very good scientific abstracts had to be rejected. With an acceptance rate of 33%, ECR is at the fore of congresses worldwide; further proof of the international top quality of the scientific lectures and exhibits.

The educational programme offers a comprehensive range of refresher courses, workshops and foundation courses, with a growing focus on interactivity. Categorical courses on MDCT, MRI, and breast imaging, and mini courses on women's imaging and molecular imaging present the opportunity to gain compact and systematic information on especially important and dynamically evolving fields of our speciality.

I would like to draw your attention to two new formats that will be introduced at ECR 2008. During the session 'ESR meets Partner Disciplines', radiologists will discuss themes of common interest with top class general practitioners. We decided on coronary heart disease and peripheral occlusive artery disease as being of particular topicality. The new 'Face-off' session will allow you to experience live the efficiency of workstations from different manufacturers, e.g. in the detection of colon polyps or in the interpretation of examinations of coronary arteries.

Health systems worldwide are confronted with difficult challenges. Radiology has to be aware of its social responsibilities in a socio-economic and political context, not least in view of the political unification of Europe, which has more and more influence on the daily work of doctors. By creating ESR as common house of radiology in Europe, we have now established an organisation that can effectively represent and coordinate our interests and demands. The postponement of the EU Physical Agents Directive on electromagnetic fields is an encouraging example of this.

Radiology has to adapt to the demographic changes in our society. In the special focus session on 'Geriatric Tsunami' we will seek solutions for suitable radiological care for old and very old people. The situation of female professionals in radiology is another topic which deserves our attention. What has to be done so our female colleagues can combine family and work in a better way, and their talents, experience and skills do not get lost? Intelligent and flexible working hours and a new understanding of female roles by their male colleagues could play an important part in this necessary change. This topic will be discussed in a Professional Challenges Session moderated by the former ECR Congress President Prof. Helen Carty.

I would like to express my sincere thanks to everybody who has invested time, effort and commitment in the preparations for ECR 2008 – the Programme Planning Committee, the Subspecialty

Societies and the great many researchers who have actively contributed to the scientific and educational programme. I am especially grateful to the wonderful team at the ESR Office for their exceptional cooperation.

Vienna is a city full of history and traditions, which is at the same time young and fresh, and offers new facets and attractions again and again.

I look forward to welcoming you to this fascinating city for another marvellous ECR.



Maximilian F. Reiser  
ECR 2008 Congress President

## Committees & Dignitaries

### Programme Overviews & Floor Plans

### ECR Information from A–Z

### Programme by Topics

### Educational & Scientific Programme

<b>6</b>	<b>Committees</b>
<b>8</b>	<b>Subcommittees</b>
<b>10</b>	<b>Topic Coordinators</b>
<b>11</b>	<b>ESR Dignitaries</b>
24	Programme Overviews
34	Floor Plans
42	Meeting Rooms
45	Metro Map
48	ECR Information from A-Z
57	EIBIR – European Institute for Biomedical Imaging Research
58	CME at ECR 2008
60	ESR meets Germany, Israel, India and GPs
62	ESR e-Learning for Free
64	ESR Electronic Congress
65	IMAGINE at ECR 2008
66	Plenary Sessions
68	Image Interpretation Quizzes
69	Hospital Management Symposium
70	EPOS™ – Scientific Exhibition
72	ESR Job Forum
73	Welcome to our Industry Partners
74	Food & Drink at ECR 2008
75	Free Publications
77	European Radiology
78	ESOR – European School of Radiology
85	Special Exhibition
86	Arts & Culture
90	New Horizons Sessions
90	State-of-the-Art Symposia
91	Special Focus Sessions
96	Professional Challenges Sessions
97	Categorical Courses
100	Mini Courses
101	Refresher Courses / Scientific Sessions
120	E <sup>3</sup> – European Excellence in Education
123	Radiology Trainees Forum
124	Hands-on Workshops
128	1 <sup>st</sup> Workstation Face-Off Session
129	Satellite Symposia
134	Industry Hands-on Workshops
139	Contents
141	Postgraduate Educational Programme
268	Scientific Sessions
361	Scientific and Educational Exhibits
450	List of Authors and Co-authors
499	List of Moderators
502	Personal Planner

## ESR Executive Council

### ESR President

A. Adam; London/UK

### ESR 1<sup>st</sup> Vice-President

I.W. McCall; Oswestry/UK

### ESR 2<sup>nd</sup> Vice-President

G. Frija; Paris/FR

### Members

A.L. Baert; Leuven/BE

J.I. Bilbao; Pamplona/ES

L. Bonomo; Rome/IT

É. Breatnach; Dublin/IE

A.K. Dixon; Cambridge/UK

L. Donoso; Sabadell/ES

G.P. Krestin; Rotterdam/NL

B. Marincek; Zurich/CH

Y. Menu; Le Kremlin-Bicêtre/FR

A. Palkó; Szeged/HU

M.F. Reiser; Munich/DE

B. Silberman; Paris/FR

M. Szczerbo-Trojanowska; Lublin/PL

P. Baierl; Vienna/AT

## ESOR Steering Committee

### Scientific/Educational Director:

N. Gourtsoyannis; Iraklion/GR

### Committee Members:

M. Szczerbo-Trojanowska; Lublin/PL

C.D. Becker; Geneva/CH

G. Mostbeck; Vienna/AT

### Ex-officio Member:

W. Steinbrich; Basel/CH

### Co-opted Members:

B. Marincek; Zurich/CH

A. Palkó; Szeged/HU

## ECR Committees and Topic Coordinators

### Congress President

M.F. Reiser; Munich/DE

### 1<sup>st</sup> Congress Vice-President

B. Marincek; Zurich/CH

### 2<sup>nd</sup> Congress Vice-President

M. Szczerbo-Trojanowska; Lublin/PL

## PROGRAMME PLANNING COMMITTEE

### Postgraduate Educational Programme

**Chairman:** M. Szczerbo-Trojanowska; Lublin/PL

**Members:** A.M. Davies; Birmingham/UK

M.I. Furmanek; Warsaw/PL

R. Lencioni; Pisa/IT

P.K. Prassopoulos; Alexandroupolis/GR

C. Roche; Galway/IE

V.E. Sinitsyn; Moscow/RU

M.M. Thurnher; Vienna/AT

J. Vilar; Valencia/ES

### Scientific Papers

**Chairman:** Y. Menu; Le Kremlin-Bicêtre/FR

**Members:** U. Bick; Berlin/DE

I.M. Björkman-Burtscher; Lund/SE

S.J. Golding; Oxford/UK

### Scientific Exhibition (EPOSTM)

**Chairman:** B. Hamm; Berlin/DE

**Members:** O. Akhan; Ankara/TR

R. Hermans; Leuven/BE

### Categorical Courses

**Coordinators:** C. Catalano; Rome/IT


M. Prokop; Utrecht/NL

S.O. Schönberg; Mannheim/DE

A. Tardivon; Paris/FR

### E<sup>3</sup> – Interactive Teaching Sessions

**Coordinator:** J. Cáceres; Barcelona/ES



### **Foundation Course**

*J.I. Bilbao; Pamplona/ES*

### **Interactive Teaching Course**

*J. Cáceres; Barcelona/ES*

### **E-Learning**

*D. Caramella; Pisa/IT  
P. Pokieser; Vienna/AT*

### **Cases-of-the-Day**

*A. Palkó; Szeged/HU*

### **Physics Programme**

*J. Damilakis; Iraklion/GR*

### **Image Interpretation Quiz**

*A. Watkinson; Exeter/UK*

### **Junior Image Interpretation Quiz**

*H.J. Michaely; Mannheim/DE*

### **Evaluation**

*K. Kinkel; Chêne-Bougeries/CH*

### **Liaison 'European Radiology'**

*A.L. Baert; Leuven/BE  
A.K. Dixon; Cambridge/UK*

### **Technical Exhibition**

*B. Marincek; Zurich/CH*

## **TECHNICAL EXHIBITION COMMITTEE**

### **Members**

*P. Baierl, Executive Director, ESR  
M.C. Cedrini, Bracco  
Z. Dakic, Philips Healthcare  
N. Denjoy, COCIR  
S. Hammer, GE Healthcare  
K. Koolen, AGFA HealthCare  
J. Kulla, Siemens Medical Systems  
R. Wies, IPCAA*

### **Supporting Member Companies**

#### **2-Star level:**

*Az Corp.  
Shimadzu  
Vital Images*

#### **4-Star level:**

*Agfa  
Bayer Schering Pharma  
Bracco  
Carestream Health  
GE Healthcare  
Hitachi  
Philips Healthcare  
Siemens Medical Systems*

**SCIENTIFIC SUBCOMMITTEES**
**Abdominal and Gastrointestinal**

**Chairmen:** T.K. Helmberger; Lübeck/DE  
W. Schima; Vienna/AT

**Members:** N. Elmas; Izmir/TR  
K.A. Herrmann; Munich/DE  
A. Laghi; Latina/IT  
P. Lefere; Roeselare/BE  
D.J. Lomas; Cambridge/UK  
D.E. Malone; Dublin/IE  
G. Morana; Treviso/IT  
B. Op de Beeck; Antwerp/BE  
N. Papanikolaou; Iraklion/GR  
J. Puig Domingo; Sabadell/ES  
A.-S. Rangheard;  
Le Kremlin-Bicêtre/FR  
J. Stoker; Amsterdam/NL  
I. Távora; Lisbon/PT  
C. Triantopoulou; Athens/GR  
V. Válek; Brno/CZ  
D. Weishaupt; Zurich/CH

**Breast**

**Chairman:** R. Chersevani; Gorizia/IT  
**Members:** S. Barter; Bedford/UK  
C. Boetes; Nijmegen/NL  
G. Esen; Istanbul/TR  
C.K. Kuhl; Bonn/DE  
P. Skaane; Oslo/NO  
M. Torres Tabanera; Madrid/ES  
A. van Steen; Leuven/BE  
B. Vitak; Linköping/SE

**Cardiac**

**Chairman:** M. Pasowicz; Krakow/PL  
**Members:** T. Bader; Vienna/AT  
R. Fattori; Bologna/IT  
C. Herzog; Munich/DE  
N.L. Kelekis; Athens/GR  
A.J.B.S. Madureira; Porto/PT  
G. Roditi; Glasgow/UK  
R. Soler; La Coruña/ES  
P.M.A. van Ooijen; Groningen/NL

**Chest**

**Chairman:** C. Schaefer-Prokop; Amsterdam/NL  
**Members:** W. De Wever; Leuven/BE  
G. Ferretti; Grenoble/FR  
F. Gleeson; Oxford/UK  
M. Herman; Olomouc/CZ  
N. Howarth; Chêne-Bougeries/CH  
A.R. Larici; Rome/IT  
I.E. Tyurin; Moscow/RU  
D. Wormanns; Berlin/DE

**Computer Applications**


**Chairman:** E.R. Ranschaert; 's-Hertogenbosch/NL  
**Members:** A. Abildgaard; Oslo/NO  
K. Foord; St. Leonards-on-Sea/UK  
P. Mildemberger; Mainz/DE  
E. Pietka; Gliwice/PL  
J. Reponen; Raaha/FI  
P. Sacco; Siena/IT

**Molecular Imaging and Contrast Media**

**Chairman:** W. Semmler; Heidelberg/DE  
**Members:** J.O. Barentsz; Nijmegen/NL  
A. Bischof Delaloye; Lausanne/CH  
C. Bremer; Münster/DE  
E. Canet Soulas; Bron/FR  
C. Moonen; Bordeaux/FR  
S.K. Morcos; Sheffield/UK  
H.S. Thomsen; Herlev/DK  
B. van Beers; Brussels/BE

**Genitourinary**

**Chairman:** A. Magnusson; Uppsala/SE  
**Members:** C.S. Balleyguier; Villejuif/FR  
B. Brkljacic; Zagreb/HR  
T.M. Cunha; Lisbon/PT  
K. Darge; Würzburg/DE  
J.J. Fütterer; Nijmegen/NL  
V. Løgager; Copenhagen/DK  
J. McHugo; Birmingham/UK  
M. Memarsadeghi; Vienna/AT



## Head and Neck

**Chairman:** C. Czerny; Vienna/AT

**Members:** L. Akesson; Lund/SE  
T. Beale; London/UK  
M. Keberle; Hannover/DE  
B. Kress; Frankfurt/DE  
M.M. Lemmerling; Gent/BE  
F. Pameijer; Amsterdam/NL  
M. Scaglione; Naples/IT  
H. Thoeny; Berne/CH  
A. Trojanowska; Lublin/PL

## Interventional Radiology

**Chairman:** R. Morgan; London/UK

**Members:** P.E. Andersen; Odense/DK  
E. Boullosa; Vigo/ES  
B. Dolgushin; Moscow/RU  
R. Gandini; Rome/IT  
W.R. Jaschke; Innsbruck/AT  
M. Köcher; Olomouc/CZ  
S. Müller-Hülsbeck; Kiel/DE  
M. Sapoval; Paris/FR

## Musculoskeletal

**Chairman:** A. Cotton; Lille/FR

**Members:** S.E. Anderson; Berne/CH  
I. Boric; Zagreb/HR  
A.J. Grainger; Leeds/UK  
E. Llopis; Valencia/ES  
C. Martinoli; Genoa/IT  
A.R. van Erkel; Leiden/NL  
F.M.H.M. Vanhoenacker; Antwerp/BE  
K. Wörtler; Munich/DE

## Neuro

**Chairman:** G. Wilms; Leuven/BE

**Members:** L. Biscoito; Lisbon/PT  
J.-F. Bonneville; Besançon/FR  
M. Essig; Heidelberg/DE  
B. Gómez-Ansón; Barcelona/ES  
K.-O. Løvblad; Geneva/CH  
A. Rossi; Genoa/IT  
R. Siemund; Lund/SE  
E.T. Tali; Ankara/TR

## Pediatric

**Chairman:** F.E. Avni; Brussels/BE

**Members:** M.I. Argyropoulou; Ioannina/GR  
J.-F. Chateil; Bordeaux/FR  
J. Fonseca-Santos; Lisbon/PT  
M.P. García-Peña; Barcelona/ES  
C.J. Kellenberger; Zurich/CH  
E. Kis; Budapest/HU  
C. Owens; London/UK  
G. Staatz; Erlangen/DE

## Physics in Radiology

**Chairman:** K. Faulkner; Wallsend/UK

**Members:** E. Atalar; Ankara/TR  
H. Bosmans; Leuven/BE  
S. Christofides; Nicosia/CY  
C. Leidecker; Forchheim/DE  
M. Tosetti; Pisa/IT  
R. Wirestam; Lund/SE  
U. Zdesar; Ljubljana/SI

## Radiographers

**Chairmen:** J. Camps Herrero; Valencia/ES

D. Katsifarakis; Athens/GR  
**Members:** B.T. Andersson; Lund/SE  
S. Braico; Rome/IT  
H. Harries-Jones; Poole/UK  
A. Hartvig Sode; Odense/DK  
A. Lukken; Tartu/EE  
S. Muscat; Dingli/MT

## Vascular

**Chairman:** C. Catalano; Rome/IT

**Members:** T. Jargiello; Lublin/PL  
A.F. Kopp; Tübingen/DE  
C. Loewe; Vienna/AT  
L. Lönn; Copenhagen/DK  
H.I. Manninen; Kuopio/FI  
Z. Morvay; Szeged/HU  
T. Sabharwal; London/UK  
D.K. Tsetis; Iraklion/GR

## TOPIC COORDINATORS

### Categorical Courses

#### MRI

*S.O. Schönberg; Mannheim/DE*

#### Breast: From Basics to Advanced Imaging

*A. Tardivon; Paris/FR*

#### Multidetector CT Made Easy

*C. Catalano; Rome/IT*

*M. Prokop; Utrecht/NL*

### Mini Courses

#### Molecular Imaging

*O. Clément; Paris/FR*

#### Women's Imaging: Female Pelvis

*H. Hricak; New York, NY/US*

### E<sup>3</sup>-European Excellence in Education

#### Foundation Course:

##### Interventional Radiology

*J.I. Bilbao; Pamplona/ES*

#### Interactive Teaching Course:

##### Useful Signs in Imaging

*J. Cáceres; Barcelona/ES*

#### Interactive Teaching Sessions

*J. Cáceres; Barcelona/ES*

#### Breast Imaging

*T.H. Helbich; Toronto, ON/CA*

### Hands-on Workshops

#### Image Guided Breast Biopsy: How to do it

*C.S. Balleyguier; Paris/FR*

*T.H. Helbich; Toronto, ON/CA*

#### Experience Vascular Procedures

##### Using Simulators

*T. Sabharwal, London/UK*

#### Tips and Tricks in Radiofrequency Ablation

*R. Lencioni; Pisa/IT*

#### Test-Driving your Workstation

*D. Caramella; Pisa/IT*


*W.J. Niessen; Rotterdam/NL*

*B.M. ter Haar Romeny; Eindhoven/NL*

#### 1<sup>st</sup> Workstation Face-Off Session

*A. Graser; Munich/DE*





## ESR Dignitaries




### **Lifetime Achievement Award**

Albert L. Baert; Leuven/BE




### **Gold Medallist**

Nicholas Gourtsoyiannis; Iraklion/GR



### **Honorary Members**

R. Gilbert Jost; St. Louis, MO/US  
Frederick S. Keller; Portland, OR/US  
Lizbeth M. Kenny; Brisbane, QLD/AU



### **Inaugural Lecturer**

Ernst Pöppel; Munich/DE

### **Honorary Lecturers**

Jürgen Hennig; Freiburg/DE  
Christiane K. Kuhl; Bonn/DE  
James H. Thrall; Boston, MA/US



**Albert L. Baert**  
Leuven/BE

**Lifetime Achievement Award**

was born in 1931 in Meldert, Belgium. He obtained his medical degree in 1956 and his diploma in medical radiology in 1961 from Leuven Catholic University.

He further specialised in diagnostic radiology at the University Hospitals of Hamburg, Leuven, Paris and Zurich. In 1968 he received a PhD degree from Leuven Catholic University for a dissertation entitled 'Angiography of Renal Tumours'.

Now a Professor Emeritus with special assignment, Albert Baert started teaching at Leuven University in 1962 and rose through the academic ranks to obtain full professorship in 1971. The same year, he was appointed Chairman of the Department of Radiology of the University Hospitals of Leuven, which developed into one of the largest departments in Europe under his leadership, acquiring fame for its clinical research performed in the areas of abdominal sectional imaging (US, CT, MRI). In 1986, Prof. Baert was appointed member of the Board of Directors of the University Hospitals of Leuven, before becoming their Deputy Medical Director in 1994. He also served as Chairman of the Belgian Government Committee for Radiological Board Certification from 1987 to 1997.

His interests in lymphography, angiography and later body CT tomography were reflected in 580 authored or co-authored scientific papers, numerous book chapters and 5 books. His book on contrast enhancement body CT tomography, first published in 1981, rapidly became a standard for this new revolutionary imaging method. He has also widely lectured on these topics in both Europe and the United States.

His exceptional achievements have been internationally acclaimed and he has been awarded Honorary Membership by prestigious societies such as:


*the Radiological Society of North America, the International Society of Radiology, the Faculty of Radiologists of the Royal College of Surgeons Ireland, the Czech Society of Radiology, the German Society of Radiology, the Royal College of Radiology, the Russian Radiological Society, the Slovakian Radiological Society, the Italian Radiological Society, the Hungarian Radiological Society, the Société française de Radiologie, the Österreichische Röntgengesellschaft and the Cardiovascular and Interventional Radiological Society of Europe (CIRSE).*

Prof. Baert also received membership of the Russian Academy of Medical Sciences and many national and international scientific awards, including the Röntgenplakette and the Schinz Medaille.

His outstanding scientific involvement aside, he has also greatly contributed to the development of radiology in Europe. He was twice appointed President of the European Congress of Radiology (1993 and 1995), and eventually received the ECR Gold Medal in 1999. He was also President of the European Association of Radiology (EAR) from 1995 until 1997.

Although retired since 1997, he has remained extremely active. He has been editor-in-chief of *European Radiology* for twelve years, a position from which he will resign in December 2007. Under his leadership, *European Radiology* has become the second highest ranked truly general radiological journal.

**In recognition of his exceptional achievements in radiology, particularly in the field of peripheral angiography and abdominal CT, as well as his leadership and crucial role in the development of radiology in Europe, Professor Albert L. Baert is honoured with a Lifetime Achievement Award from the European Society of Radiology.**



**Gold Medallist**

was born in Amfissa, Greece, in 1943. He obtained his medical degree from Thessaloniki University in 1967 and his doctoral thesis from Athens University in 1977. After a three-year internship in Internal Medicine at the Red Cross Hospital of Athens, he completed a three-year residency in Radiology at Evangelismos Hospital in Athens and did a 2-year fellowship at the Radcliffe Infirmary in Oxford (1977–1979). He served the Hellenic Air Forces Hospital in Athens between 1975 and 1987, where he was head of the Radiology Department after 1981.

He was elected Associate Professor of Radiology of the University of Crete in 1986, and since 1990 he has been Professor and Chairman of the Department of Radiology. He has served as the first Medical Director at the University Hospital of Crete (1997–1999) and spent two terms as Dean of the Faculty of Medicine of the University of Crete (1999–2001 and 2001–2003).

Professor Gourtsoyiannis is the founding father of the Hellenic College of Academic Radiology. He has served as its President from 1997 until 2001 and he is its Honorary President. He is also a founding member of the European Society of Gastrointestinal and Abdominal Radiology (ESGAR). He was President of two of the annual ESGAR meetings (1990, 1996), President of the Society (1997–2000), and President of the joint European (ESGAR) and American (SGR) Abdominal congress in 2006.

His greatest interest has been in the radiology of diseases of the small intestine, and he is currently contributing to the evaluation of small bowel imaging with MR. His work in Radiological-Pathologic Correlation spurred him on to mastermind

**Nicholas Gourtsoyiannis  
Iraklion/GR**



ECR's Categorical Course and Syllabi in this discipline, introducing Radiological-Pathologic Correlation at ECR. An active researcher, he has published more than 250 scientific articles in international peer-reviewed journals and he has written or co-written 28 book chapters.

He has served on the Editorial Board of numerous journals, including *Abdominal Imaging*, *Investigative Radiology*, *Acta Radiologica* and *Magnetic Resonance in Medical Science*. He has also been the editor of *Hellenic Radiology*. He is currently section editor of *European Radiology* and a reviewer for several national and international scientific journals on medical imaging and gastrointestinal diseases. Last but not least, he is also the editor or co-editor of 3 books, *Imaging of Small Bowel Tumors* (Elsevier, 1997), *Small Bowel Imaging* (Springer-Verlag, 2003) and *Radiologic-Pathologic Correlations* (Springer-Verlag, 2005).

Nicholas Gourtsoyiannis has been visiting professor at 23 Universities and he has delivered more than 250 invited lectures worldwide. In recognition of his international achievements and the excellence of his work, he has been awarded honorary membership by the following societies:

*the Radiological Society of North America, the British Institute of Radiology, the French Society of Radiology, the Radiological Society of Switzerland, the Austrian Society of Radiology, the Italian Society of Medical Radiology, the Royal Belgian Radiological Society, the Argentinean Society of Radiology, the Bulgarian Association of Radiology, the Association of Bosnia and Herzegovina Radiologists, the Turkish Radiological Society, the Hungarian Society of Radiology, the Nordic Radiological Society, the Swedish Society of Radiology and the Polish Society of Medical Radiology.*

**Nicholas Gourtsoyiannis**  
**Iraklion/GR****Gold Medallist**

He has also received honorary fellowships from the Royal College of Radiologists (UK) and the Royal College of Surgeons (Ireland), and he is a member of the Russian academy of medical sciences. He is the recipient of the 2000 Gold Medal of ESGAR, the 2001 Olson Medal of Sweden, the 2003 Schinz Medal of Switzerland, the first Gold Medal of the Hellenic Society of Radiology in 2004 and the Boris Rajewsky Medal of the EAR in 2007.

He was President of ECR in 2003 and chairman of the ECR executive committee in 2004. From 1999 to 2003 he was chairman of the subspecialties committee of the EAR and from 2004 to 2007 he was President of the European Association of Radiology (EAR). He introduced the Electronic Presentation Online System (EPOS™) and the European School of Radiology (ESOR), and he masterminded the creation of the European Society of Radiology (ESR). Nicholas Gourtsoyiannis was the first President of the European Society of Radiology (Dec 2006 to March 2007).

He is now the Scientific/Educational Director of the European School of Radiology and currently serves as Secretary General of the International Society of Radiology.

He and his wife Emmy have two children, Christos and Sofia, who also is a radiologist.

**In recognition of his exceptional achievements in radiology, particularly in the field of gastrointestinal imaging, as well as his leadership and pivotal role in the creation of ESR, Professor Nicholas Gourtsoyiannis is awarded the Gold Medal of the European Society of Radiology.**



**Honorary Member**

**R. Gilbert Jost**  
**St. Louis, MO/US**



was born in 1942 in Philadelphia, Pennsylvania. He earned a bachelor's degree from Harvard University in 1964 and a medical degree from Yale University in 1969.

After an internship in internal medicine in Cleveland, Ohio, he worked for two years as a research associate for the National Institutes of Health at the Laboratory of Neural Control in Bethesda, Maryland. However, in 1972, he opted for a residency in radiology, which he completed in 1975, holding the position of Chief resident at Mallinckrodt Institute of Radiology (MIR), Washington University School of Medicine in St. Louis, Missouri.

Since that time, Dr. Jost has spent his entire professional career at the Mallinckrodt Institute. In 1985 he was promoted to the rank of Professor of Radiology, and in the same year, he was named Chief of Diagnostic Radiology and he was appointed as an Affiliate Professor of Computer Science. He assumed the leadership of the Department in 1999. He is currently the Elizabeth Mallinckrodt Professor of Radiology, chair of the Department of Radiology at Washington University, director of the Mallinckrodt Institute of Radiology, and radiologist-in-chief at Barnes-Jewish Hospital, one of America's elite medical centres.

Dr. Jost is an internationally recognised leader in computer applications in radiology and informatics. In view of his long time interest in radiology information systems, particularly the conversion of radiologic images into digital form, it is not surpris-

ing that he has played a key role on the Radiology of North America (RSNA) Radiology Informatics Committee (formerly the Electronic Communication Committee). He joined the committee in 1993 and served as its chair in 1999. He has been a key figure and has influenced some of the specialty's most important information technology projects, including the adoption of the Digital Imaging and Communications in Medicine, or DICOM, standard. He was instrumental in launching the movement to establish standardised computer interfaces in medicine which is known as Integrating the Healthcare Enterprise (IHE).

Dr. Jost is the author or co-author of 120 scientific peer-reviewed articles, and has been invited to present his work more than 90 times at scientific meetings. He is a fellow of the American College of Radiology (ACR) as well as an Inaugural Fellow of the Society for Computer Applications in Radiology. Last but not least, he has served on the RSNA Board of Directors for eight years and was appointed as President of that Society in 2007.

He has been married since 1967 to Margaret Ann Carr, with whom he has two daughters, Sarah and Amy.

**In recognition of his exceptional achievements in radiology, and particularly his commitment to improving information technology in its practise, Professor R. Gilbert Jost is awarded Honorary Membership of the European Society of Radiology.**



**Frederick S. Keller**  
Portland, OR/US

**Honorary Member**

was born in Pittsburgh, Pennsylvania/US, in 1942. He graduated from Swarthmore College, Pennsylvania, in 1964, and received his medical degree from the University of Pennsylvania Medical School in Philadelphia in 1968. He then completed an internship at the University of Wisconsin Hospital and Clinics in Madison in 1969, and a residency at the University of Oregon Medical School in Portland in 1977. He was chief resident and a fellow of the American Cancer Society in 1976–1977. Certified with the American Board of Radiology in 1977, Professor Keller received a Certificate of Added Qualification in Vascular and Interventional Radiology in 1994, recertified in 2003.


Director of the Dotter Interventional Institute of the Oregon Health and Science University (OHSU) since 1993, Frederick S. Keller has been active in both the clinical and academic aspects of interventional radiology at OHSU. He is the Cook Professor of Interventional Therapy, medical director of the Department of Interventional Radiology, professor of Surgery and chair of the Department of Diagnostic Radiology at OHSU.

Active in the interventional radiology professional community, Prof. Keller belongs to numerous vascular and interventional radiology organisations. He served on the executive committee for the Society of Cardiovascular and Interventional Radiology (SCVIR) and was president of that society in 1999. He has also served on the board of directors of the Cardiovascular and Interventional Radiology Research and Educational Foundation (CIRREF) since 1996 and became chairman in 1999. He holds directorships on the boards of the Medical Technology Research Forum and the University Medical Group at Oregon Health Sciences University.

During his career, Prof. Keller has been responsible for training 50 fellows in interventional radiology and in introducing interventional radiology to over 150 diagnostic radiology residents. Prof. Keller's academic contributions have been recognised by his students. Residents of both the radiology and internal medicine departments named him outstanding teacher and best radiology discussant. He has authored 230 scientific papers and book chapters, and delivered or participated in more than 1,000 lectures, panels and exhibits all over the world. He has also served, or serves, on the editorial boards for the *Journal of Interventional Radiology*, *Seminars in Interventional Radiology*, *Cardiovascular and Interventional Radiology*, and the *Journal of Vascular and Interventional Radiology*.

Professor Keller was named Honorary Professor at the Third Beijing University School of Medicine, Beijing, China in 1994; Professor Titular of the Faculty of Medicine, Universidad de Buenos Aires, Argentina, in 1997; Honorary Member of the Japanese Society of Radiology. He was awarded the gold medal of the Society of Interventional Radiology in 2005; became a distinguished fellow of the Cardiovascular and Interventional Radiology Society of Europe and an honorary fellow of the British Society of Interventional Radiology. Also, in 2005, an endowed chair, the Frederick S. Keller Chair of Interventional Radiology, was established in his honour at the Oregon Health and Science University.

**In recognition of his untiring efforts in the field of radiological education, training and research, Professor Keller is awarded Honorary Membership of the European Society of Radiology.**



**Honorary Member**

**Lizbeth M. Kenny**  
**Brisbane, QLD/AU**



was born in Glasgow, Scotland, in 1957 and immigrated to Brisbane Australia at the age of 12. She earned a medical degree in 1980 from Queensland University and undertook her residency at the Royal Brisbane Hospital. She then undertook specialty training in radiation oncology in 1983 and completed this in 1987.

After nine years in private practice, she decided to return to the Royal Brisbane and Women's Hospital where she was appointed as a senior staff specialist in radiation oncology. In 2005 she became Director of Cancer Services for the Central Area Health Service in Queensland, which encompasses a large part of Queensland with the Royal Brisbane and Women's as the principal tertiary and quaternary referral hospital providing many state wide services. There, Dr. Kenny has been jointly responsible for developing a state wide implementation plan for cancer services, which has required clinical, bureaucratic and political buy-in. She has also established the fellowship programme in radiation oncology in Queensland.

A strong advocate for multidisciplinary care, in 2002 she was elected President of the Clinical Oncological Society of Australia, an umbrella organisation with over 20 specialist, craft and tumour specific groups involved in clinical cancer care. She thus contributed to the development of the national service improvement framework for cancer. She was also Chairman of the National Assessment of Clinical Cancer Research Grants Applications from 2001–2004 and currently serves on a number of committees for Cancer Australia.

From 2005 to 2007, Dr. Kenny has been President of the Royal Australian and New Zealand College of Radiologists (RANZCR), with which she has been involved since attaining fellowship. She was also elected to the Radiation Oncology Faculty Board in 1995 and became Dean of the Faculty of Radiation

Oncology, serving two terms in this capacity from 1998 to 2002. During her term as Dean she instigated and chaired the development of the National Strategic Plan for Radiation Oncology in Australia. In addition, she chairs the development of the Quality Program in Radiation Treatment Service Delivery.

In her capacity as President of RANZCR, Dr. Kenny has been committed to refocusing the role of radiologists as central in patient care and management. She is convinced that involving radiologists early in clinical diagnosis and management is more likely to get the correct test done properly the first time and reduce the burden on the entire medical system. Although this model of care requires major changes to legislation and practice in Australia and New Zealand, it is likely to lead to improved patient care and a reduction in unnecessary exposure.

Overseas, Dr. Kenny has served on the International Relations Committee of the European Society of Radiology and the International Advisory Board of the Radiological Society of North America. She has also been invited to become a member of the QUESTRO project for ESTRO – the European Society for Therapeutic Radiation Oncology. She has been a guest visitor to ASTRO (American Society of Therapeutic Radiation Oncology) on two occasions and a member of the International Affairs Committee to the American Society of Clinical Oncology.

She has been married to Colin since 1978 and they have two children, William and Sophie. Liz's family remains the most important focus of her life and she is immensely grateful for their support in everything that she does.

**In recognition of her exceptional achievements, especially in emphasising the clinical role of radiology in cancer care, Dr. Liz Kenny is awarded Honorary Membership of the European Society of Radiology.**



**Ernst Pöppel**  
Munich/DE

**Inaugural Lecturer**

was born in 1940 in Schwessin, Germany. He studied psychology and biology in Germany and Austria, and obtained a PhD. degree in psychology from Innsbruck University in 1968. He then went to the US where he successively worked as a research associate at the Department of Psychology and Brain Science and as a staff scientist for a neuroscience research programme at the prestigious Massachusetts Institute of Technology (MIT).

Back in Europe, he completed two Habilitationen (postdoctoral lecture qualifications), one in Sensory Physiology at the Medical Faculty of Munich University, the other in Psychology at the Science Faculty in Innsbruck. In parallel, he worked as a fellow and research associate for several Max-Planck-Institutes.

In 1976 he became Professor (Ordinarius) in Medical Psychology at the Munich University, a position he has held since. From 1968, he has been teaching lectures and seminars in Medical Psychology, Neuropsychology, Psychophysics, Sensory Physiology and Special Areas of Philosophy at the Faculty of Medicine of Jena and Munich, as well as the Faculty of Natural Sciences of Innsbruck.

Prof. Pöppel has been the head of the Institute of Medical Psychology since 1977, and of the Human Science Centre since 1997, both at Munich University.

Between 1992 and 1997, he was on the board of directors of the 'Forschungszentrum Jülich' (medicine,

biotechnology, and environmental research), where he founded a brain imaging centre.

His main fields of research are neuropsychology of perception of the visual modality, restitution of functions after brain injuries, and neuropsychological rehabilitation, as well as temporal perception in neural systems and behaviour. His involvement in research has gained him many distinctions, including membership of the European Academy of Sciences and Art, the J.E. Purkinje Medal of the Czech Medical Society and the Award of the Association of German Medical Journalists.

He has also been offered membership by well established societies such as the International Brain Research Organisation (IBRO), the European Brain and Behaviour Society (EBBS), the European Neuroscience Association (ENA) and the Society for Neuroscience.

He has published some 350 scientific articles, on visual perception, temporal control, and on general neuroscientific problems, and more than 20 books, some for the general public. He has delivered approximately 1,000 lectures worldwide. He has overseen some 30 co-workers' Habilitationen and about 250 students' MD's and PhD's.

**In recognition of his exceptional achievements and his leadership in neurosciences as well as in research and teaching, Professor Ernst Pöppel will present the Inaugural Lecture 'Images in the brain – pictures in the eyes' at ECR 2008.**





**Honorary Lecturer**

**Jürgen Hennig  
Freiburg/DE**

was born in 1951 in Stuttgart, Germany. He earned a PhD in physical chemistry from the Albert Ludwig Freiburg University.

After one year of research as a fellow, he left for Switzerland where he undertook two years of postdoctorate study at the Department of physical chemistry of Zurich University. But he soon came back to Freiburg University to install a clinical MR institute at the Department of Radiology, where he headed research until 1992. He obtained full Professorship one year later.

In 1998, he was appointed Chairman of the section of Medical Physics of the service of diagnostic radiology, where he was eventually appointed research Director three years later. The same year, he took the lead of the newly established 'Magnetic Resonance Development and Application Centre' (MRDAC) at Freiburg University.

He has been Co-Chairman and Scientific Director of the Department of Radiology – Medical Physics at the University Hospital Freiburg since 2004.

Jürgen Hennig's contribution to MRI has been crucial to the development of this modality. Under his leadership, the Freiburg MR research group has implemented new ideas and concepts for the use of MRI in a broad spectrum of applications. The measurement procedures they developed have since been implemented in all MRI devices worldwide, and are used for all MRI patient examinations. The core of their development work has been in the establishment of fast and ultra-fast MRI, the functional imaging of brain and heart, molecular imaging for the development of highly selective contrast agents, and in the use of MRI for the development and testing of new drugs.

These achievements have earned Jürgen Hennig the recognition of his peers and prestigious awards: the European Magnetic Resonance Award in 1992, the Kernspintomographie Preis in 1993, and the

Gold Medal of the Society of Magnetic Resonance in 1994. He notably served as President of the International Society of Magnetic Resonance in Medicine (ISMRM). Lately, he was honoured with the Max Planck Award in the category Medicine/Life Sciences (2004) and the Albers-Schönberg Medal of the German Radiological Society (2006). In 2006, he was also appointed Scientific Director of the European Institute for Biomedical Imaging Research (EIBIR).

Over the years, Prof. Hennig has also shown a real commitment to sharing his knowledge with colleagues from all over the world, and has been striving for developing cooperation between Europe and other continents. As a young man, he went to study chemistry in the UK and Switzerland. In 2002 he was offered a Dunhill-Chair for Neuroscience at the University of Oxford.

Lately, his foreign activities have attracted him more and more eastwards. Chairman of the Academic Committee for the new National MRI Brain Mapping Centre in Beijing, he is also President of the European-Chinese Society for Clinical Magnetic Resonance. In 2003, he was notably awarded Honorary Membership by the Chinese Medical Society and Chinese Radiological Society.

He is also the current chairman of the Scientific Advisory Board 'Singapore Brain Imaging Centre', as well as a member of the Academy of Science of Tatarstan Republic.

He has been married since 1984 to Annemarie Hennig-Rüegg with whom he has two children, Julian and Olivia.

**In recognition of his outstanding achievements in the field of MRI, Professor Jürgen Hennig is invited to be an Honorary Lecturer of the European Congress of Radiology. He will present the Wilhelm Conrad Röntgen – Honorary Lecture: 'Pushing the speed limits in MR imaging'.**



**Christiane K. Kuhl**  
Bonn/DE

**Honorary Lecturer**

was born in 1966 in Bonn, Germany. She obtained a medical degree from Bonn University in 1991. After a residency in radiology from 1992 to 1996, and a doctoral thesis on 31P magnetic resonance spectroscopy in mitochondrial encephalomyopathies (obtained with *summa cum laude*), she undertook a residency in neurosurgery in 1996–1997. She completed it with a fellowship in neuro-radiology in 2002, and is a board certified neuro-radiologist. Since 2004, she has been Professor of Radiology and Vice Chairman of the Radiological department, as well as Director of the Division of oncologic imaging and interventional therapy of Bonn University.

Her main fields of interest are breast imaging, oncological imaging and interventional oncology (minimally-invasive therapy of cancers and metastases), as well as high field MR imaging. Professor Kuhl's work on early and non-invasive diagnosis of breast cancer has been frequently saluted by her peers. She was notably the first woman to receive the European Magnetic Resonance Award (2006) and her research is available and documented on both sides of the Atlantic. She received the American College of Radiology Imaging Network award for 'Outstanding Contributions' in 2004 and an Honorary Membership at the Royal College of Radiologists Breast Group (UK) in 2006. Back home, she has received the Award for Technical Innovation of the German Federal Ministry of Science and Education (2000) and the 'Holthusen-Ring', the highest award for scientific achievements of the German Radiological Society (2003).

Her contribution to the medical sphere has also been recognised by other specialties such as oncology. During the last American Society of Clinical Oncology (ASCO) congress, the paper she and her colleagues presented was selected as

'Best of ASCO', for their discovery that, to detect pre-invasive breast cancer (DCIS), the addition of high-resolution MRI offers a significantly higher sensitivity compared with state-of-the-art mammography.

Prof. Kuhl belongs to a number of prestigious subspecialty and international societies such as the Radiological Society of North America (RSNA), the International Society of Magnetic Resonance in Medicine (ISMRM), and the American Society of Clinical Oncology (ASCO). She is also a member of the 'Working Group on Breast MRI' at the National Cancer Institute, Bethesda, Maryland, US, and member of the Breast Section of ACRIN (American College of Radiology Imaging Network).

In addition to 23 review articles, about 240 citeable scientific abstracts and 7 book chapters, she authored 76 original articles. These latter yielded a total of 326 impact factors – a number that indicates the quality of the respective publications. She is associate editor and consultant to the editor of *Radiology*, and a member of the scientific editorial board of *RöFo* (Journal of the German Radiological Society), and a peer reviewer for *Journal of Magnetic Resonance*, *Journal of Clinical Oncology European Journal of Cancer*, and *Nature Medicine*, among others.

**In recognition of her outstanding contributions to basic and applied research in medical magnetic resonance, particularly in breast imaging, Professor Christiane K. Kuhl is invited to be an Honorary Lecturer of the European Congress of Radiology. She will present the Peter E. Peters – Honorary Lecture entitled 'New paradigms in breast imaging'.**



**Honorary Lecturer**

**James H. Thrall**  
Boston, MA/US



was born in 1943 in Ann Arbor, Michigan. He obtained his Bachelor's degree in mathematics at the University of Michigan in 1964 and his medical degree from University of Michigan Medical School, Ann Arbor, Michigan in 1968.

He completed training in Radiology and Nuclear Medicine at the Walter Reed Army Medical Center, Washington, D.C. where he subsequently served as the Assistant Chief of Nuclear Medicine from 1973–1975. He returned to the University of Michigan as Assistant Professor of Internal Medicine and Radiology in 1975 and was promoted to Professor in 1981.

Prof. Thrall served for five years as Chairman of the Department of Radiology at the Henry Ford Hospital in Detroit, Michigan, where he was also a physician trustee and held the position of vice-chairman of the Board of Governors of the Henry Ford Medical Staff. He also served on the Board of Trustees of the Henry Ford Health Care Corporation.

In 1988, he was the first person to receive the Juan M. Taveras Professorship of Radiology at the Harvard Medical School and became Radiologist-in-Chief at Massachusetts General Hospital (MGH), positions he has held since then. He also currently serves as a Trustee of the Massachusetts General Physicians Organization and chairs the Executive Committee of the Harvard Departments of Radiology.

Prof. Thrall has worked extensively on the development of telemedicine systems and chairs the International Medicine Committee of the MGH. He has co-founded two companies in partnership with MGH to provide teleradiology and telemedicine services.

He is the Chairman of the Board of Directors at Mobile Aspects, a leading provider of radio fre-

quency identification (RFID) tracking solutions for the healthcare industry, and the Chairman on the Board of Directors of Worldcare, Ltd. He notably co-founded WorldCare Clinical (WCC), an imaging CRO that provides end-to-end imaging services for clinical trials in the pharmaceutical, biotechnology, and medical device industries, in 1992.

Nationally, Prof. Thrall serves on the Board of Trustees of the Research and Education Foundation of the Radiological Society of North America (RSNA), and the Board of Councilors of the Society of Chiefs of Academic Radiology Departments. He is a past President of the American Roentgen Ray Society and currently holds the position of Vice-Chairman of the Board of Chancellors of the American College of Radiology.

The quality of his work has granted him prestigious awards such as fellowship of the American College of Radiology, the Excellence of Leadership award of the magazine *Diagnostic Imaging* and the Gold Medal of both the RSNA and the American Roentgen Ray Society.

Prof. Thrall is an author of over 260 publications and reviews and is the founder and editor of the *Requisites in Radiology* textbook series. He is or has been part of the editorial board of the *Journal of Nuclear Medicine*, *International Journal of Cardiac Imaging*, *Investigative Radiology* and *Journal of the American College of Radiology*.

**In recognition of his outstanding career and his contribution to radiology, Professor James H. Thrall will be invited as Honorary Lecturer. He will present the Josef Lissner – Honorary Lecture entitled: 'The coming of age of imaging in biomedical research'.**

# *Inaugural Lecture and Concert*

**Friday, March 7, 17:45**

**Austria Center Vienna, Room A**

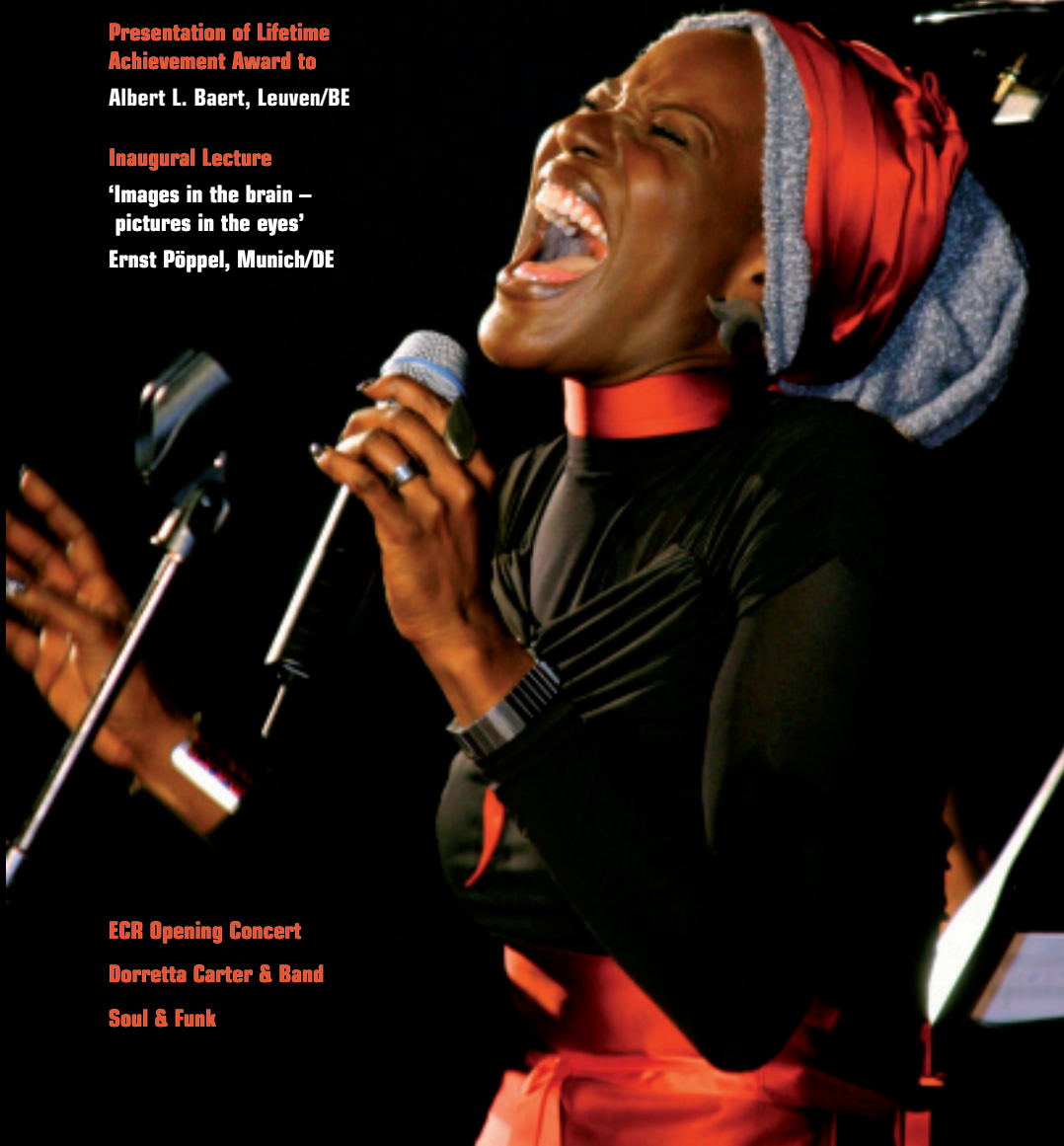**Presentation of Lifetime  
Achievement Award to**

**Albert L. Baert, Leuven/BE**

**Inaugural Lecture**

**'Images in the brain –  
pictures in the eyes'**

**Ernst Pöppel, Munich/DE**



**ECR Opening Concert**

**Dorretta Carter & Band**

**Soul & Funk**

## Committees & Dignitaries

- 6 Committees
- 8 Subcommittees
- 10 Topic Coordinators
- 11 ESR Dignitaries

## Programme Overviews & Floor Plans

- 24 Programme Overviews**
- 34 Floor Plans**
- 42 Meeting Rooms**
- 45 Metro Map**

## ECR Information from A–Z

- 48 ECR Information from A-Z
- 57 EIBIR – European Institute for Biomedical Imaging Research
- 58 CME at ECR 2008
- 60 ESR meets Germany, Israel, India and GPs
- 62 ESR e-Learning for Free
- 64 ESR Electronic Congress
- 65 IMAGINE at ECR 2008
- 66 Plenary Sessions
- 68 Image Interpretation Quizzes
- 69 Hospital Management Symposium
- 70 EPOS™ – Scientific Exhibition
- 72 ESR Job Forum
- 73 Welcome to our Industry Partners
- 74 Food & Drink at ECR 2008
- 75 Free Publications
- 77 European Radiology
- 78 ESOR – European School of Radiology
- 85 Special Exhibition
- 86 Arts & Culture

## Programme by Topics

- 90 New Horizons Sessions
- 90 State-of-the-Art Symposia
- 91 Special Focus Sessions
- 96 Professional Challenges Sessions
- 97 Categorical Courses
- 100 Mini Courses
- 101 Refresher Courses / Scientific Sessions
- 120 E<sup>3</sup> – European Excellence in Education
- 123 Radiology Trainees Forum
- 124 Hands-on Workshops
- 128 1<sup>st</sup> Workstation Face-Off Session
- 129 Satellite Symposia
- 134 Industry Hands-on Workshops

## Educational & Scientific Programme

- 139 Contents
- 141 Postgraduate Educational Programme
- 268 Scientific Sessions
- 361 Scientific and Educational Exhibits
- 450 List of Authors and Co-authors
- 499 List of Moderators
- 502 Personal Planner

Friday, March 7

	room A 2nd level	room B 2nd level	room C 2nd level	room E1 entr. level	room E2 entr. level	room F1 entr. level	room F2 entr. level	room G/H lower level	room I lower level
07:00									
07:30									
08:00									
08:30									
09:00	<b>CC 116</b> MRI MR techniques: From basic to advanced (p. 141)	<b>CC 117</b> Multidetector CT Made Easy MDCT imple- mentation: Making the best of the technol- ogy race (p. 141)	<b>NH 1</b> New Horizons Session MR diffusion and perfusion: Can they replace PET? (p. 142)	<b>RC 110</b> Musculo- skeletal Foot and ankle (p. 143)	<b>E<sup>3</sup> 120a</b> Foundation Course: Interventional Radiology Arteries (p. 144)	<b>E<sup>3</sup> 120b</b> Interactive Teaching Session The imaging management of breast cancer (p. 144)	<b>SF 1</b> Special Focus Session Uterine fibroid embolisation – the case for and against: Gynecologist, radiologist, patient (p. 145)	<b>RC 111</b> Neuro Stroke (p. 146)	<b>RC 115</b> Vascular Non-invasive vascular imaging (p. 146)
09:30									
10:00									
10:30									
11:00		<b>SS 210</b> Musculo- skeletal Peripheral nerves and muscle disorders (p. 268)	<b>SS 201b</b> GI Tract Advances in abdominal imaging (p. 269)	<b>SS 206b</b> Molecular Imaging Preclinical studies (p. 270)	<b>E<sup>3</sup> 220</b> Foundation Course: Interventional Radiology Veins (p. 151)	<b>SS 207</b> Genitourinary The uterus (p. 271)	<b>SS 202</b> Breast Advances in digital mammography (p. 272)	<b>SS 208</b> Head and Neck Lesion detection and characteri- sation (p. 273)	<b>SS 215</b> Vascular Carotid imaging (p. 274)
11:30									
12:00									
12:30									
13:00									
13:30									
14:00									
14:30									
15:00		<b>SS 310</b> Musculo- skeletal Spine and shoulder (p. 281)	<b>SS 301a</b> Abdominal Viscera Challenges in hepatobiliary diseases (p. 283)	<b>SY 1</b> Bayer Schering Pharma Satellite Symposium (p. 129)	<b>E<sup>3</sup> 320</b> Foundation Course: Interventional Radiology Gastro- intestinal tract (p. 152)	<b>SS 307</b> Genitourinary Imaging of the pelvis (p. 284)	<b>SS 302</b> Breast Innovations in breast diagnosis (p. 285)	<b>SS 308</b> Head and Neck Tumors: Metastases and imaging in therapy (p. 286)	<b>SS 315</b> Vascular CT angiography (p. 287)
15:30									
16:00									
16:30		<b>CC 417</b> Multidetector CT Made Easy The heart: A newly found land (p. 152)	<b>SA 4</b> State-of- Art Symposium The radiologist as the therapist in liver tumors (p. 153)	<b>CC 418</b> Breast: From Basics to Advanced Imaging From pathol- ogy to breast imaging: Radio- logic-pathologic correlations (p. 154)	<b>E<sup>3</sup> 420a</b> Foundation Course: Interventional Radiology Genitourinary (p. 155)	<b>E<sup>3</sup> 420b</b> Interactive Teaching Course: Useful Signs in imaging Signs in neuro- radiology and in head and neck imaging (p. 155)	<b>RC 402</b> Breast Digital mammography (p. 156)	<b>SF 4</b> Special Focus Session Dual source CT/Dual energy CT: Doubly informative? (p. 157)	<b>RC 415</b> Vascular Imaging in carotid disease (p. 158)
17:00									
17:30									
18:00									
18:30									
19:00									

 Opening Ceremony/  
Presentation of  
Gold Medal  
Award and  
Honorary  
Members

Technical Exhibition

EPOS™ - Scientific Exhibition

Registration

 Lifetime  
Achievement  
Award  
  
Inaugural  
Lecture  
(p. 163)  
  
ECR Opening  
Concert



room K lower level	room L/M 1st level	room N/O 1st level	room R1 1st level	room R2 1st level	room R3 1st level	room U 2nd level	room X 2nd level	room XI, Z & Y 2nd level	room Z 2nd level		
										07:00	
										07:30	
										08:00	
<b>RC 105 Computer Applications</b> What can PACS do today? (p. 147)	<b>MC 125 Women's Imaging: Female Pelvis</b> Assessment of anatomy and imaging in benign lesions (p. 148)	<b>MC 119 Molecular Imaging</b> Molecular imaging (p. 148)	<b>RC 104 Chest</b> Volumetric HRCT of diffuse lung diseases (p. 149)	<b>RC 101 Abdominal and Gastro- intestinal</b> Imaging of malignant liver lesions (p. 150)	<b>RC 108 Head and Neck</b> Imaging of the orbit (p. 150)					08:30	
										09:00	
										09:30	
										10:00	
<b>SS 205 Computer Applications</b> CAD and auto- mated image analysis (p. 275)	<b>SS 211 Neuro</b> CT angio- graphy and perfusion (p. 276)	<b>SS 206a Contrast Media</b> Side effects (p. 277)	<b>SS 204 Chest</b> Advances in tumor imaging (p. 278)	<b>SS 203 Cardiac</b> Advances in cardiac CT (p. 279)	<b>SS 209 Interventional Radiology</b> Vascular interventions (1) (p. 280)		<b>WS 222 Experience Vascular Procedures Using Simulators</b> (p. 125)		<b>WS 224 Test-Driving your Workstation</b> (p. 127)	10:30	
											11:00
											11:30
										12:00	
										12:30	
										13:00	
										13:30	
<b>SS 305 Computer Applications</b> Image viewing and PACS (p. 288)	<b>SS 311a Neuro</b> Advanced spinal MRI (p. 289)	<b>SS 311b Neuro</b> Brain tumors (p. 290)	<b>SS 304 Chest</b> Screening/ Pulmonary nodule (p. 291)	<b>SS 303 Cardiac</b> Advances in cardiac MR (p. 292)	<b>SS 309 Interventional Radiology</b> Thoracic interventions (p. 293)		<b>WS 322 Experience Vascular Procedures Using Simulators</b> (p. 125)		<b>WS 24A1 Test-Driving your Workstation</b> (p. 127)	14:00	
											14:30
											15:00
										15:30	
<b>RC 405 Computer Applications</b> PACS in evolution (p. 158)	<b>MC 425 Women's Imaging: Female Pelvis</b> Malignant tumors (p. 159)	<b>RC 408 Head and Neck</b> Head and neck imaging: A practical approach (p. 160)	<b>RC 404 Chest</b> A practical approach for interpreting the chest radiograph (p. 161)	<b>RC 401 Abdominal and Gastro- intestinal</b> Diseases of the mesentery and peritoneum (p. 161)	<b>RC 409 Interventional Radiology</b> Endovascular treatment of aortic/iliac occlu- sive disease: How far can interventional radiology go? (p. 162)					16:00	
										16:30	
										17:00	
										17:30	
										18:00	
										18:30	
										19:00	

Saturday, March 8


	room A 2nd level	room B 2nd level	room C 2nd level	room E1 entr. level	room E2 entr. level	room F1 entr. level	room F2 entr. level	room G/H lower level	room I lower level	
07:00										
07:30										
08:00										
08:30										
09:00	CC 516 MRI Neuro: The brain as the centre of the world (p. 164)	CC 517 Multidetector CT Made Easy The guts: Growing opportunities (p. 164)	NH 5 New Horizons Session The further minimisation of minimally invasive therapy (p. 165)	CC 518 Breast: From Basics to Advanced Imaging Breast lesions at mammography: How to characterise? (p. 166)	E <sup>3</sup> 520a Foundation Course: Interventional Radiology Liver tumors (p. 167)	E <sup>3</sup> 520b Interactive Teaching Session Prostate cancer: Meeting clinical needs by MRI at diagnosis and on follow-up (p. 167)	SF 5a Special Focus Session Nephrogenic systemic fibrosis: Current situation and future direction (p. 168)	EF 1 EFOMP Workshop State-of-the-art of high field MRI instrumentation (p. 169)	WS 521 Image Guided Breast Biopsy: How to do it Hands-on Workshop Lecture (p. 124)	
09:30										
10:00										
10:30										
11:00	EM 1 ESR meets Germany Computer aided diagnosis (CAD) (p. 174)	SS 610 Musculo-skeletal Hand, knee, feet (p. 295)	SS 601a Abdominal Viscera Functional imaging of the abdomen: Are we there yet? (p. 296)		E <sup>3</sup> 620 Foundation Course: Interventional Radiology Musculo-skeletal (p. 175)		SS 609a Interventional Radiology Spine (p. 297)	SS 602 Breast Intervention (p. 298)	EF 2 EFOMP Workshop Clinical applications, safety issues and regulations for very high field MRI (p. 176)	SS 613 Physics in Radiology Radiation dose in CT (p. 299)
11:30										
12:00										
12:30		Honorary Lecture 1 (p. 177)								
13:00			SY 3 GE Healthcare Satellite Symposium (p. 129)	Workstation Face-Off Session (p. 128)				SY 4 Bracco Satellite Symposium (p. 129)		
13:30										
14:00										
14:30	SS 710 Musculo-skeletal Arthritis (p. 304)	SS 701a Abdominal Viscera Magic bullets for hepatic lesions (p. 306)	SS 701b GI Tract Colon and rectum (p. 307)	SY 6 Bayer Schering Pharma Satellite Symposium (p. 130)	E <sup>3</sup> 720 Interactive Teaching Course: Useful Signs in Imaging Signs in abdominal imaging (p. 177)	SS 709a Interventional Radiology Radio-frequency ablation (p. 308)	SY 7 Siemens Satellite Symposium (p. 130)	SS 708 Head and Neck New approaches to examination techniques (p. 309)	SS 713 Physics in Radiology New approaches in MRI (p. 310)	
15:00										
15:30										
16:00										
16:30	CC 816 MRI Musculo-skeletal: A step-by-step approach (p. 178)	CC 817 Multidetector CT Made Easy The chest: A high resolution country (p. 178)	EM 2 ESR meets General Practitioners Manifestations of atherosclerosis: A common challenge in diagnosis and treatment (p. 179)	RC 810 Musculo-skeletal Osteoporosis (p. 180)	E <sup>3</sup> 820 Interactive Teaching Course: Useful Signs in Imaging Signs in genitourinary imaging (p. 181)	RC 807 Genitourinary What to do with all these small renal masses? (p. 181)	RC 802 Breast MRI of the breast (p. 182)	RC 811 Neuro Basic MR (p. 183)	RC 815 Vascular Non-invasive imaging of the lower limb venous system (p. 183)	
17:00										
17:30										
18:00										
18:30										
19:00										

Technical Exhibition

EPOS™ - Scientific Exhibition

Registration






room K lower level	room L/M 1st level	room N/O 1st level	room R1 1st level	room R2 1st level	room R3 1st level	room U 2nd level	room X 2nd level	room XI, Z & Y 2nd level	room Z 2nd level				
										07:00			
										07:30			
										08:00			
HS 1 Hospital Management Symposium Management (p. 69)	SF 5b Special Focus Session Comprehensive evaluation of the heart (p. 170)	MC 519 Molecular Imaging Molecular imaging in cardiovascular diseases (p. 171)	RC 504 Chest Pulmonary embolism update (p. 172)	RC 501 Abdominal and Gastro- intestinal Imaging in pancreatitis (p. 173)	RC 507 Genitourinary Imaging of the pelvic floor (p. 173)					08:30			
										09:00			
										09:30			
										10:00			
HS 2 Hospital Management Symposium Information Technology (p. 69)	SS 611 Neuro New vascular MR techniques (p. 300)	SS 604 Chest Reporting and CAD (CXR and CT) (p. 301)	SY 2 Bracco Satellite Symposium (p. 129)	SS 603 Cardiac Imaging of the right heart (p. 302)	SS 609b Interventional Radiology Liver: Embolisation (p. 303)	WS 621 Image Guided Breast Biopsy: How to do it (p. 124)	WS 622 Experience Vascular Procedures Using Simulators (p. 125)	WS 623 Tips and Tricks in Radio- frequency Ablation (p. 126)		10:30			
													11:00
													11:30
HS 3 Hospital Management Symposium Finance (p. 69)										12:00			
				SY 5 Siemens and Bayer Schering Pharma Joint Satellite Symposium (p. 130)						12:30			
										13:00			
										13:30			
SS 712 Pediatric Fetal imaging (p. 311)	SS 715 Vascular MR angiography (p. 312)	SS 711 Neuro Grey and white matter (p. 313)	SS 704 Chest Pulmonary embolism (p. 314)	SS 703 Cardiac CT/MR in cardiovascular risk assessment (p. 315)	SS 709b Interventional Radiology Musculo- skeletal intervention (p. 317)	WS 721 Image Guided Breast Biopsy: How to do it (p. 124)	WS 722 Experience Vascular Procedures Using Simulators (p. 125)	WS 723 Tips and Tricks in Radio- frequency Ablation (p. 126)	WS 24B1 Test-Driving your Workstation (p. 127)	14:00			
													14:30
									WS 24B2 Test-Driving your Workstation (p. 127)	15:00			
										15:30			
TF 1 RTF Radiology Trainees Forum Highlighted Lectures (p. 184)	SF 8a Special Focus Session Fat radiology: Imaging in obesity and metabolic syndrome (p. 185)	RC 808 Head and Neck Imaging after treatment of head and neck tumors (p. 186)	RC 803 Cardiac How to perform a complete CT/MR examination of the heart (p. 186)	RC 801 Abdominal and Gastro- intestinal Imaging of the acute abdomen (p. 187)	RC 809 Interventional Radiology Percutaneous interventions in musculo- skeletal disease (p. 188)				SF 8b Special Focus Session Novel image analysis and modelling techniques to improve diagno- sis and therapy of cancer (p. 188)	16:00			
										16:30			
										17:00			
										17:30			
										18:00			
										18:30			
										19:00			

Sunday, March 9

		room A 2nd level	room B 2nd level	room C 2nd level	room E1 entr. level	room E2 entr. level	room F1 entr. level	room F2 entr. level	room G/H lower level	room I lower level	
07:00	Registration EPOS™ - Scientific Exhibition Technical Exhibition										
07:30											
08:00											
08:30											
09:00			<b>CC 916</b> <b>MRI</b> Neuro: Conquering important territories (p. 190)	<b>CC 917</b> <b>Multidetector CT Made Easy</b> Bones and joints: CT is still alive! (p. 191)	<b>NH 9</b> <b>New Horizons Session</b> Above 3 T: Clinical tool or toys for the boys? (p. 192)	<b>RC 910</b> <b>Musculo-skeletal</b> Hip (p. 193)	<b>E<sup>3</sup> 920a</b> <b>Interactive Teaching Session</b> Classifying breast lesions: The BI-RADS™ exercise (p. 194)	<b>E<sup>3</sup> 920b</b> <b>Interactive Teaching Session</b> Inflammatory small bowel diseases (p. 194)	<b>SF 9a</b> <b>Special Focus Session</b> Cardiothoracic CT: One test solves all (p. 195)	<b>SF 9b</b> <b>Special Focus Session</b> Hybrid imaging: PET/CT, SPECT/CT, PET/MRI .... where next? (p. 196)	<b>RC 913</b> <b>Physics in Radiology</b> MR-guided cardiovascular interventions (p. 197)
09:30											
10:00											
10:30											
11:00			<b>EM 3</b> <b>ESR meets Israel</b> Views and impressions from radiology in Israel (p. 203)	<b>SS 1010</b> <b>Musculo-skeletal</b> Osteoporosis and hip disorders (p. 318)	<b>SS 1001b</b> <b>GI Tract</b> CT colonography (p. 319)	<b>SY 8</b> <b>GE</b> <b>Healthcare Satellite Symposium</b> (p. 130)	<b>E<sup>3</sup> 1020</b> <b>Interactive Teaching Course:</b> Useful Signs in Imaging Signs in chest imaging (p. 204)	<b>SS 1007</b> <b>Genitourinary</b> Imaging of the urinary tract: Do new techniques give new answers? (p. 320)	<b>SS 1002</b> <b>Breast</b> MR: New clinical findings (p. 321)	<b>SS 1005</b> <b>Computer Applications</b> Radiological reporting and teaching (p. 322)	<b>SS 1013</b> <b>Physics in Radiology</b> Dose, risk assessment and optimisation (p. 323)
11:30											
12:00											
12:30			<b>Honorary Lecture 2</b> (p. 204)								
13:00				<b>SY 10</b> <b>GE</b> <b>Healthcare Satellite Symposium</b> (p. 131)	<b>SY 11</b> <b>Hitachi</b> <b>Satellite Symposium</b> (p. 131)			<b>SY 12</b> <b>Bracco</b> <b>Satellite Symposium</b> (p. 131)			
13:30											
14:00											
14:30		<b>IIQ</b> <b>Image Interpretation Quiz</b>		<b>SY 14</b> <b>GE</b> <b>Healthcare Satellite Symposium</b> (p. 132)	<b>SY 15</b> <b>Guerbet</b> <b>Satellite Symposium</b> (p. 132)			<b>SY 16</b> <b>Hologic</b> <b>Satellite Symposium</b> (p. 132)			
15:00											
15:30											
16:00		<b>CC 1216</b> <b>MRI</b> Vascular: From head to toe (p. 205)	<b>CC 1217</b> <b>Multidetector CT Made Easy</b> The abdomen: The realm of MDCT (p. 206)	<b>SA 12</b> <b>State-of-the-Art Symposium</b> Coronary CTA comes of age: Technical advances, decision modeling and cost effectiveness (p. 207)	<b>RC 1210</b> <b>Musculo-skeletal</b> Spine (p. 208)	<b>E<sup>3</sup> 1220</b> <b>Interactive Teaching Course:</b> Useful Signs in Imaging Signs in musculo-skeletal imaging (p. 208)	<b>RC 1207</b> <b>Genitourinary</b> Imaging of the adnexal masses (p. 209)	<b>SF 12</b> <b>Special Focus Session</b> Whole body MR imaging: Valuable screening or life style choice for the worried rich? (p. 210)	<b>RC 1211</b> <b>Neuro</b> Imaging of vascular brain disease (p. 211)	<b>RC 1213</b> <b>Physics in Radiology</b> Physics and technology of multi-modality imaging systems (p. 212)	
16:30											
17:00											
17:30											
18:00											
18:30											
19:00											



room K lower level	room L/M 1st level	room N/O 1st level	room R1 1st level	room R2 1st level	room R3 1st level	room U 2nd level	room X 2nd level	room XI, Z & Y 2nd level	room Z 2nd level	
										07:00
										07:30
										08:00
										08:30
										09:00
										09:30
										10:00
										10:30
										11:00
										11:30
										12:00
										12:30
										13:00
										13:30
										14:00
										14:30
										15:00
										15:30
										16:00
										16:30
										17:00
										17:30
										18:00
										18:30
										19:00

SF 9c Special Focus Session Imaging your youngest patients: Fetal MRI (p. 198)	RC 914 Radio- graphers MRI (p. 199)	MC 919 Molecular Imaging Cancer and inflammation (p. 200)	RC 903 Cardiac The atherosclerotic plaque (p. 200)	RC 901 Abdominal and Gastro- intestinal Small nodules in the cirrhotic liver: What to do? (p. 201)	RC 907 Genitourinary Imaging of the male genitalia (p. 202)	WS 921 Image Guided Breast Biopsy: How to do it (p. 124)				
SS 1012 Pediatric Chest and abdomen (p. 324)	SS 1014 Radio- graphers Development of the professional role (p. 325)	SS 1011 Neuro Functional MRI (p. 326)	SY 9 Carestream Health Satellite Symposium (p. 131)	SS 1003 Cardiac Myocardial and pericardial diseases (p. 327)	SS 1009 Interventional Radiology Abdomen and pelvis (p. 328)	WS 1021 Image Guided Breast Biopsy: How to do it (p. 124)	WS 1022 Experience Vascular Procedures Using Simulators (p. 125)	WS 1023 Tips and Tricks in Radio- frequency Ablation (p. 126)	WS 1024 Test-Driving your Workstation (p. 128)	
				SY 13 Philips Healthcare Satellite Symposium (p. 132)						
			SY 17 Toshiba Satellite Symposium (p. 133)	SY 18 Philips Healthcare Satellite Symposium (p. 133)		WS 1121 Image Guided Breast Biopsy: How to do it (p. 124)	WS 1122 Experience Vascular Procedures Using Simulators (p. 125)	WS 1123 Tips and Tricks in Radio- frequency Ablation (p. 126)	WS 24C1 Test-Driving your Workstation (p. 127)	
									WS 24C2 Test-Driving your Workstation (p. 127)	
RC 1212 Pediatric Gastro- intestinal tract (p. 212)	RC 1214 Radio- graphers Professional profile developments: The extended role of the radiographer (p. 213)	RC 1206 Molecular Imaging and Contrast Media Angiogenesis imaging in clinical practice today (p. 214)	RC 1204 Chest Bronchogenic carcinoma: Screening and staging (p. 215)	CC 1218 Breast: From Basics to Advanced Imaging Characterisa- tion of breast lesions by US and MRI (p. 215)	PC 12 Professional Challenges Session Teleradiology: Film reading at the sea side? (p. 216)					

Monday, March 10

	room A 2nd level	room B 2nd level	room C 2nd level	room E1 entr. level	room E2 entr. level	room F1 entr. level	room F2 entr. level	room G/H lower level	room I lower level
07:00									
07:30									
08:00									
08:30									
09:00	<b>CC 1316 MRI</b> Abdomen: Is MRI the ultimate tool? (p. 218)	<b>CC 1317 Multidetector CT Made Easy</b> CT of the brain, head and neck: Is there anything new? (p. 219)	<b>SF 13 Special Focus Session</b> The radiologist in image-guided surgery: Just a tour guide? (p. 220)	<b>RC 1310 Musculo-skeletal</b> Shoulder (p. 221)	<b>E<sup>3</sup> 1320 Interactive Teaching Session</b> The imaging management of lung cancer (p. 222)	<b>RC 1308 Head and Neck</b> Imaging of the thyroid and parathyroid (p. 222)	<b>RC 1302 Breast</b> Changing approaches to breast diseases? (p. 223)	<b>RC 1311 Neuro</b> Pediatric neuroradiology (p. 223)	<b>RC 1313 Physics in Radiology</b> Quality control and dose reduction in digital radiology (p. 224)
09:30									
10:00									
10:30									
11:00	<b>SS 1410 Musculo-skeletal</b> Cartilage (p. 329)	<b>SS 1401a Abdominal Viscera</b> Checking out the pancreatobiliary system (p. 330)	<b>SS 1401b GI Tract</b> Esophageal and gastric cancer: New approaches (p. 332)	<b>ESR General Assembly</b>	<b>E<sup>1</sup> 1420 Interactive Teaching Session</b> The imaging management of stroke (p. 229)	<b>SS 1407 Genitourinary</b> Imaging of renal lesions: Perfusion diffusion and more (p. 333)	<b>SS 1402 Breast</b> MR: Know-how for new approaches (p. 334)	<b>SS 1406b Molecular Imaging</b> Clinical applications (p. 335)	<b>SS 1413 Physics in Radiology</b> New advances in imaging techniques and applications (p. 336)
11:30									
12:00									
12:30		<b>Honorary Lecture 3</b> (p. 230)							
13:00									
13:30									
14:00									
14:30	<b>EM 4 ESR meets India</b> Tuberculosis (p. 230)	<b>CC 1517 Multidetector CT Made Easy</b> MDCT angiography: Do we need anything else? (p. 231)	<b>SA 15 State-of-the-Art Symposium</b> Small bowel: Old problems, new tricks (p. 232)	<b>SF 15a Special Focus Session</b> Frontiers in liver imaging (p. 233)	<b>E<sup>1</sup> 1520 Interactive Teaching Session</b> The imaging management of back pain (p. 234)	<b>RC 1507 Genitourinary</b> Percutaneous stone extraction: Success by team work (p. 235)	<b>RC 1502 Breast</b> Ultrasound and breast disease (p. 235)	<b>RC 1511 Neuro</b> Brain tumors (p. 236)	<b>RC 1513 Physics in Radiology</b> Managing patient dose (p. 237)
15:00									
15:30									
16:00									
16:30	<b>CC 1616 MRI</b> Cardiac MRI: An affair of the heart (p. 242)	<b>PC 16 Professional Challenges Session</b> Women in radiology: How to maximise their input (p. 243)	<b>SF 16a Special Focus Session</b> Emergency imaging: Avoiding serious mistakes! (p. 244)	<b>RC 1610 Musculo-skeletal</b> New trends in musculo-skeletal radiology (p. 245)	<b>E<sup>3</sup> 1620 Interactive Teaching Session</b> Traps in imaging of cirrhosis and portal hypertension (p. 246)	<b>SF 16b Special Focus Session</b> Molecular imaging (p. 246)	<b>RC 1602 Breast</b> Diagnosis and staging of breast cancer (p. 247)	<b>RC 1611 Neuro</b> Grey and white matter disease (p.248)	<b>RC 1613 Physics in Radiology</b> Monitor reporting: Quality and diagnostic accuracy (p. 249)
17:00									
17:30									
18:00									
18:30									
19:00									

 Registration  
 EPOS™ - Scientific Exhibition  
 Technical Exhibition



room K lower level	room L/M 1st level	room N/O 1st level	room R1 1st level	room R2 1st level	room R3 1st level	room U 2nd level	room XI, Z & Y 2nd level	room Y 2nd level	room Z 2nd level	
										07:00
										07:30
										08:00
										08:30
RC 1312 Pediatric Chest imaging (p. 225)	RC 1314 Radio- graphers Trauma (p. 226)	PC 13 Professional Challenges Session Capturing the market: How quality helps (p. 226)	RC 1303 Cardiac Imaging of myocardial infarction (p. 227)	RC 1301 Abdominal and Gastro- intestinal CT colono- graphy: How to use it (p. 228)	RC 1309 Interventional Radiology Interventions in non-malignant liver diseases (p. 229)					09:00
										09:30
										10:00
										10:30
SS 1415 Vascular MR: Angiography, microcircu- lation and lymphography (p. 337)	SS 1414 Radio- graphers Dose reduction strategies (p. 338)	SS 1411 Neuro MRI at 7 T (p. 339)	SS 1404 Chest Advances in CT (p. 340)	SS 1403 Cardiac MR/CT in treatment evaluations (p. 341)	SS 1409 Interventional Radiology Tumor ablation/Liver regeneration (p. 342)	WS 1421 Image Guided Breast Biopsy: How to do it (p. 124)			WS 1424 Test-Driving your Workstation (p. 127)	11:00
										11:30
										12:00
										12:30
					SY 20 Guerbet Satellite Symposium (p. 133)					13:00
										13:30
										14:00
RC 1512 Pediatric Neuro imaging (p. 237)	RC 1514 Radio- graphers Computed tomography: CT and contrast media (p. 238)	SF 15b Special Focus Session Advances in tumor ablation (p. 239)	RC 1504 Chest Diagnostic mimics in chest diseases (p. 240)	CC 1518 Breast: From Basics to Advanced Imaging Interventional procedures (p. 241)	RC 1509 Interventional Radiology Treatment of acute hemorrhage (p. 241)	WS 1521 Image Guided Breast Biopsy: How to do it (p. 124)			WS 24D1 Test-Driving your Workstation (p. 127)	14:30
										15:00
									WS 24D2 Test-Driving your Workstation (p. 127)	15:30
										16:00
RC 1612 Pediatric Safety considerations in imaging (p. 249)	RC 1614 Radio- graphers Non medical applications (p. 250)	RC 1606 Molecular Imaging and Contrast Media US contrast agents (p. 251)	RC 1604 Chest Computer- aided diagnosis in the chest (p. 251)	CC 1618 Breast: From Basics to Advanced Imaging Advanced imaging: Full-field digital mammography (FFDM)/MRI (p. 252)	RC 1609 Interventional Radiology Carotid interventions (p. 253)	WS 1621 Image Guided Breast Biopsy: How to do it (p. 124)				16:30
										17:00
										17:30
										18:00
										18:30
										19:00

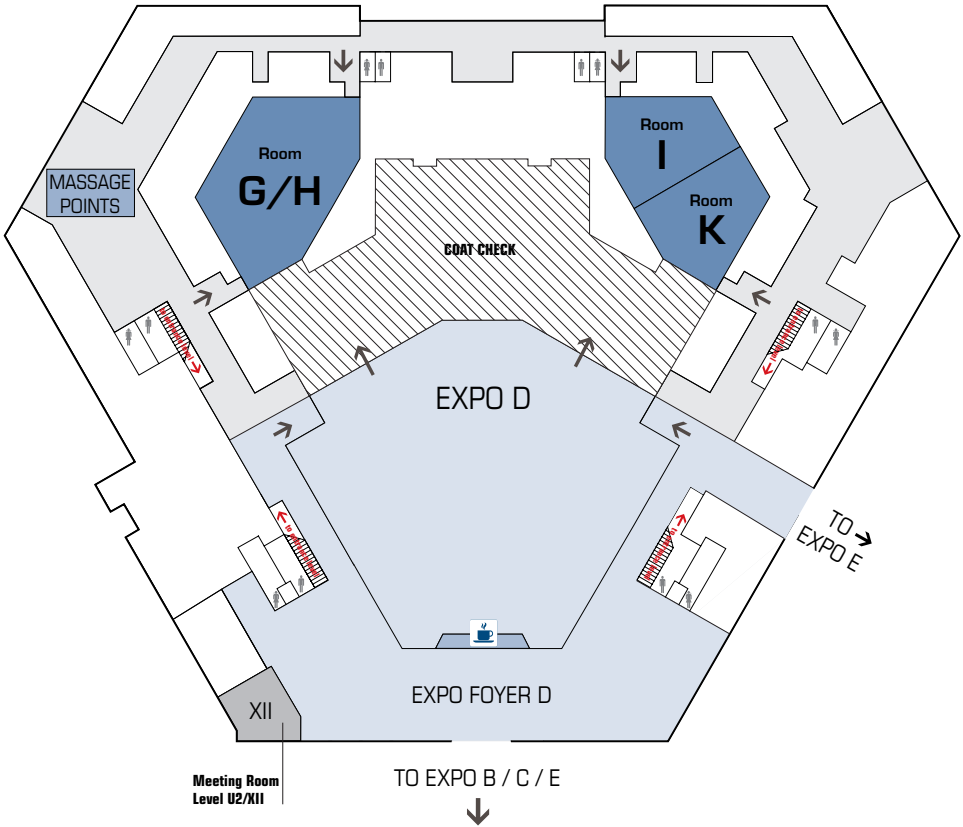
Tuesday, March 11

	room A 2nd level	room B 2nd level	room C 2nd level	room E1 entr. level	room E2 entr. level	room F1 entr. level	room F1 entr. level	room G/H lower level	room I lower level
07:00									
07:30									
08:00									
08:30									
09:00	<b>CC 1716 MRI</b> The future is now! (p. 254)	<b>SF 17a Special Focus Session</b> CT and MR urography: is intravenous urography dead? (p. 255)	<b>RC 1701 Abdominal and Gastro-intestinal</b> Liver vasculature: Radiologic anatomy and disorders (p. 256)	<b>RC 1710 Musculo-skeletal</b> Extra-spinal interventional procedures (p. 256)	<b>E<sup>3</sup> 1720 Interactive Teaching Session</b> Detection and diagnosis of interstitial lung diseases (p. 257)	<b>RC 1708 Head and Neck</b> What you always wanted to hear about hearing loss (p. 258)	<b>SF 17b Special Focus Session</b> New radiation risk estimation: Can we relax? (p. 259)	<b>RC 1711 Neuro</b> Interventional neuroradiology (p. 260)	<b>RC 1715 Vascular</b> Imaging of critical limb ischemia (p. 261)
09:30									
10:00									
10:30									
11:00	<b>SS 1810 Musculo-skeletal</b> Tumors and marrow disease (p. 344)	<b>SS 1801a Abdominal Viscera</b> HCC, still tantalising and bewildering (p. 345)	<b>SS 1801b GI Tract</b> Small bowel and appendix (p. 346)	<b>SS 1803a Cardiac</b> Coronary artery imaging (p. 347)	<b>E<sup>3</sup> 1820 BI-RADS™</b> Olympics (p. 267)	<b>SS 1807 Genitourinary</b> Prostate imaging: Diagnosis, therapy and follow-up (p. 348)	<b>SS 1802 Breast</b> MR: Role in patient management (p. 349)	<b>SS 1808 Head and Neck</b> Skull base and temporal bone (p. 350)	<b>SS 1815 Vascular</b> Therapy, evaluation and outcome (p. 351)
11:30									
12:00									
12:30	EPOS™ - Scientific Exhibition Registration	<b>JIIQ Junior Image Interpretation Quiz</b>							
13:00			<b>Closing Ceremony</b>						
13:30									
14:00									
14:30									
15:00									
15:30									
16:00									
16:30									
17:00									
17:30									
18:00									
18:30									
19:00									

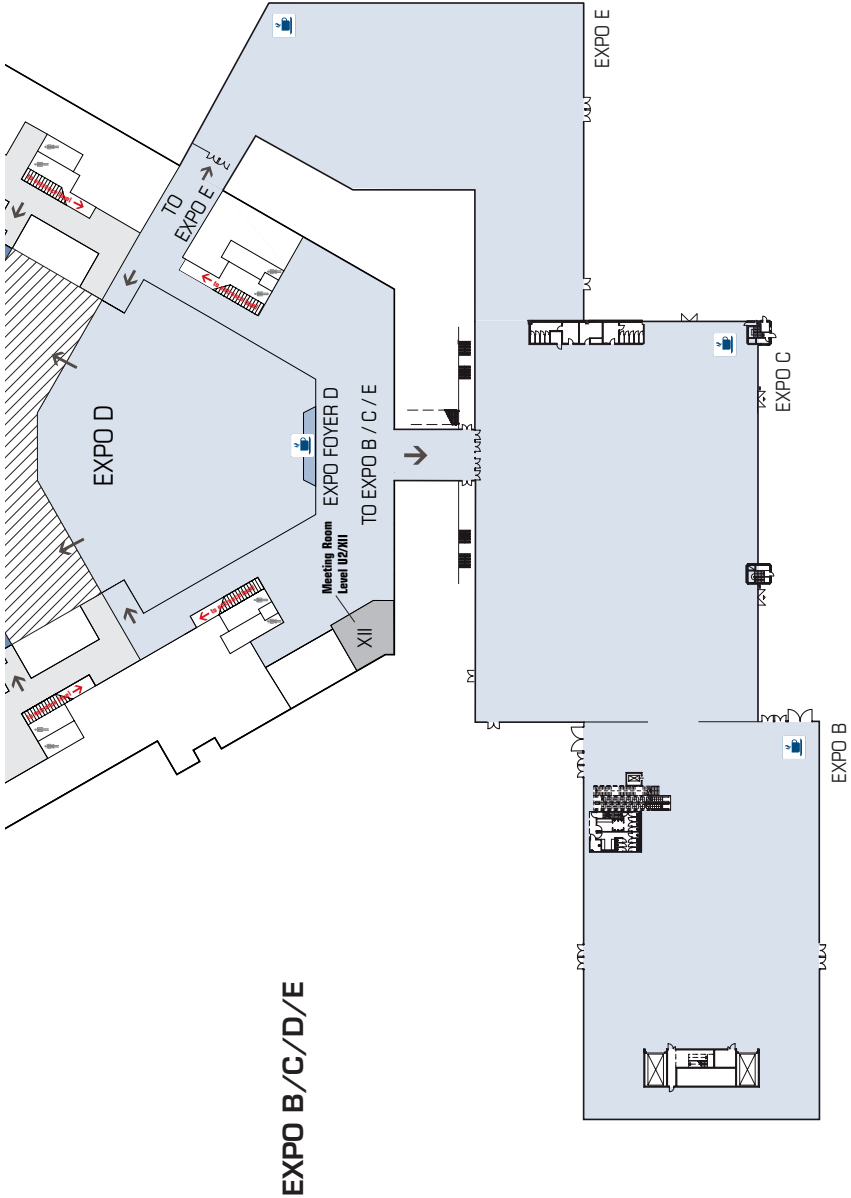



room K lower level	room L/M 1st level	room N/O 1st level	room R1 1st level	room R2 1st level	room R3 1st level	room U 2nd level	room X 2nd level	room XI, Z & Y 2nd level	room Z 2nd level	
										07:00
										07:30
										08:00
<b>RC 1712 Pediatric Trauma</b> (p. 261)	<b>SF 17c Special Focus Session</b> The upcoming 'geriatric tsunami' and its consequences to imaging services (p. 262)	<b>SF 17d Special Focus Session</b> Undergraduate radiological education (p. 263)	<b>RC 1703 Cardiac CT vs MRI</b> (p. 264)	<b>CC 1718 Breast: From Basics to Advanced Imaging</b> Advanced imaging (p. 265)	<b>RC 1709 Interventional Radiology</b> Update on endovascular aortic interventions (p. 266)					08:30
										09:00
										09:30
										10:00
<b>SS 1812 Pediatric Advances in CT and MRI</b> (p. 352)	<b>SS 1806a Contrast Media</b> From research to practice (p. 354)	<b>SS 1811 Neuro</b> Epilepsy and development issues (p. 355)	<b>SS 1804 Chest</b> Technical advances/ Pulmonary hypertension and perfusion (p. 356)	<b>SS 1803b Cardiac</b> Valvular and cardiac function studies (p. 357)	<b>SS 1809 Interventional Radiology</b> Vascular interventions (2) (p. 358)					10:30
										11:00
										11:30
										12:00
										12:30
										13:00
										13:30
										14:00
										14:30
										15:00
										15:30
										16:00
										16:30
										17:00
										17:30
										18:00
										18:30
										19:00

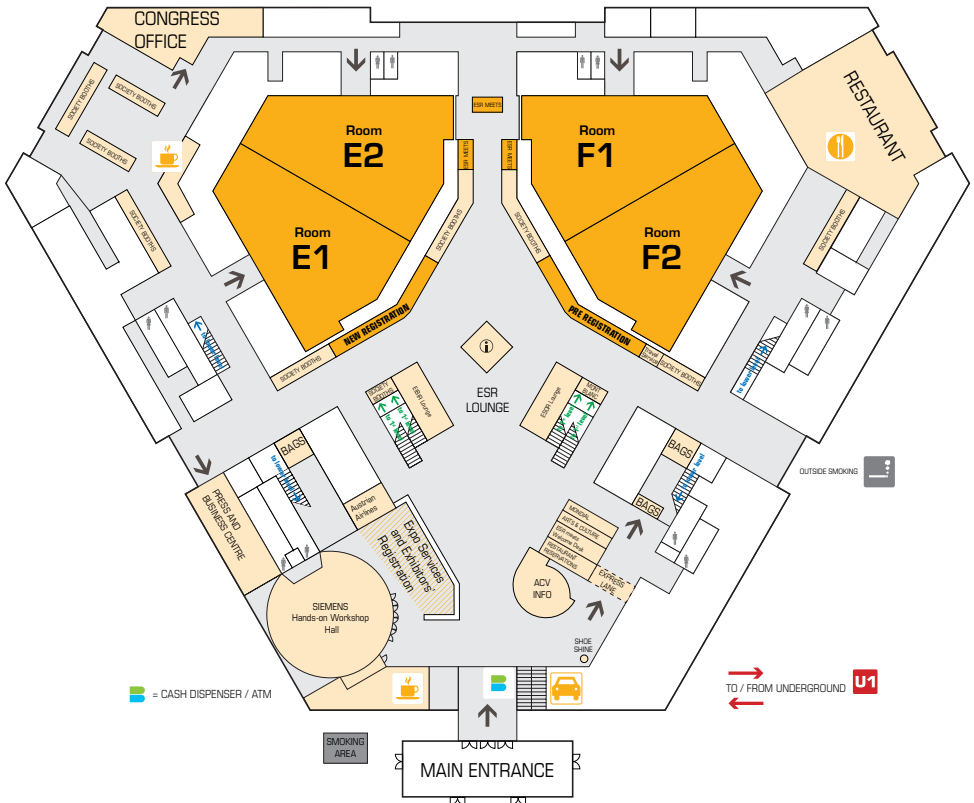
### U2 - LOWER LEVEL

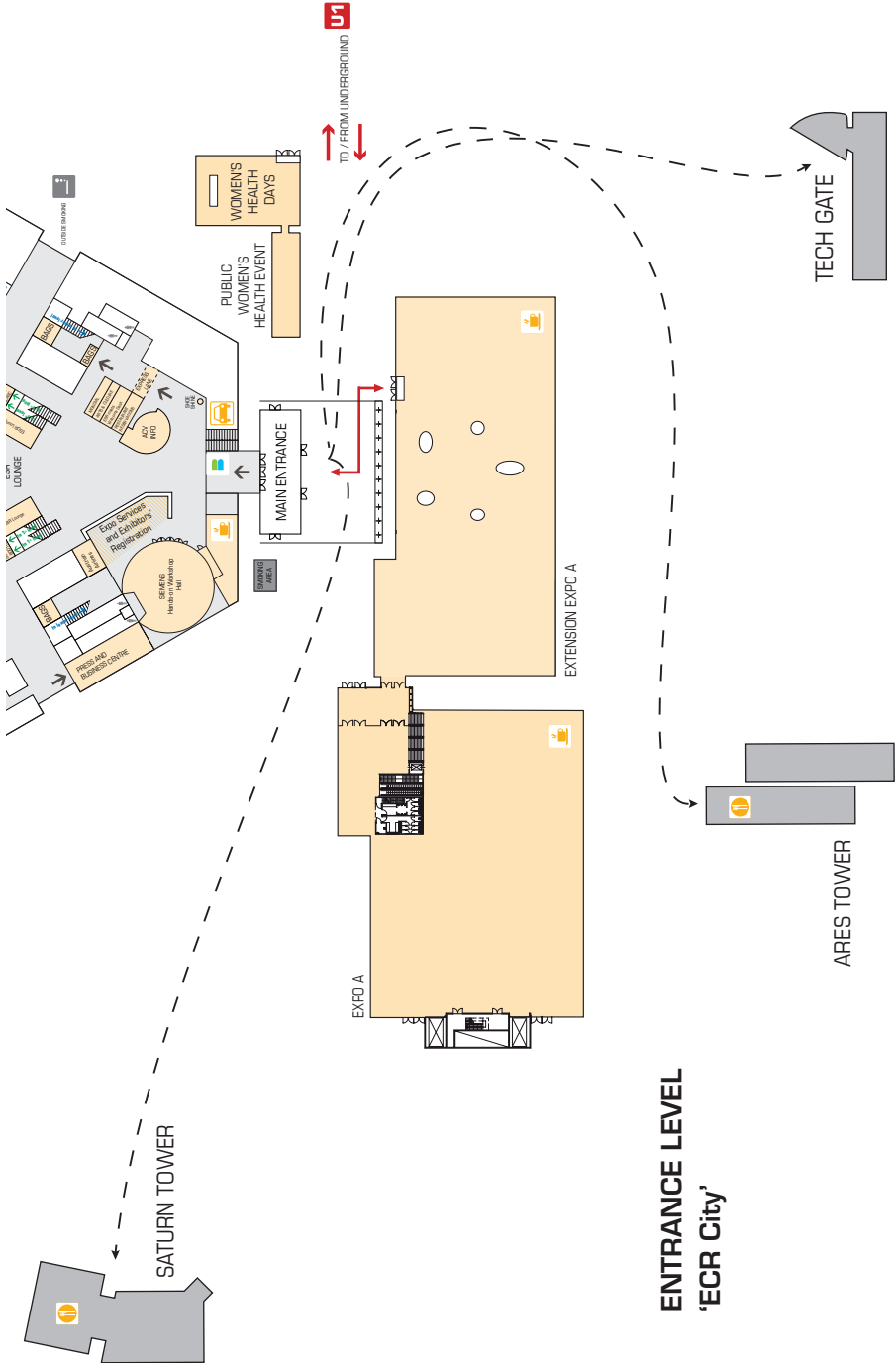





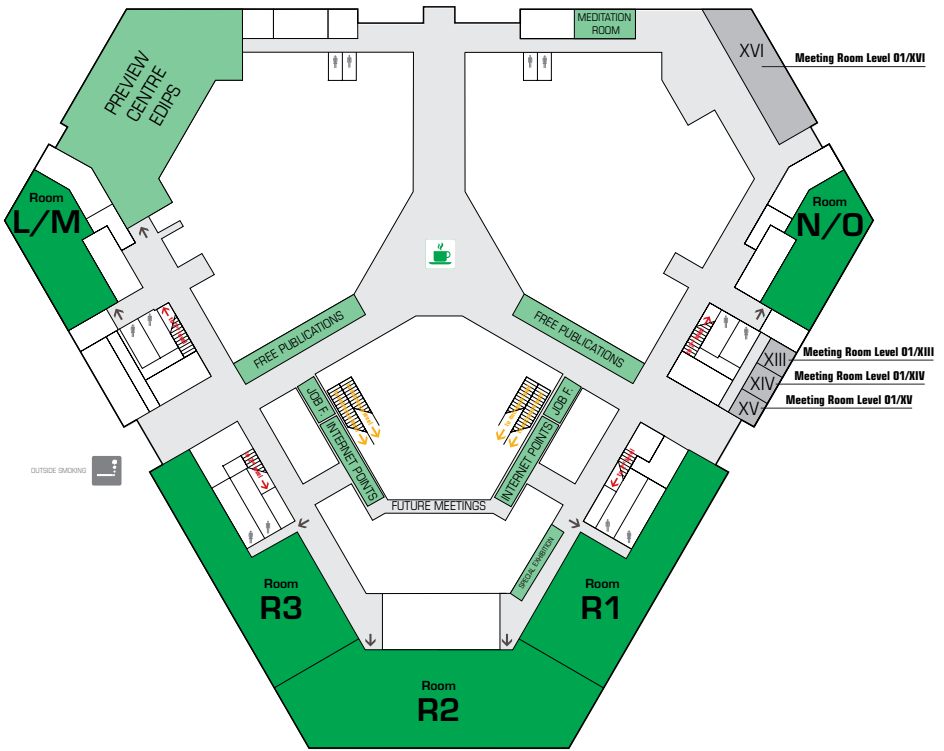



**OE – ENTRANCE LEVEL**



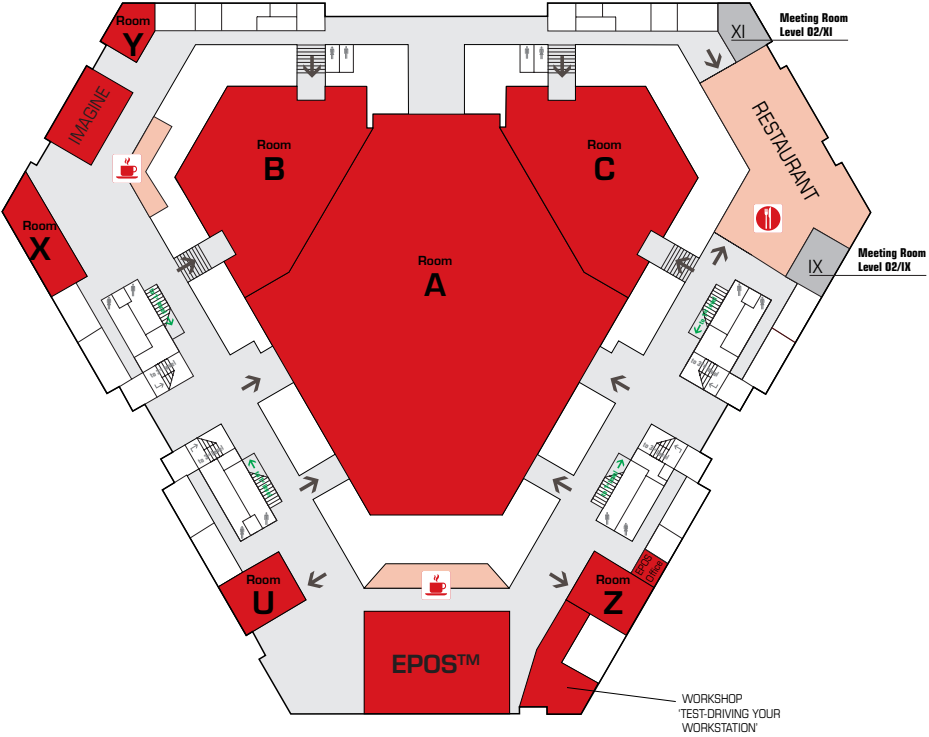


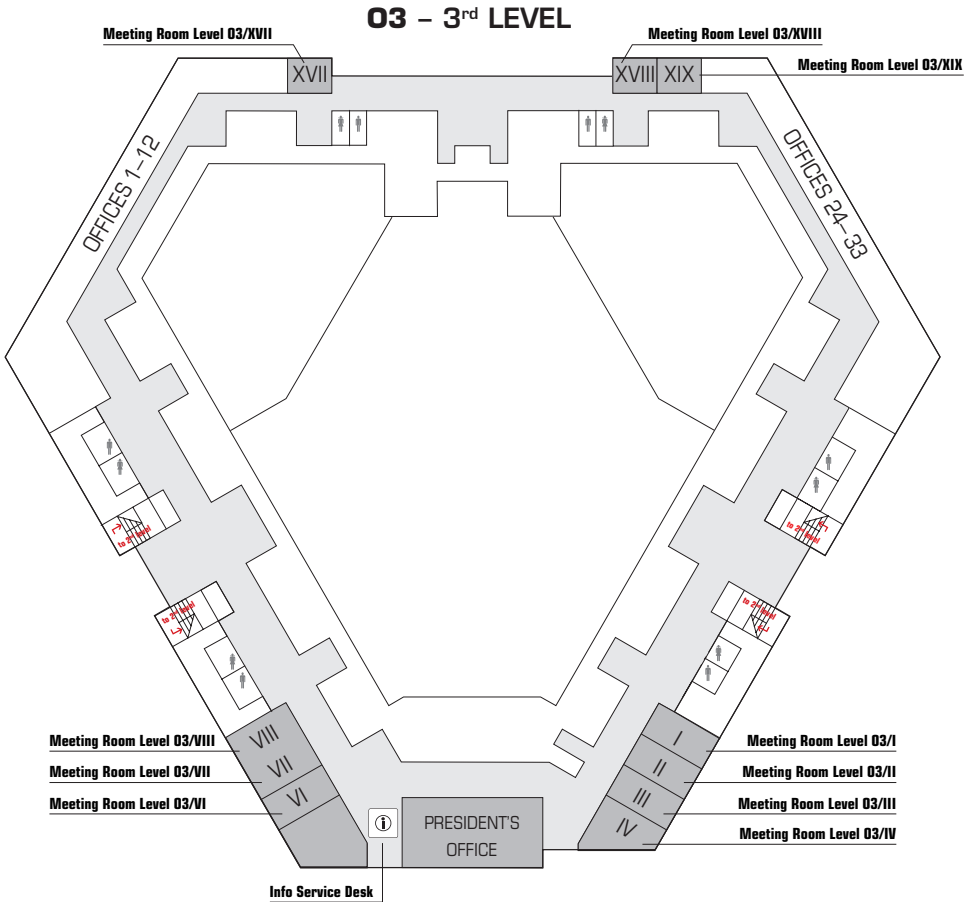
**01 – 1<sup>st</sup> LEVEL**





**02 – 2<sup>nd</sup> LEVEL**





Become a member  
for only  
€ 10.- per year

**29,375**  
members as per January 8, 2008



## Meeting Rooms

For Onsite Booking of Meeting Rooms please contact our staff at the Info Service Desk (Level 03).

### 03 – 3<sup>rd</sup> Level

Meeting Room Level 03/I  
 Meeting Room Level 03/II  
 Meeting Room Level 03/III  
 Meeting Room Level 03/IV  
 Meeting Room Level 03/V  
 Meeting Room Level 03/VI  
 Meeting Room Level 03/VII  
 Meeting Room Level 03/VIII

Meeting Room Level 03/XVII  
 Meeting Room Level 03/XVIII  
 Meeting Room Level 03/XIX

### 02 – 2<sup>nd</sup> Level

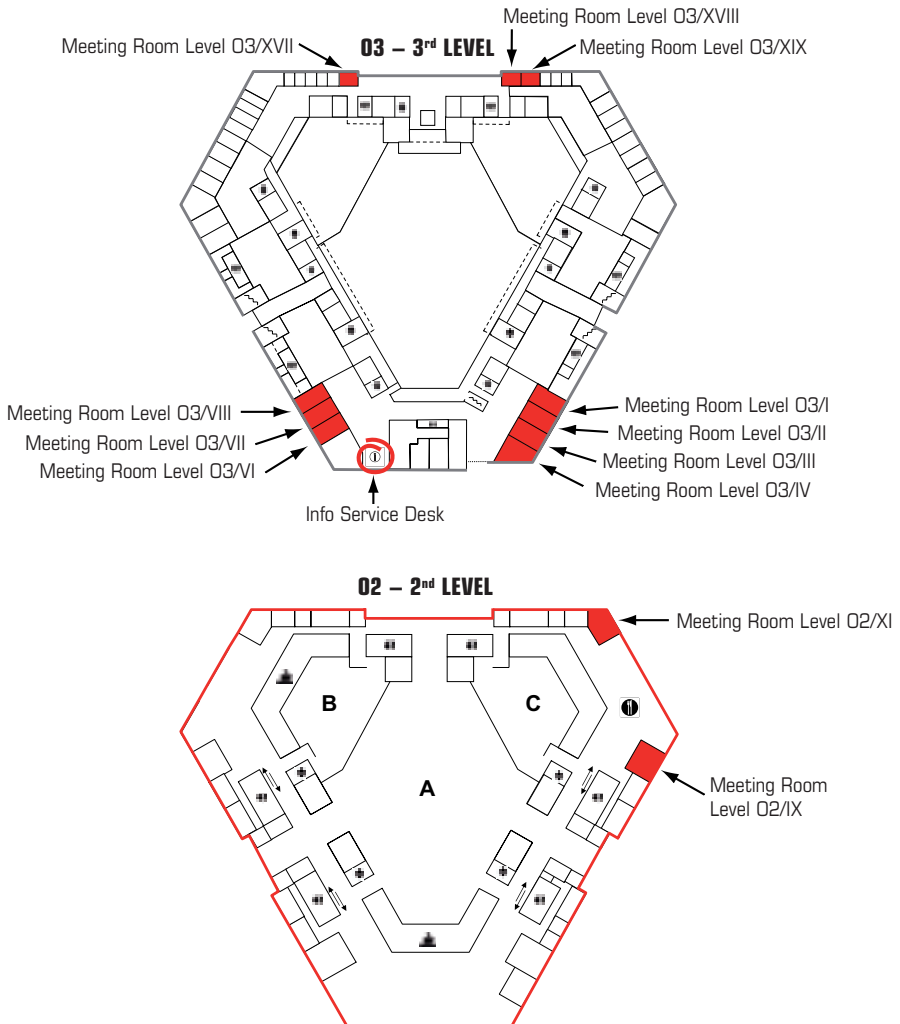
Meeting Room Level 02/IX  
 Meeting Room Level 02/XI

### 01 – 1<sup>st</sup> Level

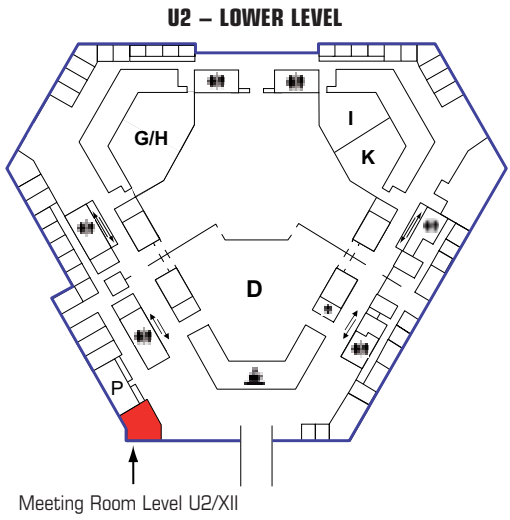
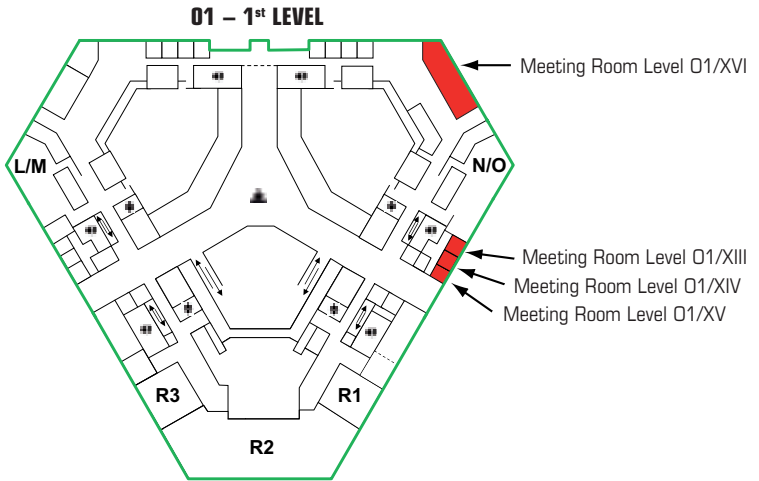

Meeting Room Level 01/XIII  
 Meeting Room Level 01/XIV  
 Meeting Room Level 01/XV  
 Meeting Room Level 01/XVI

### U2 – Lower Level

Meeting Room Level U2/XII









# ESR Women's Health Days

March 7–10, 2008

in front of the Austria Center Vienna

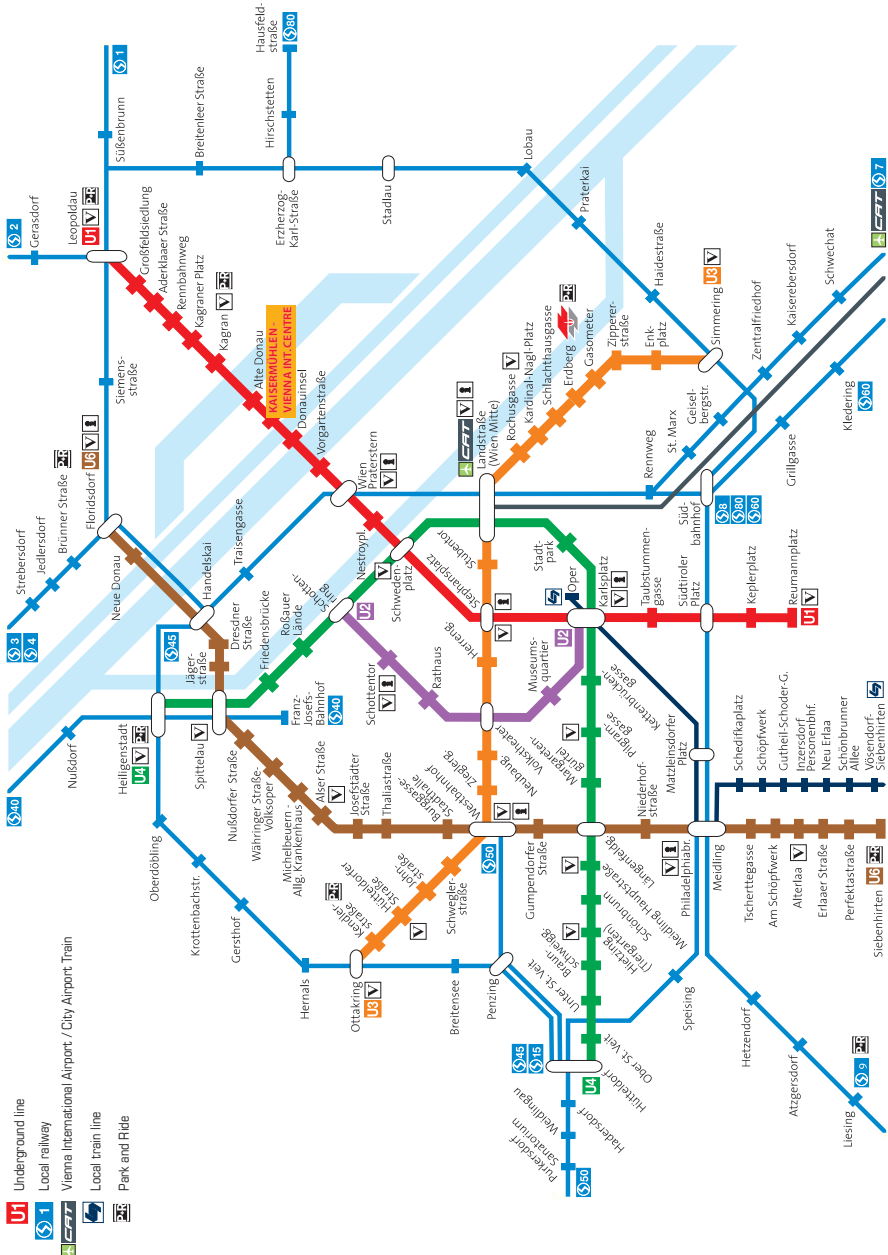

*Awareness for life*

An ESR event for Vienna's women, to raise public awareness of  
women's health and the role of imaging



[myESR.org](http://myESR.org)

kindly supported by **SIEMENS**



Hitachi Real-time Tissue Elastography:

# Discovering with all senses.

.artundwork.designbüro



**HI-RTE**

Hitachi Real-time Tissue Elastography

HI-RTE is an emerging ultrasound modality for the assessment and real-time colour display of tissue elasticity. The value of this 2nd generation ultrasound modality has been proven in a variety of different clinical areas, including breast, urology, endoscopy and many more.

#### **This unique HI-RTE modality...**

- Extracts strain data ensuring that quantitative measurements are available from the Strain Ratio tool
- Is easy to perform, fast, accurate and reproducible
- Incorporates an adjustable colour transparency feature, enabling instant correlation between the native B-mode and elasto image
- Is available for the new range of HI Vision platforms

**Don't miss our lunch symposium on HI-RTE on Sunday, March 9, 12.30–13.30, Room E1.**

## **Visit us in Expo B, Booth 203!**

Hitachi Medical Systems Europe Holding AG · Sumpfstasse 13 · CH-6300 Zug  
[www.hitachi-medical-systems.com](http://www.hitachi-medical-systems.com)

**HITACHI**  
Inspire the Next

## Committees & Dignitaries

- 6 Committees
- 8 Subcommittees
- 10 Topic Coordinators
- 11 ESR Dignitaries

## Programme Overviews & Floor Plans

- 23 Programme Overviews
- 34 Floor Plans
- 42 Meeting Rooms
- 45 Metro Map

## ECR Information from A–Z

- 48 ECR Information from A-Z**
- 57 EIBIR – European Institute for Biomedical Imaging Research**
- 58 CME at ECR 2008**
- 60 ESR meets Germany, Israel, India and GPs**
- 62 ESR e-Learning for Free**
- 64 ESR Electronic Congress**
- 65 IMAGINE at ECR 2008**
- 66 Plenary Sessions**
- 68 Image Interpretation Quizzes**
- 69 Hospital Management Symposium**
- 70 EPOS™ – Scientific Exhibition**
- 72 ESR Job Forum**
- 73 Welcome to our Industry Partners**
- 74 Food & Drink at ECR 2008**
- 75 Free Publications**
- 77 European Radiology**
- 78 ESOR – European School of Radiology**
- 85 Special Exhibition**
- 86 Arts & Culture**

## Programme by Topics

- 90 New Horizons Sessions
- 90 State-of-the-Art Symposia
- 91 Special Focus Sessions
- 96 Professional Challenges Sessions
- 97 Categorical Courses
- 100 Mini Courses
- 101 Refresher Courses / Scientific Sessions
- 120 E<sup>3</sup> – European Excellence in Education
- 123 Radiology Trainees Forum
- 124 Hands-on Workshops
- 128 1<sup>st</sup> Workstation Face-Off Session
- 129 Satellite Symposia
- 134 Industry Hands-on Workshops

## Educational & Scientific Programme

- 139 Contents
- 141 Postgraduate Educational Programme
- 268 Scientific Sessions
- 361 Scientific and Educational Exhibits
- 450 List of Authors and Co-authors
- 499 List of Moderators
- 502 Personal Planner

## Arts & Culture

Delegates are encouraged to visit the Arts & Culture Booth in the entrance hall to get information on Vienna's cultural events such as exclusive opera performances, delightful concerts, and the fascinating exhibitions in Vienna's most important and remarkable museums. Pick up your personal brochure at this counter to find descriptions of all cultural places!

## Badges

For organisational and security reasons, badges must be worn at the congress venue. Access to the different areas will only be granted upon presentation of an adequate badge.

Please note that in order to obtain CME credits, it is mandatory to affix your PersonalID – formerly ECRID – stickers to the evaluation forms available in each scientific session, and to drop these into the dedicated boxes.

## Lost Badge / Forgotten Badge

In the case of loss, a replacement badge will only be provided on full payment of the applicable onsite registration fee.

Forgotten badges will be replaced against a deposit of the full onsite fee.

## Book of Abstracts – 'European Radiology Supplements' (Supplement 1 to Volume 18)

Professional registrants will find a complimentary copy in their congress bag.

## Business Centre

The Press & Business Centre provides copy and data processing facilities for a certain fee. In addition, a wireless LAN is available in the Business Centre, allowing you to access the Internet with your private laptop. The Press & Business Centre is located on the entrance level.

## Cases-of-the-Day

From Friday through Monday, five Cases-of-the-Day covering different sections of radiology will be shown in EPOST™ (ECR's Electronic Presentation Online System) on the 2<sup>nd</sup> level. Participants are invited

to submit their diagnoses. The winners will be announced on the ESR website.

We would like to acknowledge the contribution of the following first authors to the Cases-of-the-Day:

*U. Bick (Germany), S. Bisdas (Germany), N. Bolog (Romania), J. Calvo-Blanco (Spain), G. Chatzakis (Greece), R. De Wyngaert (Belgium), S. Diekmann (Germany), G. Erbas (Turkey), M.P. García-Peña (Spain), S. Haegeman (Belgium), L.J. Kemna (Germany), A.R. Larici (Italy), E. Llopis (Spain), M.L. Lobo (Portugal), S. Schepers (Belgium), S. Siurana (Spain), C. Triantopoulou (Greece), L. Tzarouhi (Greece), F.M.H.M. Vanhoenacker (Belgium), I. Várkonyi (Hungary).*

## Categorical Courses

Two new Categorical Courses on 'MRI' and on 'Breast: From Basics to Advanced Imaging' will be presented at ECR 2008. The Categorical Course on 'Multidetector CT Made Easy' is repeated from ECR 2007. The presentation material will be available at EDIPS Download (<http://edips-download.myESR.org>) after the congress.

Places will be allocated on a first-come, first-served basis. Please refer to pages 97–100 for the courses' programmes.

## Churches and Religious Communities in Vienna

Vienna is a multi-religious, multi-ethnic city. We will be pleased to provide you with information on your religious community at the Travel Service Desk.

## CME Accreditation System


See pages 58–59.

## Coat Check

The coat check service is located on the lower level and offered free of charge to ECR 2008 delegates.

## Coffee / Snack Bars

If you are looking for an ideal communication point, or if you just want to take a short break, the various foyer cafés and coffee shops will suit you best. They are situated throughout the whole congress venue and across all levels of the building, offering a variety of tasty hot and cold snacks. Fine Italian



coffee is served, as well as pastries, pies and other delicacies to suit guests from a variety of cultural backgrounds. Within the technical exhibition area, ECR has built its own cafés in Extension Expo A, C, D and E. Please look at the 'coffee-cup' signs on the floor plans to locate the various foyer cafés.

Additionally, all delegates and exhibitors are invited to satisfy their hunger at the two restaurants in the Austria Center Vienna, where you will find a delicious buffet lunch and live cooking. Participants can also dine at the stylish Saturn Lounge at Saturn Tower and the restaurant Avocado at Ares Tower in 'ECR City', reachable within only 2 minutes walk. For detailed information and opening hours, please look at the 'Restaurants' section of this programme.

#### **Confirmation of Payment and Attendance / CME Accreditation**

Any congress-related confirmation will be available during and after the congress at the ESR website ([www.myESR.org](http://www.myESR.org)) in the MyUser area (login with your last name and your PersonalID as printed on your badge). Internet access will be provided at the registration terminals (from Sunday, March 9 onwards) as well as at the internet points and W-LAN areas (see floor plans).

#### **Congress Language**

English

#### **Congress Venue**

Austria Center Vienna  
Bruno Kreisky Platz 1  
1220 Vienna, Austria  
Phone: (+43 1) 533 40 64-0

To reach the ACV by public transport from the city centre (Stephansplatz) take the U1 underground line (red line, direction Leopoldau). Get off at Vienna International Centre/Kaisermühlen and take the exit marked Schüttaustraße. Travelling time: Approximately eight minutes.

#### **ECR Cares**

ECR is an environmentally conscious meeting, thus there will be no more plastic bottles distributed by ECR, and no carpets.

Water coolers are placed throughout the congress venue. In addition, free massage is offered in Foyer G/H on the lower level, shoe shining services will be available on the entrance level free of charge.

#### **ECR Today**

ECR Today, the popular daily newspaper of the congress, will again be published from Friday to Monday and distributed in the entrance hall of the congress venue and in the entrance area of the Technical Exhibition.

#### **EFOMP (European Federation of Organisations for Medical Physics) Workshop**

The 10<sup>th</sup> EFOMP workshop at ECR will focus on the technological aspects, clinical perspectives and safety implications of high-field magnetic resonance imaging (please refer to page 118).

#### **EIBIR Lounge**

Visit the EIBIR Lounge in the entrance hall of the congress venue and receive the most recent news on the European Institute for Biomedical Imaging Research.

#### **Emergency Information / First Aid**

For fire, medical or police assistance, please contact ACV Information on internal telephone number 155, or dial the emergency number 123. All elevators are fitted with telephones. A medical specialist trained in emergency medicine will be present throughout the congress.

#### **ePACS**

ePACS is an e-learning tool for both novices and experts, and will be shown in EPOS™ on the 2<sup>nd</sup> level. It intends to support lectures and courses by enabling participants to improve their performance in diagnosing and reporting of cases presented with clinical and radiological information only. See page 62.

#### **EPOS™ – Scientific Exhibition**

At the start of ECR 2008, EPOS™, the Electronic Presentation Online System, will grow by more than 1,000 electronic presentations. A total of 944 posters were accepted for presentation in EPOS™

(486 scientific exhibits and 458 educational exhibits). An additional 82 presentations have been submitted by speakers from the educational/scientific programme. More than 100 computer workstations are available.

Besides EURORAD, the largest peer-reviewed database of radiology teaching files on the Internet, Cases-of-the-Day, Self-Assessment in Interventional Radiology and ePACS are also available in EPOST™ (see pages 70–71).

During ECR 2008, EPOST™, located on the 2<sup>nd</sup> level, is accessible daily: Friday to Monday from 07:00 to 19:00 and Tuesday from 07:00 to 14:00.

Note: On Saturday, March 8, 12:15–13:15, EPOST™ will be closed for a self-assessment test for the participants of the foundation course on interventional radiology.

### ESOR Lounge

Visit the ESOR Lounge in the entrance hall of the congress venue and receive the latest news on the European School of Radiology.

### ESR Booth

Visit the ESR Booth in the entrance hall! Find all relevant information about ESR Membership and the journal *European Radiology*. Become a Member!

### 'ESR Meets' Sessions

The purpose of 'ESR meets' is to forge closer ties between the invited countries and ESR. The host nation is the country of the Congress President: **Germany**. The two guest nations of this year's ECR are **India** and **Israel**. There are dedicated sessions for the radiological communities of these nations to demonstrate the excellence of radiology in their countries to congress attendees.

In addition, ECR 2008 introduces a new feature, where there will also be special activities focussing on various partner disciplines, this year the General Practitioners, which will provide a platform to establish closer ties.

Places at these sessions will be allocated on a first-come, first-served basis. Please refer to page 60–61 for the programmes of the sessions.

As a special service for our guest countries, ECR will maintain dedicated Welcome Desks in the entrance hall.

### ESR Office

Neutorgasse 9  
1010 Vienna, Austria  
Phone: (+43-1) 533 40 64-0  
Fax: (+43-1) 533 40 64-448  
myESR.org

During ECR 2008 the ESR Office will be onsite at the Austria Center Vienna.

### 'European Radiology'

Subscribe to ESR's official journal at the ESR Booth in the entrance hall.

See page 77.

### Face-Off Session

For the first time ever, in 2008, ECR will present a 'Workstation Face-Off' session.


The aim of this session is to simulate a realistic 'reading room' atmosphere and to give an impression of how different workstations perform in a clinical scenario. We would like to cordially invite you to attend this 'competition' of post-processing (see page 128).

### Foundation Course

This basic teaching course, which will take place under the heading of **E<sup>3</sup> – European Excellence in Education**, in room E2 on the entrance level, is designed to be suitable for trainees and for those who wish to refresh their knowledge. The motto of the course is 'All you need to know about interventional radiology in 12 easy lessons. This course answers your questions!' The 30-minute lectures are followed by 15-minute interactive Q&A sessions with the use of an electronic voting system (key-pads).

The course will be concluded with a self-marking electronic examination that will allow the participants to assess what they have learned. The self-assessment test will take place in the EPOST™ area on Saturday, March 8, 12:15–13:15. Certificates will be provided to the attendees. The presentation material will be available at EDIPS Download (<http://edips-download.myESR.org>) after the congress.





Places will be allocated on a first-come, first-served basis. Please refer to pages 120–121 for the course programme.

### Free Publications

After last year's enormous success, ECR again presents the 'Free Publications' booth located on the 1<sup>st</sup> level. Pick up your free copies of radiology journals and magazines and get free access to online radiology journals! Free bags are provided for your convenience.

### Hands-on Workshops

The following Hands-on Workshops are presented at ECR 2008:

- Image Guided Breast Biopsy: How to do it
- Experience Vascular Procedures Using Simulators
- Tips and Tricks in Radiofrequency Ablation
- Test-Driving your Workstation

The number of participants of each workshop is restricted. Please refer to pages 124–128 for the workshops' programmes.

### Hospital Management Symposium

Do not miss out on the 5<sup>th</sup> edition of the Hospital Management Symposium to be held on Saturday, March 8, on hot topics related to 'Management, IT and finance for hospitals and radiologists'. The symposium is presented and organised by ECR and European Hospital.

See page 69.

### IMAGINE

ECR's popular high-tech specialty exhibit is back. New technological developments in the field of diagnostic and interventional radiology will be shown on the 2<sup>nd</sup> level in Foyer A.

The focus is on CAD, interactive visualisation, image-guided interventions & robotics, and computer-based training.

### Opening hours:

Friday, March 7: 12:00–17:00  
Saturday, March 8 to Monday, March 10:  
10:00–17:00

See page 65.

### Industry Hands-on Workshops

At ECR 2008 there are various Industry Hands-on Workshops scheduled around ECR City:

### Austria Center

- Industry OsiriX User Meeting organised by Apple  
Come and discover OsiriX at the OsiriX User Meeting @ ECR 2008, on Saturday March 8, 15:30, Meeting Room Level U2/XII.
- Industry Hands-on Workshops organised by Siemens Medical Solutions  
'Siemens Hands-on Workshop Hall'  
For different modalities like MR, CT and interventional angiography, guided by clinical experts.  
Friday, March 7 to Monday, March 10

### Tech Gate (two minutes walking distance)

- Industry Hands-on Workshop organised by Carestream Health  
Digital Mammography Workshop  
'Fit for Screening'  
Saturday, March 8 and Sunday, March 9, 08:30–18:00
- Industry Hands-on Workshop organised by Philips Healthcare  
Experience simplicity in CT daily routine at Philips CT 3D lab. Technologists are invited!  
Sunday, March 9, 09:30–16:00

Industry Hands-on Workshops are CME accredited.  
See pages 134–135.

### Interactive Teaching Course and Sessions

Under the heading of **E<sup>3</sup> – European Excellence in Education**, ECR 2008 presents a course on 'Useful Signs in Imaging', focusing on head and neck, abdominal, genitourinary, chest and musculoskeletal imaging as well as ten interactive teaching sessions dealing with specific topics of diagnostic imaging, establishing a two-way interaction between the presenters and the participants.

The material will be presented in an interactive way with audience participation and self assessment by use of an electronic voting system (key-pads).

Places will be allocated on a first-come, first-served basis. Please refer to pages 121–122 for the programmes of the sessions.

### Internet Points

Computer terminals with internet connections are available on the 1<sup>st</sup> level and can be used for multiple purposes. Delegates can compile their personal session itineraries using the programme planner, send e-mails and browse the World Wide Web.

### (Junior) Image Interpretation Quiz

The Image Interpretation Quizzes are two traditional highlights of every ECR. This year's themes are 'The battle of the sexes' and 'Europe vs India' (see page 68).

### Job Forum

The ESR Job Forum is a newly established recruitment platform bringing together job-seekers and employers from all over the world in the field of radiology and related disciplines. It is easy to use, offers various beneficial services, handles sensitive data discreetly, and concentrates on the specific requirements of the radiological community.

Visit the ESR Job Forum onsite 1<sup>st</sup> level or at [www.myESR.org/jobforum](http://www.myESR.org/jobforum). Post your vacant position or your profile today to find your ideal job-connection!

### Liability

ESR and the Austria Center Vienna are free from all liabilities that may arise from the delegates' and presenters' participation in ECR 2008 and its activities.

### Lost and Found

Lost and Found articles may be picked up at the ACV Information Desk located in the entrance area.

### Meditation Room

The Meditation Room is located on the 1<sup>st</sup> level, close to the restaurant. You will find it marked on the floor plan.

### Meeting Rooms

Meeting Rooms at ECR 2008 are to be found on:

3<sup>rd</sup> Level: Meeting Rooms I – IV, VI – VIII, XVIII – XIX

2<sup>nd</sup> Level: Meeting Rooms IX and XI, next to the restaurant

1<sup>st</sup> Level: Meeting Rooms XIII – XV

Lower Level: Meeting Room XII

You will find them marked on the floor plan.

Please contact the Info Service Desk on the 3<sup>rd</sup> level for access to and onsite booking of meeting rooms.

### Membership

For membership application and renewal, please contact the ESR Booth in the entrance hall.

### Mini Courses

Two Mini Courses are presented at ECR 2008: 'Molecular Imaging' and 'Women's Imaging: Female Pelvis'. The presentation material will be available at EDIPS Download (<http://edips-download.myESR.org>) after the congress.

Places will be allocated on a first-come, first-served basis.


Please refer to pages 100–101 for the courses' programmes.

### New Horizons Sessions

The aim of the New Horizons Sessions is to provide practitioners with an overview of the new developments in a specific area of practice e.g. specialty, technique, or disease. These developments may become routine within a few years, or may indicate a new direction for research and clinical application. Places will be allocated on a first-come, first-served basis. Please refer to page 90 for the programmes of the sessions.

### Plenary Sessions

See pages 66–67.



## Press

A press conference takes place on Friday, March 7, at 09:00 at the Austria Center Vienna, Meeting Room IX (2<sup>nd</sup> level). For press accreditation, please contact the Press Office on the entrance level. To obtain a press badge, an international press ID or a confirmation letter from the relevant medium must be presented.

Delegates and exhibitors may display their press kits in the Press & Business Centre.

## Preview Centre – EDIPS

EDIPS, ECR's digital preview system, allows for fast and easy presenter identification through badge scanning. Big screens in the waiting area display the names of the presenters asked to proceed to the Check-In counter where they hand in their presentations. At the Preview Stations, presenters have the opportunity to do a final check on their presentations. Again, for this year, presenters were offered the option of submitting their material prior to the congress!

The preview centre is located on the 1<sup>st</sup> level, Foyer L/M.

## Opening hours:

Thursday, March 6: 12:00–19:00

Friday, March 7 through

Monday, March 10: 07:00–19:00

Tuesday, March 11: 07:00–14:00

Please note that only digital material will be allowed for oral presentations.

The material must be in English and must be provided on CD-ROM, DVD, ZIP disk or USB devices so that it can be transferred to a central server onsite. It is mandatory that the data carriers are delivered to the audiovisual preview centre 2 hours prior to the session, at the latest. Computers connected to data projectors are provided in each lecture room for the speaker to retrieve the saved data. Private laptops/notebooks may not be used.

The material remains the property of the speakers and will not be reused without permission. The data will be deleted after the congress. Presenters will be asked to give their permission for their presentations to be shown electronically after the congress at EDIPS Download (<http://edips-download.myESR.org>).

## Professional Challenges Sessions

The concept of these sessions is to communicate and exchange issues on radiological training and education, research networking, radiological management and professional developments. This year's topics are:

- Teleradiology: Film reading at the seaside?
- Capturing the market: How quality helps
- Women in radiology: How to maximise their input.

Places will be allocated on a first-come, first-served basis. Please refer to page 96 for the sessions' programmes.

## Public Transport

Tickets for public transportation are available at the Mondial Desk in the entrance area.

Special ECR Tickets:

5 days (valid from March 7): € 15.90

4 days (valid from March 7): € 14.20

72-hour ticket: € 13.60

Single tickets (one way only): € 1.70

Metro map: see page 45.

## Radiology Trainees Forum (RTF)

RTF promotes and coordinates the efforts of radiology trainees at a European level in order to improve the progress of radiology and related sciences. One of RTF's most important goals is to provide an equal level of radiological knowledge and skills for radiology trainees all over Europe.

'Highlighted Lectures' organised by RTF will be given on Saturday, March 8, 16:00–17:30 in Room K (see page 123).

A cocktail reception will take place on Saturday evening at the Restaurant Barbaro (Neuer Markt 8, at 19:30. Free admittance for trainees, registration required).

The RTF General Assembly will be held on Sunday, March 9, 16:30–18:00, Meeting Room XI (2<sup>nd</sup> level). For more detailed information please visit the RTF booth on the entrance level.

## Recording

Video or audio recording of presentations is not allowed without the speaker's/exhibitor's and ECR's prior permission. Please contact the ECR Press and Business Centre in case of enquiries.

## Refresher Courses

75 refresher courses have been organised by the various subcommittees for ECR 2008.

Places will be allocated on a first-come, first-served basis.

Please refer to pages 101–120 for the programmes of the sessions.

## Registration

### Opening Hours

Thursday, March 6	09:00–19:00
Friday, March 7	07:00–19:00
Saturday, March 8	07:00–19:00
Sunday, March 9	07:00–18:00
Monday, March 10	07:00–18:00
Tuesday, March 11	07:00–14:00

## Restaurants

Besides various foyer cafés and coffee shops – see 'Coffee / Snack Bars' in this programme – meals and drinks are served at the two restaurants in the Austria Center Vienna. There, live cooking and a delicious buffet lunch are waiting for you, offering a wide range of food.

In addition, ECR 2008 features two new restaurants within 'ECR City'. For the first time, delegates as well as exhibitors can satisfy their hunger at the stylish Saturn Lounge in Saturn Tower and the restaurant Avocado in Ares Tower. Within only 2 minutes walk you can enjoy tasty Austrian and International cuisine.

All participants are invited to find refreshments in the restaurants during the opening hours:

- Restaurant in the Austria Center Vienna (Foyer F, OE): 11:30 am – 2 pm (March 7–10)
- Restaurant in the Austria Center Vienna (Foyer C, O2): 11:30 am – 2 pm (March 7–10)

- Avocado (Ares Tower): weekdays 8 am – 7 pm, weekend 11 am – 6 pm
- Saturn Lounge (Saturn Tower): weekdays 8 am – 7 pm, weekend 8 am – 3 pm

## Restaurant Reservations

Our staff at the Congress Restaurant Reservations Desk will be pleased to recommend places to eat close to your hotel or near a certain theatre, and will be happy to reserve a table of your choice.

## Satellite Symposia

Industrial satellite symposia (see pages 129–133) have been organised by international companies. Attendance at these symposia will be certified – on condition that the relevant completed evaluation form has been received by the organisation. Places will be allocated on a first-come, first-served basis.

## Scientific Presentation Prizes

The authors of the best scientific papers and scientific/educational exhibits will be awarded a prize of € 1,500.-.

**Scientific Papers:** The prize will be assigned to the best paper presentation of each topic, based on the evaluation by session moderators. Selection criteria will comprise quality of presentation and images, scientific content and overall impression of the performance.

The prize winners will be informed after the congress and will be published on the ESR website and in the ESR Newsletter. ECR 2009 registration fees will be waived for the presenters.

Scientific/educational exhibits: see page 70 (Scientific Exhibition Awards).

## Scientific Programme Planner / Abstract Viewer

All ECR 2008 abstracts can be accessed online via the Scientific Programme Planner tool on the ESR website. This easy-to-use tool allows you to explore the entire scientific and educational programme by session type, topic and date. You can also search for abstract texts, authors and abstract titles.

In addition, the system offers a user-friendly feature to create your personal schedule for the



meeting, either to print out or upload to your PDA. Customising your schedule for ECR 2008 could not be easier.

### **Security / Safety**

The safety of all congress attendees is of utmost importance to the European Society of Radiology. The Austria Center Vienna and ESR have taken security precautions to ensure the maximum possible safety for all ECR participants. Please inform our staff, especially our room attendants, immediately if security problems occur.

ESR reserves the right to check your identification upon admission to the congress centre and/or inside the building. You may be asked at any time to present adequate proof of identity by showing either your passport, driver's licence, national or military identification, or student ID, all with photograph and signature.

### **Smoking**

Smoking is not permitted inside the Austria Center Vienna. ECR is a non-smoking congress. Outside the building, we kindly ask you to use the ashtrays provided.

### **Society Booths**

More than 60 national and international radiological societies present their meetings and societies in the society booths area, which is located at the entrance level, next to the registration desk and in front of Foyer E.

### **Special Assistance**

Delegates with special needs may park on the lower level as well as on the square in front of the main entrance, where wheelchair access is possible. All lecture rooms are accessible by wheelchair.

### **Special Exhibition**

In compliance with ECR's tradition of offering its delegates an ambitious supporting programme at the annual congress, ECR is again proud to present an exhibition by Prof. Vogel, from Hamburg/DE, in cooperation with the German Röntgenmuseum. This year's exhibit is entitled 'X-Rays and Society. Perception, Threat, Torture.' and is presented on the 1<sup>st</sup> level, opposite Room R1.

### **Special Focus Sessions**

The concept of a Special Focus Session is to deal with a topic at the cutting edge of development and clinical application. A traditional didactic approach is inappropriate for such a session, which should reflect the lecturer's forthright personal views on a developing subject. The topics of these sessions should be presented in such a way so as to promote debate and to give an in-depth analysis. The chairman will introduce each aspect of the topic and the panellists will then discuss their different perspectives and opinions. The audience will have the opportunity to discuss their ideas with the lecturers. Places will be allocated on a first-come, first-served basis. Please refer to pages 91–95 for the programme of the sessions.

### **State-of-the-Art Symposia**

These sessions will inform the audience about the 'real state of the art' of a given subject. Each of the lecturers is an expert on the topic as a whole or on some specific aspect of the topic, which will be the subject of the respective session. The presentations will be followed by a discussion conducted by the panellists, led by the chairman. Places will be allocated on a first-come, first-served basis. Please refer to pages 90–91 for the programmes of the sessions.

### **Taxi**

There is a taxi stand outside the main entrance. To call a taxi, please dial (+43 1) 40 100.

### **Technical Exhibition**

#### **Opening hours:**

Friday, March 7:

14:00–18:00

Saturday, March 8 to Monday, March 10:

10:00–18:00

Detailed information on the Technical Exhibition can be found in the 'On Show Exhibition Guide – Exhibitor Directory and Product Information', which will be distributed together with the congress bags.

### Travel Service

ESR and ECR are proud to offer their delegates a series of services that should facilitate their travel arrangements and make their stay in Vienna as pleasant as possible. Close to ESR's Travel Service Desk you will find ECR's official travel agency, Mondial, which will be open from Thursday, March 6 until Monday, March 10, 07:00–18:00 and on Tuesday, March 11, 07:00–12:00. It is located on the entrance level of the Austria Center Vienna.



### Air Travel/Housing

The Austrian Airlines desk in the entrance area offers the following services for Austrian Airlines and Star Alliance flights:

#### Ticket office:

Friday, March 7 to Monday, March 10:

09:00–18:00

Tuesday, March 11:

09:00–14:00

#### Check-in services:

Sunday, March 9 to Monday, March 10:

09:00–18:00

Tuesday, March 11:

09:00–14:00

### At Vienna Airport

- Check-in for Star Alliance flights with hand-baggage only:  
Deadline: Latest passengers to show up at the respective boarding gate at Vienna Airport according to boarding time shown on boarding pass
- Check-in for Star Alliance flights (except flights to Tel-Aviv and USA) with baggage:  
Deadline: Latest passenger to show up with baggage at dedicated congress check-in desk / Terminal 1 at Vienna Airport 45 minutes before departure.

### Wireless LAN

Free wireless LAN access is available all over the congress venue.

# EIBIR Information Bulletin

First success stories of EIBIR's networking activities put down to experience:

- Completion of EIBIR Research Policy Paper as a co-ordinated European research plan within the 6<sup>th</sup> EU Framework Programme 'Life Sciences, genomics and biotechnology for health'
- EIBIR Report November 2007, with news about future networking activities and initiatives for the forthcoming years
- Database of members' expertise plus calendar for training courses and workshops on biomedical imaging, online
- ENCITE – European Network for Cell Imaging and Tracking Expertise: a project within the 7<sup>th</sup> EU framework programme on the theme 'Co-operation Health – in vivo image-guidance for cell therapy'. Co-ordinated by EIBIR, 21 international project partners with leading expertise in the field of cell imaging will develop and implement:
  - new imaging methods to improve tracking of labelled cells
  - dual and multimodality imaging procedures
  - new contrast agents improving specificity of cellular labelling
  - combining molecular biology for the generation of molecular and cellular imaging reporters with multimodal imaging techniques

EIBIR has grown into a strong network, with 202 members throughout Europe.

Interested in becoming a member of EIBIR?

Please apply at: [www.eibir.org](http://www.eibir.org)

Contact:  
EIBIR office  
Neutorgasse 9/2a  
1010 Vienna, Austria  
Phone: (+43-1) 533 40 64-20  
Fax: (+43-1) 535 70 41  
E-mail: [office@eibir.org](mailto:office@eibir.org)

co-funded by the 6<sup>th</sup> EU Framework



## CME AT ECR 2008

### General Information

Each ECR delegate receives a confirmation of the attended activities (CME confirmation – Record of attendance). The approximate maximum number of hours to attend at scientific activities is 40 (please note that this number differs from the maximum number of UEMS/EACCME credits).

### CME ACCREDITATION

#### Europe

The ECR – European Congress of Radiology 2008 is accredited by the European Accreditation Council for Continuing Medical Education (EACCME) to provide the following CME activity for medical specialists. The EACCME is an institution of the European Union of Medical Specialists (UEMS), [www.ums.net](http://www.ums.net).

ECR 2008 is designated for a maximum of 27 hours of European external CME credits. Each medical specialist should claim only those hours of credit that he/she actually spent in the educational activity. European Accreditation is granted by the EACCME in order to allow participants to validate the credits obtained at this activity in their home European Country.

The following countries are members of the UEMS: Austria, Azerbaijan, Belgium, Bulgaria, Croatia, Cyprus, Czech Republic, Denmark, Estonia, Finland, France, Georgia, Germany, Greece, Hungary, Iceland, Ireland, Italy, Latvia, Luxembourg, Malta, Netherlands, Norway, Poland, Portugal, Romania, Slovakia, Slovenia, Spain, Sweden, Switzerland, Turkey, United Kingdom.

#### USA

The American Medical Association (AMA) has an agreement of mutual recognition of continuing medical education (CME) credit with the European Union of Medical Specialties (UEMS). Under the terms of this agreement, the AMA will convert CME credit certified by the European Accreditation Council for Continuing Medical Education (EACCME), the accrediting arm of the UEMS, to AMA PRA Category 1 Credit™. Physicians (MDs, DOs or equivalent international degree) may have their EACCME credit

converted to AMA PRA Category 1 Credit™ by applying to the AMA.

For further information about the conversion of EACCME credits into AMA PRA Category 1 credits, please contact the AMA at [pra@ama-assn.org](mailto:pra@ama-assn.org) or visit the AMA website at <http://www.ama-assn.org>

### Worldwide

CME claimed at the ECR are accepted by almost all national CME authorities worldwide.

#### Austria

ECR is an accredited CME provider of the Austrian Medical Chamber. The Austrian Medical Chamber has granted a maximum of 40 DFP (Diplom-Fortbildungs-Programm der Österreichischen Akademie der Ärzte) credits for ECR 2008.

#### Germany


Austrian CME credits (DFP-Punkte) earned during this meeting are recognized by all German Medical Chambers 1:1. The key for converting CME hours into DFP credits is as follows: DFP Credits = number of hours x 60 / 45.

#### Contact

ECR CME Support  
Mr. Benjamin Ohr  
Neutorgasse 9  
1010 Vienna, Austria

E-mail: [cme@myESR.org](mailto:cme@myESR.org)  
Phone: (+43 1) 533 40 64-0  
Fax: (+43 1) 533 40 64-448  
Web: [myESR.org](http://myESR.org) → ECR Congress → CME





### **CME Acquisition Procedure**

CME (continuing medical education) credits will only be awarded, if

- the questionnaire provided at the entrance of each session is fully completed,
- your unique personal CME sticker, which you will receive together with your badge, is affixed,
- and the form is dropped into the provided box immediately after the relevant scientific session.

The combined participation and evaluation questionnaire considerably helps the next organising committee to select subjects for future ECRs. Evaluation sheets differ depending on the types of the scientific event.

A maximum of 3 hours of attendance at the scientific exhibition (SE) will be listed if the participant has completed and submitted the online SE evaluation form using EPOS™ (Electronic Presentation Online System).

### **Guidance**

Confirmation of participation in the scientific programme is to be obtained as follows:

#### **Scientific Sessions**

1. Participate in the event of your interest.
2. Personalise the relevant questionnaire (evaluation form) using your CME sticker, since otherwise it is not possible to sort out the forms afterwards and to provide confirmation.
3. Fill in this form completely during the session.
4. Drop the completed form into the box provided at the exit of the room when leaving the session.

### **Scientific Exhibition**

Attendance and evaluation are recorded online in EPOS™.

1. Enter EPOS™ (Electronic Presentation Online System) and view the posters of your interest. If you logout EPOS™, you will be asked to complete the evaluation form.
2. Fill in this form completely and press the 'Submit' button.

Please note that confirmation of any additional attendance of the scientific programme, for which you have not submitted an evaluation form during the congress, cannot be claimed at a later date as late requests cannot be processed and can thus not be included in your record of attendance.

### **CME Confirmations**

Every participant will be able to view, download and print his/her personal record of attendance from the ESR website at [www.myESR.org](http://www.myESR.org) (MyUser Area) on the condition that the above mentioned procedures have been accomplished. This service is already available onsite at the numerous computer terminals.

Please note that your PersonalID (former ECRID), printed on your badge, is required for login.

The printout of your record will be recognised by the national accreditation society upon submission.

Please note that the record of attendance will be issued only to the participant. It will not be supplied to any accreditation agency or other organisation/health authority.

After the congress CME certificates will still be available online. To show and print your CME certificates after the congress, please log into the 'MyUser Area' with your last name and PersonalID (former ECRID).

Although participants may partially attend multiple concurrent sessions, the total number of hours printed at the end of the list limits the credit to the equivalent of a single session during that time slot.

For further information, please contact: ECR CME Support at [cme@myESR.org](mailto:cme@myESR.org).

Following a well-liked tradition, ECR/ESR welcomes its 'ESR meets' guest countries for 2008 – namely Germany, Israel and India – for which there will be special scientific focus activities as listed below. In addition, ECR 2008 introduces a new feature, where there will also be special activities focussing on various partner disciplines, this year the General Practitioners, which will provide a platform to establish closer ties.



## ESR meets Germany

**Saturday, March 8, 10:30–12:00, Room A**

### EM 1 **Computer aided diagnosis (CAD)**

Presiding: *A. Adam; London/UK*  
*M. Laniado; Dresden/DE*  
*M.F. Reiser; Munich/DE*

- **Introduction** (A-130)  
*M. Laniado; Dresden/DE*
- **CAD in mammography** (A-131)  
*U. Bick; Berlin/DE*
- **CAD of the lungs: Pulmonary nodules and beyond** (A-132)  
*H.-U. Kauczor; Heidelberg/DE*
- **CAD in virtual colonography** (A-133)  
*A.J. Aschoff; Ulm/DE*
- **CAD of the liver: Imaging and intervention** (A-134)  
*H.-O. Peitgen; Bremen/DE*
- **Panel discussion**



## ESR meets Israel


**Sunday, March 9, 10:30–12:00, Room A**

### EM 3 **Views and impressions from radiology in Israel**

Presiding: *A. Adam; London/UK*  
*M. Graif; Tel Aviv/IL*  
*M.F. Reiser; Munich/DE*

- **Introduction** (A-240)  
*M. Graif; Tel Aviv/IL*
- **The hi-tech environment in Israel: Contribution of the radiological community to projects in medical imaging** (A-241)  
*Y. Inbar; Tel Hashomer/IL*  
*T. Gaspar; Haifa/IL*
- **Patterns of CT utilisation in emergency medicine: From the single patient to mass casualties** (A-242)  
*A. Blachar; Tel Aviv/IL*  
*A. Engel; Haifa/IL*
- **Large scale radiological projects and surveys: Local data and comparison with international database** (A-243)  
*D. Shaham; Jerusalem/IL*  
*J. Sosna; Jerusalem/IL*
- **Panel discussion**

# להתראות ביניה!



Please visit the Special Welcome Desk for delegates from Israel, India and Germany in the entrance hall



## ESR meets India

Monday, March 10, 14:00–15:30, Room A

### EM 4

#### Tuberculosis

Presiding: A. Adam; London/UK  
N. Kulasekaran; Chennai/IN  
M.F. Reiser; Munich/DE

- **Introduction** (A-340)  
*H. Satishchandra; Bangalore/IN*
- **Unusual appearances of intracranial tubercular infection** (A-341)  
*D.P. Patkar; Mumbai/IN*
- **Spinal tuberculosis revisited** (A-342)  
*R. Kapur; New Delhi/IN*
- **Ultrasound features in peritoneal and intestinal tuberculosis** (A-343)  
*S.S. Doda; New Delhi/IN*
- **Chest tuberculosis: Atypical radiological appearances** (A-344)  
*P.R. Kundur; Hyderabad/IN*
- **Panel discussion**

वियना में आपका स्वागत है!

## ESR meets General Practitioners

Saturday, March 8, 16:00–17:30, Room C

### EM 2

#### Manifestations of atherosclerosis: A common challenge in diagnosis and treatment

Presiding: A. Adam; London/UK  
M.F. Reiser; Munich/DE  
I. Švab; Ljubljana/SI

- **Introduction** (A-149)  
*M.F. Reiser; Munich/DE  
I. Švab; Ljubljana/SI*
- **Assessment of coronary artery disease** (A-150 – A-151)  
*General practitioner: C. Lionis; Iraklion/GR  
Radiologist: N.R. Mollet; Rotterdam/NL*
- **Patients with peripheral arterial obstructive disease (PAOD) in primary care** (A-152 – A-153)  
*General practitioner: M. Maier; Vienna/AT  
Radiologist: M. Treitl; Munich/DE*
- **Panel discussion**

# EDIPS



ECR Digital Preview System

## DOWNLOAD

### EDIPS – ECR Digital Preview System

EDIPS Download is part of ECR's Digital Preview System. It enables you to download presentations from ECR 2006, 2007 and 2008 throughout the year.

As an ESR member enjoy browsing for free through over 1,099 presentations covering a wide variety of radiological topics, and provided by the most esteemed scientists from all over the world.

# e-ECR



Electronic European Congress of Radiology

### eECR – Electronic European Congress of Radiology

ECR's electronic congress tool eECR brings a selection of scientific highlights of ECR right to your home. View and listen to talks from ECR 2004, 2005, 2006 and 2007 as well as presentations from ESGAR and ESMRMB (in total over 300).

#### Experience

- 'ECR meets' Sessions
- Categorical Courses
- Foundation Courses
- Interactive Image Teaching Sessions
- Special Focus Sessions
- New Horizons Sessions
- Refresher Courses
- State-of-the-Art Symposia
- Image Interpretation Quizzes
- Junior Image Interpretation Quizzes
- Satellite Symposia
- Hospital Administrator Symposia Presentations

Search the database easily by topic, title or keywords. eECR holds something for everyone and can be accessed free of charge by ESR members.

# ePACS

PACS-supported radiological report training

### ePACS – A New Method of Learning

**Study images in DICOM, learn to diagnose and to report**

**Coordinators:** *D. Caramella; Pisa/IT*  
*P. Pokieser; Vienna/AT*

At ECR 2008, ePACS is being relaunched with more than 100 new cases out of the special topics

'Cardiac CT' and 'Acute Abdomen'. ePACS, a new e-learning tool for radiological training, will be available on more than 100 workstations at the same time.

ePACS offers a new method of learning on the basis of original radiological reports, with either self directed or guided training in an emulated radiological working environment, using a modified web based PACS-system. Attendees will study images in DICOM quality, and will learn how to diagnose and draw up written results. At the end of each teaching file, an expert report will be provided. Participants will have the option to obtain a diploma by using the supplied self assessment module.



# EPOSE

Electronic Presentation Online System

## **EPOSTM – Electronic Presentation Online System**

EPOSTM – almost 8,000 electronic presentations currently online!

Some years ago, ECR took a bold step and introduced an all-electronic scientific exhibition using EPOSTM, the Electronic Presentation Online System,

thus setting new standards in the medical meeting industry.

At ECR 2008, the electronic scientific exhibition continues its path of success under EPOSTM. 944 scientific and educational exhibits, 14 presentations by invited lecturers and 68 paper presentations will be displayed on more than 100 terminals.

Browse through more than 8,000 electronic exhibits from ECR 2003–2008 and from several subspecialty societies, including CIRSE, ESGAR, ESMRMB, ESCR, ESSR, and SIR.

The online EPOSTM database can be accessed free of charge by ESR members.

# EURO RAD

Radiological Case Database

## **EURORAD – Radiological Case Database**

The largest peer-reviewed teaching database of radiology on the internet offers ESR members free access to a wealth of medical information and imaging data, whose accuracy and quality have been validated by some of the most experienced radiolo-

gists in Europe. EURORAD contains case reports for medical students (simple cases), residents in radiology (everyday cases) and senior radiologists (complex cases).

For easy retrieval of required cases, the website offers a new powerful search engine as well as multi-lingual navigation. EURORAD allows you to download, save, and print the cases as PDF documents, or e-mail them via the web-based e-mail client. All EURORAD cases are registered with a DOI (Digital Object Identifier), which makes all cases citable.

## ESR Electronic Congress – it's that simple!

The European Society of Radiology is proud to introduce a new service to all its members – the ESR Electronic Congress. It's never been so easy to check out all ESR online services at once!

The ESR Electronic Congress comprises over 11,750 abstracts, over 1,060 PowerPoint™ presentations to download, over 280 recorded lectures and webcasts, and last but not least, over 3,740 electronic exhibits. For only €10 a year, state-of-the-art knowledge and expertise is now accessible to all ESR members.

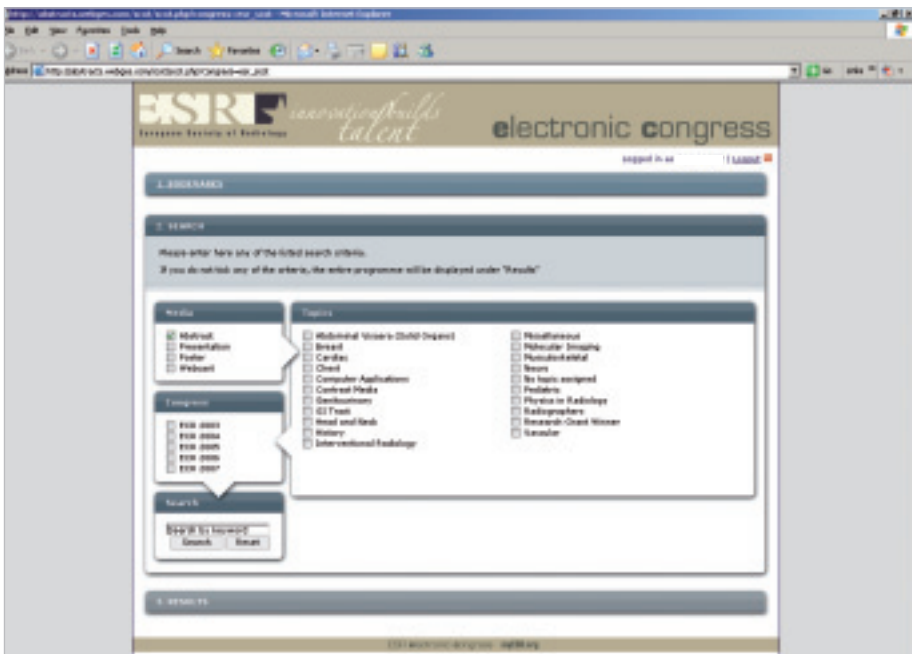It's never been simpler. Once you've received your ID, you simply log on to the website and you can choose your desired media, topic of interest and the relevant congress. Our unique Meta data Search offers a total overview in just one click.

We all know how busy congresses can get and sometimes you don't get to attend all the lectures you would like to see. Members can now print or download the abstracts, scientific exhibits and lectures they're interested in and read them whenever they have time.

Your own secure area in the Electronic Congress also contains a bookmark section. There you will find your bookmarked sessions and lectures. This allows you to create your own archive without going through the entire programme every time you wish to find something. Simply browse through the programme and tick the sessions you wish to bookmark.

In other words, the ESR Electronic Congress provides you with all the scientific knowledge of every ECR since 2003 in a nutshell.

## electronic congress





# IMAGINE

## **Back for good – IMAGINE at ECR 2008**

The enormous success at ECR 2007 proved that it was the right decision to re-establish a most popular feature of the congress – IMAGINE, the high-tech specialty exhibit. It was thus confirmed that an exhibition of this quality and particular content certainly contributes to ECR's reputation as one of the world's outstanding conferences regarding advanced technology in radiology.

As before, the main aim of IMAGINE in 2008 will be to provide a platform at ECR to show new technological developments in the field of diagnostic and interventional radiology. In contrast to the technical exhibition, which shows currently available products, IMAGINE will focus on research and give a preview of future evolution and trends. IMAGINE aspires to function as an 'antenna' for developments soon to come but not yet on the market.


The focus will be on CAD, Interactive Visualization, Image Guided Interventions & Robotics, and Computer-Based Training.

The location on the second floor of the congress venue, in Foyer A, is ideally suited for the presentation of IMAGINE, as it will provide sufficient space for all groups and for discussions in front of the booths. It will therefore help to intensify cooperation and further contact between individuals, institutes and universities, thus adding to ECR's status as the perfect meeting place for all those who want to be part of the future of imaging.

### **Opening hours:**

Friday, March 7  
12:00–17:00

Saturday, March 8 to Monday, March 10  
10:00–17:00



## Plenary Sessions

**Friday, March 7**  
**12:15–13:30, Room A**

### Opening Ceremony

Musical performance by Mnozil Brass

### Welcome Addresses

*Andy Adam; London/UK*  
ESR President

*Maximilian F. Reiser; Munich/DE*  
Congress President ECR 2008

### Presentation of ESR Honorary Membership to

*R. Gilbert Jost; St. Louis, MO/US*  
*Frederick S. Keller; Portland, OR/US*  
*Lizbeth M. Kenny; Brisbane, QLD/AU*

### Presentation of the ESR Gold Medal Award to

*Nicholas Gourtsyannis; Iraklion/GR*

**17:45–19:15, Room A**

### Presentation of ESR Lifetime Achievement Award to

*Albert L. Baert; Leuven/BE*

### Inaugural Lecture

**'Images in the brain – pictures in the eyes'**

*Ernst Pöppel; Munich/DE*

### ECR Opening Concert

Dorretta Carter & Band





**Saturday, March 8**  
**12:15–12:45, Room B**

**Wilhelm Conrad Röntgen – Honorary Lecture**  
**'Pushing the speed limits in MR imaging'**  
*Jürgen Hennig; Freiburg/DE*

**Sunday, March 9**  
**12:15–12:45, Room B**

**Josef Lissner – Honorary Lecture**  
**'The coming of age of imaging in biomedical research'**  
*James H. Thrall; Boston, MA/US*

**14:00–15:30, Room A**

**Image Interpretation Quiz 'The battle of the sexes'**

**Moderator:**  
*Anthony Watkinson; Exeter/UK*

**Panellists:**  
Ladies:  
*Laura Crocetti; Pisa/IT*  
*Martina M. Morrin; Dublin/IE*  
*Claudia Schüller-Weidekamm; Vienna/AT*  
*Anne Tardivon; Paris/FR*

Gentlemen:  
*Mario Bezzi; Rome/IT*  
*Afshin Gangi; Strasbourg/FR*  
*Tomasz Jargiello; Lublin/PL*  
*Giles Maskell; Truro/UK*

**Monday, March 10**  
**12:15–12:45, Room B**

**Peter E. Peters – Honorary Lecture**  
**'New paradigms in breast imaging'**  
*Christiane K. Kuhl; Bonn/DE*

**Tuesday, March 11**  
**12:15–13:30, Room A**

**Junior Image Interpretation Quiz 'Europe vs India'**

**Moderator:**  
*Henrik J. Michaely; Mannheim/DE*

**Panellists:**  
Europe:  
*Valentina Battaglia; Pisa/IT*  
*Ali Devrim Karaosmanoglu; Ankara/IT*  
*Derek G. Lohan; Galway/IE*  
India:  
*Amarnath Chellathurai; Chennai/IN*  
*Harsh Kandpal; New Delhi/IN*  
*Bathala Tharakeswara Kumar; Bangalore/IN*

**Closing Ceremony**

**Concluding Remarks**  
*Maximilian F. Reiser; Munich/DE*  
Congress President ECR 2008

*Andy Adam; London/UK*  
Outgoing ESR President

**Address by the Incoming ESR President**

**Address by the Congress President ECR 2009**  
*Borut Marincek; Zurich/CH*

## Image Interpretation Quizzes

The Image Interpretation sessions, two traditional highlights of every ECR, provide both education and entertainment. Two panels of distinguished radiologists will share their knowledge and diagnosis strategies with you.

In the 'senior' quiz, four ladies and four gentlemen will challenge each other in an enjoyable and exciting competition where they will face tricky cases, which will be shown to them only one day before the show. The moderator will guide them, while a charming young lady will keep track of the scores.

The 'juniors' slogan is 'Europe vs India'. The panelists will be confronted with their cases just one hour before the session, which will raise the suspense even more, and the moderator will guarantee a scientifically challenging and entertaining session.

**Sunday, March 9, 14:00–15:30, Room A**

### Image Interpretation Quiz: The battle of the sexes

**Moderator:**

*A. Watkinson; Exeter/UK*

**Panelists:**

Ladies:

*L. Crocetti; Pisa/IT*

*M.M. Morrin; Dublin/IE*

*C. Schüller-Weidekamm; Vienna/AT*

*A. Tardivon; Paris/FR*

Gentlemen:

*M. Bezzi; Rome/IT*

*A. Gangi; Strasbourg/FR*

*T. Jargiello; Lublin/PL*

*G. Maskell, Truro/UK*

**Tuesday, March 11, 12:15–13:15, Room A**

### Junior Image Interpretation Quiz: Europe vs India

**Moderator:**

*H.J. Michaely; Mannheim/DE*

**Panelists:**

Europe:

*V. Battaglia; Pisa/IT*

*A.D. Karaosmanoglu; Ankara/IT*

*D.G. Lohan; Galway/IE*

India:

*A. Chellathurai; Chennai/IN*

*H. Kandpal; New Delhi; IN*

*B.T. Kumar; Bangalore; IN*

# HOSPITAL MANAGEMENT SYMPOSIUM AT ECR 2008

## Management, IT and Finance for Hospitals and Radiologists

March 8, 08:30–13:30, Room K

Presented and organised by: **ECR 2008**  
European Congress of Radiology  
March 7–11, Vienna / Austria



Moderation by Prof. Christian Köck, M.D., Sc.D., Health Care Company AG, Austria

### Programme

#### • Welcome address

**08:30–08:40**

Welcome address and introduction by Professor Maximilian F. Reiser, ECR 2008 Congress President

### Management

**08:40–10:15**

• **The management of innovation and efficiency: How to inspire creativity while assuming productivity**  
Britta Fünfstück; Head of Business Development/Strategy, Siemens Healthcare, Erlangen, Germany

• **Strategic partnerships in the healthcare market**

Harald W. Bacheitner; Consultant, Managing Director, bacheitner contract gmbh, Hamburg, Germany

• **How to manage medical services in the Russian healthcare system**

Prof. Dr. Eugene Vladimirovich Shlyakhto; Director of the Almazov center for heart, blood and endocrinology, chief cardiologist of the Healthcare Ministry of the north-western federal region in Russia and member of the Russian Academy for Medical Sciences, St. Petersburg, Russia

• **Applying manufacturing models to the radiology subsystem of the inpatient hospitalisation process**

Marty Bledsoe; Chief Administrator of the Russell H. Morgan Department of Radiology and Radiological Science at Johns Hopkins Medicine, Baltimore, Maryland, United States.

### Information Technology

**10:15–11:50**

• **Outsourcing as part of hospital IT optimisation: Doing it the right way!**

Dr. Thomas Geisinger; Global Manager for E-Health integration at Agfa HealthCare, Bonn, Germany

• **Using a single HIS and PACS platform for patient medical data sharing between different healthcare providers**

Dr. Peeter Ross; Director of Research and Development, East Tallinn Central Hospital, Tallinn, Estonia

• **Managed services in patient data archiving: The impact on IT, finance and physicians**

Pierre-Yves Nectoux; eHealth Managed Services European Business Manager, Carestream Health, Toulouse, France

• **The Finnish patient data archive: Countrywide data and resource sharing to save money for hospitals**

Dr. tech. Hanna Pohjonen; Consultant in healthcare information systems & networks, e-health, Espoo, Finland

### Finance

**11:50–13:30**

• **The future of hospital financing in Germany**

Jürgen Abshoff; Economist and Consultant for hospitals, founder and member of the 'Association for Quality Management in Hamburg Hospitals (EQS)' and Member of Advisory Council, Congress for the German healthcare industry, Hamburg, Germany

• **How to afford and keep pace of top-notch technology without going broke**

Eric-Jan Ruten; General Manager, Professional Healthcare Solutions, Philips Healthcare International, Eindhoven, The Netherlands

• **International healthcare systems – a comparative study**

Dr. Alex M. Blaicher, Director Landeskrankenhaus Vöcklabruck, Austria

• **Hospital financing based on business plans:**

**The launch planning of a hospital begins the same day its construction ends**

Luis Barcia Albarca; General Manager of the Hospital Torrevieja Salud, Torrevieja, Spain

## EPOS™ – Scientific Exhibition

### Opening Hours:

Friday, March 7 to Monday, March 10:

07:00–19:00

Tuesday, March 11:

07:00–14:00

### Location:

2<sup>nd</sup> level/Foyer A

The EPOS™ staff will be glad to assist you during these times.

### Note:

On Saturday, March 8, 12:15–13:15, EPOS™ will be closed for a self assessment test for the participants of the foundation course on interventional radiology.

### What's New in EPOS™ (ECR's Electronic Presentation System) at ECR 2008?

- 944 electronic exhibits:
- 458 educational and 486 scientific exhibits
- 14 invited lectures
- 68 scientific papers
- 20 Cases-of-the-Day (five new cases each day)
- Self-Assessment: Interventional Radiology
- ePACS
- EURORAD – Radiological Case Database

### Scientific Exhibition Awards

An independent jury consisting of 114 European radiologists has judged all scientific and educational exhibits with regard to their scientific content, educational value, originality and visual impression. Taking advantage of EPOS™, the rating was carried-out online, prior to the congress, enabling a detailed and considered assessment. On this basis, the scientific exhibition committee has awarded prizes to the best posters, as follows:

Magna Cum Laude (6)

Cum Laude (10)

Certificate of Merit (15)

Each of the Magna Cum Laude winners will be presented with a monetary prize (€ 1,500) and a certificate. Winners of the Cum Laude and Certificate of Merit award will get a certificate and a small gift, which can be picked up at the EPOS™ Office.

All awarded posters are flagged in EPOS™ and will be published on the ESR website. ECR 2009 registration fees will be waived for presenters of Magna Cum Laude awarded posters.

### Attendance and Evaluation

of the scientific exhibition are recorded online in EPOS™:

1. Enter EPOS™ and view the posters of your interest. If you logout EPOS™, you will be asked to complete the evaluation form.
2. Fill in this form completely and press the 'Submit' button.

The evaluation of the electronic scientific exhibition is very important for future planning.

Your opinion and comments will be highly appreciated.

For those who login and who submit completed evaluation forms, a maximum of 3 hours attendance at the scientific exhibition will be listed in the record of attendance.

**EPOS™ at ECR 2008 is kindly sponsored by Siemens.**

**SIEMENS**



We cordially thank the members of the **Scientific Exhibition Jury** who were ready to review and grade the electronic posters online via EPOS™ from February 8 to 15, 2008, establishing the basis for assigning the awards.

**Abdominal Viscera (Solid Organs)**

D. Akata; Ankara/TR  
A. Denys; Lausanne/CH  
A. Lewszuk; Bialystok/PL  
D.E. Malone; Dublin/IE  
E. Neri; Pisa/IT  
P.K. Prassopoulos;  
Alexandroupolis/GR  
D. Vanbeckevoort; Leuven/BE  
V. Vilgrain; Clichy/FR  
C.J. Zech; Munich/DE

**Breast**

P.B. Dean; Turku/FI  
F. Diekmann; Berlin/DE  
G. Forrai; Budapest/HU  
A.A. Ghiatas; Athens/GR  
A. Olivier; Paris/FR  
P. Skaane; Oslo/NO

**Cardiac**

E.E.J.G. Coche; Brussels/BE  
M. Gardarsdottir; Reykjavik/IS  
M. Gutberlet; Berlin/DE  
G. Hadjidekov; Sofia/BG  
K. Hergan; Salzburg/AT  
I. Mastorakou; Athens/GR  
D. Stukalova; Moscow/RU  
S. Wildermuth; St. Gallen/CH

**Chest**

M. Ariyürek; Ankara/TR  
G. Gavelli; Bologna/IT  
B. Ghaye; Liège/BE  
J. Im; Seoul/KR  
K. Lehmann; Karlsruhe/DE  
J. Neuwirth; Prague/CZ  
C. Trinidad; Vigo/ES  
G.A. Wegenius; Uppsala/SE

**Computer Applications**

D.J. Allison; New Malden/UK  
F. Barneveld Binkhuysen; Soest/NL  
C. Capotondi; Rome/IT

**Genitourinary**

B. Brkijacic; Zagreb/HR  
T. El Diasty; Mansoura/EG  
R. García Figueiras;  
Santiago de Compostela/ES

K. Karlinger; Budapest/HU  
Z. Markovic; Belgrade/RS  
U.G. Mueller-Lisse; Munich/DE  
L.H. Ros Mendoza; Zaragoza/ES  
A. Tsili; Ioannina/GR  
A. Zubarev; Moscow/RU

**GI Tract**

G.J. Antes; Kempten/DE  
C.I. Bartram; London/UK  
B.I. Choi; Seoul/KR  
F.-T. Fork; Malmö/SE  
A. Ginai; Rotterdam/NL  
G. Karmazanovsky; Moscow/RU  
U. Korman; Istanbul/TR  
S. Schmidt; Lausanne/CH  
C. Tsampoulas; Ioannina/GR

**Head and Neck**

E. Ada; Izmir/TR  
E.J. Adam; London/UK  
F. Dubrulle; Lille/FR  
S. Dzelzite; Riga/LV  
H.B. Eggesbø; Oslo/NO  
R. Klingebiel; Berlin/DE

**Interventional Radiology**

D. Akinci; Ankara/TR  
M. Bezzi; Rome/IT  
K.A. Hausegger; Klagenfurt/AT  
J.S. Laméris; Amsterdam/NL  
A. Lubienski; Lübeck/DE  
G. Maleux; Leuven/BE  
J.H. Peregrin; Prague/CZ  
T. Roeren; Aarau/CH  
M. Szajner; Lublin/PL

**Molecular Imaging and Contrast Media**

C.A. Cuénod; Paris/FR  
J.Á. Jakobsen; Oslo/NO  
G. Morana; Treviso/IT

**Musculoskeletal**

R. Dominguez; Barcelona/ES  
B. Forgács; Rotherham/UK  
A. Karpenko; St. Petersburg/RU  
C. Masciocchi; L'Aquila/IT  
S. Pans; Leuven/BE  
W.C.G. Peh; Singapore/Singapore

D. Tervonen; Oulu/FI  
M. Uhl; Freiburg/DE  
D.J. Wilson; Oxford/UK

**Neuro**

L. Cyrylowski; Szczecin/PL  
A. Drevelegas; Thessaloniki/GR  
K. Koprivsek;  
Sremska Kamenica/RS  
M. Leonardi; Bologna/IT  
R.A. Meuli; Lausanne/CH  
C. Oppenheim; Paris/FR  
A. Rovira-Cañellas; Barcelona/ES  
I. Saatci; Ankara/TR  
A. Server Alonso; Oslo/NO  
I. Szikora; Budapest/HU  
L. van den Hauwe; Brasschaat/BE  
B. Verbist; Leiden/NL

**Pediatric**

V. Donoghue; Dublin/IE  
R. Fotter; Graz/AT  
E. Kis; Budapest/HU  
C. Martinoli; Genoa/IT  
B. Smevik; Oslo/NO  
A.P. Wieczorek; Lublin/PL

**Physics in Radiology**

M. Gambaccini; Ferrara/IT  
K. Kepler; Tartu/EE  
A. Noel;  
Vandoeuvre-les-Nancy/FR  
H.-P. Schlemmer; Tübingen/DE  
M. Torres-Tabanera; Madrid/ES  
F.R. Verdun; Lausanne/CH

**Radiographers**

K. Eklund; Lund/SE  
G. Robertsen; Trondheim/NO  
A.M.K. Thomas; Orpington/UK

**Vascular**

M. Čejna; Feldkirch/AT  
P.C. Douek; Lyon/FR  
J. Rose; Newcastle upon Tyne/UK  
R. Szentgyörgyi; Krems/AT  
A. Waaijer; Utrecht/NL  
J.E. Wildberger; Berlin/DE

## ESR Job Forum – the most effective way to connect job-seekers and employers in radiology

The European Society of Radiology is always looking for new ways to benefit the radiological community, and is proud to announce its latest innovation – the ESR Job Forum. This platform brings together prospective employers and employees from all over the world, in the field of radiology and related disciplines. Whether you are a job seeker from Italy looking for a position in Germany or you are an employer in China searching for the ideal candidate, the ESR Job Forum is your perfect resource as it connects people from all around the globe.

The ESR Job Forum was introduced in autumn 2007 and is still in its early stages, so we kindly invite you to actively support our service by using it and spreading the idea among your colleagues so that its full potential can be fulfilled, to your advantage!

Visit the ESR Job Forum onsite at the Austria Center Vienna, 1<sup>st</sup> level or at [www.myESR.org/jobforum](http://www.myESR.org/jobforum). Post your vacant position or your profile today to find your ideal job-connection!



Innovation builds talent

The **ESR Job Forum** connects job seekers and employers in radiology.

Enjoy another valuable benefit of your **ESR Membership!**



New job?

myESR.org/jobforum



## **ECR 2008 welcomes you to 'ECR City'!**

### **ECR spreads out to 'ECR City'**

After tremendous enlargement of the technical exhibition space for ECR 2007, we are proud to announce a new total area of 26,000m<sup>2</sup> for ECR 2008, due to further increased demand. We are delighted with this enormous level of interest and welcome all our long-standing industry partners, as well as newcomers, to ECR 2008.



After months of substantial changes and refurbishments at the Austria Center Vienna, participants can now enjoy an even more attractive congress, especially in the TechGate, which will host the hands-on workshops of Philips Healthcare and Carestream Health. As registration may be required for these workshops, please visit their main booths in the technical exhibition halls.



Further attractions include various workshops being held at the Siemens Hands-on Workshop Hall, and an OsiriX User Meeting, organised by Apple, which will take place at the Austria Center Vienna – please note that registration is necessary.

### **ESR welcomes its Supporting Members**

ESR gives a warm welcome to all its supporting member companies! They contribute to the success of the society and its congress with their continuous support for the cause of radiology in Europe. Along with Agfa, Bracco, Carestream Health, GE Healthcare, Hitachi, Philips Healthcare and Siemens Medical Systems (all four-star supporting members), Vital Images, Shimadzu and Az Corp. confirmed their two-star supporting membership in autumn 2007. Thank you!



### **'ESR meets' countries**

Already kind of a tradition, ECR places a special focus on its 'ESR meets' countries – in 2008 namely Germany, India and Israel – with particular emphasis on their scientific and technological developments. ESR, industry companies and the national societies work closely together to highlight these countries, and ESR was present with a booth promoting ECR 2008 at each of their national congresses. We herewith invite you to visit the society booths of our 'ESR meets' countries, Germany, India and Israel, which you can find easily in the entrance hall.



## Food & Drink at ECR 2008

Looking for the right place to eat? – Find tasty Austrian as well as international cuisine in four different restaurants: the two restaurants in the Austria Center Vienna (buffet lunch and live cooking), or the two new special eateries within ‘ECR City’ – the stylish Saturn Lounge in Saturn Tower and the Avocado restaurant in Ares Tower. Guten Appetit!

### Restaurant in the Austria Center Vienna

#### (Foyer F, OE):

11:30–14:30 (March 7–10) – live cooking

### Restaurant in the Austria Center Vienna

#### (Foyer C, O2):

11:30–14:30 (March 7–10) – buffet lunch and live cooking (to be seated)

### Avocado (Ares Tower):

weekdays 08:00–19:00, weekend 11:00–18:00

### Saturn Lounge (Saturn Tower):

weekdays 08:00–19:00, weekend 08:00–15:00

If you prefer a short coffee-break or snacks, please visit the various foyer cafés and coffee shops throughout the congress venue:

Entrance level (next to the main entrance and Foyer E), 1<sup>st</sup> level, 2<sup>nd</sup> level (Foyer A and B), Extension Expo A, Expo C, D and E, lower level (Foyer D).



### Restaurants in the Austria Center Vienna

#### (Foyer C, O2, Foyer F, OE)

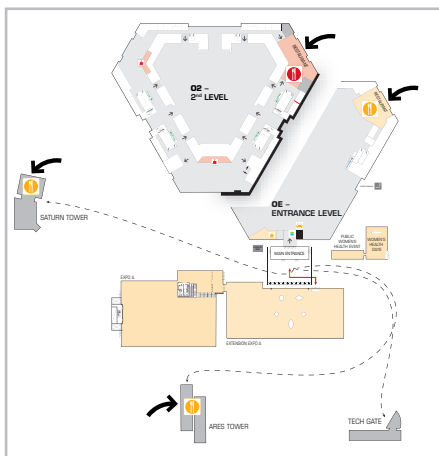
11:30–14:30 (March 7–10)



### Avocado

#### (Ares Tower)

weekdays 08:00–19:00, weekend 11:00–18:00



### Saturn Lounge

#### (Saturn Tower)

weekdays 08:00–19:00, weekend 08:00–15:00





## **Pick up your free copies of radiology journals and magazines ...**

### **Free access to online radiology journals ...**

Encouraged by the successful introduction of this special feature last year, we are proud to extend the project and present the FREE PUBLICATIONS booth again at this year's meeting. This new form of cooperation with our partners at publishing houses and medical journals was remarkably well received by visitors to ECR 2007.


The dedicated Free Publications booth, which has been specially designed to display both print publications and online media in the most effective way, is located on the first floor of the congress venue. More than 35 publishers have joined this initiative up to now presenting almost 60 print media and more than 50 online journals. Our partners include top publishing houses such as Springer and Elsevier as well as smaller or previously lesser known publishers from all over the world.

For the convenience of congress participants, we have also set up electronic terminals around this booth, dedicated to online media. By simply clicking the banner of the relevant journal on the terminal, delegates can browse through the selected publication.

Furthermore, dedicated ECR staff will not only distribute the journals and magazines, but will also be at the delegates' disposal to provide detailed information and any assistance that might be needed.

If you are interested in more journals than you can carry, just make use of the free bags provided at the booth!


Enjoy another valuable service at ECR!



- The only scientific journal for **€10 – online**
- The only scientific journal for **€70 – in print**



**No European  
Radiology ?  
No thanks!**



## **European Radiology** The official journal of ESR

Since its foundation by Prof. J. Lissner in 1991, *European Radiology*, the official journal of ESR, has grown rapidly and considerably. Our journal has become highly regarded in the imaging field, thanks to the enormous commitment of outgoing Editor-in-Chief Prof. Dr. Albert L. Baert, and I hope that this fantastic progress will continue in 2008.

The clearest indicator of *European Radiology's* growth is the ISI Impact Factor 2006, released in June 2007, which now places the journal 22<sup>nd</sup> out of 85 titles in the overall imaging field, with an IF of 2.554, signifying a further increase since 2005 (2.437/rank 24 out of 84) and making it the second highest ranked truly general radiological journal.

Manuscript submission also reached new heights during 2007, with 391 of 1,231 submitted manuscripts published over a total of 3,262 pages. With further reduction of the peer-review time period, and of the interval between manuscript acceptance and online publication, this means *European Radiology* now presents important radiological findings to the reader faster than ever. All of these encouraging developments will give our new editorial team plenty to consider, as we attempt to maintain the high level of quality that *European Radiology* is now renowned for.

The year marked a revolutionary change in the circulation rate, as all ESR members (around 30,000!) can now gain electronic access to *European Radiology* as part of their basic membership fee of €10. Such instantaneous access to the journal is a real benefit, but a full subscription to the paper copy can also be included in the ESR membership package for a mere €70; remarkably good value compared to other radiological journals.

You will of course be able to arrange your subscription to *European Radiology* in person at ECR, by visiting the ESR Booth in the entrance hall. The journal's presence at the congress will also extend to numerous editorial meetings, as well as the presentation of awards for the most cited paper and Interpretation Corner. Another key point of the congress will be the extremely well-deserved 'Lifetime Achievement Award' that will be presented to the previous editor, Prof. Dr. Albert L. Baert, on Friday, March 7, during the Opening Ceremony.

Adrian K. Dixon  
Editor-in-Chief

# European Radiology

**ESOR 2008**  
European School of Radiology

*Education in  
partnership*

[myESR.org/esor](http://myESR.org/esor)

## **GALEN Foundation Courses**

### **Visiting School**

**Abdominal/Genito-Urinary Radiology**  
Alexandroupolis/GR, May 16–18, 2008

**Neuro/Musculoskeletal Radiology**  
Lublin/PL, June 27–29, 2008

**Paediatric Radiology**  
Prague/CZ, September 5–7, 2008

**Oncologic Imaging**  
Bucharest/RO, October 17–19, 2008

**Chest/Cardiovascular Radiology**  
Budapest/HU, October 31– November 2, 2008

An ESR initiative, in co-operation  
with GE Healthcare Medical Diagnostics South Central Europe  
GE Healthcare



Visit us at the **ESOR booth in the entrance hall of the Austria Center**  
or online at [www.myESR.org/esor](http://www.myESR.org/esor).

**ESOR 2008**  
European School of Radiology

*Education in  
partnership*

[myESR.org/esor](http://myESR.org/esor)

**GALEN**  
**Advanced Courses**

**Visiting School**

**Cardiac Cross-Sectional Imaging**  
Rome/IT, June 20–21, 2008

**Women's Cross-Sectional Imaging**  
Berlin/DE, July 4–5, 2008

**Abdominal Cross-Sectional Imaging**  
Stockholm/SE, October 10–11, 2008

**Musculoskeletal Cross-Sectional Imaging**  
Amsterdam/NL, November 7–8, 2008

An ESR initiative, supported by GE Healthcare  
GE Healthcare



Visit us at the **ESOR booth in the entrance hall of the Austria Center**  
or online at [www.myESR.org/esor](http://www.myESR.org/esor).

**ESOR 2008**  
European School of Radiology

*Education in  
partnership*

[myESR.org/esor](http://myESR.org/esor)

**AIMS**  
**Advanced Imaging**  
**Multimodality Seminars**

**Visiting School in China**

Spring Seminars  
**Chest and Musculoskeletal Radiology**

April 10–14, 2008  
**Beijing • Changsha • Dalian**

Summer Seminars  
**Abdominal and Urogenital Radiology**

July 20–24, 2008  
**Shanghai • Hangzhou • Chengdu**

An ESR initiative, in co-operation with the CSR, Chinese Society of Radiology,  
and made possible by an unrestricted grant from Bracco



**CSR**  
Chinese Society of Radiology

Visit us at the **ESOR booth in the entrance hall of the Austria Center**  
or online at [www.myESR.org/esor](http://www.myESR.org/esor).

**ESOR 2008**  
European School of Radiology

*Education in  
partnership*

For more information and  
registration please visit:  
[www.esmrm.org](http://www.esmrm.org)

## **ESMRMB School of MRI**

**Applied MR Techniques, Basic Course**

May 22–24, Basel/CH

**Advanced Neuro Imaging: Diffusion, Perfusion, Spectroscopy**

May 29–31, Bern/CH

**Advanced MR Imaging of the Musculoskeletal System**

July 03–05, Moscow/RU

**Advanced Breast & Pelvis MR Imaging**

September 04–06, Brussels/BE

**Clinical fMRI – Theory and Practice**

September 11–13, Heidelberg/DE

**Advanced MR Imaging of the Abdomen**

September 18–20, Verona/IT

**Advanced Cardiac MR Imaging**

September 25–27, Rome/IT

**Advanced MR Imaging of the Musculoskeletal System**

September 25–27, Vienna/AT

**Applied MR Techniques, Advanced Course**

October 16–18, Leuven/BE

**Advanced Head & Neck MR Imaging**

October 16–18, Prague/CZ

**Advanced MR Imaging in Paediatric Radiology – NEW!**

November 06–08, Brussels/BE

**Advanced MR Imaging of the Vascular System**

November 13–15, Valencia/ES

**ESMRMB**

European Society for Magnetic Resonance in Medicine and Biology

**ESOR 2008**  
European School of Radiology

*Education in  
partnership*

## **Visiting Scholarship Programme**

**Musculoskeletal Radiology**

**Neuroradiology/Head and Neck**

**Urogenital Radiology**

**Breast Imaging**

**Cardiac Imaging**

**Oncologic Imaging**

**MRI Protocols**

**Multidetector CT Protocols**

The visiting scholarship programme is aimed at residents in their 3<sup>rd</sup>, 4<sup>th</sup> or 5<sup>th</sup> year of training. 12 scholarships will be offered in 2008. Successful applicants will be provided with intense modular theoretical and hands-on-training for a period of three months.

An ESR initiative, in co-operation with Bracco



[myESR.org/esor](http://myESR.org/esor)

Visit us at the **ESOR booth in the entrance hall of the Austria Center**  
or online at [www.myESR.org/esor](http://www.myESR.org/esor).



**ESOR 2008**  
European School of Radiology

*Education in  
partnership*

[myESR.org/esor](http://myESR.org/esor)

## **CARDIAC IMAGING** Fellowship Programme

The fellowship programme is aimed at residents in their 4<sup>th</sup> or 5<sup>th</sup> year of training and board-certified radiologists. 10 fellowships will be offered in 2008. Successful applicants will be provided with intense training in cardiac imaging for a period of eight weeks.

An initiative of the ESR, in co-operation with  
the European Society of Cardiac Radiology



Visit us at the **ESOR booth in the entrance hall of the Austria Center**  
or online at [www.myESR.org/esor](http://www.myESR.org/esor).



Join us  
in  
Florence

**CIRSE** foundation

Pre-registration  
available at the  
**CIRSE booth**  
in the  
entrance hall

## ET 2008 | ECIO 2008

European Conference on  
Embolotherapy

European Conference on  
Interventional Oncology

April 9-12  
Florence, Italy

- Hands-on Workshops
- Technical and Clinical Focus Sessions
- Learning Centres
- Industry Symposia

[www.et2008.org](http://www.et2008.org) | [www.ecio2008.org](http://www.ecio2008.org)



## **ECR 2008 Special Exhibition: X-Rays and Society. Perception, Threat, Torture**


A notably popular feature at the European Congress of Radiology is the special exhibition initiated and compiled by Prof. Hermann Vogel from Hamburg, Germany, in cooperation with the Deutsches Röntgenmuseum, which has for years been part of the annual meeting. ECR 2008 is glad and proud that Prof. Vogel will again present his fascinating findings and his very particular view of imaging techniques.

This year's exhibit is entitled X-Rays and Society. Perception, Threat, Torture.

The **perception** of x-rays varies. Time and context are shaping factors. This is recognisable in the use of elements of radiology in advertising. X-rays are considered a **threat** where nuclear energy is concerned; and they can be read as a document, as demonstrated when dealing with **torture**.

Prof. Hermann Vogel is head physician at the Albers-Schönberg-Institute, the department of radiology at St. Georg Hospital in Hamburg. A request for images from amnesty international launched his first exhibition. Today there are four exhibits available, with legends in German, English, French, Polish and Arabic, which have been shown more than 50 times throughout the world.

The new exhibition, which will be shown for the first time at ECR 2008, again features more than 20 posters with partly provocative images. It will be presented on the first level of the congress venue opposite Room R1.









# Welcome to ECR Arts & Culture!

ESR is proud and happy to present to you again an extensive and distinguished cultural programme during your time at ECR 2008.

Vienna fulfils anew its reputation as cultural capital of the world, providing a boundless variety of artistic endeavours. Be it the virtuosity of Vienna's famous orchestras led by the world's leading conductors, the transcendent beauty of the opera, or the sheer abundance of fine arts ranging from ancient Greek sculptures to Baroque paintings, from Art Nouveau furniture to installations representing visionary views of the 21<sup>st</sup> century – there is sure to be found something for every artistic taste.

Visit the **Arts & Culture Booth** in the entrance hall of the congress venue to pick up your brochure with details and information about the cultural programme offered during your stay in Vienna.

**Enjoy your stay in Vienna!**



left page: Pablo Picasso | Woman in a green hat, 1947 © Succession Picasso/VBK Wien, 2007, Albertina, Wien – Dauerleihgabe der Sammlung Batliner  
right page: Oskar Kokoschka | In the garden, 1934 © VBK Wien, 2007, Albertina, Wien – Dauerleihgabe der Sammlung Batliner  
René Magritte | The enchanted domain, 1953 © VBK Wien, 2007, Albertina, Wien – Dauerleihgabe der Sammlung Batliner  
Claude Monet | The water lily pond, around 1919 © VBK Wien, 2007, Albertina, Wien – Dauerleihgabe der Sammlung Batliner

# thinnovation

## thin·no·va·tion™

1. Truly integrated and modular thin client PACS solutions.
2. Blazingly fast 2D, 3D, and 4D performance anywhere, anytime.
3. Scalable architecture providing a wealth of possibilities.
4. Enterprise-wide advanced visualization deployment.
5. Strengthening business through enhanced imaging productivity.

Visit us at ECR  
EXPO C, Booth No. 344



Whether you need a PACS or are unhappy with your current PACS, come visit us at [www.visageimaging.com](http://www.visageimaging.com) to see how Thinnovation™ from Visage Imaging can optimize your PACS performance and workflow.

## Committees & Dignitaries

- 6 Committees
- 8 Subcommittees
- 10 Topic Coordinators
- 11 ESR Dignitaries

## Programme Overviews & Floor Plans

- 24 Programme Overviews
- 34 Floor Plans
- 42 Meeting Rooms
- 45 Metro Map

## ECR Information from A–Z

- 48 ECR Information from A-Z
- 57 EIBIR – European Institute for Biomedical Imaging Research
- 58 CME at ECR 2008
- 60 ESR meets Germany, Israel, India and GPs
- 62 ESR e-Learning for Free
- 64 ESR Electronic Congress
- 65 IMAGINE at ECR 2008
- 66 Plenary Sessions
- 68 Image Interpretation Quizzes
- 69 Hospital Management Symposium
- 70 EPOST™ – Scientific Exhibition
- 72 ESR Job Forum
- 73 Welcome to our Industry Partners
- 74 Food & Drink at ECR 2008
- 75 Free Publications
- 77 European Radiology
- 78 ESOR – European School of Radiology
- 85 Special Exhibition
- 86 Arts & Culture

## Programme by Topics

- 90 New Horizons Sessions**
- 90 State-of-the-Art Symposia**
- 91 Special Focus Sessions**
- 96 Professional Challenges Sessions**
- 97 Categorical Courses**
- 100 Mini Courses**
- 101 Refresher Courses / Scientific Sessions**
- 120 E<sup>3</sup> – European Excellence in Education**
- 123 Radiology Trainees Forum**
- 124 Hands-on Workshops**
- 128 1<sup>st</sup> Workstation Face-Off Session**
- 129 Satellite Symposia**
- 134 Industry Hands-on Workshops**

## Educational & Scientific Programme

- 139 Contents
- 141 Postgraduate Educational Programme
- 268 Scientific Sessions
- 361 Scientific and Educational Exhibits
- 450 List of Authors and Co-authors
- 499 List of Moderators
- 502 Personal Planner

**New Horizons Sessions****Friday, March 7, 08:30–10:00, Room C**

- NH 1**     **MR diffusion and perfusion: Can they replace PET?**  
(A-006 – A-010)
- **Chairman's introduction**  
*M. Essig; Heidelberg/DE*
  - **PET and PET/CT in oncological imaging**  
*H.C. Steinert; Zurich/CH*
  - **Diffusion weighted imaging in the assessment of lymph node metastases**  
*A. Herneth; Vienna/AT*
  - **Perfusion imaging in the assessment of response to anticancer therapy**  
*F. Berger; Munich/DE*
  - **Quantification strategies for perfusion and diffusion MRI**  
*B. Stieltjes; Heidelberg/DE*
  - **Panel discussion: How and when to use MRI instead of PET**

**Saturday, March 8, 08:30–10:00, Room C**

- NH 5**     **The further minimisation of minimally invasive therapy**  
(A-097 – A-100)
- **Chairman's introduction**  
*A. Adam; London/UK*
  - **MR-guided focussed ultrasound therapy**  
*W.M.W. Gedroyc; London/UK*
  - **Interventional radiology in drug delivery and gene therapy**  
*B.J. Wood; Bethesda, MD/US*
  - **Cyberknife: Its potential and its interaction with radiology**  
*A. Muacevic; Munich/DE*
  - **Panel discussion**


**Sunday, March 9, 08:30–10:00, Room C**

- NH 9**     **Above 3T: Clinical tool or toys for the boys?**  
(A-201 – A-204)
- **Chairman's introduction**  
*D.G. Norris; Nijmegen/NL*
  - **New perspectives on extremely high field applications**  
*J. Hennig; Freiburg/DE*
  - **Neuroimaging: Potential clinical benefits**  
*D.P. Auer; Nottingham/UK*
  - **Whole body imaging: A challenge apart**  
*M. Ladd; Essen/DE*
  - **Panel discussion: Acquiring a 7 T system: Are there short term gains or is this a long term investment?**

**State-of-the-Art Symposia****Friday, March 7, 16:00–17:30, Room C**

- SA 4**     **The radiologist as the therapist in liver tumors**  
(A-052 – A-055)
- **Chairman's introduction**  
*R. Lencioni; Pisa/IT*
  - **Transarterial chemoembolisation**  
*T.F. Jakobs; Munich/DE*
  - **Selective internal radiation therapy**  
*J.I. Bilbao; Pamplona/ES*
  - **Radiofrequency ablation and combination therapies**  
*R. Lencioni; Pisa/IT*
  - **Panel discussion: Can interventional radiology replace surgery?**





## Sunday, March 9, 16:00–17:30, Room C

### SA 12

#### **Coronary CTA comes of age: Technical advances, decision modeling and cost effectiveness**

(A-253 – A-256)

- **Chairman's introduction**  
*G.P. Krestin; Rotterdam/NL*
- **What's new in coronary CTA technology**  
*S. Leschka; Zurich/CH*
- **Clinical selection of patients for coronary CTA**  
*S. Achenbach; Erlangen/DE*
- **Economical impact of coronary CTA on patient management**  
*M.G.M. Hunink; Rotterdam/NL*
- **Panel discussion: Who should get a coronary CTA?**

## Monday, March 10, 14:00–15:30, Room C

### SA 15

#### **Small bowel: Old problems, new tricks**

(A-348 – A-351)

- **Chairman's introduction**  
*Y. Menu; Le Kremlin-Bicêtre/FR*
- **Computed tomography: The heavy worker**  
*G.A. Rollandi; Genoa/IT*
- **Magnetic resonance: The ultimate?**  
*N. Gourtsyiannis; Iraklion/GR*
- **Videocapsule and ultrasound: A complementary approach**  
*J.-M. Bruel; Montpellier/FR*
- **Epilogue**

## Special Focus Sessions

### Friday, March 7, 08:30–10:00, Room F2

#### SF 1

#### **Uterine fibroid embolisation – the case for and against: Gynecologist, radiologist, patient**

(A-017 – A-020)

- **Chairman's introduction**  
*A. Nicholson; Leeds/UK*
- **Clinical aspects and treatment options in uterine fibroids**  
*W.M. Ankum; Amsterdam/NL*
- **Technique and results**  
*J.-P. Pelage; Boulogne/FR*
- **Fibroid disease from a patient perspective**  
*V. Norton; Bremen/DE*
- **Panel discussion: How will we be treating fibroids in ten years?**

### Friday, March 7, 16:00–17:30, Room G/H

#### SF 4

#### **Dual source CT/dual energy CT: Doubly informative?**

(A-065 – A-068)

- **Chairman's introduction**  
*W.A. Kalender; Erlangen/DE*
- **Technical considerations**  
*W.A. Kalender; Erlangen/DE*
- **Current applications**  
*T.R. Johnson; Munich/DE*
- **Future applications**  
*I. Vlahos; New York, NY/US*
- **Panel discussion: How much more information do we get?**

**Saturday, March 8, 08:30–10:00, Room F2**

- SF 5a Nephrogenic systemic fibrosis: Current situation and future direction** (A-106 – A-110)
- **Chairman's introduction**  
*B. Hamm; Berlin/DE*
  - **What is it, and where does it come from?**  
*S.E. Cowper; New Haven, CT/US*
  - **Fundamental mechanisms and their implications on clinical practice**  
*P. Persson; Berlin/DE*
  - **Clinical prevalence and risk factors**  
*H.S. Thomsen; Herlev/DK*
  - **How to avoid NSF in the future**  
*S.K. Morcos; Sheffield/UK*
  - **Panel discussion: Future aspects**

**Saturday, March 8, 08:30–10:00, Room L/M**


- SF 5b Comprehensive evaluation of the heart** (A-114 – A-117)
- **Chairman's introduction**  
*B. Marincek; Zurich/CH*
  - **What does MDCT offer?**  
*H. Alkadhi; Zurich/CH*
  - **What does MRI offer?**  
*M. Gutberlet; Leipzig/DE*
  - **Integrating MDCT and MRI in the work-up of heart disease**  
*V.E. Sinitsyn; Moscow/RU*
  - **Panel discussion: One-stop shopping with cardiac imaging: CT or MRI?**

**Saturday, March 8, 16:00–17:30, Room L/M**

- SF 8a Fat radiology: Imaging in obesity and metabolic syndrome** (A-174 – A-177)
- **Chairman's introduction**  
*W. Torreggiani; Dublin/IE*
  - **The implications of obese patients for radiologists and clinicians**  
*O. Buckley; Dublin/IE*
  - **Optimising imaging obese patients**  
*A.G. Ryan; Waterford City/IE*
  - **Imaging of morbid obesity procedures and their complications**  
*S.W. Trenkner; Rochester, MN/US*
  - **Panel discussion: Are we doing enough to optimise imaging of the obese patient?**

**Saturday, March 8, 16:00–17:30, Room Z**

- SF 8b Novel image analysis and modelling techniques to improve diagnosis and therapy of cancer** (an IMAGINE – the high-tech specialty exhibit session) (A-190 – A-194)
- **Chairman's introduction**  
*W.J. Niessen; Rotterdam/NL*
  - **Tumor response imaging biomarkers: A practical framework for development**  
*A.R. Padhani; Northwood/UK*
  - **Cutting the errors in evaluating the response to treatment in solid tumor**  
*H.-O. Peitgen; Bremen/DE*
  - **Oncological image analysis: Medical and molecular imaging**  
*M. Brady; Oxford/UK*
  - **Image guidance in interventional radiology and radiotherapy**  
*D.J. Hawkes; London/UK*
  - **Panel discussion: Can new technology cut errors in cancer diagnosis and treatment?**



## Sunday, March 9, 08:30–10:00, Room F2

- SF 9a**     **Cardiothoracic CT: One test solves all** (A-210 – A-213)
- **Chairman's introduction**  
*M. Rémy-Jardin; Lille/FR*
  - **Examination techniques**  
*K. Nikolaou; Munich/DE*
  - **Should chest radiologists look at the heart?**  
*P.A. Grenier; Paris/FR*
  - **Acute chest pain**  
*C.S. White; Baltimore, MD/US*
  - **Panel discussion: ECG-gated CT angiography of the chest: An alternative or a complementary scanning protocol for chest diseases?**

## Sunday, March 9, 08:30–10:00, Room G/H

- SF 9b**     **Hybrid imaging: PET/CT, SPECT/CT, PET/MRI ..., where next?** (A-214 – A-217)
- **Chairman's introduction**  
*A. Bischof Delaloye; Lausanne/CH*
  - **PET/CT: Trends and future developments**  
*L. Højgaard; Copenhagen/DK*
  - **SPECT/CT: The new workhorse?**  
*T. Kuwert; Erlangen/DE*
  - **PET/MRI: The next racehorse?**  
*R. Krieg; Erlangen/DE*
  - **Panel discussion: Is there a real need for more than PET/CT? Has PET(SPECT)/MRI the potential to ultimately replace PET-SPECT/CT?**

## Sunday, March 9, 08:30–10:00, Room K

- SF 9c**     **Imaging your youngest patients: Fetal MRI** (A-221 – A-225)
- **Chairman's introduction**  
*T.A.G.M. Huisman; Zurich/CH*
  - **Patient preparation and MRI technique**  
*D. Prayer; Vienna/AT*

- **Central nervous system**  
*T.A.G.M. Huisman; Zurich/CH*
- **Thorax**  
*M. Hörmann; Vienna/AT*
- **Abdomen**  
*F.E. Avni; Brussels/BE*
- **Panel discussion: Does fetal MRI change pre-, peri- or postnatal management?**

## Sunday, March 9, 16:00–17:30, Room F2

- SF 12**     **Whole body MR imaging: Valuable screening or life style choice for the worried rich?** (A-265 – A-268)
- **Chairman's introduction**  
*A.K. Dixon; Cambridge/UK*
  - **Methods and results**  
*S.C. Ladd; Essen/DE*
  - **Cost effectiveness**  
*S.J. Eustace; Dublin/IE*
  - **Ethical implications**  
*S. Reiter-Theil; Basle/CH*
  - **Panel discussion: Would members of this audience buy a whole body MR scan on their 50<sup>th</sup> birthday?**

## Monday, March 10, 08:30–10:00, Room C

- SF 13**     **The radiologist in image guided surgery: Just a tour guide?** (A-300 – A-303)
- **Chairman's introduction**  
*C. Bartolozzi; Pisa/IT*
  - **Intraoperative navigation using radiological data and software support**  
*N. Navab; Munich/DE*
  - **Image-guided therapy (IGT): Who carries it out?**  
*H. Hricak; New York, NY/US*
  - **Radiology and surgery: A new integrated training environment**  
*D. Caramella; Pisa/IT*
  - **Panel discussion: Imaging and interventions: The need for a new kind of radiologist**

**Monday, March 10, 14:00–15:30, Room E1**

- SF 15a Frontiers in liver imaging**  
(A-352 – A-356)
- **Chairman's introduction**  
*E.J. Rummeny; Munich/DE*
  - **Optimising MDCT for the detection and characterisation of liver tumors**  
*F. Caseiro-Alves; Coimbra/PT*
  - **Maximising the accuracy of MRI for the detection and characterisation of liver tumors**  
*J. Gaa; Munich/DE*
  - **The role of contrast agents in liver MRI**  
*P.J.A. Robinson; Leeds/UK*
  - **Why liver tumors appear as they do? Imaging-pathologic correlation**  
*P.R. Ros; Barcelona/ES*
  - **Panel discussion: When to use CT and when MR imaging for the diagnostic work up in patients with suspected liver tumors and what are the advantages and limitations of the use of liver specific MR contrast agents?**

**Monday, March 10, 14:00–15:30, Room N/O**


- SF 15b Advances in tumor ablation**  
(A-375 – A-378)
- **Chairman's introduction**  
*A. Gangi; Strasbourg/FR*
  - **Should thermal ablation replace partial nephrectomy?**  
*P.R. Mueller; Boston, MA/US*
  - **Percutaneous cryotherapy: When should it be preferred to radiofrequency?**  
*X. Buy; Strasbourg/FR*
  - **High frequency focused ultrasound: Is it a real clinical tool?**  
*G. ter Haar; Sutton/UK*
  - **Panel discussion: Evolution and progress in tumor ablation**

**Monday, March 10, 16:00–17:30, Room C**

- SF 16a Emergency imaging: Avoiding serious mistakes!**  
(A-396 – A-400)
- **Chairman's introduction**  
*R.F. Dondelinger; Liège/BE*
  - **Central nervous system**  
*D. Balériaux; Brussels/BE*
  - **Chest**  
*C. Beigelman-Aubry; Paris/FR*
  - **Abdomen**  
*A.H. Freeman; Cambridge/UK*
  - **Musculoskeletal**  
*K. Bohndorf; Augsburg/DE*
  - **Panel discussion: Highlights of imaging pitfalls and limits in emergency conditions**

**Monday, March 10, 16:00–17:30, Room F1**

- SF 16b Molecular imaging**  
(A-405 – A-409)  
*In cooperation with the European Association of Nuclear Medicine*
- **Chairmen's introduction**  
*F. Berger; Munich/DE*  
*U. Haberkorn; Heidelberg/DE*
  - **Angiogenesis**
  - **Imaging of angiogenesis with MRI**  
*M. Neeman; Rehovot/IL*
  - **Imaging of angiogenesis using radiolabelled peptides**  
*R. Haubner; Innsbruck/AT*
  - **Tracking stem cells**
  - **Tracking of stem cells by radioisotopes**  
*W. Brenner; Hamburg/DE*
  - **Following stem cells by MRI**  
*P. Jendelova; Prague/CZ*
  - **Panel discussion**



## Tuesday, March 11, 08:30–10:00, Room B

- SF 17a CT and MR urography: Is intravenous urography dead?**  
(A-439 – A-442)
- **Chairman's introduction**  
*A.J. van der Molen; Leiden/NL*
  - **CT urography**  
*N.C. Cowan; Oxford/UK*
  - **MR urography**  
*C.C.A. Nolte-Ernsting; Mülheim a.d. Ruhr/DE*
  - **Cost-effectiveness of CTU vs MRU vs IVU**  
*H.S. Thomsen; Herlev/DK*
  - **Panel discussion: Is intravenous urography really dead?**

## Tuesday, March 11, 08:30–10:00, Room F2

- SF 17b New radiation risk estimation: Can we relax?**  
(A-453 – A-456)
- **Chairman's introduction**  
*J. Damilakis; Iraklion/GR*
  - **Does the ever increasing exposure of patients in diagnostic radiology really pose a problem?**  
*J. Griebel; Neuherberg/DE*
  - **Appropriate use of a modality with high diagnostic accuracy and high radiation exposure: Multidetector CT**  
*J.R. Mayo; Vancouver, BC/CA*
  - **Radiation protection, ethics, law and public awareness: In harmony or out of tune?**  
*J. Malone; Dublin/IE*
  - **Panel discussion: Diagnostic X-rays and radiation risk assessment: Facts and controversies**

## Tuesday, March 11, 08:30–10:00, Room L/M

- SF 17c The upcoming 'geriatric tsunami' and its consequences to imaging services**  
(A-466 – A-470)
- **Chairman's introduction**  
*F. Laerum; Oslo/NO*
  - **Mobile, digital X-ray services for nursing homes**  
*J.C. Hellund; Oslo/NO*
  - **Imaging and the increasing incidence of cancer in geriatric populations**  
*O. Ekberg; Malmö/SE*
  - **Stroke**  
*J. Schenkel; Munich/DE*
  - **Dementia**  
*D.J. Brooks; London/UK*
  - **Panel discussion: The elderly population: Special radiological needs and demands**

## Tuesday, March 11, 08:30–10:00, Room N/O

- SF 17d Undergraduate radiological education**  
(A-471 – A-474)
- **Chairman's introduction**  
*F. Kainberger; Vienna/AT*
  - **Learning objectives and limitations**  
*F. Kainberger; Vienna/AT*
  - **Mentoring the enthusiastic student**  
*M. Maas; Amsterdam/NL*
  - **Analogue to digital learning tools**  
*K. Verstraete; Gent/BE*
  - **Panel discussion: What is the radiologist's role in a problem-based integrated curriculum?**

## Professional Challenges Sessions

**Sunday, March 9, 16:00–17:30, Room R3**


- PC 12 Teleradiology: Film reading at the sea side?** (A-289 – A-293)
- **Chairman's introduction**  
*L. Donoso; Sabadell/ES*
  - **Quality standards**  
*J. Reponen; Raahe/FI*
  - **Opportunities and risks**  
*J. Størmer; Tromsø/NO*
  - **Provider's point of view**  
*F.H. Barneveld Binkhuysen; Mechelen/BE*
  - **Professional issues and international guidelines**  
*I.W. McCall; Oswestry/UK*
  - **Panel discussion: Is teleradiology good for our health?**

**Monday, March 10, 08:30–10:00, Room N/O**

- PC 13 Capturing the market: How quality helps** (A-325 – A-328)
- **Chairman's introduction**  
*C.J. Herold; Vienna/AT*
  - **A look at the market: Which factors make a radiology practice thrive?**  
*J.H. Thrall; Boston, MA/US*
  - **Quality as a success factor**  
*J.E. Husband; London/UK*
  - **Setting up a quality management, risk management and patient safety programme: Practical tips**  
*M. Breitenseher; Horn/AT*
  - **Panel discussion (with devil's advocate)**

**Monday, March 10, 16:00–17:30, Room B**

- PC 16 Women in radiology: How to maximise their input** (A-391 – A-395)
- **Chairman's introduction**  
*H.M.L. Carty; Liverpool/UK*
  - **Life as a radiologist, before and after children**  
*B. Ertl-Wagner; Munich/DE*
  - **Eastern Europe: Are the issues the same?**  
*K. Gruszczynska; Katowice/PL*
  - **Can you be a good parent and a good academic radiologist?**  
*I.M. Björkman-Burtscher; Lund/SE*
  - **Family friendly work patterns: How to integrate them in radiology departments**  
*C. Roche; Galway/IE*
  - **Panel discussion: Surviving parenthood and radiology. Having it all. Doing it all. Missing it all?**



## Categorical Course:

### MRI

**Friday, March 7, 08:30–10:00, Room A**

- CC 116 MR techniques: From basic to advanced**  
Moderator:  
*D. Weishaupt; Zurich/CH*
- **A. MRI physics explained by a clinical radiologist** (A-001)  
*W. Kucharczyk; Toronto, ON/CA*
  - **B. Scanner and pulse sequences: Towards higher robustness in clinical routine** (A-002)  
*J. Hennig; Freiburg/DE*

**Saturday, March 8, 08:30–10:00, Room A**

- CC 516 Neuro: The brain as the centre of the world**  
Moderator:  
*O. Flodmark; Stockholm/SE*
- **A. Stroke** (A-091)  
*J. Hendrikse; Utrecht/NL*
  - **B. Tumors** (A-092)  
*N. Colombo; Milan/IT*
  - **C. Infections** (A-093)  
*C.F. Andreula; Bari/IT*

**Saturday, March 8, 16:00–17:30, Room A**

- CC 816 Musculoskeletal: A step-by-step approach**  
Moderator:  
*M. Zanetti; Zurich/CH*
- **A. Trauma** (A-143)  
*C. Glaser; Munich/DE*
  - **B. Neoplasms** (A-144)  
*A.M. Davies; Birmingham/UK*
  - **C. Inflammatory and infectious diseases** (A-145)  
*V.N. Cassar-Pullicino; Oswestry/UK*

**Sunday, March 9, 08:30–10:00, Room A**

- CC 916 Neuro: Conquering important territories**  
Moderator:  
*D. Goldsher; Haifa/IL*
- **A. Spine: Degenerative disc disease** (A-195)  
*M. Gallucci; L'Aquila/IT*
  - **B. Demyelinating diseases and myelopathy** (A-196)  
*V. Dousset; Bordeaux/FR*
  - **C. Trauma and hemorrhage** (A-197)  
*M. Stajgis; Poznan/PL*

**Sunday, March 9, 16:00–17:30, Room A**

- CC 1216 Vascular: From head to toe**  
Moderator:  
*J.F.M. Meaney; Dublin/IE*
- **A. Atherosclerosis** (A-247)  
*H.J. Michaely; Mannheim/DE*
  - **B. Non-atherosclerotic arterial disease** (A-248)  
*T. Leiner; Maastricht/NL*
  - **C. Venous disease** (A-249)  
*M. Aschauer; Graz/AT*

**Monday, March 10, 08:30–10:00, Room A**

- CC 1316 Abdomen: Is MRI the ultimate tool?**  
Moderator:  
*G. Brown; Sutton/UK*
- **A. Liver** (A-294)  
*L. Marti-Bonmati; Valencia/ES*
  - **B. Pancreas** (A-295)  
*C. Matos; Brussels/BE*
  - **C. Small and large bowel** (A-296)  
*K.A. Herrmann; Munich/DE*

**Monday, March 10, 16:00–17:30, Room A**
**CC 1616 Cardiac MRI:**
**An affair of the heart**

Moderator:

*V.E. Sinitsyn; Moscow/RU*

- **A. Ischemic disease** (A-388)  
*A. de Roos; Leiden/NL*
- **B. Non-ischemic diseases: Does MRI see them all?** (A-389)  
*J. Bogaert; Leuven/BE*
- **C. Congenital disease** (A-390)  
*J. Bremerich; Basle/CH*

**Tuesday, March 11, 08:30–10:00, Room A**
**CC 1716 The future is now!**

Moderator:

*C. Loewe; Vienna/AT*

- **A. Faster! Accelerated MRI with parallel imaging** (A-436)  
*B.J. Wintersperger; Munich/DE*
- **B. Larger! Whole-body MRI: From morphology to disease** (A-437)  
*H.K. Ahlström; Uppsala/SE*
- **C. Better! Diffusion weighted MRI and MR-PETography** (A-438)  
*T. La Folie; Marseille/FR*

**Categorical Course:**
**Breast: From Basics to Advanced Imaging**
**Friday, March 7, 16:00–17:30, Room E1**
**CC 418 From pathology to breast imaging: Radiologic-pathologic correlations**

Moderator:

*C. El Khoury; Paris/FR*

- **A. Benign masses and invasive carcinomas** (A-056)  
*T. Tot; Falun/SE*
- **B. Benign and malignant calcifications** (A-057)  
*D. Faverly; Brussels/BE*

**Saturday, March 8, 08:30–10:00, Room E1**
**CC 518 Breast lesions at mammography: How to characterise?**

Moderator:

*A. Fausto; Milan/IT*

- **A. Mass, focal asymmetry and architectural distortion** (A-101)  
*M. Michell; London/UK*

- **B. Clustered microcalcifications** (A-102)  
*G. Forrai; Budapest/HU*

**Sunday, March 9, 16:00–17:30, Room R2**
**CC 1218 Characterisation of breast lesions by US and MRI**

Moderator:

*E. Azavedo; Stockholm/SE*

- **A. Breast lesions detected by US** (A-287)  
*M. Locatelli; Gorizia/IT*
- **B. Breast lesions detected by MRI** (A-288)  
*K. Kinkel; Chêne-Bougeries/CH*

**Monday, March 10, 14:00–15:30, Room R2**
**CC 1518 Interventional procedures**

Moderator:

*D. Flöry; Vienna/AT*

- **A. Mammography guidance** (A-382)  
*C. Del Frate; Udine/IT*
- **B. US guidance** (A-383)  
*J. Camps-Herrero; Valencia/ES*
- **C. MR guidance** (A-384)  
*J. Veltman; Nijmegen/NL*


**Monday, March 10, 16:00–17:30, Room R2**
**CC 1618 Advanced imaging: Full-field digital mammography (FFDM)/MRI**

Moderator:

*N. Karssemeijer; Nijmegen/NL*

- **A. FFDM = CAD, angio-mammography** (A-430)  
*C. Dromain; Villejuif/FR*
- **B. FFDM = Tomosynthesis** (A-431)  
*R.A. Jong; Toronto, ON/CA*
- **C. MRI: MR techniques for optimal diagnostic accuracy** (A-432)  
*C.K. Kuhl; Bonn/DE*





## Tuesday, March 11, 08:30–10:00, Room R2

### CC 1718 Advanced imaging

Moderator:  
*L.S. Fournier; Paris/FR*

- **A. PET imaging** (A-478)  
*P. Rigo; Monaco/MC*
- **B. Optical imaging** (A-479)  
*C. Bremer; Münster/DE*
- **C. Functional imaging: MR spectroscopy and beyond** (A-480)  
*T.H. Helbich; Toronto, ON/CA*

### Categorical Course: Multidetector CT Made Easy

#### Friday, March 7, 08:30–10:00, Room B

### CC 117 MDCT implementation: Making the best of the technology race

Moderator:  
*M. Kachelrieß; Erlangen/DE*

- **A. The choice of scanner: A strategic decision** (A-003)  
*M. Prokop; Utrecht/NL*
- **B. Injecting contrast with ever faster scanners** (A-004)  
*D. Fleischmann; Stanford, CA/US*
- **C. How to justify and reduce the dose** (A-005)  
*A.J. van der Molen; Leiden/NL*

#### Friday, March 7, 16:00–17:30, Room B

### CC 417 The heart: A newly found land

Moderator:  
*D.N. Exarhos; Athens/GR*

- **A. Cardiac CT: Protocols and anatomy** (A-049)  
*F. Cademartiri; Rotterdam/NL*
- **B. The coronary arteries: MDCT as the new standard?** (A-050)  
*C.R. Becker; Munich/DE*
- **C. Beyond the coronaries** (A-051)  
*H. Alkadhi; Zurich/CH*

## Saturday, March 8, 08:30–10:00, Room B

### CC 517 The guts: Growing opportunities

Moderator:  
*J. Puig Domingo; Sabadell/ES*

- **A. Small bowel CT: Try it, you'll like it!** (A-094)  
*P. Rogalla; Berlin/DE*
- **B. Bowel emergencies: The basic tool** (A-095)  
*J. Stoker; Amsterdam/NL*
- **C. Colon and rectum: Not only colonography** (A-096)  
*A. Laghi; Latina/IT*

## Saturday, March 8, 16:00–17:30, Room B

### CC 817 The chest: A high resolution country

Moderator:  
*Y. Pallardó; Valencia/ES*

- **A. Submillimetric imaging of lung parenchyma** (A-146)  
*J.A. Verschakelen; Leuven/BE*
- **B. Lung cancer screening: The new challenges** (A-147)  
*T.E. Hartman; Rochester, MN/US*
- **C. Functional insights into lung and airways diseases using CT** (A-148)  
*P.A. Grenier; Paris/FR*

## Sunday, March 9, 08:30–10:00, Room B

### CC 917 Bones and joints: CT is still alive!

Moderator:  
*G.B. Adam; Hamburg/DE*

- **A. The spine: Yalta CT/ MRI?** (A-198)  
*D. Weishaupt; Zurich/CH*
- **B. Polytraumatized patient: CT as the first line technique** (A-199)  
*R.A. Novelline; Boston, MA/US*
- **C. Peripheral bones and joints: What is left for CT?** (A-200)  
*T. Marshall; Norwich/UK*

**Sunday, March 9, 16:00–17:30, Room B****CC 1217 The abdomen:****The realm of MDCT**

Moderator:

*G. Marchal; Leuven/BE*

- **A. The liver: Is MDCT beating MRI?** (A-250)  
*R.C. Nelson; Durham, NC/US*
- **B. The pancreas: MDCT stays the number one** (A-251)  
*M. Zins; Paris/FR*
- **C. The kidneys and excretory system: Substituting IVU** (A-252)  
*F. Stacul; Trieste/IT*

**Monday, March 10, 08:30–10:00, Room B****CC 1317 CT of the brain, head and neck: Is there anything new?**

Moderator:

*E.T. Tali; Ankara/TR*

- **A. Acute and chronic ischemia: Combining CT with CTP** (A-297)  
*P.M. Parizel; Antwerp/BE*
- **B. Aneurysms and AVMs: When is CT enough?** (A-298)  
*M.M. Thurnher; Vienna/AT*
- **C. Head and neck lesions: A new role for CT?** (A-299)  
*M. Annertz; Lund/SE*

**Monday, March 10, 14:00–15:30, Room B****CC 1517 MDCT angiography: Do we need anything else?**

Moderator:

*K.H. Tay; Singapore/SG*

- **A. The pulmonary vessels** (A-345)  
*M. Rémy-Jardin; Lille/FR*
- **B. The arterial highways** (A-346)  
*G.D. Rubin; Stanford, CA/US*
- **C. Detours** (A-347)  
*C. Catalano; Rome/IT*

**Mini Course:****Molecular Imaging****Friday, March 7, 08:30–10:00, Room N/O****MC 119 Molecular imaging**

Moderator:

*N. Grenier; Bordeaux/FR*

- **A. Introduction: Scope of molecular imaging** (A-033)  
*C. Bremer; Münster/DE*
- **B. MR probes for molecular imaging** (A-034)  
*S. Aime; Turin/IT*
- **C. Molecular imaging and cell therapies: Techniques** (A-035)  
*H.E. Daldrup-Link; San Francisco, CA/US*

**Saturday, March 8, 08:30–10:00, Room N/O****MC 519 Molecular imaging in cardiovascular diseases**

Moderator:

*C. Pirich; Salzburg/AT*


- **A. Atherosclerotic plaques** (A-118)  
*E. Canet Soulas; Bron/FR*
- **B. Myocardial infarction** (A-119)  
*M. Bernsen; Rotterdam/NL*
- **C. Angiogenesis** (A-120)  
*M. Neeman; Rehovot/IL*

**Sunday, March 9, 08:30–10:00, Room N/O****MC 919 Cancer and inflammation**

Moderator:

*K. Åhlström Riklund; Umeå/SE*

- **A. Neurological diseases** (A-228)  
*M. Höhn; Cologne/DE*
- **B. Diabetes** (A-229)  
*M. Hájek; Prague/CZ*
- **C. Clinical applications** (A-230)  
*O. Clément; Paris/FR*



## Mini Course: Women's Imaging: Female Pelvis

Friday, March 7, 08:30–10:00, Room L/M

### MC 125 Assessment of anatomy and imaging in benign lesions

Moderator:

*M. Bekiesinska-Figatowska; Warsaw/PL*

- **A. Normal anatomy (US, CT, PET/CT and MR)** (A-030)  
*E. Sala; Cambridge/UK*
- **B. Infertility: Imaging of the uterus and Fallopian tubes** (A-031)  
*D. Levine; Boston, MA/US*
- **C. Benign tumors of the uterus: Detection and characterisation** (A-032)  
*C. Reinhold; Montreal, QC/CA*

Friday, March 7, 16:00–17:30, Room L/M

### MC 425 Malignant tumors

Moderator:

*D. Grenier; Paris/FR*

- **A. Cancer of the uterus: Primary and metastatic** (A-075)  
*M.H. Fuchsjäger; Vienna/AT*
- **B. Cancer of the cervix: Primary staging and detection of cancer recurrence** (A-076)  
*B. Hamm; Berlin/DE*
- **C. Cancer of the ovary: Relevance of imaging to patient management** (A-077)  
*H. Hricak; New York, NY/US*

## Refresher Courses / Scientific Sessions: Abdominal and Gastrointestinal

Friday, March 7, 08:30–10:00, Room R2

### RC 101 Imaging of malignant liver lesions

Moderator:

*D.J. Lomas; Cambridge/UK*

- **A. Liver metastases** (A-039)  
*A. Palkó; Szeged/HU*
- **B. Primary malignancies in the non-cirrhotic liver** (A-040)  
*T.K. Helmberger; Munich/DE*
- **C. Primary malignancies in the cirrhotic liver** (A-041)  
*G. Brancatelli; Palermo/IT*

Friday, March 7, 10:30–12:00, Room C

### SS 201b Advances in abdominal imaging

(B-011 – B-020)

Moderators:

*E. Biscaldi; Genoa/IT*

*Y. Imai; Isehara/JP*

Friday, March 7, 14:00–15:30, Room C

### SS 301a Challenges in hepatobiliary diseases

(B-141 – B-150)

Moderators:

*J.S. Laméris; Amsterdam/NL*

*A. Lubienski; Lübeck/DE*

Friday, March 7, 16:00–17:30, Room R2

### RC 401 Diseases of the mesentery and peritoneum

Moderator:

*P.K. Prassopoulos;*

*Alexandroupolis/GR*

- **A. Radiologic anatomy of the mesentery and peritoneum** (A-084)  
*A. Ba-Ssalamah; Vienna/AT*
- **B. Neoplastic diseases** (A-085)  
*Y. Menu; Le Kremlin-Bicêtre/FR*
- **C. Infectious and inflammatory disease** (A-086)  
*L. Crocetti; Pisa/IT*

**Saturday, March 8, 08:30–10:00, Room R2**
**RC 501 Imaging in pancreatitis**

Moderator:

*P. Soffia; Santiago/CL*

- **A. Acute pancreatitis** (A-124)  
*N. Elmas; Izmir/TR*
- **B. Chronic pancreatitis** (A-125)  
*W. Schima; Vienna/AT*
- **C. Complications of pancreatitis** (A-126)  
*C. Triantopoulou; Athens/GR*

**Saturday, March 8, 10:30–12:00, Room C**
**SS 601a Functional imaging of the abdomen: Are we there yet?**

(B-261 – B-270)

Moderators:

*F. Arredondo; Guatemala City/GT*  
*C.S. Reiner; Zurich/CH*
**Saturday, March 8, 14:00–15:30, Room B**
**SS 701a Magic bullets for hepatic lesions** (B-351 – B-360)

Moderators:

*B.I. Choi; Seoul/KR*  
*L. Curvo-Semedo; Coimbra/PT*
**Saturday, March 8, 14:00–15:30, Room C**
**SS 701b Colon and rectum**

(B-361 – B-370)

Moderators:

*G. Maskell; Truro/UK*  
*S. Schmidt; Lausanne/CH*
**Saturday, March 8, 16:00–17:30, Room R2**
**RC 801 Imaging of the acute abdomen**

Moderator:

*M. Marotti; Zagreb/HR*

- **A. Diagnosis of acute abdomen: Any imaging prior to MDCT?** (A-184)  
*P.-A. Poletti; Geneva/CH*
- **B. CT as the first line examination** (A-185)  
*P. Taourel; Montpellier/FR*
- **C. Increasing role for emergency MRI?** (A-186)  
*K. Schunk; Koblenz/DE*

**Sunday, March 9, 08:30–10:00, Room R2**
**RC 901 Small nodules in the cirrhotic liver: What to do?**

Moderator:

*C. Aubé; Angers/FR*

- **A. Surveillance of the cirrhotic patient** (A-234)  
*C. Bru; Barcelona/ES*
- **B. How to characterise a small focal lesion in cirrhosis** (A-235)  
*D. Cioni; Pisa/IT*
- **C. When and how to treat** (A-236)  
*C.D. Becker; Geneva/CH*

**Sunday, March 9, 10:30–12:00, Room C**
**SS 1001b CT colonography**

(B-471 – B-480)

Moderators:

*E. Neri; Pisa/IT*  
*S. Somers; Dundas, ON/CA*
**Monday, March 10, 08:30–10:00, Room R2**
**RC 1301 CT colonography: How to use it**

Moderator:

*S.A. Taylor; London/UK*

- **A. How to do it** (A-332)  
*H. Fenlon; Dublin/IE*
- **B. How to read it** (A-333)  
*T. Mang; Vienna/AT*
- **C. Clinical value** (A-334)  
*P. Lefere; Roeselare/BE*

**Monday, March 10, 10:30–12:00, Room B**
**SS 1401a Checking out the pancreaticobiliary system**

(B-581 – B-590)


Moderators:

*P.E. Huppert; Darmstadt/DE*  
*F. Takis; Keratea/GR*
**Monday, March 10, 10:30–12:00, Room C**
**SS 1401b Esophageal and gastric cancer: New approaches**

(B-591 – B-600)

Moderators:

*M.A. Bali; Brussels/BE*  
*N. Papanicolaou; Philadelphia, PA/US*



## Tuesday, March 11, 08:30–10:00, Room C

- RC 1701 Liver vasculature: Radiologic anatomy and disorders**  
 Moderator:  
*R.W. Prokesch; Zell am See/AT*
- **A. Anatomy of liver vasculature: What the radiologist needs to know** (A-443)  
*F. Caseiro-Alves; Coimbra/PT*
  - **B. Portal hypertension: Imaging features** (A-444)  
*M.-P. Vullierme; Clichy/FR*
  - **C. Parenchymal disorders of vascular origin** (A-445)  
*C.J. Zech; Munich/DE*

## Tuesday, March 11, 10:30–12:00, Room B

- SS 1801a HCC, still tantalising and bewildering**  
 (B-711 – B-720)  
 Moderators:  
*M.-F. Bellin; Villejuif/FR*  
*L. Crocetti; Pisa/IT*

## Tuesday, March 11, 10:30–12:00, Room C

- SS 1801b Small bowel and appendix**  
 (B-721 – B-730)  
 Moderators:  
*G.J. Antes; Kempten/DE*  
*V. Maniatis; Athens/GR*

## Breast

### Friday, March 7, 10:30–12:00, Room F2

- SS 202 Advances in digital mammography**  
 (B-041 – B-050)  
 Moderators:  
*L. Khoo; London/UK*  
*R.L. Lavayssiere; Sarcelles/FR*

### Friday, March 7, 14:00–15:30, Room F2

- SS 302 Innovation in breast diagnosis**  
 (B-161 – B-170)  
 Moderators:  
*G. Rizzatto; Gorizia/IT*  
*S. Weum; Tromsø/NO*

### Friday, March 7, 16:00–17:30, Room F2

- RC 402 Digital mammography**  
 Moderator:  
*R. Salvador; Barcelona/ES*
- **A. Quality assurance and quality vs dose** (A-062)  
*H. Bosmans; Leuven/BE*
  - **B. Computer-aided detection and diagnosis** (A-063)  
*L. Khoo; London/UK*
  - **C. Screening: Practical issues** (A-064)  
*N.M. Perry; London/UK*

### Saturday, March 8, 10:30–12:00, Room F2

- SS 602 Intervention**  
 (B-281 – B-290)  
 Moderators:  
*P. Petrow; Paris/FR*  
*M. Sentis; Sabadell/ES*

### Saturday, March 8, 16:00–17:30, Room F2

- RC 802 MRI of the breast**  
 Moderator:  
*F. Pediconi; Rome/IT*
- **A. Basics and new techniques** (A-162)  
*T.H. Helbich; Toronto, ON/CA*
  - **B. Staging** (A-163)  
*C.K. Kuhl; Bonn/DE*
  - **C. Monitoring response to neoadjuvant chemotherapy** (A-164)  
*L. Ollivier; Paris/FR*

**Sunday, March 9, 10:30–12:00, Room F2**

**SS 1002 MR: New clinical findings**  
 (B-491 – B-500)  
 Moderators:  
*R.A. Jong; Toronto, ON/CA*  
*J. Veltman; Nijmegen/NL*

**Monday, March 10, 08:30–10:00, Room F2**

**RC 1302 Changing approaches to breast diseases?**  
 Moderator:  
*P. Viehweg; Dresden/DE*

- **A. Screening in high risk groups** (A-311)  
*F.J. Gilbert; Aberdeen/UK*
- **B. Interventional treatment** (A-312)  
*M. Torres-Tabanera; Madrid/ES*
- **C. Follow-up and surveillance** (A-313)  
*S. Barter; Cambridge/UK*

**Monday, March 10, 10:30–12:00, Room F2**

**SS 1402 MR: Know-how for new approaches**  
 (B-611 – B-620)  
 Moderators:  
*M. Müller-Schimpfle; Frankfurt a. Main/DE*  
*K. Vassiou; Larissa/GR*

**Monday, March 10, 14:00–15:30, Room F2**

**RC 1502 Ultrasound and breast disease**  
 Moderator:  
*H.M. Zonderland; Amsterdam/NL*

- **A. Understanding anatomy to detect disease** (A-361)  
*G. Rizzato; Gorizia/IT*
- **B. 3D-4D breast ultrasound** (A-362)  
*C.F. Weismann; Salzburg/AT*
- **C. Lesion characterisation** (A-363)  
*M. Locatelli; Gorizia/IT*

**Monday, March 10, 16:00–17:30, Room F2**

**RC 1602 Diagnosis and staging of breast cancer**  
 Moderator:  
*R. Schulz-Wendtland; Erlangen/DE*

- **A. IDC and ILC: Diagnostic challenges** (A-410)  
*C. Boetes; Nijmegen/NL*
- **B. Lymph-node evaluation** (A-411)  
*M.H. Fuchsjäger; Vienna/AT*
- **C. Interventional procedures** (A-412)  
*L. Steyaert; Bruges/BE*

**Tuesday, March 11, 10:30–12:00, Room F2**

**SS 1802 MR: Role in patient management**  
 (B-751 – B-760)  
 Moderators:  
*H. Dobson; Glasgow/UK*  
*A. Tardivon; Paris/FR*

**Cardiac**
**Friday, March 7, 10:30–12:00, Room R2**

**SS 203 Advances in cardiac CT**  
 (B-111 – B-120)  
 Moderators:  
*G. Hadjidekov; Sofia/BG*  
*C.S. White; Baltimore, MD/US*

**Friday, March 7, 14:00–15:30, Room R2**


**SS 303 Advances in cardiac MR**  
 (B-231 – B-240)  
 Moderators:  
*E. Di Cesare; L'Aquila/IT*  
*C. Saraiva; Lisbon/PT*

**Saturday, March 8, 10:30–12:00, Room R2**

**SS 603 Imaging of the right heart**  
 (B-321 – B-330)  
 Moderators:  
*M. Gardarsdottir; Reykjavik/IS*  
*F. Sardanelli; Milan/IT*

**Saturday, March 8, 14:00–15:30, Room R2**

**SS 703 CT/MR in cardiovascular risk assessment** (B-441 – B-450)  
 Moderators:  
*A. Bücker; Homburg/DE*  
*R. Vliegenthart; Groningen/NL*



## Saturday, March 8, 16:00–17:30, Room R1

### RC 803 How to perform a complete:

Moderator:  
*L. Natale; Rome/IT*

- **A. CT examination of the heart** (A-181)  
*F. Cademartiri; Rotterdam/NL*
- **B. MR examination of the heart** (A-182)  
*J. Bogaert; Leuven/BE*
- **C. Examination of the heart in children** (A-183)  
*A.J.B.S. Madureira; Porto/PT*

## Sunday, March 9, 08:30–10:00, Room R1

### RC 903 The atherosclerotic plaque

Moderator:  
*E. Spüntrup; Cologne/DE*

- **A. CT plaque imaging and characterisation** (A-231)  
*A. Küttner; Erlangen/DE*
- **B. MR plaque imaging and differentiation** (A-232)  
*Z.A. Fayad; New York, NY/US*
- **C. Calcium scoring and CT angiography in clinical practice** (A-233)  
*G. Feuchtner; Innsbruck/AT*

## Sunday, March 9, 10:30–12:00, Room R2

### SS 1003 Myocardial and pericardial diseases

(B-551 – B-560)  
Moderators:  
*Z.M. Metafratzi; Ioannina/GR*  
*D. Piotrowska-Kownacka; Warsaw/PL*

## Monday, March 10, 08:30–10:00, Room R1

### RC 1303 Imaging of myocardial infarction

Moderator:  
*M. Oudkerk; Groningen/NL*

- **A. MR imaging of acute myocardial infarction** (A-329)  
*J.-F. Paul; Le Plessis Robinson/FR*
- **B. Prediction of myocardial viability with MR** (A-330)  
*M.R. Rees; Gwynedd/UK*
- **C. MDCT for the detection and quantification of myocardial infarction** (A-331)  
*I. Mastorakou; Athens/GR*

## Monday, March 10, 10:30–12:00, Room R2

### SS 1403 MR/CT in treatment evaluation

(B-681 – B-690)  
Moderators:  
*A. Jacquier; Marseille/FR*  
*S.D. Ganadli; Lausanne/CH*

## Tuesday, March 11, 08:30–10:00, Room R1

### RC 1703 CT vs MRI

Moderator:  
*R. Maksimovic; Belgrade/CS*

- **A. Congenital heart disease** (A-475)  
*J. Glowacki; Zabrze/PL*
- **B. Cardiomyopathies** (A-476)  
*J. Bremerich; Basle/CH*
- **C. Tumor and pericardial disease** (A-477)  
*H. Scheffel; Zurich/CH*

## Tuesday, March 11, 10:30–12:00, Room E1

### SS 1803a Coronary artery imaging

(B-731 – B-740)  
Moderators:  
*F. Pugliese; Rotterdam/NL*  
*H.-J. Smith; Oslo/NO*

**Tuesday, March 11, 10:30–12:00, Room R2**
**SS 1803b Valvular and cardiac function studies**

(B-821 – B-830)

Moderators:

*N.L. Kelekis; Athens/GR*
*G.K. Schneider;*
*Homburg a.d. Saar/DE*
**Chest**
**Friday, March 7, 08:30–10:00, Room R1**
**RC 104 Volumetric HRCT of diffuse lung diseases**

Moderator:

*J. Neuwirth; Prague/CZ*

- **A. Technical and dose considerations in imaging interstitial lung disease** (A-036)  
*D. Tack; Brussels/BE*
- **B. Airway diseases** (A-037)  
*G. Ferretti; Grenoble/FR*
- **C. Collagen vascular diseases** (A-038)  
*S.R. Desai; London/UK*

**Friday, March 7, 10:30–12:00, Room R1**
**SS 204 Advances in tumor imaging**

(B-101 – B-110)

Moderators:

*M. Boijssen; Gothenburg/SE*
*A. Oikonomou;*
*Alexandroupolis/GR*
**Friday, March 7, 14:00–15:30, Room R1**
**SS 304 Screening/Pulmonary nodule**

(B-221 – B-230)

Moderators:

*G. Bastarrrika; Pamplona/ES*
*J. Votrubová; Prague/CZ*
**Friday, March 7, 16:00–17:30, Room R1**
**RC 404 A practical approach for interpreting the chest radiograph**

Moderator:

*K. Malagari; Athens/GR*

- **A. General principles** (A-081)  
*A.A. Bankier; Boston, MA/US*

- **B. The frontal view** (A-082)  
*N. Howarth; Chêne-Bougeries/CH*
- **C. The lateral view** (A-083)  
*J. Cáceres; Barcelona/ES*

**Saturday, March 8, 08:30–10:00, Room R1**
**RC 504 Pulmonary embolism update**

Moderator:

*J. Vilar; Valencia/ES*

- **A. How to optimise the examination technique** (A-121)  
*I. Hartmann; Rotterdam/NL*
- **B. The dyspnoeic patient: Which diagnostic strategy?** (A-122)  
*L. Bonomo; Rome/IT*
- **C. Subsegmental emboli** (A-123)  
*C. Engelke; Munich/DE*

**Saturday, March 8, 10:30–12:00, Room N/O**
**SS 604 Reporting and CAD (CXR and CT)**

(B-311 – B-320)

Moderators:

*K. Marten; Würzburg/DE*
*M. Skilakaki; Athens/GR*
**Saturday, March 8, 14:00–15:30, Room R1**
**SS 704 Pulmonary embolism**

(B-431 – B-440)

Moderators:

*A.P. Pankar; Bergen/NO*
*E.J. Stern; Seattle, WA/US*
**Sunday, March 9, 16:00–17:30, Room R1**
**RC 1204 Bronchogenic carcinoma: Screening and staging**

Moderator:

*M.L. Storto; Chieti/IT*

- **A. Screening: Guidelines for follow-up** (A-284)  
*S. Diederich; Düsseldorf/DE*
- **B. Staging with CT and MRI** (A-285)  
*T.C. McLeod; Boston, MA/US*
- **C. Staging with PET/CT** (A-286)  
*W. De Wever; Leuven/BE*





## Monday, March 10, 10:30–12:00, Room R1

- SS 1404 Advances in CT**  
(B-671 – B-680)  
Moderators:  
*R. McDermott; Dublin/IE*  
*P. Goodman; Durham, NC/US*

## Monday, March 10, 14:00–15:30, Room R1

- RC 1504 Diagnostic mimics in chest diseases**  
Moderator:  
*E. Castañer; Sabadell/ES*
- **A. Focal opacity** (A-379)  
*F. Gleeson; Oxford/UK*
  - **B. Alveolar opacities** (A-380)  
*C. Schaefer-Prokop; Amsterdam/NL*
  - **C. Interstitial opacities** (A-381)  
*A. Oikonomou; Alexandroupolis/GR*

## Monday, March 10, 16:00–17:30, Room R1

- RC 1604 Computer-aided diagnosis in the chest**  
Moderator:  
*P.A. Grenier; Paris/FR*
- **A. Techniques behind CAD** (A-427)  
*B. van Ginneken; Utrecht/NL*
  - **B. Lung nodule: Detection and characterisation** (A-428)  
*D. Wormanns; Berlin/DE*
  - **C. Advanced applications** (A-429)  
*H.-U. Kauczor; Heidelberg/DE*

## Tuesday, March 11, 10:30–12:00, Room R1

- SS 1804 Technical advances/Pulmonary hypertension and perfusion**  
(B-811 – B-820)  
Moderators:  
*M. Bellomi; Milan/IT*  
*C. Mueller-Mang; Vienna/AT*

## Computer Applications

### Friday, March 7, 08:30–10:00, Room K

- RC 105 What can PACS do today?**  
Moderator:  
*E. Bellon; Leuven/BE*
- **A. Speech recognition and PACS-RIS: Friend or foe?** (A-027)  
*C.G. Trumm; Munich/DE*
  - **B. PACS and post-processing: Engagement, wedding and divorce** (A-028)  
*A. Blum; Nancy/FR*
  - **C. PACS as an essential for radiology education** (A-029)  
*A. Toms; Norwich/UK*

### Friday, March 7, 10:30–12:00, Room K

- SS 205 CAD and automated image analysis** (B-071 – B-080)  
Moderators:  
*D. Loeckx; Leuven/BE*  
*R. Passariello; Rome/IT*

### Friday, March 7, 14:00–15:30, Room K

- SS 305 Image viewing and PACS** (B-191 – B-200)  
Moderators:  
*J. Fernandez-Bayó; Sabadell/ES*  
*R. W.R. Loose; Nuremberg/DE*

### Friday, March 7, 16:00–17:30, Room K

- RC 405 PACS in evolution**  
Moderator:  
*N.H. Strickland; London/UK*
- **A. Structured reporting** (A-072)  
*P. Mildenberger; Mainz/DE*
  - **B. Process management and quality assurance in PACS** (A-073)  
*J.G. Blickman; Nijmegen/NL*
  - **C. Regional and national PACS and EPR** (A-074)  
*R. Vogl; Münster/DE*

### Sunday, March 9, 10:30–12:00, Room G/H

- SS 1005 Radiological reporting and teaching** (B-501 – B-510)  
Moderators:  
*G. Pärtan; Vienna/A*  
*G. Turóczy; Budapest/HU*

## Molecular Imaging and Contrast Media

Friday, March 7, 10:30–12:00, Room E1

**SS 206b Preclinical studies**  
(B-021 – B-030)  
Moderators:  
*I. Carrió; Barcelona/ES*  
*F. Kiessling; Heidelberg/DE*

Friday, March 7, 10:30–12:00, Room N/O

**SS 206a Side effects** (B-091 – B-100)  
Moderators:  
*J. Grimm; New York, NY/US*  
*S.K. Morcos; Sheffield/UK*

Sunday, March 9, 16:00–17:30, Room N/O

**RC 1206 Angiogenesis imaging in clinical practice today**  
Moderator:  
*W.A. Kaiser; Jena/DE*

- **A. Principles** (A-281)  
*K.A. Miles; Brighton/UK*
- **B. How to do it** (A-282)  
*A.R. Padhani; Northwood/UK*
- **C. Information you can get** (A-283)  
*J.D. Barentsz; Nijmegen/NL*

Monday, March 10, 10:30–12:00, Room G/H

**SS 1406b Clinical applications**  
(B-621 – B-630)  
Moderators:  
*C.A. Cuénod; Paris/FR*  
*C.C. Riedl; New York, NY/US*

Monday, March 10, 16:00–17:30, Room N/O

**RC 1606 US contrast agents**  
Moderator:  
*D. Catalano; Naples/IT*

- **A. Basics of US contrast agents** (A-424)  
*A.P. Wieczorek; Lublin/PL*
- **B. Current and future applications** (A-425)  
*J.-M. Correas; Paris/FR*
- **C. Targeted US bubbles** (A-426)  
*M. Mäurer; Erlangen/DE*

Tuesday, March 11, 10:30–12:00, Room L/M

**SS 1806a From research to practice**  
(B-791 – B-800)  
Moderators:  
*J.-M. Correas; Paris/FR*  
*D. Reddan; Galway/IE*

## Genitourinary

Friday, March 7, 10:30–12:00, Room F1

**SS 207 The uterus** (B-031 – B-040)  
Moderators:  
*E.J. Adam; London/UK*  
*R. Girometti; Udine/IT*

Friday, March 7, 14:00–15:30, Room F1

**SS 307 Imaging of the pelvis**  
(B-151 – B-160)  
Moderators:  
*P. Aspelin; Stockholm/SE*  
*A. Bianek-Bodzak; Gdansk/PL*

Saturday, March 8, 08:30–10:00, Room R3


**RC 507 Imaging of the pelvic floor**  
Moderator:  
*R. Manfredi; Verona/IT*

- **A. Assessment of anatomy and function with MRI** (A-127)  
*R.F.M. El Sayed; Cairo/EG*
- **B. Functional MRI: When and how?** (A-128)  
*T. Fischer; Munich/DE*
- **C. US in stress incontinence** (A-129)  
*C. Roy; Strasbourg/FR*

Saturday, March 8, 16:00–17:30, Room F1

**RC 807 What to do with all these small renal masses?**  
Moderator:  
*J.E. Husband; London/UK*

- **A. Detection and characterisation: How far can we reach with our imaging techniques?** (A-159)  
*A. Cieszanowski; Warsaw/PL*
- **B. Renal masses: When and why to biopsy them** (A-160)  
*S.G. Silverman; Boston, MA/US*
- **C. Alternative treatment: RF ablation** (A-161)  
*B.J. Wood; Bethesda, MD/US*



## Sunday, March 9, 08:30–10:00, Room R3

### RC 907 Imaging of the male genitalia

Moderator:  
*G. Malahias; Athens/GR*

- **A. The acute scrotum** (A-237)  
*L.E. Derchi; Genoa/IT*
- **B. Testicular tumors** (A-238)  
*R.H. Oyen; Leuven/BE*
- **C. The penis** (A-239)  
*P. Pavlica; Bologna/IT*

## Sunday, March 9, 10:30–12:00, Room F1

### SS 1007 Imaging of the urinary tract: Do new techniques give new answers? (B-481 – B-490)

Moderators:  
*J.J. Fütterer; Nijmegen/NL*  
*S.A.A.Z. Hanna; Cairo/EG*

## Sunday, March 9, 16:00–17:30, Room F1

### RC 1207 Imaging of the adnexal masses

Moderator:  
*M. Basak; Istanbul/TR*

- **A. What to do with an adnexal mass: Sonography** (A-262)  
*M. Weston; Leeds/UK*
- **B. How to characterise an indeterminate adnexal mass with MRI** (A-263)  
*R. Forstner; Salzburg/AT*
- **C. CT staging for sonographically malignant lesions** (A-264)  
*C.S. Balleyguier; Villejuif/FR*

## Monday, March 10, 10:30–12:00, Room F1

### SS 1407 Imaging of renal lesions: Perfusion, diffusion and more (B-601 – B-610)

Moderators:  
*M. Claudon; Vandoeuvre-les-Nancy/FR*  
*T. Meindl; Munich/DE*

## Monday, March 10, 14:00–15:30, Room F1

### RC 1507 Percutaneous stone extraction: Success by team work

Moderator:  
*M. Riccabona; Graz/AT*

- **A. Which stones need a percutaneous extraction and how is it done?** (A-358)  
*S. Moussa; Edinburgh/UK*
- **B. The role of the radiologist** (A-359)  
*A. Magnusson; Uppsala/SE*
- **C. The role of the endourologist** (A-360)  
*M. Brehmer; Stockholm/SE*

## Tuesday, March 11, 10:30–12:00, Room F1

### SS 1807 Prostate imaging: Diagnosis, therapy and follow-up (B-741–B-750)

Moderators:  
*N. Al-Nakshabandi; Riyadh/SA*  
*J.C. Vilanova; Girona/ES*

## Head and Neck

### Friday, March 7, 08:30–10:00, Room R3

#### RC 108 Imaging of the orbit

Moderator:  
*B. Kreuzberg; Plzen/CZ*

- **A. Ocular pathology** (A-042)  
*N. Hosten; Greifswald/DE*
- **B. Extraocular orbital pathology** (A-043)  
*C. Czerny; Vienna/AT*
- **C. Extraorbital causes of diplopia** (A-044)  
*M.M. Lemmerling; Gent/BE*

### Friday, March 7, 10:30–12:00, Room G/H

#### SS 208 Lesion detection and characterisation (B-051 – B-060)

Moderators:  
*A. Borges; Lisbon/PT*  
*V. Vandecaveye; Leuven/BE*

**Friday, March 7, 14:00–15:30, Room G/H**

- SS 308 Tumors: Metastases and imaging in therapy**  
 (B-171 – B-180)  
 Moderators:  
*H.B. Eggesbø; Oslo/NO*  
*P. Piñero; Sevilla/ES*

**Friday, March 7, 16:00–17:30, Room N/O**

- RC 408 Head and neck imaging: A practical approach**  
 Moderator:  
*S. Robinson; Vienna/AT*
- **A. Inflammatory lesions** (A-078)  
*R. Maroldi; Brescia/IT*
  - **B. Traumatic lesions** (A-079)  
*M. Becker; Geneva/CH*
  - **C. Tumors** (A-080)  
*R. Hermans; Leuven/BE*

**Saturday, March 8, 14:00–15:30, Room G/H**

- SS 708 New approaches to examination techniques**  
 (B-381 – B-390)  
 Moderators:  
*R. Maroldi; Brescia/IT*  
*A. Trojanowska; Lublin/PL*

**Saturday, March 8, 16:00–17:30, Room N/O**

- RC 808 Imaging after treatment of head and neck tumors**  
 Moderator:  
*A. Trojanowska; Lublin/PL*
- **A. Tissue changes after treatment: The expected ones** (A-178)  
*R.D. Brüning; Hamburg/DE*
  - **B. Tumor recurrence and treatment complications: The feared ones** (A-179)  
*R.C. Sigal; Villejuif/FR*
  - **C. Imaging alterations due to denervation** (A-180)  
*A. Borges; Lisbon/PT*

**Monday, March 10, 08:30–10:00, Room F1**


- RC 1308 Imaging the thyroid and parathyroid**  
 Moderator:  
*M.G. Mack; Frankfurt a. Main/DE*
- **A. Clinical perspective and nuclear medicine** (A-308)  
*A. Kurtaran; Vienna/AT*
  - **B. Ultrasound and US-guided biopsy** (A-309)  
*N. Gritzmann; Salzburg/AT*
  - **C. CT and MRI** (A-310)  
*J.E. Kabala; Bristol/UK*

**Tuesday, March 11, 08:30–10:00, Room F1**

- RC 1708 What you always wanted to hear about hearing loss**  
 Moderator:  
*B.F. Schuknecht; Zurich/CH*
- **A. What the ENT surgeon wants to know from the radiologist** (A-450)  
*W. Gstöttner; Frankfurt a. Main/DE*
  - **B. Pathology of the external and middle ear** (A-451)  
*F. Veillon; Strasbourg/FR*
  - **C. Pathology of the inner ear** (A-452)  
*J.W. Casselman; Bruges/BE*

**Tuesday, March 11, 10:30–12:00, Room G/H**

- SS 1808 Skull base and temporal bone**  
 (B-761 – B-770)  
 Moderators:  
*R.B.-J. de Bondt; Maastricht/NL*  
*S. Kösling; Halle a.d. Saale/DE*



## Interventional Radiology

Friday, March 7, 10:30–12:00, Room R3

**SS 209 Vascular interventions (1)**  
 (B-121 – B-130)  
 Moderators:  
*B. Nemes; Budapest/HU*  
*S. Soimakallio; Tampere/FI*

Friday, March 7, 14:00–15:30, Room R3

**SS 309 Thoracic interventions**  
 (B-241 – B-250)  
 Moderators:  
*B.V. Czermak; Innsbruck/AT*  
*M. Köcher; Olomouc/CZ*

Friday, March 7, 16:00–17:30, Room R3

**RC 409 Endovascular treatment of aortoiliac occlusive disease: How far can interventional radiology go?**  
 Moderator:  
*A. Chatzizoiannou; Athens/GR*

- **A. Aortic bifurcation disease** (A-087)  
*G. O'Sullivan; Galway/IE*
- **B. Occlusions: Techniques, tips and tricks** (A-088)  
*E. Minar; Vienna/AT*
- **C. Trial results and TASC recommendations** (A-089)  
*J. Lammer; Vienna/AT*

Saturday, March 8, 10:30–12:00, Room F1

**SS 609a Spine** (B-271 – B-280)  
 Moderators:  
*D. Bilecen; Basle/CH*  
*A. Dimopoulou; Uppsala/SE*

Saturday, March 8, 10:30–12:00, Room R3

**SS 609b Liver: Embolisation**  
 (B-331 – B-340)  
 Moderators:  
*V. Bérczi; Budapest/HU*  
*T.J. Popiela; Kraków/PL*

Saturday, March 8, 14:00–15:30, Room F1

**SS 709a Radiofrequency ablation**  
 (B-371 – B-380)  
 Moderators:  
*T. de Baère; Villejuif/FR*  
*D. Kuhelj; Ljubljana/SI*

Saturday, March 8, 14:00–15:30, Room R3

**SS 709b Musculoskeletal intervention**  
 (B-451 – B-460)  
 Moderators:  
*M. Matson; London/UK*  
*P. Reimer; Karlsruhe/DE*

Saturday, March 8, 16:00–17:30, Room R3

**RC 809 Percutaneous interventions in musculoskeletal disease**  
 Moderator:  
*L. Pierot; Reims/FR*

- **A. Vertebroplasty and kyphoplasty** (A-187)  
*J. Blasco Andaluz; Barcelona/ES*
- **B. Discs and facet joints** (A-188)  
*A.D. Kelekis; Athens/GR*
- **C. Bone biopsy and RF ablation** (A-189)  
*A.D. Kelekis; Athens/GR*

Sunday, March 9, 10:30–12:00, Room R3

**SS 1009 Abdomen and pelvis**  
 (B-561 – B-570)  
 Moderators:  
*S. Fabiano; Rome/IT*  
*H.-M. Hoogewoud; Fribourg/CH*

Monday, March 10, 08:30–10:00, Room R3

**RC 1309 Interventions in non-malignant liver diseases**  
 Moderator:  
*K.A. Hausegger; Klagenfurt/AT*

- **A. Benign biliary disease** (A-335)  
*M. Glynos; Athens/GR*
- **B. Management of complications post liver transplantations** (A-336)  
*J.B. Karani; London/UK*
- **C. Interventions in the portal system** (A-337)  
*A. Krajina; Hradec Králové/CZ*

Monday, March 10, 10:30–12:00, Room R3

**SS 1409 Tumor ablation/Liver regeneration** (B-692 – B-700)  
 Moderators:  
*H.A. Deutschmann; Graz/AT*  
*I. Rozanes; Istanbul/TR*

**Monday, March 10, 14:00–15:30, Room R3**

**RC 1509 Treatment of acute hemorrhage**  
 Moderator:  
*J.E. Jackson; London/UK*

- **A. Hemoptysis** (A-385)  
*M. Szczerbo-Trojanowska; Lublin/PL*
- **B. Gastrointestinal hemorrhage** (A-386)  
*D.M. van Delden; Amsterdam/NL*
- **C. Posttraumatic hemorrhage** (A-387)  
*D. Pellerin; Paris/FR*

**Monday, March 10, 16:00–17:30, Room R3**

**RC 1609 Carotid interventions**  
 Moderator:  
*A. Basile; Catania/IT*

- **A. Patient selection and preprocedure imaging** (A-433)  
*S. MacDonald; Newcastle upon Tyne/UK*
- **B. Stenting technique, tips and tricks** (A-434)  
*L. Stockx; Genk/BE*
- **C. Results of stenting vs surgery trials** (A-435)  
*J.C. van den Berg; Lugano/CH*

**Tuesday, March 11, 08:30–10:00, Room R3**

**RC 1709 Update on endovascular aortic interventions**  
 Moderator:  
*C.C. Basekim; Istanbul/TR*

- **A. Abdominal aortic aneurysm** (A-481)  
*S. Müller-Hülsbeck; Kiel/DE*
- **B. Thoracic aortic aneurysm** (A-482)  
*G.J. Munneke; London/UK*
- **C. Aortic dissection** (A-483)  
*F. Fanelli; Rome/IT*

**Tuesday, March 11, 10:30–12:00, Room R3**

**SS 1809 Vascular interventions (2)**  
 (B-831 – B-840)  
 Moderators:  
*P.M. Bosnjakovic; Nis/RS*  
*I.P. Vulev; Bratislava/SK*

**Musculoskeletal**
**Friday, March 7, 08:30–10:00, Room E1**

**RC 110 Foot and ankle**  
 Moderator:  
*C. Faletti; Turin/IT*

- **A. Normal variants and MRI pitfalls** (A-011)  
*M. Zanetti; Zurich/CH*
- **B. Value and limitations of US** (A-012)  
*E.G. McNally; Oxford/UK*
- **C. Ankle trauma** (A-013)  
*M. Shahabpour-David; Brussels/BE*

**Friday, March 7, 10:30–12:00, Room B**

**SS 210 Peripheral nerves and muscle disorders** (B-001 – B-010)  
 Moderators:  
*R. Arkun; Izmir/TR*  
*M. Baramia; Tbilisi/GE*

**Friday, March 7, 14:00–15:30, Room B**


**SS 310 Spine and shoulder**  
 (B-131 – B-140)  
 Moderators:  
*M. Abd El Bagi; Riyadh/SA*  
*A. Siemianowicz; Piekary Slaskie/PL*

**Saturday, March 8, 10:30–12:00, Room B**

**SS 610 Hand, knee, feet**  
 (B-251 – B-260)  
 Moderators:  
*C. Masciocchi; L'Aquila/IT*  
*B. Forgács; Rotherham/UK*

**Saturday, March 8, 14:00–15:30, Room A**

**SS 710 Arthritis** (B-341 – B-350)  
 Moderators:  
*W.C.G. Peh; Singapore/SG*  
*P. Peloschek; Vienna/AT*



## Saturday, March 8, 16:00–17:30, Room E1

### RC 810 Osteoporosis

Moderator:  
*G. Kruminia; Riga/LV*

- **A. Bone densitometry: The essentials** (A-154)  
*G. Guglielmi; Foggia/IT*
- **B. Vertebral fractures: Definition, classification and significance** (A-155)  
*J.E. Adams; Manchester/UK*
- **C. MRI of osteoporotic insufficiency fractures** (A-156)  
*T.M. Link; San Francisco, CA/US*

## Sunday, March 9, 08:30–10:00, Room E1

### RC 910 Hip

Moderator:  
*H. Imhof; Vienna/AT*

- **A. Femoroacetabular impingement** (A-205)  
*S.E. Anderson; Berne/CH*
- **B. Femoral head edema** (A-206)  
*B. Vande Berg; Brussels/BE*
- **C. Sports injuries** (A-207)  
*M. Padrón; Madrid/ES*

## Sunday, March 9, 10:30–12:00, Room B

### SS 1010 Osteoporosis and hip disorders

(B-461 – B-470)  
Moderators:  
*J.L. Bloem; Leiden/NL*  
*A. Klauser; Innsbruck/AT*

## Sunday, March 9, 16:00–17:30, Room E1

### RC 1210 Spine

Moderator:  
*F. Lecouvet; Brussels/BE*

- **A. Bone tumors** (A-257)  
*V.N. Cassar-Pullicino; Oswestry/UK*
- **B. Infection** (A-258)  
*V. Jevtic; Ljubljana/SI*
- **C. The post-operative spine** (A-259)  
*J.W. van Goethem; Antwerp/BE*

## Monday, March 10, 08:30–10:00, Room E1

### RC 1310 Shoulder

Moderator:  
*E. Llopis; Valencia/ES*

- **A. Impingement** (A-304)  
*J. Kramer; Linz/AT*
- **B. Instability** (A-305)  
*P. Hughes; Plymouth/UK*
- **C. Superior labrum and biceps tendon lesions** (A-306)  
*K. Wörtler; Munich/DE*

## Monday, March 10, 10:30–12:00, Room A

### SS 1410 Cartilage

(B-571 – B-580)  
Moderators:  
*M.A. Cova; Trieste/IT*  
*V. Jevtic; Ljubljana/SI*

## Monday, March 10, 16:00–17:30, Room E1

### RC 1610 New trends in musculoskeletal radiology

Moderator:  
*A. Baur-Melnyk; Munich/DE*

- **A. Cartilage imaging** (A-401)  
*C. Glaser; Munich/DE*
- **B. Diffusion imaging and tractography** (A-402)  
*C. Khalil; Lille/FR*
- **C. MR contrast media** (A-403)  
*D. Weishaupt; Zurich/CH*

## Tuesday, March 11, 08:30–10:00, Room E1

### RC 1710 Extra-spinal interventional procedures

Moderator:  
*M. Breitenseher; Horn/AT*

- **A. Basic interventional procedures** (A-446)  
*G.K.D. Åström; Uppsala/SE*
- **B. Advanced interventional procedures** (A-447)  
*J.-L. Drapé; Paris/FR*
- **C. US-guided procedures** (A-448)  
*C. Martinoli; Genoa/IT*

**Tuesday, March 11, 10:30–12:00, Room A**

**SS 1810 Tumors and marrow disease**  
 (B-701 – B-710)  
 Moderators:  
*E.E. Drakonaki; Iraklion/GR*  
*A.R. Mester; Budapest/HU*

**Neuro**
**Friday, March 7, 08:30–10:00, Room G/H**

**RC 111 Stroke**  
 Moderator:  
*S. Pedraza; Girona/ES*

- **A. Cerebral vascular territories**  
 (A-021)  
*A. Urbanik; Krakow/PL*
- **B. Early signs on CT and MRI**  
 (A-022)  
*G. Krumina; Riga/LV*
- **C. The ischemic penumbra: Diagnosis and clinical impact**  
 (A-023)  
*E.-M. Law; New York, NY/US*

**Friday, March 7, 10:30–12:00, Room L/M**

**SS 211 CT – angiography and perfusion** (B-081 – B-090)  
 Moderators:  
*I.M. Björkman-Burtscher; Lund/SE*  
*J. Walecki; Warsaw/PL*

**Friday, March 7, 14:00–15:30, Room L/M**

**SS 311a Advanced spinal MRI**  
 (B-202 – B-210)  
 Moderators:  
*M. Sasiadek; Wroclaw/PL*  
*A. Urbanik; Krakow/PL*

**Friday, March 7, 14:00–15:30, Room N/O**

**SS 311b Brain tumors** (B-211 – B-220)  
 Moderators:  
*P.C. Maly Sundgren; Ann Arbor, MI/US*  
*T.A. Yousry; London/UK*

**Saturday, March 8, 10:30–12:00, Room L/M**

**SS 611 New vascular MR techniques**  
 (B-301 – B-310)  
 Moderators:  
*X. Leclerc; Lille/FR*  
*M.A. Lucic; Novi Sad/RS*

**Saturday, March 8, 14:00–15:30, Room N/O**

**SS 711 Grey and white matter**  
 (B-421 – B-430)  
 Moderators:  
*S.P. Morozov; Moscow/RU*  
*Z. Patay; Memphis, TN/US*

**Saturday, March 8, 16:00–17:30, Room G/H**

**RC 811 Basic MR**  
 Moderator:  
*P.H. Nakstad; Oslo/NO*

- **A. From signal to diagnosis: Basic interpretation of T1 and T2 behaviour of brain lesions**  
 (A-165)  
*G. Wilms; Leuven/BE*
- **B. Differential diagnosis of bright lesions on diffusion-weighted MR images** (A-166)  
*M.M. Thurnher; Vienna/AT*
- **C. Cortical anatomy on MR**  
 (A-167)  
*T.A. Yousry; London/UK*

**Sunday, March 9, 10:30–12:00, Room N/O**


**SS 1011 Functional MRI** (B-541 – B-550)  
 Moderators:  
*B. Göraj; Nijmegen/NL*  
*M. Stajgis; Poznan/PL*

**Sunday, March 9, 16:00–17:30, Room G/H**

**RC 1211 Imaging of vascular brain disease**  
 Moderator:  
*R. Gasparotti; Brescia/IT*

- **A. Spontaneous intracerebral haemorrhage** (A-269)  
*P.M. Parizel; Antwerp/BE*
- **B. Chronic vascular diseases**  
 (A-270)  
*M.A. van Buchem; Leiden/NL*
- **C. Cerebral venous thrombosis**  
 (A-271)  
*L. Biscoito; Lisbon/PT*





## Monday, March 10, 08:30–10:00, Room G/H

### RC 1311 Pediatric neuroradiology

Moderator:  
Z. Merhemic; Sarajevo/BA

- **A. Migration disorders** (A-314)  
P. Demaerel; Leuven/BE
- **B. CNS infections** (A-315)  
P.C. Maly Sundgren;  
Ann Arbor, MI/US
- **C. Congenital brain tumors**  
(A-316)  
A. Rossi; Genoa/IT

## Monday, March 10, 10:30–12:00, Room N/O

### SS 1411 MRI at 7 T (B-661 – B-670)

Moderators:  
M. Cirillo; Naples/IT  
E.-M.B. Larsson; Aalborg/DK

## Monday, March 10, 14:00–15:30, Room G/H

### RC 1511 Brain tumors

Moderator:  
J. Rusalleda; Barcelona/ES

- **A. Pituitary lesions** (A-364)  
F. Bonneville; Paris/FR
- **B. Primary brain tumors**  
(A-365)  
S. Karampekios; Iraklion/GR
- **C. Pseudo-tumoral lesions: Diagnosis and differential diagnosis** (A-366)  
C.F. Andreula; Bari/IT

## Monday, March 10, 16:00–17:30, Room G/H

### RC 1611 Grey and white matter disease

Moderator:  
H.R. Jäger; London/UK

- **A. Demyelinating diseases**  
(A-413)  
E.-W. Radü; Basle/CH
- **B. Dementia** (A-414)  
B. Gómez-Ansón; Barcelona/ES
- **C. Brain and meningeal infections** (A-415)  
E.T. Tali; Ankara/TR

## Tuesday, March 11, 08:30–10:00, Room G/H

### RC 1711 Interventional neuroradiology

Moderator:  
G. Pellicanò; Florence/IT

- **A. Management of the non-ruptured intracranial aneurysm**  
(A-457)  
T. Krings; Aachen/DE
- **B. Intracranial stenting** (A-458)  
I. Szikora; Budapest/HU
- **C. Intracranial trombectomy**  
(A-459)  
R. Chapot; Essen/DE

## Tuesday, March 11, 10:30–12:00, Room N/O

### SS 1811 Epilepsy and development issues (B-801 – B-810)

Moderators:  
A. Cianfoni; Rome/IT  
J.M. García Santos; Murcia/ES

## Pediatric

## Saturday, March 8, 14:00–15:30, Room K

### SS 712 Fetal imaging (B-401 – B-410)

Moderators:  
C. Balassy; Vienna/AT  
V. Donoghue; Dublin/IE

## Sunday, March 9, 10:30–12:00, Room K

### SS 1012 Chest and abdomen

(B-521 – B-530)  
Moderators:  
A. Paterson; Belfast/UK  
B. Silberman; Paris/FR

## Sunday, March 9, 16:00–17:30, Room K

### RC 1212 Gastrointestinal tract

Moderator:  
M. Hiorns; London/UK

- **A. Gastrointestinal emergencies** (A-275)  
E. Beek; Utrecht/NL
- **B. Inflammatory bowel disease**  
(A-276)  
J.P. Pracros; Lyon/FR
- **C. Biliary tract** (A-277)  
M. Rasero; Madrid/ES

**Monday, March 10, 08:30–10:00, Room K**
**RC 1312 Chest imaging**

Moderator:  
*P. Tomà; Genoa/IT*

- **A. Neonatal chest diseases**  
(A-320)  
*M.P. García-Peña; Barcelona/ES*
- **B. Acute chest diseases**  
(A-321)  
*J. Fonseca-Santos; Lisbon/PT*
- **C. Foreign body aspiration and ingestion** (A-322)  
*K. Darge; Würzburg/DE*

**Monday, March 10, 14:00–15:30, Room K**
**RC 1512 Neuro imaging**

Moderator:  
*S. Cakirer; Istanbul/TR*

- **A. State-of-the-art neurosonography** (A-370)  
*C. Veyrac; Montpellier/FR*
- **B. Neurotrauma** (A-371)  
*C. Christophe; Brussels/BE*
- **C. MR of the hypothalamo-pituitary axis** (A-372)  
*M.I. Argyropoulou; Ioannina/GR*

**Monday, March 10, 16:00–17:30, Room K**
**RC 1612 Safety considerations in imaging**

Moderator:  
*R. Fötter; Graz/AT*

- **A. Dose reduction** (A-419)  
*C. Owens; London/UK*
- **B. MR friendly: Safety and techniques adapted to children** (A-420)  
*D.E. Olsen; London/UK*
- **C. Anesthesia and sedation in pediatric imaging** (A-421)  
*F. De Groot; Brussels/BE*

**Tuesday, March 11, 08:30–10:00, Room K**
**RC 1712 Trauma**

Moderator:  
*J.-F. Chateil; Bordeaux/FR*

- **A. Abdominal trauma**  
(A-463)  
*G. Staatz; Erlangen/DE*
- **B. Renal trauma** (A-464)  
*J.-N. Dacher; Rouen/FR*
- **C. The limping child**  
(A-465)  
*C.J. Kellenberger; Zurich/CH*

**Tuesday, March 11, 10:30–12:00, Room K**
**SS 1812 Advances in CT and MRI**

(B-781 – B-790)  
Moderators:  
*S. Chapman; Birmingham/UK*  
*R.R. van Rijn; Amsterdam/NL*

**Physics in Radiology**
**Saturday, March 8, 10:30–12:00, Room I**
**SS 613 Radiation dose in CT**

(B-291 – B-300)  
Moderators:  
*N. Marshall; London/UK*  
*P. Vock; Berne/CH*


**Saturday, March 8, 14:00–15:30, Room I**
**SS 713 New approaches in MRI**

(B-391 – B-400)  
Moderators:  
*A. Del Guerra; Pisa/IT*  
*O. Dietrich; Munich/DE*

**Sunday, March 9, 08:30–10:00, Room I**
**RC 913 MR-guided cardiovascular interventions**

Moderators:  
*J. Bittoun; Le Kremlin-Bicêtre/FR*  
*C. Thomsen; Copenhagen/DK*

- **A. Instrument visualisation techniques** (A-218)  
*H.H. Quick; Essen/DE*
- **B. Endovascular applications** (A-219)  
*F.K. Wacker; Berlin/DE*
- **C. Cardiac applications** (A-220)  
*E. Atalar; Ankara/TR*



## Sunday, March 9, 10:30–12:00, Room I

**SS 1013 Dose, risk assessment and optimisation** (B-511 – B-520)  
Moderators:  
*F.R. Verdun; Lausanne/CH*  
*U. Zdesar; Ljubljana/SI*

## Sunday, March 9, 16:00–17:30, Room I

**RC 1213 Physics and technology of multi-modality imaging systems**  
Moderators:  
*A. Bockisch; Essen/DE*  
*M. Gambaccini; Ferrara/IT*

- **A. CT-PET** (A-272)  
*A.A. Lammertsma; Amsterdam/NL*
- **B. CT-SPECT** (A-273)  
*T. Kuwert; Erlangen/DE*
- **C. MR-PET** (A-274)  
*R. Krieg; Erlangen/DE*

## Monday, March 10, 08:30–10:00, Room I

**RC 1313 Quality control and dose reduction in digital radiology**  
Moderators:  
*A. Lisbona; Saint-Herblain/FR*  
*O. Ratib; Geneva/CH*

- **A. Principles of flat panel detectors** (A-317)  
*N. Marshall; London/UK*
- **B. Managing patient dose** (A-318)  
*E. Vaño; Madrid/ES*
- **C. Quality assurance** (A-319)  
*H.-P. Busch; Trier/DE*

## Monday, March 10, 10:30–12:00, Room I

**SS 1413 New advances in imaging techniques and applications** (B-631 – B-640)  
Moderators:  
*T.G. Maris; Iraklion/GR*  
*W.J.M. van der Putten; Galway/IE*

## Monday, March 10, 14:00–15:30, Room I

**RC 1513 Managing patient dose**  
Moderators:  
*W. Burkart; Vienna/AT*  
*M. Raissaki; Iraklion/GR*

- **A. In diagnostic radiology** (A-367)  
*K. Faulkner; Wallsend/UK*
- **B. In interventional radiology** (A-368)  
*R. Padovani; Udine/IT*
- **C. In nuclear medicine** (A-369)  
*S. Christofides; Nicosia/CY*

## Monday, March 10, 16:00–17:30, Room I

**RC 1613 Monitor reporting: Quality and diagnostic accuracy**  
Moderators:  
*C. Leidecker; Malvern, PA/US*  
*S. Wirth; Munich/DE*

- **A. Display system requirements for full field digital mammography: FDA perspective** (A-416)  
*K. Chakrabarti; Rockville, MD/US*
- **B. MoniQA: Software for monitor QA** (A-417)  
*H. Bosmans; Leuven/BE*
- **C. Cost effectiveness of monitor reporting** (A-418)  
*M.G. Wallis; Coventry/UK*

## EFOMP Workshop

**Saturday, March 8, 08:30–12:00**

### **New technology in diagnostic radiology: High field MRI for clinical and preclinical studies**

Organising Committee:

Chairman:

*A. Del Guerra; Pisa/IT*

Members:

*S. Christofides; Nicosia/CY*

*G.P. Krestin; Rotterdam/NL*

*W. Schlegel; Heidelberg/DE*

*M. Tosetti; Pisa/IT*

**Saturday, March 8, 08:30–10:00, Room G/H**

### **EF 1 State-of-the-art of high field MRI instrumentation**

Moderators:

*S. Christofides; Nicosia/CY*

*M. Tosetti; Pisa/IT*

- **Welcome address**  
*M.F. Reiser; Munich/DE*  
*S. Christofides; Nicosia/CY*
- **High field clinical MRI: Instrumentation and methods** (A-111)  
*R. Turner; Leipzig/DE*
- **Pre-clinical studies with high field and very high field MRI: What is available, what is needed?** (A-112)  
*S. Aime; Turin/IT*
- **PET-MRI combined modalities for pre-clinical and clinical studies** (A-113)  
*A. Carpenter; Cambridge/UK*

**Saturday, March 8, 10:30–12:00, Room G/H**

### **EF 2 Clinical applications, safety issues and regulations for very high field MRI**

Moderators:

*S. Christofides; Nicosia/CY*

*G.P. Krestin; Rotterdam/NL*

- **Safety issues and regulations for high field MRI** (A-137)  
*M. Ladd; Essen/DE*

- **Physical implications of a 7 Tesla MRI installation**

(A-138)

*O. Speck; Magdeburg/DE*

- **Future impact of the 7 Tesla MRI in the clinical applications**

(A-139)

*R.W. Bowtell; Nottingham/UK*

## Radiographers

**Sunday, March 9, 08:30–10:00, Room L/M**

### **RC 914 MRI**

Moderators:

*C. Garvey; Liverpool/UK*

*K. Thanassoulas; Athens/GR*

- **A. Advanced neuro imaging**

(A-226)

*N. Delikanakis; Athens/GR*

- **B. Artifacts in clinical MRI: Identification and correction**

(A-227)

*J. Castillo; Msida/MT*

**Sunday, March 9, 10:30–12:00, Room L/M**

### **SS 1014 Development of the professional role**

(B-531 – B-540)

Moderators:

*L. Dalla Palma; Trieste/IT*

*I.-H. Tassiopoulos; Athens/GR*

**Sunday, March 9, 16:00–17:30, Room L/M**

### **RC 1214 Professional profile developments: The extended role of the radiographer**

Moderators:

*G.A. Marshall; Lancaster/UK*

*C. Roche; Galway/IE*

- **A. Changing roles in the 21<sup>st</sup> century: Reporting, research, management, consultants**

(A-278)


*A. Paterson; London/UK*

- **B. The Norwegian Radiography Research Group** (A-279)

*B. Strøm; Bergen/NO*

- **C. Radiology informatics: A new research area** (A-280)

*N. Lundberg; Stockholm/SE*



## Monday, March 10, 08:30–10:00, Room L/M

### RC 1314 Trauma

Moderators:

*A.M. Davies; Birmingham/UK  
J. Nicklin; Poole/UK*

- **A. Introducing digital radiography into the trauma unit** (A-323)  
*H. Harries-Jones; Poole/UK*
- **B. Emergency radiographer: An emerging role** (A-324)  
*B. Snaith; Wakefield/UK*

## Monday, March 10, 10:30–12:00, Room L/M

### SS 1414 Dose reduction strategies

(B-651–B-660)

Moderators:

*L. Lönn; Copenhagen/DK  
S. Willis; Exeter/UK*

## Monday, March 10, 14:00–15:30, Room L/M

### RC 1514 Computed tomography: CT and contrast media

Moderators:

*S. Huber; Munich/DE  
H. Ringertz; Stanford, CA/US*

- **A. Optimising CM injection protocols in MDCT: Is faster always better?** (A-373)  
*E. Agadakos; Athens/GR*
- **B. The patterns of contrast enhancement of vessels and tissues related to the parameters of intravenous injection of CM** (A-374)  
*A. Lukken; Tartu/EE*

## Monday, March 10, 16:00–17:30, Room L/M

### RC 1614 Non medical applications

Moderators:

*I. Isherwood; Manchester/UK  
M. Jökel; Hamburg/DE*

- **A. Imaging in archaeology** (A-422)  
*P. Pipan; Trieste/IT*
- **B. Imaging in art** (A-423)  
*P. Gerson; Paris/FR*

## Vascular

### Friday, March 7, 08:30–10:00, Room I

#### RC 115 Non-invasive vascular imaging

Moderator:

*M.I. Furmanek; Warsaw/PL*

- **A. Whole body MRA** (A-024)  
*S.G. Ruehm; Los Angeles, CA/US*
- **B. Whole body CTA** (A-025)  
*A. Napoli; Rome/IT*
- **C. Is there a role for catheter angiography?** (A-026)  
*D.K. Tsetis; Iraklion/GR*

### Friday, March 7, 10:30–12:00, Room I

#### SS 215 Carotid imaging

(B-061–B-070)

Moderators:

*R.A. Bucek; Vienna/AT  
M.W. de Haan; Maastricht/NL*

### Friday, March 7, 14:00–15:30, Room I

#### SS 315 CT angiography

(B-181–B-190)

Moderators:

*L. Boyer; Clermont-Ferrand/FR  
J. Ferda; Plzen/CZ*

### Friday, March 7, 16:00–17:30, Room I

#### RC 415 Imaging in carotid disease

Moderator:

*A.L.J. Bojanovic; Nis/RS*

- **A. Ultrasound** (A-069)  
*N. Liasis; Athens/GR*
- **B. MRA and CTA** (A-070)  
*N. Anzalone; Milan/IT*
- **C. Plaque imaging** (A-071)  
*M. Lell; Erlangen/DE*

### Saturday, March 8, 14:00–15:30, Room L/M

#### SS 715 MR angiography

(B-411–B-420)

Moderators:

*I. Bargellini; Pisa/IT  
S.G. Ruehm; Los Angeles, CA/US*

**Saturday, March 8, 16:00–17:30, Room I**

**RC 815 Non-invasive imaging of the lower limb venous system**  
 Moderator:  
*P.M.T. Patyngama; Rotterdam/NL*

- **A. Anatomy and physiology: Correlation with imaging** (A-168)  
*V. Bérczi; Budapest/HU*
- **B. Sonography: Clinical applications and results** (A-169)  
*N. Grenier; Bordeaux/FR*
- **C. CTA and MRA: Is there a role?** (A-170)  
*B. Ghaye; Liège/BE*

**Monday, March 10, 10:30–12:00, Room K**

**SS 1415 MR: Angiography, micro-circulation and lymphography** (B-641 – B-650)  
 Moderators:  
*F. De Cobelli; Milan/IT*  
*R.W. Günther; Aachen/DE*

**Tuesday, March 11, 08:30–10:00, Room I**

**RC 1715 Imaging of critical limb ischemia**  
 Moderator:  
*M.-S. Grammenou-Pomoni; Athens/GR*

- **A. Sonography: Just time consuming?** (A-460)  
*R. Uberoi; Oxford/UK*
- **B. MRA: Tips to improve results** (A-461)  
*J.F.M. Meaney; Dublin/IE*
- **C. MDCT: Just too many images?** (A-462)  
*G.D. Rubin; Stanford, CA/US*

**Tuesday, March 11, 10:30–12:00, Room I**

**SS 1815 Therapy, evaluation and outcome** (B-771–B-780)  
 Moderators:  
*M. Heller; Kiel/DE*  
*P. Vilela; Almada/PT*

**E<sup>3</sup> – European Excellence in Education Foundation Course: Interventional Radiology**
**Friday, March 7, 08:30–10:00, Room E2**

**E<sup>3</sup> 120a Arteries**  
 Moderator:  
*J. Kettenbach, Vienna/AT*

- **A. How to treat superficial femoral artery stenosis** (A-014)  
*H.-J. Wagner; Berlin/DE*
- **B. How and when to use renal artery stents** (A-015)  
*J.H. Peregrin; Prague/CZ*

**Friday, March 7, 10:30–12:00, Room E2**

**E<sup>3</sup> 220 Veins**  
 Moderator:  
*R. Morgan; London/UK*

- **A. Common problems with dialysis fistulae** (A-045)  
*D. Vorwerk; Ingolstadt/DE*
- **B. How to deal with vascular malformations** (A-046)  
*A. Martinez de la Cuesta; Pamplona/ES*

**Friday, March 7, 14:00–15:30, Room E2**

**E<sup>3</sup> 320 Gastrointestinal tract**  
 Moderator:  
*T. Pfammatter; Zurich/CH*

- **A. Colonic stenting** (A-047)  
*J. Medrano; Zaragoza/ES*
- **B. Management of gastrointestinal bleeding: A starter kit** (A-048)  
*E. Brountzos; Athens/GR*


**Friday, March 7, 16:00–17:30, Room E2**

**E<sup>3</sup> 420a Genitourinary**  
 Moderator:  
*I.S. Kaskarelis; Athens/GR*

- **A. Percutaneous nephrostomy** (A-058)  
*D. Akhan; Ankara/TR*
- **B. Uterine fibroids** (A-059)  
*J.-P. Pelage; Boulogne/FR*



Interactive session with electronic voting self assessment



## Saturday, March 8, 08:30–10:00, Room E2

E<sup>3</sup> 520a

### Liver tumors

Moderator:

*R. Lencioni; Pisa/IT*



- **A. Percutaneous treatments** (A-103)  
*L. Solbiati; Busto Arsizio/IT*
- **B. Endovascular treatments** (A-104)  
*F. Orsi; Milan/IT*

## Saturday, March 8, 10:30–12:00, Room E2

E<sup>3</sup> 620

### Musculoskeletal

Moderator:

*J.-I. Bilbao; Pamplona/ES*



- **A. Traumatic hemorrhage** (A-135)  
*A. Nicholson; Leeds/UK*
- **B. Vertebroplasty** (A-136)  
*A. Gangi; Strasbourg/FR*

## Saturday, March 8, 12:15–13:15, EPOS area

### Self assessment test: Interactive computer evaluation of course learning

Moderator:

*J.-I. Bilbao; Pamplona/ES*



## E<sup>3</sup> – European Excellence in Education Interactive Teaching Course: Useful Signs in Imaging

### Friday, March 7, 16:00–17:30, Room F1

E<sup>3</sup> 420b

### Signs in neuroradiology and in head and neck imaging

Moderator:

*J.A. Castellijns; Amsterdam/NL*



- **A. Neuro** (A-060)  
*I.M. Björkman-Burtscher; Lund/SE*
- **B. Head and neck** (A-061)  
*S.J. Golding; Oxford/UK*

## Saturday, March 8, 14:00–15:30, Room E2

E<sup>3</sup> 720

### Signs in abdominal imaging

Moderator:

*S.C. Efremidis; Ioannina/GR*



- **A. Abdomen: Viscera** (A-141)  
*F. Caseiro-Alves; Coimbra/PT*
- **B. Abdomen: GI** (A-142)  
*P. Rogalla; Berlin/DE*

## Saturday, March 8, 16:00–17:30, Room E2

E<sup>3</sup> 820

### Signs in genitourinary imaging

Moderator:

*G. Heinz-Peer; Vienna/AT*



- **A. Retroperitoneum** (A-157)  
*P. Soffia; Santiago/CL*
- **B. Pelvis** (A-158)  
*R. Pozzi-Mucelli; Verona/IT*

## Sunday, March 9, 10:30–12:00, Room E2

E<sup>3</sup> 1020

### Signs in chest imaging

Moderator:

*J.A. Verschakelen; Leuven/BE*



- **A. Lungs** (A-244)  
*J. Cáceres; Barcelona/ES*
- **B. Mediastinum and pleura** (A-245)  
*G.J. Herold; Vienna/AT*

## Sunday, March 9, 16:00–17:30, Room E2

E<sup>3</sup> 1220

### Signs in musculoskeletal imaging

Moderator:

*K. Bohndorf; Augsburg/DE*



- **A. Axial skeleton** (A-260)  
*A.H. Karantanas; Iraklion/GR*
- **B. Extremities** (A-261)  
*F.M.H.M. Vanhoenacker; Antwerp/BE*



Interactive session with electronic voting self assessment

## E<sup>3</sup> – European Excellence in Education Interactive Teaching Sessions

**Friday, March 7, 08:30–10:00, Room F1**

**E<sup>3</sup> 120b The imaging management of breast cancer** (A-016)

Moderator:  
*R.C.Otto; Baden/CH*

*J. Camps-Herrero; Valencia/ES*  
*M. Locatelli; Gorizia/IT*



**Saturday, March 8, 08:30–10:00, Room F1**

**E<sup>3</sup> 520b Prostate cancer: Meeting clinical needs by MRI at diagnosis and on follow-up** (A-105)

Moderator:  
*É. Breatnach; Dublin/IE*

*A.R. Padhani; Northwood/UK*  
*A. Graser; Munich/DE*



**Sunday, March 9, 08:30–10:00, Room E2**

**E<sup>3</sup> 920a Classifying breast lesions: The BI-RADS™ exercise** (A-208)

Moderator:  
*M.G. Wallis; Coventry/UK*

*I. Tocino; New Haven, CT/US*  
*C.S. Balleyguier; Villejuif/FR*



**Sunday, March 9, 08:30–10:00, Room F1**

**E<sup>3</sup> 920b Inflammatory small bowel diseases** (A-209)

Moderator:  
*A. Laghi; Latina/IT*

*N. Gourtsoyiannis; Iraklion/GR*  
*S.D. Yarmenitis; Iraklion/GR*



**Monday, March 10, 08:30–10:00, Room E2**

**E<sup>3</sup> 1320 The imaging management of lung cancer** (A-307)

Moderator:  
*G.H. Mostbeck; Vienna/AT*

*J. Cáceres; Barcelona/ES*  
*J. Vilar; Valencia/ES*



**Monday, March 10, 10:30–12:00, Room E2**

**E<sup>3</sup> 1420 The imaging management of stroke** (A-338)

Moderator:  
*P.M. Parizel; Antwerp/BE*

*A. Rovira-Cañellas; Barcelona/ES*  
*T. Krings; Aachen/DE*



**Monday, March 10, 14:00–15:30, Room E2**

**E<sup>3</sup> 1520 The imaging management of back pain** (A-357)

Moderator:  
*D.J. Wilson; Oxford/UK*

*V.N. Cassar-Pullicino; Oswestry/UK*  
*F. Aparisi; Valencia/ES*



**Monday, March 10, 16:00–17:30, Room E2**

**E<sup>3</sup> 1620 Traps in imaging of cirrhosis and portal hypertension** (A-404)

Moderator:  
*M. Escobar; Barcelona/ES*

*Y. Menu; Le Kremlin-Bicêtre/FR*  
*A. Besim; Ankara/TR*



**Tuesday, March 11, 08:30–10:00, Room E2**

**E<sup>3</sup> 1720 Detection and diagnosis of interstitial lung diseases** (A-449)

Moderator:  
*J. Andreu; Barcelona/ES*

*S.R. Desai; London/UK*  
*S.P.G. Padley; London/UK*



## E<sup>3</sup> – European Excellence in Education Breast Imaging

**Tuesday, March 11, 10:30–12:00, Room E2**

**E<sup>3</sup> 1820 BI-RADS™ – Olympics** (A-484)


Moderators:  
*T.H. Helbich; Toronto, ON/CA*  
*K. Kinkel; Chêne-Bougeries/CH*

- **Chairman's Introduction**  
*T.H. Helbich; Toronto, ON/CA*
- **Mammography and ultrasound**  
*T.H. Helbich; Toronto, ON/CA*
- **MR imaging**  
*K. Kinkel; Chêne-Bougeries/CH*



Interactive session with electronic voting self assessment





## Radiology Trainees Forum

The Radiology Trainees Forum promotes and coordinates the efforts of radiology trainees at a European level in order to improve the progress of radiology and related sciences. Apart from that, one of RTF's most important goals is to provide an equal level of radiological knowledge and skills for radiology trainees all over Europe.

The RTF Board cordially invites all trainees to attend RTF events at the upcoming ECR:

### Saturday, March 8, 16:00–17:30, Room K

#### RTF Highlighted Lectures

Moderators:

*P.R. Kornaat; Leiden/NL*

*C. Nyhsen; Sunderland/UK*

- **Always hypertension? What else can be the cause of intracerebral hemorrhage**

*(A-171)*

*M. Forsting; Essen/DE*

- **Vascular interventions today: Challenges and opportunities**

*(A-172)*

*J.A. Reekers; Amsterdam/NL*

- **Pitfalls in trauma imaging**

*(A-173)*

*N. Raby; Glasgow/UK*

### Saturday, March 8, 19:30

#### RTF Cocktail

Restaurant Barbaro

Neuer Markt 8, 1010 Vienna

Admittance free for trainees.

Registration required.

### Sunday, March 9, 16:30–18:00

#### RTF – General Assembly

Visit us at the RTF booth on the entrance level in the Austria Center!

## Image Guided Breast Biopsy: How to do it

**Coordinators:** *C.S. Balleyguier; Villejuif/FR  
T.H. Helbich; Toronto, ON/CA*

**Speakers:** *C. Boetes; Nijmegen/NL  
T.H. Helbich; Toronto, ON/CA  
I. Schreer; Kiel/DE*

**Instructors:** *G. Esen; Istanbul/TR  
M.H. Fuchsjäger; Vienna/AT  
L. Levy; Paris/FR  
M. Locatelli; Gorizia/IT  
R. Salvador; Barcelona/ES*

The workshop is organised to provide participants with an introduction to the most important issues in percutaneous imaging-guided biopsy of breast lesions under stereotactic and ultrasound guidance.

Percutaneous imaging-guided needle biopsy has increasingly become an alternative to surgical biopsy for the histologic assessment of breast lesions. Percutaneous biopsy is faster, less invasive and less expensive than surgical biopsy. Tissue acquisition is performed with automated large core needles or directional vacuum-assisted biopsy probes. In some instances, cytology is helpful, but requires a strong collaboration with a trained pathologist. Guidance for percutaneous biopsy is usually provided by stereotaxis and ultrasound. In the near future, MRI may play a significant role, especially in high risk patients. Imaging guidance depends on lesion type and the results of diagnostic imaging studies. This workshop reviews indications, advantages, limitations and controversial issues in percutaneous imaging-guided biopsy of breast lesions under stereotactic and ultrasound guidance. Participants will work on phantoms to learn how to hit a lesion or, for the more experienced, how to improve their personal 'hit rate'.

Participants will have the opportunity to attend a series of lectures on the most important issues. Then, during practical sessions, they will be instructed how to perform breast biopsy under stereotactic and ultrasound guidance. State-of-the-art equipment will be available, including different automated large core needles and/or directional vacuum-assisted biopsy probes, and sessions will be arranged to allow time for each participant to perform examinations under supervision.

Participants are required to attend the complete workshop.

### Learning Objectives:

1. To learn indications, advantages, limitations and controversial issues (e.g. cytology vs. histology) in percutaneous imaging-guided biopsy of breast lesions under stereotactic, US and MRI guidance.
2. To learn how to perform breast biopsy under US guidance.
3. To learn how to perform breast biopsy under stereotactic guidance.
4. To learn the potential advantages and limits of MR guided biopsy.
5. To learn which technique should be preferably used (automated large core needles or directional vacuum-assisted biopsy probes).

### Registration:

The number of participants for each session is limited.

Pre-registrations have been arranged according to the order in which they were received. Registration is possible onsite, though all seats may be occupied by then. Please register in front of room U, 20 minutes before the sessions begin. Please note that an extra fee of € 30, - per participant is charged for this workshop.

Attendance at the lecture session on Saturday morning is mandatory to participate in the two pre-registered hands-on workshops.

### Time Schedule:

#### Saturday, March 8

WS 521	08:30–10:00	Lecture
WS 621	10:30–12:00	US biopsy
WS 721	14:00–15:30	Stereotactic guidance

#### Sunday, March 9

WS 921	08:30–10:00	Stereotactic guidance
WS 1021	10:30–12:00	US biopsy
WS 1121	14:00–15:30	Stereotactic guidance

#### Monday, March 10

WS 1321	08:30–10:00	Stereotactic guidance
WS 1421	10:30–12:00	US biopsy
WS 1521	14:00–15:30	Stereotactic guidance
WS 1621	16:00–17:30	Stereotactic guidance

All workshops will take place in room U (2<sup>nd</sup> level)



## Experience Vascular Procedures Using Simulators

*Kindly supported by CIRSE*

**Coordinator:** *T. Sabharwal; London/UK*  
**Instructors:** *E. Brountzos; Athens/GR*  
*F. Fanelli; Rome/IT*  
*N. Fotiadis; London/UK*  
*M. Glynos; Athens/GR*  
*P. Goutzios; Athens/GR*  
*P. Haage; Wuppertal/DE*  
*M. Hamady; London/UK*  
*F. Irani; London/UK*  
*S. MacDonald;*  
*Newcastle upon Tyne/UK*  
*R. Morgan; London/UK*  
*S. Punamiya; Mumbai/IN*  
*M. Sapoval; Paris/FR*  
*H.-J. Wagner; Berlin/DE*

This workshop aims to expose participants to a developing new paradigm in interventional training – the use of computerised medical simulators.

Training in interventional catheter-based procedures, especially with the increasing use of non-invasive imaging, has made it difficult for doctors to become skilled. Patients can experience pain, and be at increased risk during the trainee's learning phase for a new instrument or technique. The simulator attempts to reproduce the physics and physiology of the human cardiovascular system. Various procedures – such as diagnostic angiography, angioplasty, and stenting (renals, carotids, subclavians and peripherals) – can in theory be learnt prior to performing on patients. What we know today is that these simulator models can provide the participant with an opportunity to experience, and probably learn, the various steps of a procedure – choosing appropriate catheters, wires, stents, and angles of fluoroscopy rotation.

All this learning is without the use of X-rays, exposure to blood, or pain/danger to patients!

Come and see the future in vascular interventional training and test your skills!

### Learning Objectives:

1. To get exposure to medical simulator machines.
2. To experience the procedural steps of catheter-based intervention on simulator machines (carotid stenting, renal stenting, peripheral stenting).
3. By the end of the workshop the participants should have a good understanding of medical simulator machines and have performed the theoretical steps for arterial stenting as it would be in patients.

### Target Group

Trainees and consultants with an interest in learning interventional catheter-based procedures in radiology.

### Registration

The number of participants for each session is limited.

Pre-registrations have been arranged according to the order in which they were received. Registration is possible onsite, though all seats may be occupied by then. Please register in front of room X, 20 minutes before the sessions begin. Please note that an extra fee of € 30, - per participant is charged for this workshop.

### Time Schedule

#### Friday, March 7

WS 222	10:30–12:00	Carotids
WS 322	14:00–15:30	Renals/Peripherals

#### Saturday, March 8

WS 622	10:30–12:00	Carotids
WS 722	14:00–15:30	Renals/Peripherals

#### Sunday, March 9

WS 1022	10:30–12:00	Carotids
WS 1122	14:00–15:30	Renals/Peripherals

All workshops will take place in room X (2<sup>nd</sup> level)

## Tips and Tricks in Radiofrequency Ablation

**Coordinator:** *R. Lencioni; Pisa/IT*

**Instructors:** *E. Bozzi; Pisa/IT*

*C. Bru; Barcelona/ES*

*A. Gangi; Strasbourg/FR*

*A.R. Gillams; London/UK*

*T.K. Helmberger; Munich/DE*

*R.-T. Hoffmann; Munich/DE*

*Y. Ni; Leuven/BE*

*L. Solbiati; Busto Arsizio/IT*

The workshop will be held in four sessions (two basic and two advanced) of 90 minutes each and is limited to a maximum of 30 participants per session. Basic workshops will be focused on principles and techniques for radiofrequency ablation as well as on practical clues for its clinical application in liver tumor treatment ('what you need to know to start'). Advanced workshops will present more complex techniques for liver ablation as well as tips and tricks to approach lung, kidney, and bone tumors.

Each workshop will include a theoretical part of 45 minutes with case presentations, followed by a 45 minutes 'hands-on' part with ultrasound-guided ablations in cow livers by using different RF generators and electrodes.

### Learning Objectives

1. To describe approaches and methods that can improve outcome or decrease the chance of complications in liver, lung, kidney and bone RF ablation.
2. To learn how to handle different equipment and electrodes available for RF ablation.
3. By the end of the workshop the participants should have a good understanding of the spectrum of RF techniques and be aware of some key clues for proper clinical application.

### Registration

The number of participants for each session is limited.

Pre-registrations have been arranged according to the order in which they were received. Registration is possible onsite, though all seats may be occupied by then. Please register in front of room XI (for Basic) or room Z (for Advanced), 20 minutes before the sessions begin. Please note that an extra fee of € 30, - per participant is charged for this workshop.

Participants are asked to meet in front of room XI (for Basic) or room Z (for Advanced), 10 minutes before the sessions begin.

### Time Schedule

#### Saturday, March 8

WS 623 10:30–12:00 Basic

Room XI and Y (2<sup>nd</sup> level)

WS 723 14:00–15:30 Advanced

Room Z and Y (2<sup>nd</sup> level)


#### Sunday, March 9

WS 1023 10:30–12:00 Basic

Room XI and Y (2<sup>nd</sup> level)

WS 1123 14:00–15:30 Advanced

Room Z and Y (2<sup>nd</sup> level)



## Test-Driving your Workstation

**Coordinators:** *D. Caramella; Pisa/IT*  
*W.J. Niessen; Rotterdam/NL*  
*B.M. ter Haar Romeny;*  
*Eindhoven/NL*

**Speakers:** *W.J. Niessen; Rotterdam/NL*  
*H.-O. Peitgen; Bremen/DE*  
*P. Suetens; Leuven/BE*

Diagnostic workstations are the 'super-assistants' of the modern radiologist. Each year, new applications are added to the repertoire. The radiological end-user not only has the responsibility to deliver quality work to his/her patient, he/she also has the responsibility to understand what is under the hood of the programme ('how does it actually work?'). He/she should be able to judge the relative merits of the applications, by comparing different solutions, and estimate the importance of constraints, like the number of false-positives in CAD, the error sources in quantitative analysis, and object definition problems in 3D visualisations.

This workshop gives a state-of-the-art overview, focusing on insight and experience in a range of powerful workstation applications.

The workshop focuses on three main areas:

- Computer-aided diagnosis
- Quantitative image analysis
- Interactive 3D visualisation

In the three workshops the participants are presented two 45-minute lectures by renowned experts in the field, with the first lecture focusing on state-of-the-art applications, and the second lecture demonstrating how to use the workstation software. The second part of each workshop provides the hands-on experience in a dedicated 'reading room'. In a 60 minute session the participants can practice the presented applications on industry- and academia-supplied workstations with dozens of practical example datasets. Experts are available to guide the participants through the applications.

The lectures are given once. 24 workstations are available Friday through Monday, from 14:00 to 16:00, and are reserved for your session accord-

ing to pre-registration. It is recommended that participants attend at least one set of lectures (90 minutes) and one hands-on session (60 minutes).

### Lecture Programme:

#### Computer-aided diagnosis

Applications: Overview of current CAD techniques

CAD in digital mammography; Contrast-enhanced dynamic MR mammography; Risk analysis and surgery planning in liver, lung, and brain; Tumor volumetry and monitoring

Technical: How does CAD work?

Patterns and shapes; Biophysical modelling and numerical simulation; Intra- and inter-observer variability

#### Quantitative image analysis

Applications: Overview of quantitative image analysis

Dynamical perfusion/diffusion; Cardiac applications, Cascore, soft/hard plaque; Vessel analysis; The European VICORA project

Quantitative image analysis: Under the hood

Modelling the physics of the underlying process; Multi-spectral methods; Texture and shape analysis; Realtime handling of huge datasets

#### New 2D and 3D visualisation techniques

Applications: Modern developments in 2D and 3D visualisation

Follow-up study of thoracic CT images; Oral and maxillofacial surgery planning (incl. soft tissue deformation); Simulation of thoracic expansion for COPD treatment; Fiber tracking in diffusion tensor imaging; 3D angiography (head and neck, heart, liver, lungs); Image-guided therapy (cardiac ablation, laparoscopic rectum resection); Virtual endoscopy (bronchoscopy, colonoscopy); 3D visualisation for education

Technical components: Rigid and nonrigid registration; Bone removal; Probabilistic labelling; Tracking; Color coding; Surface and volume rendering; Physics based rendering; Virtual and augmented reality; Navigation; Hardware requirements

### Learning Objectives

1. To know how to perform efficient and effective CAD with proper parameter settings.
2. To know the basic mechanisms behind a range of quantitative image analysis methods.
3. To learn about the use and principles of new interactive 2D and 3D display and visualisation tools.
4. To estimate the power, pitfalls and constraints of modern workstation applications.

Participants are invited to bring their own DVD with DICOM data of patients.

### Registration

The number of participants for each session is limited.

Pre-registrations have been arranged according to the order in which they were received. Registration is possible onsite, though all seats may be occupied by then. Please register in front of room Z, 20 minutes before the hands-on sessions begin. Please note that an extra fee of € 30, - per participant is charged for this workshop.

### Time Schedule

#### Lectures

Places will be allocated on a first-come, first-served basis. All lectures will be given in room Z (2<sup>nd</sup> level).

<b>Friday, March 7</b>	WS 224	10:30–12:00
<b>Sunday, March 9</b>	WS 1024	10:30–12:00
<b>Monday, March 10</b>	WS 1424	10:30–12:00

#### Hands-on Sessions

Pre-registration required. All hands-on sessions will take place in the foyer Z (2<sup>nd</sup> level).

#### Friday, March 7

WS 24A1	14:00–15:00
WS 24A2	15:00–16:00

#### Saturday, March 8

WS 24B1	14:00–15:00
WS 24B2	15:00–16:00

#### Sunday, March 9

WS 24C1	14:00–15:00
WS 24C2	15:00–16:00

#### Monday, March 10

WS 24D1	14:00–15:00
WS 24D2	15:00–16:00

## 1<sup>st</sup> Workstation Face-Off Session at ECR 2008

**Coordinator:** A. Graser; Munich/DE

**Saturday, March 8, 12:30–13:30, Room E1**


For the first time ever, in 2008, ECR will present a 'Workstation Face-Off' session at the annual meeting in Vienna.

More so than ever before, radiology in 2008 requires radiologists to be able to deal with various 3D applications and large data volumes. For many applications, state-of-the-art workstations are mandatory. All major vendors offer an ample variety of hardware and software, and it is often difficult to recognise the comparative strengths and weaknesses of different equipment. The new Face-Off session will allow you

to get an impression of the 3D capabilities provided by the latest workstation technology.

Several workstations from GE, Philips Healthcare, Siemens, Terarecon, Toshiba and Vital Images will be set up on stage next to each other, and cases provided by the ESR will be demonstrated. The cases will include large volume datasets like CT angiography of the heart and CT colonography.

The aim of this session is to simulate a realistic 'reading room' atmosphere and to give an impression of how different workstations perform in a clinical scenario. We would like to cordially invite you to attend this 'competition' of post processing.



## Satellite Symposium organised by Bayer Schering Pharma

Friday, March 7, 14:00–15:30, Room E1

- SY 1**     **Diagnostic imaging and patient safety** (D-01 – D-03)  
 Moderator:  
*B. Marincek; Zurich/CH*
- **Update and facts on NSF**  
*D. Weishaupt; Zurich/CH*
  - **Recommendations how to avoid CIN**  
*P. Persson; Berlin/DE*
  - **The EMF directive of the European Commission and its implications for the use of MRI**  
*G.P. Krestin; Rotterdam/NL*

## Satellite Symposium organised by Bracco

Saturday, March 8, 10:30–12:00, Room R1

- SY 2**     **Optimising risk-benefit in contrast-enhanced MR imaging** (D-04 – D-07)  
 Moderators:  
*R.C. Semelka; Chapel Hill, NC/US*  
*H.S. Thomsen; Herlev/DK*
- **Risks associated with the administration of Gd-based contrast agents**  
*H.S. Thomsen; Herlev/DK*
  - **How to optimise contrast-enhanced MRI of the CNS in risk patients**  
*H.A. Rowley; Madison, WI/US*
  - **MRA in renally impaired patients: When and how**  
*P.C. Douek; Lyon/FR*
  - **How to maximise the risk-benefit ratio of contrast-enhanced MRI in risk patients**  
*R.C. Semelka; Chapel Hill, NC/US*

## Satellite Symposium organised by GE Healthcare

Saturday, March 8, 12:30–13:30, Room C

- SY 3**     **Re-imagine diagnostic X-ray with new volumetric applications** (D-08 – D-10)  
 Moderator:  
*L. Katz; Buc/FR*
- **VolumeRad: Our initial experiences with digital volumetric imaging in the acute setting**  
*S. Phillips; Bridgend/UK*
  - **VolumeRad: Clinical experience with 3D X-ray imaging in a chest setting**  
*J. Vikgren; Göteborg/SE*
  - **Digital breast tomosynthesis: Clinical experience, potential benefits and challenges**  
*C. di Maggio; Padova/IT*

## Satellite Symposium organised by Bracco

Saturday, March 8, 12:30–13:30, Room F2

- SY 4**     **Cardiovascular imaging: Technology, contrast optimisation and patient management** (D-11 – D-14)  
 Moderator:  
*A. de Roos; Leiden/NL*
- **Evolving role of CT in cardiovascular imaging**  
*A. Küttner; Erlangen/DE*
  - **Contrast optimisation in cardiac CT**  
*F. Cademartini; Rotterdam/NL*
  - **Optimising radiation dose and image quality**  
*J.-F. Paul; Le Plessis Robinson/FR*
  - **Management of renally impaired patients undergoing CT angiography**  
*S.K. Marcos; Sheffield/UK*

## Joint Satellite Symposium by Siemens and Bayer Schering Pharma

Saturday, March 8, 12:30–13:30, Room R2

### SY 5

**Clinical experience with the next generation CT** (D-15 – D19)

Moderator:

*S.O. Schönberg; Mannheim/DE*

- **New methods in dose protection**  
*W.A. Kalender; Erlangen/DE*
- **DSCT in acute chest pain without heart rate control**  
*U.J. Schoepf; Charleston, SC/US*
- **Dual energy in daily routine**  
*A.H. Mahnken; Aachen/DE*
- **Adding dimensions to CT intervention**  
*K. Nikolaou; Munich/DE*
- **Whole organ perfusion**  
*M. Lell; Erlangen/DE*

## Satellite Symposium organised by Bayer Schering Pharma

Saturday, March 8, 14:00–15:30, Room E1

### SY 6

**Changing patient management** (D-20 – 23)

Moderator:

*B. Hamm; Berlin/DE*

- **MRI in multiple sclerosis management**  
*K.-O. Løvblad; Geneva/CH*
- **Health economic considerations in liver MRI: Do they influence patient management?**  
*C.J. Zech; Munich/DE*
- **Treatment decisions for patients with PAOD**  
*W.A. Willinek; Bonn/DE*
- **Managing the CAD patient based on CT**  
*C.R. Becker; Munich/DE*

## Satellite Symposium organised by Siemens

Saturday, March 8, 14:00–15:30, Room F2

### SY 7

**Revisiting routine MRI: State-of-the-art orthopedics and oncology imaging** (D-24 – D-25)

Moderator:

*F.A. Fellner; Linz/AT*

- **From routine imaging to early osteoarthritis detection**  
*C. Marnisch; Berne/CH*
- **Improving the clinical workflow with TimCT Oncology**  
*A.-O. Schäfer; Freiburg/DE*

## Satellite Symposium organised by GE Healthcare

Sunday, March 9, 10:30–12:00, Room E1

### SY 8


**Ultrasound Re-imagined, bringing technology into practice** (D-26 – D-30)

Moderator:

*G. Rizzatto; Gorizia/IT*

- **Emerging technologies in ultrasound**  
*D. Becker; Milwaukee, WI/US*
- **Ultrasound Re-imagined, bringing technology into practice: The breast**  
*G. Rizzatto; Gorizia/IT*
- **Volume ultrasound role in the treatment planning for thyroid radio-iodine therapy: A preliminary experience**  
*R. Malago; Verona/IT*
- **Volume guided ultrasound in musculoskeletal applications: A preliminary experience and its future opportunities**  
*S. Torp-Pedersen; Copenhagen/DK*
- **The expanding role of contrast enhanced ultrasound in oncology: From early diagnosis to treatment monitoring**  
*H.-P. Weskott; Hannover/DE*





## Satellite Symposium organised by Carestream Health

Sunday, March 9, 10:30–12:00, Room R1

- SY 9 Mammography in transition: Exploring the key trends**  
(D-31 – D-34)  
Moderator:  
*C. Varian; Hemel Hempstead/UK*
- **Physical aspects of digital mammography**  
*R. Schätzing; Rochester, NY/US*
  - **Digital screening at ‘Schwarzer Bär’ in Hannover**  
*R. Rathmann; Hannover/DE*
  - **Digital screening mammography in Finland**  
*J. Karhu; Helsinki/FI*
  - **Clinical aspects of digital mammography**  
*U. Bick; Berlin/DE*

## Satellite Symposium organised by GE Healthcare

Sunday, March 9, 12:30–13:45, Room C

- SY 10 Facing the challenges of the increasing population of high-risk patients in CT practice: Recognising the problem, improving outcomes and reducing the risks**  
(D-35 – D-38)  
Moderator:  
*E.K. Fishman; Baltimore, MD/US*
- **Introduction**  
*E.K. Fishman; Baltimore, MD/US*
  - **Optimising practice efficiency and patient care**  
*F. Stacul; Trieste/IT*
  - **Hydration protocols and contrast agent selection: Insights into the latest evidence**  
*M. Downes; Canterbury/UK*
  - **Practical strategies for improving CT and cardiac CTA outcomes in high-risk patients**  
*E.K. Fishman; Baltimore, MD/US*
  - **Discussion**

## Satellite Symposium organised by Hitachi

Sunday, March 9, 12:30–13:30, Room E1

- SY 11 Hitachi Real-time tissue elastography: Stretching diagnostic boundaries – myth or valuable clinical tool?**  
(D-39 – D-42)  
Moderator:  
*F. Frauscher; Innsbruck/AT  
M. Nakajima; Saitama/JP*
- **Value of real-time elastography in the diagnostic evaluation of prostate cancer and testicular masses**  
*F. Frauscher; Innsbruck/AT  
M. Nakajima; Saitama/JP*
  - **Elastography in breast ultrasound: A useful user-friendly technique for characterising breast lesions**  
*A. Tardivon; Paris/FR*
  - **Elastography: New developments in ultrasound for predicting malignancy in thyroid nodules**  
*P. Vitti; Pisa/IT  
T. Rago; Pisa/IT*
  - **Elastography for musculoskeletal applications**  
*A. Klauser; Innsbruck/AT*
  - **Elastographic diagnosis of skin tumours**  
*M. Nakajima; Saitama/JP*

## Satellite Symposium organised by Bracco

**Sunday, March 9, 12:30–13:30, Room F2**

**SY 12**

**From words to blows: The clinical evidence of contrast enhanced ultrasound modality**  
(D-43 – D-46)

Moderator:  
*C. Bru; Barcelona/ES*

- **Clinical guidelines: The consensus opinion of expert on the role of contrast enhanced ultrasound (CEUS) modality**  
*R. Lencioni; Pisa/IT*
- **Focal liver lesions (FLL): The clinical value of CEUS in colorectal cancer patients**  
*S.D. Yarmenitis; Iraklion/GR*
- **The German opinion about the role of CEUS in FLL: Results from a large multicenter clinical trial (DEGUM study)**  
*T. Bernatik; Erlangen/DE*
- **The French opinion about the role of CEUS in FLL: Results from a large multicenter clinical trial (STIC study)**  
*F. Tranquart; Tours/FR*

## Satellite Symposium organised by Philips Healthcare

**Sunday, March 9, 12:30–13:30, Room R2**

**SY 13**

**Healthcare simplified with MRI and CT**  
(D-47 – D-49)

Moderator:  
*L. De Vries; Best/NL*

- **First experience on the new generation scanner: The iCT**  
*N. Peled; Haifa/IL*
- **Perfusion territory imaging: Clinical applications of selective arterial spin labeling MRI**  
*J. Hendrikse; Utrecht/NL*
- **Cardiac CT: New acquisition technique ('step and shoot')**  
*P.C. Douek; Lyon/FR*

## Satellite Symposium organised by GE Healthcare

**Sunday, March 9, 14:00–15:30, Room C**

**SY 14**

**MR: New Horizons**  
(D-50 – D-53)

Moderator:  
*C. Bartolozzi; Pisa/IT*

- **Abdominal MRI at 1.5 Tesla: '3D or nothing'**  
*M. Zins; Paris/FR*
- **Pelvic imaging and therapy: How cube can help**  
*W.M.W. Gedroyc; London/UK*
- **Gadolinium and NSF: Concerns in clinical routine**  
*C.U. Herborn; Hamburg/DE*
- **MRI of cardiovascular disease: A population study**  
*H.K. Ahlström; Uppsala/SE*

## Satellite Symposium organised by Guerbet


**Sunday, March 9, 14:00–15:30, Room E1**

**SY 15**

**Cutting edge in CT imaging**  
(D-54 – D-59)

Moderator:  
*A. de Roos; Leiden/NL*

- **Introduction and symposium objectives**  
*N.N.*
- **PET/CT: PET and CT - friends or foes?**  
*N.N.*
- **MDCT in acute chest pain**  
*N.N.*
- **Contrast media practice in the 21<sup>st</sup> Century**  
*N.N.*
- **Xenetic in Scanbag: The users' viewpoint**  
*N.N.*
- **Conclusion**  
*N.N.*



## Satellite Symposium organised by Hologic

Sunday, March 9, 14:00–15:30, Room F2

### SY 16

**Emerging technologies in breast cancer detection, intervention and therapy**  
(D-60 – D-63)

Moderator:

*A. Smith; Bedford, MA/US*

- **Assessing radiologist performance using breast tomosynthesis and digital mammography**  
*H.J. Teertstra; Amsterdam/NL*  
*L. Niklason; Bedford, MA/US*
- **The promise of a fully-automated breast density assessment tool**  
*J. Marshall; Santa Clara, CA/US*
- **The importance of breast MRI with intervention**  
*C.K. Kuhl; Bonn/DE*
- **The promise of targeted radiation therapy**  
*F.J. Sullivan; Galway/IE*

## Satellite Symposium organised by Toshiba

Sunday, March 9, 14:00–15:30, Room R1

### SY 17

**Leading innovations in medical imaging technologies**  
(D-77 – D-81)

Moderators:

*D.D. Cosgrove; London/UK*

*R. Fötter; Graz/AT*

- **New perspectives in non contrast imaging**  
*M. Miyazaki; Tustin, CA/US*
- **Ultrasound in radio frequency ablation of renal tumors**  
*J.-M. Correas; Paris/FR*
- **The new role of diagnostic ultrasound in breast imaging**  
*T. Fischer; Berlin/DE*
- **Multislice CT, ongoing clinical innovations**  
*P. Rogalla; Berlin/DE*
- **Discussion**

## Satellite Symposium organised by Philips Healthcare

Sunday, March 9, 14:00–15:30, Room R2

### SY 18

**Exciting advances in ultrasound: New clinical opportunities**  
(D-64 – D-67)

Moderator:

*J. Walchenbach; Böblingen/DE*

- **Volume ultrasound in daily practice**  
*S.T. Elliott;*  
*Newcastle upon Tyne/UK*
- **Nerve scanning and advances in MSK**  
*C. Martinoli; Genoa/IT*
- **C5-1 PureWave transducer: The answer to scanning the obese patient?**  
*S.T. Elliott;*  
*Newcastle upon Tyne/UK*
- **Advances in contrast enhanced ultrasound**  
*L. Solbiati; Busto Arsizio/IT*

## Satellite Symposium organised by Toshiba

Monday, March 10, 12:30–13:30, Room F2

### SY 19

**Non contrast MR angiography and CT dynamic volume imaging** (D-68 – D-71)

Moderators:

*A. de Roos; Leiden/NL*

*B. Hamm; Berlin/DE*

- **MRI: Non contrast MR angiography**  
*I. Parienty; Antony/FR*
- **CT Aquilion ONE: Abdomen**  
*P. Rogalla; Berlin/DE*
- **CT Aquilion ONE: Cardiac**  
*L. van der Kroft; Leiden/NL*
- **CT Aquilion ONE: Neuro**  
*R. Klingebiel; Berlin/DE*

**Satellite Symposium organised by Guerbet****Monday, March 10, 12:30–13:30, Room R2****SY 20****From kinetic stability to patient benefits**

(D-72 – D-76)

Moderator:

*J. Barkhausen; Essen/DE*

- **Introduction and symposium objectives**  
*J. Barkhausen; Essen/DE*
- **Kinetic stability: The Gordian knot of MRI?**  
*R. Muller; Mons/BE*
- **Future place of iterative MRI in the follow-up of breast cancer**  
*R. Hammerstingl; Frankfurt a. Main/DE*
- **Kinetic stability: Clinical benefits in MRA**  
*J. Barkhausen; Essen/DE*
- **Discussion and conclusion**  
*J. Barkhausen; Essen/DE*


**Industry Hands-on Workshop organised by Siemens Medical Solutions**

to be held in the Austria Center Vienna in the 'Siemens Hands-on Workshop Hall'

For different modalities like MR, CT and interventional angiography, guided by clinical experts. Benefit from the clinical experts' experience and learn more about the excellent evaluation tools from Siemens!

There is no additional fee for the workshops.

**Friday, March 7, 12:00–13:30**• **CT – Cardiology***B.J. Wintersperger; Munich/DE***Friday, March 7, 14:00–15:30**• **MR – Neuroradiology***T. Engelhorn; Erlangen/DE***Friday, March 7, 16:00–18:00**• **AX – Neuroradiology***A. Dörfler; Erlangen/DE**T. Engelhorn; Erlangen/DE***Saturday, March 8, 09:00–10:30**• **CT – Dual Energy***T.R. Johnson; Munich/DE***Saturday, March 8, 10:45–12:45**• **AX – Neuroradiology***A. Dörfler; Erlangen/DE**T. Engelhorn; Erlangen/DE***Saturday, March 8, 14:45–16:15**• **CT – Neuroradiology***M. Lell; Erlangen/DE***Saturday, March 8, 16:30–18:00**• **MR – Cardiology***B.J. Wintersperger; Munich/DE***Sunday, March 9, 09:00–10:30**• **Cardiac CT vs MR***B.J. Wintersperger; Munich/DE***Sunday, March 9, 10:45–12:15**• **MR – Colonography***C.U. Herborn; Hamburg/DE*



## Sunday, March 9, 12:30–14:30

- **AX – Periphery**  
*T. Waggershauser; Munich/DE*

## Sunday, March 9, 14:45–16:15

- **CT/MR – Angiography**  
*U. Kramer; Tübingen/DE*

## Sunday, March 9, 16:30–18:00

- **MR – Cardiology**  
*B.J. Wintersperger; Munich/DE*

## Monday, March 10, 09:00–11:00

- **AX – Periphery**  
*T. Waggershauser; Munich/DE*

## Monday, March 10, 11:15–12:45

- **MR – Angiography**  
*U. Kramer; Tübingen/DE*

## Monday, March 10, 13:00–14:30

- **Cardiac CT vs MR**  
*B.J. Wintersperger; Munich/DE*

## Monday, March 10, 14:45–16:15

- **CT – Oncology**  
*A. Graser; Munich/DE*

## Monday, March 10, 16:30–18:00

- **CT – Cardiology**  
*B.J. Wintersperger; Munich/DE*

## Industry OsiriX User Meeting organised by Apple

to be held at the Austria Center Vienna

### Saturday March 8, 15:30, Meeting Room Level U2/XII

Come and discover OsiriX at the OsiriX User Meeting @ ECR 2008. Fellow radiologists will share their experience, and Prof. Osman Ratib, co-founder of the OsiriX project, will present 'past, present & future of OsiriX'.  
Registration required.

## Industry Hands-on Workshop organised by Carestream Health

to be held at the Tech Gate Vienna

### Saturday, March 8 and Sunday, March 9, 08:30–18:00

#### Digital Mammography Workshop 'Fit for Screening'

Run in conjunction with Radboud University Nijmegen/NL  
One hour per workshop, 15 minutes break

Instructors:

*R. Holland; Nijmegen/NL*  
*H. Rijken; Nijmegen/NL*

## Industry Hands-on Workshop organised by Philips Healthcare

to be held at the Tech Gate Vienna

### Experience simplicity in CT daily routine at Philips CT 3D lab

#### Sunday, March 9; 09:30 –11:00

- **Vessel Analysis**  
*R. Andrew; Reigate/UK*

#### Sunday, March 9; 13:00 –14:30

- **Cardiac**  
*C. Baron; Hamburg/DE*

#### Sunday, March 9; 15:00 –16:00

- **Virtual Colonoscopy**  
*H. Wilmsen; Best/NL*

**New**

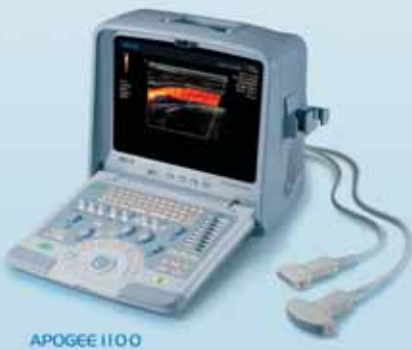## Color Doppler Ultrasound Series

*Elegant Appearance, Outstanding Performance*

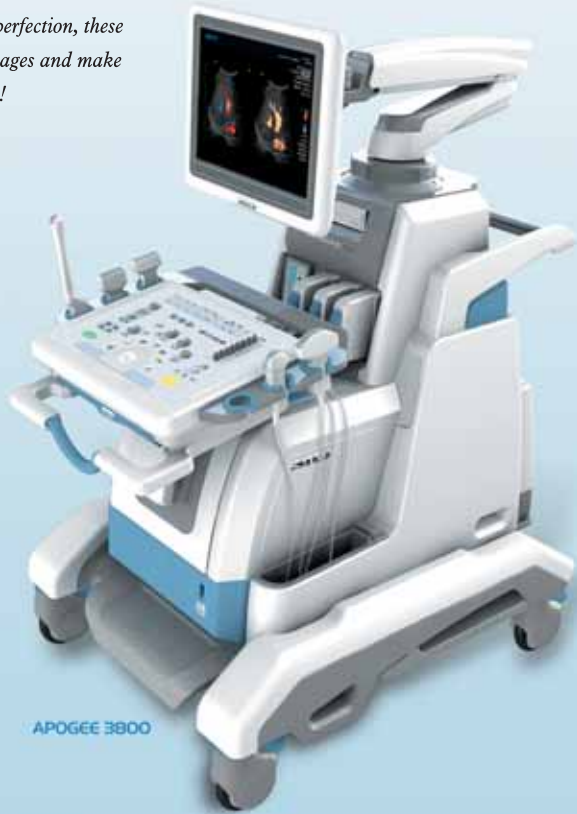*How to reduce heavy clinical workload but still keep your professional scanning techniques uncompromised?*

*New color Doppler ultrasound series products Apogee 3800 and Apogee 1100 offer the best solution to your needs.*

*SIUI is a leading manufacturer of ultrasonic instruments for 45 years. With unremitting pursuit of perfection, these new systems will surely deliver optimal images and make your diagnosis easier and more convenient!*



APOGEE 1100



APOGEE 3800

Welcome to visit us at:



Mar 7-11, 2008  
Vienna, Austria  
Ext. Expo A  
Booth: 20



April 24-27, 2008  
Tashkent, Uzbekistan  
Pavilion 1  
Booth: C94

## Committees & Dignitaries

- 6 Committees
- 8 Subcommittees
- 10 Topic Coordinators
- 11 ESR Dignitaries

## Programme Overviews & Floor Plans

- 24 Programme Overviews
- 34 Floor Plans
- 42 Meeting Rooms
- 45 Metro Map

## ECR Information from A–Z

- 48 ECR Information from A-Z
- 57 EIBIR – European Institute for Biomedical Imaging Research
- 58 CME at ECR 2008
- 60 ESR meets Germany, Israel, India and GPs
- 62 ESR e-Learning for Free
- 64 ESR Electronic Congress
- 65 IMAGINE at ECR 2008
- 66 Plenary Sessions
- 68 Image Interpretation Quizzes
- 69 Hospital Management Symposium
- 70 EPOST™ – Scientific Exhibition
- 72 ESR Job Forum
- 73 Welcome to our Industry Partners
- 74 Food & Drink at ECR 2008
- 75 Free Publications
- 77 European Radiology
- 78 ESOR – European School of Radiology
- 85 Special Exhibition
- 86 Arts & Culture

## Programme by Topics

- 90 New Horizons Sessions
- 90 State-of-the-Art Symposia
- 91 Special Focus Sessions
- 96 Professional Challenges Sessions
- 97 Categorical Courses
- 100 Mini Courses
- 101 Refresher Courses / Scientific Sessions
- 120 E<sup>3</sup> – European Excellence in Education
- 123 Radiology Trainees Forum
- 124 Hands-on Workshops
- 128 1<sup>st</sup> Workstation Face-Off Session
- 129 Satellite Symposia
- 134 Industry Hands-on Workshops

## Educational & Scientific Programme

- 139 Contents**
- 141 Postgraduate Educational Programme**
- 268 Scientific Sessions**
- 361 Scientific and Educational Exhibits**
- 450 List of Authors and Co-authors**
- 499 List of Moderators**
- 502 Personal Planner**



**Austrian Airlines** is offering the following services for Austrian Airlines and Star Alliance flights:

**TICKET OFFICE at the Austria Center Vienna**

**Opening hours:**

March 7–10      09:00–18:00  
March 11        09:00–14:00

- flight reservation
- flight confirmation
- ticketing

Forms of payment: Credit card

**CHECK-IN DESK at the Austria Center Vienna**

**Opening hours:**


March 9–10      09:00–18:00  
March 11        09:00–14:00

- Check-in for Star Alliance Flights
- Issuance of boarding pass (luggage has to be checked-in at dedicated Baggage Drop Off Counters 67 and 68 at the Airport Terminal 1)

**At Vienna Airport**

- Check-in for Star Alliance flights with hand-baggage only:  
Deadline: latest passengers to show up at the respective boarding-gate at Vienna Airport according to boarding-time shown on boarding pass
- Check-in for Star Alliance flights with baggage:  
Deadline: 45 minutes before departure latest passenger to show up with baggage at dedicated Baggage Drop Off Counters 67 and 68 in Terminal 1 at Vienna Airport






# A

## 141 Postgraduate Educational Programme


Friday through Tuesday

- Session numbers are prefixed by CC, E<sup>3</sup>, EF, EM, HL, IL, MC, NH, PC, RC, SA, SF, TF  
See Key to Abbreviations on page 140
- Presentation numbers are prefixed by the letter A
- Presentations for which the author(s) have submitted additional material and images to EPOST<sup>™</sup> are marked with the  icon.

# B

## 268 Scientific Sessions

Friday through Tuesday

- Session numbers are prefixed by SS
- Presentation numbers are prefixed by the letter B
- Presentations for which the author(s) have submitted additional material and images to EPOST<sup>™</sup> are marked with the  icon.

# C

## 361 Scientific and Educational Exhibits

– Presentation numbers are prefixed by the letter C and are grouped by topics.

- 361 Abdominal Viscera (Solid Organs)
- 369 Breast
- 375 Cardiac
- 381 Chest
- 389 Computer Applications
- 391 Contrast Media
- 393 Genitourinary
- 399 GI Tract
- 407 Head and Neck
- 411 Interventional Radiology
- 417 Molecular Imaging
- 419 Musculoskeletal
- 427 Neuro
- 435 Pediatric
- 439 Physics in Radiology
- 443 Radiographers
- 445 Vascular

# D

## 450 List of Authors and Co-authors

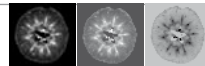
– This part lists all authors and co-authors followed by the presentation number in italic letters

## 499 List of Moderators

– This part lists all moderators followed by the session number in italic letters

**Key to Abbreviations**

- CC Categorical Course
- E<sup>3</sup> European Excellence in Education
- EF EFOMP Workshop
- EM 'ESR meets' Session
- HL Honorary Lecture
- IL Inaugural Lecture
- MC Mini Course
- NH New Horizons Session
- RC Refresher Course
- PC Professional Challenges Session
- SA State-of-the-Art Symposium
- SF Special Focus Session
- SS Scientific Session
- SY Satellite Symposium
- TF Radiology Trainees Forum



08:30 - 10:00

Room A

**MRI**

**CC 116**

**MR techniques: From basic to advanced**

*Moderator: D. Weishaupt; Zurich/CH*

**A-001** 08:30

**A. MRI physics explained by a clinical radiologist**

*W. Kucharczyk; Toronto, ON/CA*

*Learning Objectives:*

1. To understand the fundamental principles for signal generation in MRI.
2. To learn how different types of soft tissue contrast evolve.
3. To describe the development from tissue excitation to reconstruction of an MR image.

**A-002** 09:15

**B. Scanner and pulse sequences: Towards higher robustness in clinical routine**

*J. Hennig; Freiburg/DE*

*Learning Objectives:*

1. To become familiar with current developments for clinical high performance MR scanners.
2. To understand receiver coil design for gain of signal, resolution and anatomic coverage.
3. To describe the fundamental acquisition strategies in MRI.
4. To compare the different pulse sequences in terms of contrast, speed and artifacts.

08:30 - 10:00

Room B

**Multidetector CT Made Easy**

**CC 117**

**MDCT implementation: Making the best of the technology race**

*Moderator: M. Kachelrieß; Erlangen/DE*

**A-003** 08:30

**A. The choice of scanner: A strategic decision**

*M. Prokop; Utrecht/NL*

*Learning Objectives:*

1. To understand the basic differences between the various scanner generations and how these influence their clinical performance.
2. To understand the physical limits of CT scanning and where to expect future improvements.
3. To learn which trade-offs to make when buying a new scanner.
4. To understand which requirements you need for which clinical task.

**A-004** 09:00

**B. Injecting contrast with ever faster scanners**

*D. Fleischmann; Stanford, CA/US*

*Learning Objectives:*

1. To become familiar with the basic principles of early arterial contrast medium dynamics for CTA.
2. To understand the physiologic constraints of arterial enhancement which become apparent with fast CT scanners.
3. To learn strategies for achieving reliable arterial enhancement and image quality with 64-channel CT.

**A-005** 09:30**C. How to justify and reduce the dose**A.J. van der Molen; *Leiden/NL**Learning Objectives:*

1. To understand the process of justification, its current limitations and to introduce new concepts in justification.
2. To become familiar with important dose entities in CT like CT dose index, DLP and effective dose.
3. To understand the basic relation of dose and image quality.
4. To become familiar with present dose reduction strategies, including dose modulation techniques.

**08:30 - 10:00****Room C****New Horizons Session****NH 1****MR diffusion and perfusion: Can they replace PET?***Moderator: M. Essig; Heidelberg/DE***A-006** 08:30**Chairman's introduction**M. Essig; *Heidelberg/DE**Session Objectives:*

1. To give an overview on the current indications of perfusion and diffusion MRI.
2. To give an overview on the indications for PET imaging.
3. To introduce the speakers and give a short introduction about the topics.

**A-007** 08:35**PET and PET/CT in oncological imaging**H.C. Steinert; *Zurich/CH**Learning Objectives:*

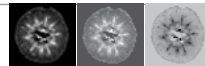
1. To review the indications for PET/CT in oncological imaging.
2. To discuss the value of fused imaging compared to standard CT or PET.
3. To discuss future directions of PET/CT imaging in oncology.

**A-008** 08:55**Diffusion weighted imaging in the assessment of lymph node metastases**A. Herneth; *Vienna/AT**Learning Objectives:*

1. To introduce the principle of measuring DTI outside the brain.
2. To explain how changes in perfusion may change the DTI data.
3. To learn how to differentiate between malignant and benign LN using DTI data.

**A-009** 09:15**Perfusion imaging in the assessment of response to anticancer therapy**F. Berger; *Munich/DE**Learning Objectives:*

1. To give an overview on the current concepts to measure perfusion.
2. To introduce the methods to assess perfusion with MRI.
3. To report on new studies using functional methods like perfusion as a surrogate marker.



**A-010** 09:35

**Quantification strategies for perfusion and diffusion MRI**

B. Stieltjes; Heidelberg/DE

*Learning Objectives:*

1. To be introduced to approaches for optimal DTI acquisition.
2. To learn current approaches for DTI quantification.
3. To be introduced to new developments in DTI.

**Panel discussion:**

**How and when to use MRI instead of PET** 09:45

---

**08:30 - 10:00**

**Room E1**

**Musculoskeletal**

**RC 110**

**Foot and ankle**

*Moderator: C. Faletti; Turin/IT*

**A-011** 08:30

**A. Normal variants and MRI pitfalls**

M. Zanetti; Zurich/CH

*Learning Objectives:*

1. To recognise anatomic variants which are potentially associated with pathologic conditions in the foot and ankle.
2. To understand the influence of foot positioning on the magic angle effect in ankle tendons.
3. To know the appropriate MR imaging technique to avoid technical and anatomical pitfalls.

**A-012** 09:00

**B. Value and limitations of US**

E.G. McNally; Oxford/UK

*Learning Objectives:*

1. To discuss the indications and use of ultrasound compared to other imaging techniques.
2. To describe the techniques for ultrasound examination of the ankle and foot.
3. To demonstrate how ultrasound assists in the diagnosis and management of common conditions.

**A-013** 09:30

**C. Ankle trauma**

M. Shahbapour-David, P. Vorlat, J. de Mey; Brussels/BE

*Learning Objectives:*

1. To review the role of imaging in management and surgical planning of traumatic lesions of the ankle.
2. To describe MR imaging findings associated with specific ligamentous injuries.
3. To provide an overview of posttraumatic complications, including impingement syndromes.

**08:30 - 10:00**
**Room E2**
**Foundation Course: Interventional Radiology**
**E<sup>3</sup> 120a**
**Arteries**
*Moderator: J. Kettenbach; Vienna/AT*
**A-014** 08:30

**A. How to treat superficial femoral artery stenosis**

 H.-J. Wagner; Berlin/DE

*Learning Objectives:*

1. To learn the appropriate indications and contraindications for endovascular treatment of superficial femoral artery (SFA) stenosis.
2. To learn the basic technical principles of balloon angioplasty and stent-supported angioplasty of the SFA.
3. To learn about the potential complications of balloon angioplasty and stent insertion.
4. To be familiar about other endovascular treatment options, e.g. cryoplasty, laser ablation and atherectomy.
5. To be able to define the current role of endovascular treatment of SFA stenosis.

**A-015** 09:15

**B. How and when to use renal artery stents**

 J.H. Peregrin; Prague/CZ

*Learning Objectives:*

1. To know when to use stents.
2. To be familiar with the different types of stents.
3. To understand the technique of renal artery stenting.
4. To be aware of the complications of renal artery stenting.

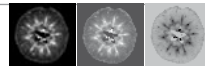
**08:30 - 10:00**
**Room F1**
**Interactive Teaching Session**
**E<sup>3</sup> 120b**
**The imaging management of breast cancer**
*Moderator: R.C. Otto; Baden/CH*
**A-016** 08:30

**The imaging management of breast cancer**

 J. Camps-Herrero<sup>1</sup>, M. Locatelli<sup>2</sup>; <sup>1</sup>Valencia/ES, <sup>2</sup>Gorizia/IT

*Learning Objectives:*

1. To understand the state-of-the-art methods for local breast cancer staging.
2. To understand the state-of-the-art for nodal breast cancer staging.
3. To learn the imaging features and management of breast borderline and less common malignant lesions.



08:30 - 10:00

Room F2

FRIDAY

**Special Focus Session**

**SF 1**

**Uterine fibroid embolisation - the case for and against: Gynecologist, radiologist, patient**

*Moderator: A. Nicholson; Leeds/UK*

**A-017** 08:30

**Chairman's introduction**

A. Nicholson; Leeds/UK

*Session Objectives:*

1. To recognise the indications for UFE rather than surgery.
2. To understand the contraindications to UFE.
3. To appreciate the cost effectiveness arguments.
4. To understand how to avoid complications and complaints post UFE.
5. To review how UFE has evolved to date.

**A-018** 08:35

**Clinical aspects and treatment options in uterine fibroids**

W.M. Ankum; Amsterdam/NL

*Learning Objectives:*

1. To recognise how and when to use medical therapy for fibroids.
2. To understand the indications and contraindications of surgery for fibroids.
3. To appreciate which patients require treatment and which don't.
4. To review how all these options compare, medically and economically.

**A-019** 09:00

**Technique and results**

J.-P. Pelage; Boulogne/FR

*Learning Objectives:*

1. To learn how to set up a UFE service.
2. To optimise your procedure and results.
3. To avoid complications and manage patient's expectations.

**A-020** 09:25

**Fibroid disease from a patient perspective**

V. Norton; Bremen/DE

*Learning Objectives:*

1. To recognise why many women desire uterus preserving treatment.
2. To understand what the patients expectations prior to UFE are.
3. To understand how women feel when expectations are not fulfilled.

**Panel discussion:**

**How will we be treating fibroids in ten years?** 09:40

---

**08:30 - 10:00****Room G/H****Neuro****RC 111****Stroke***Moderator: S. Pedraza; Girona/ES***A-021** 08:30**A. Cerebral vascular territories**A. Urbanik; *Krakow/PL**Learning Objectives:*

1. To learn the anatomic distribution of the different cerebral vascular territories.
2. To learn the neuroradiological correlates of occlusion of the major vessels of the brain as well as the smaller branches.
3. To illustrate the influence of variations of the circle of Willis on the extent and the neuroradiological appearance of a cerebral infarction.

**A-022** 09:00**B. Early signs on CT and MRI**G. Krumina; *Riga/LV**Learning Objectives:*

1. To describe the early signs of cerebral infarction on CT.
2. To describe the early signs of brain infarction on conventional MRI.
3. To learn the importance of diffusion-weighted imaging in the early detection of stroke.

**A-023** 09:30**C. The ischemic penumbra: Diagnosis and clinical impact**E.-M. Law; *New York, NY/US**Learning Objectives:*

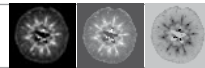
1. To recapitulate the pathophysiology of cerebral infarction.
2. To learn the concepts of ischemic penumbra and diffusion-perfusion mismatch.
3. To discuss the possibilities of demonstrating a diffusion-perfusion mismatch with CT and MRI.

---

**08:30 - 10:00****Room I****Vascular****RC 115****Non-invasive vascular imaging***Moderator: M.I. Furmanek; Warsaw/PL***A-024** 08:30**A. Whole body MRA**S.G. Ruehm; *Los Angeles, CA/US**Learning Objectives:*

1. To learn how to perform whole body MRA.
2. To understand why MRA is of interest for the vascular patient.
3. To learn what the future holds for the technique (clinical need and technical progress in the near future).





**A-025** 09:00

**B. Whole body CTA**

A. Napoli; Rome/IT

*Learning Objectives:*

1. To learn how to perform whole body CTA.
2. To understand why CTA is of interest for the vascular patient.
3. To learn what the future holds for the technique (clinical need and technical progress in the near future).

**A-026** 09:30

**C. Is there a role for catheter angiography?**

D.K. Tsetis; Iraklion/GR

*Learning Objectives:*

1. To understand specific limits and contraindications for CTA and MRA.
2. To learn specific indications for catheter-based angiography.
3. To learn principles of alternative contrast media (e.g. carbon dioxide and gadolinium chelates) in catheter-based angiography.

---

**08:30 - 10:00**

**Room K**

**Computer Applications**

**RC 105**

**What can PACS do today?**

*Moderator: E. Bellon; Leuven/BE*

**A-027** 08:30

**A. Speech recognition and PACS-RIS: Friend or foe?**

C.G. Trumm; Munich/DE

*Learning Objectives:*

1. To be familiar with the principles of the computer basics behind the application.
2. To understand and be able to critically appraise the potential clinical applications.
3. To be conversant with the organisational aspects of employing this technique in the clinical environment.
4. To appreciate the current state-of-the-art.

**A-028** 09:00

**B. PACS and post-processing: Engagement, wedding and divorce**

A. Blum, F. Lefèvre, R. Detreille, D. Roch, M. Louis; Nancy/FR

*Learning Objectives:*

1. To be familiar with the principles of the computer basics behind the application.
2. To understand and be able to critically appraise the potential clinical applications.
3. To be conversant with the organisational aspects of employing this technique in the clinical environment.
4. To appreciate the current state-of-the-art.

**A-029** 09:30

**C. PACS as an essential for radiology education**

A. Toms; Norwich/UK

*Learning Objectives:*

1. To be familiar with the principles of the computer basics behind the application.
2. To understand and be able to critically appraise the potential clinical applications.
3. To be conversant with the organisational aspects of employing this technique in the clinical environment.
4. To appreciate the current state-of-the-art.

---

**08:30 - 10:00****Room L/M****Women's Imaging: Female Pelvis****MC 125****Assessment of anatomy and imaging in benign lesions***Moderator: M. Bekiesinska-Figatowska; Warsaw/PL***A-030** 08:30**A. Normal anatomy (US, CT, PET/CT and MR)**

E. Sala; Cambridge/UK

*Learning Objectives:*

1. To understand the roles of and protocols for US, CT, PET/CT and MR imaging of the female pelvis.
2. To review the normal anatomy and physiology of the female pelvis as seen on US, CT, MRI and PET/CT.
3. To learn about potential imaging pitfalls affected by hormonal status.

**A-031** 09:00**B. Infertility: Imaging of the uterus and Fallopian tubes**

D. Levine; Boston, MA/US

*Learning Objectives:*

1. To understand the roles of HSG, US, and MR imaging techniques in the evaluation of uterine anomalies and tubal pathology.
2. To learn about HSG, US and MR imaging features characteristic of congenital anomalies and tubal pathology.
3. To understand the clinical relevance of imaging findings to patient management.

**A-032** 09:30**C. Benign tumors of the uterus: Detection and characterisation**

C. Reinhold; Montreal, QC/CA

*Learning Objectives:*

1. To understand the roles of US, CT and MR imaging techniques in the detection and characterisation of benign tumors of the uterus.
2. To become familiar with the US and MRI imaging features characteristic of benign uterine tumors.
3. To learn about potential pitfalls in the detection of uterine tumors by US, CT and MRI.

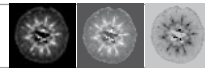
---

**08:30 - 10:00****Room N/O****Molecular Imaging****MC 119****Molecular imaging***Moderator: N. Grenier; Bordeaux/FR***A-033** 08:30**A. Introduction: Scope of molecular imaging**

C. Bremer; Münster/DE

*Learning Objectives:*

1. To highlight the spectrum of molecular imaging (MI) methods.
2. To explain the application of experimental MI tools.
3. To provide an insight into translational MI approaches.



**A-034** 09:00

**B. MR probes for molecular imaging**

S. Aime; Turin/IT

*Learning Objectives:*

1. To become familiar with the main classes of high sensitivity MR reporting systems, their limits and potential.

**A-035** 09:30

**C. Molecular imaging and cell therapies: Techniques**

H.E. Daldrup-Link; San Francisco, CA/US

*Learning Objectives:*

1. To review different techniques for in vitro cell labelling.
2. To discuss advantages and disadvantages of optical, radiotracer and MR techniques for in vivo cell tracking.
3. To review preclinical applications of in vivo cell tracking with MR imaging.

---

**08:30 - 10:00**

**Room R1**

**Chest**

**RC 104**

**Volumetric HRCT of diffuse lung diseases**

*Moderator: J. Neuwirth; Prague/CZ*

**A-036** 08:30

**A. Technical and dose considerations in imaging interstitial lung disease**

D. Tack<sup>1</sup>, C. Beigelman<sup>2</sup>; <sup>1</sup>Brussels/BE, <sup>2</sup>Paris/FR

*Learning Objectives:*

1. To define HRCT technique and detail how it is generated using volumetric MDCT acquisitions for the diagnosis of ILD.
2. To learn how CT and patients biometric parameters influence the radiation exposure of volumetric HRCT.
3. To compare the radiation dose of volumetric HRCT and low-dose sequential HRCT and to learn how to optimise the radiation dose of volumetric MDCT.

**A-037** 09:00

**B. Airway diseases**

G. Ferretti; Grenoble/FR

*Learning Objectives:*

1. To review the advantages of VHRCT for the diagnosis and characterisation of bronchial abnormalities.
2. To emphasise the postprocessing techniques that may contribute to improving the visualisation of airway diseases.
3. To recognise the main patterns of small airway diseases on VHRCT.
4. To review the clinical and HRCT findings of the most common small airway diseases encountered in clinical practice.

**A-038** 09:30

**C. Collagen vascular diseases**

S.R. Desai; London/UK

*Learning Objectives:*

1. To appreciate the wide and mixed range of lung disease in patients with collagen vascular diseases.
2. To recognise the imaging features (specifically those on thin-section CT) of lung disease in collagen vascular disease.
3. To understand the relationship between macroscopic histo-pathological patterns and CT appearances.

**08:30 - 10:00****Room R2****Abdominal and Gastrointestinal****RC 101****Imaging of malignant liver lesions***Moderator: D.J. Lomas; Cambridge/UK***A-039** 08:30**A. Liver metastases**A. Palkó; Szeged/HU*Learning Objectives:*

1. To emphasise significance of liver metastasis detection in staging and therapy planning of malignancies.
2. To define examination technique, role and accuracy of different imaging modalities.
3. To evaluate the place of different cell-specific MR contrast materials in the diagnostic process.

**A-040** 09:00**B. Primary malignancies in the non-cirrhotic liver**T.K. Helmburger; Munich/DE*Learning Objectives:*

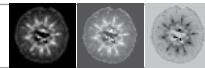
1. To present demographic and pathologic background of primary malignant lesions in the non-cirrhotic liver.
2. To describe typical imaging findings in radiological imaging modalities of these lesions.
3. To define clinically focused, diagnostic strategies or the assessment of these lesions.

**A-041** 09:30**C. Primary malignancies in the cirrhotic liver**G. Brancatelli; Palermo/IT*Learning Objectives:*

1. To discuss the process of hepatocarcinogenesis.
2. To understand the vascular changes of nodules undergoing malignant transformation.
3. To present current knowledge to characterise nodules developing in cirrhosis.

**08:30 - 10:00****Room R3****Head and Neck****RC 108****Imaging of the orbit***Moderator: B. Kreuzberg; Plzen/CZ***A-042** 08:30**A. Ocular pathology**N. Hosten; Greifswald/DE*Learning Objectives:*

1. To understand the compartmental anatomy of the orbit and the radiological anatomy of the eye.
2. To learn to choose the appropriate imaging technique.
3. To review the radiological appearance of eye pathology.



**A-043** 09:00

**B. Extraocular orbital pathology**

C. Czerny; *Vienna/AT*

*Learning Objectives:*

1. To review normal radiological anatomy of the extraocular orbital structures.
2. To learn to choose the most effective investigation technique.
3. To familiarise with the radiological appearance of extraocular orbital disease.
4. To learn the extraorbital spread patterns of orbital disease.

**A-044** 09:30

**C. Extraorbital causes of diplopia**

M.M. Lemmerling; *Gent/BE*

*Learning Objectives:*

1. To become familiar with lesions affecting oculomotor, trochlear and abducens nerve.
2. To learn about cavernous sinus lesions.
3. To understand brainstem and middle cranial fossa lesions, as cause for diplopia.

---

**10:30 - 12:00**

**Room E2**

**Foundation Course: Interventional Radiology**

**E3 220**

**Veins**

*Moderator: R. Morgan; London/UK*

**A-045** 10:30

**A. Common problems with dialysis fistulae**

D. Vorwerk; *Ingolstadt/DE*

*Learning Objectives:*

1. To learn different approaches and techniques with regard to the nature of the fistula.
2. To understand mechanical thrombectomy of thrombosed shunts.
3. To understand effective approaches to graft thromboses.
4. To learn about complication management in typical situations of shunt treatment.

**A-046** 11:15

**B. How to deal with vascular malformations**

A. Martinez de la Cuesta; *Pamplona/ES*

*Learning Objectives:*

1. To outline the current classification of superficial vascular malformations in order to establish a common work frame across the different medical specialties.
2. To provide a basic knowledge of the pathophysiology, clinical presentation and natural history of venous malformations.
3. To discuss the different therapeutic options available and their advantages and disadvantages.
4. To understand the key concepts of sclerotherapy: Sclerosing agents, physical form (liquid vs. foam), side effects, complications.
5. To review a series of illustrative cases of varying complexity in different anatomical regions.

**14:00 - 15:30**
**Room E2**
**Foundation Course: Interventional Radiology**
**E<sup>3</sup> 320**
**Gastrointestinal tract**
*Moderator: T. Pfammatter; Zurich/CH*
**A-047** 14:00

**A. Colonic stenting**

 M.A. De Gregorio, J. Medrano; *Zaragoza/ES*
*Learning Objectives:*

1. To describe the main indications and technique of colonic stenting (CS).
2. To be aware of the most important or frequent complications of CS.
3. To be familiar with the economic implications of the use of stents for the treatment of colonic stenosis and obstruction.

**A-048** 14:45

**B. Management of gastrointestinal bleeding: A starter kit**

 E. Brountzos; *Athens/GR*
*Learning Objectives:*

1. To describe the clinical presentation of the patients with GI bleeding, what laboratory tests should be obtained, and what should be done to stabilise the patient before intervention.
2. To describe the role of non invasive imaging modalities for the evaluation of the patient with GI bleeding.
3. To describe DSA findings in upper and lower GI bleeding and analyse the catheterisation strategies.
4. To describe the various embolic materials and their applicability in several clinical settings.
5. To discuss the results of embolisation for GI bleeding, describe the complications and how to avoid them.

**16:00 - 17:30**
**Room B**
**Multidetector CT Made Easy**
**CC 417**
**The heart: A newly found land**
*Moderator: D.N. Exarhos; Athens/GR*
**A-049** 16:00

**A. Cardiac CT: Protocols and anatomy**

 F. Cademartini; *Rotterdam/NL*
*Learning Objectives:*

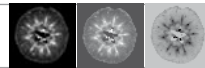
1. To learn the principles of cardiac CT to usefully design a protocol.
2. To understand the backbone of cardiac CT scanning and trade-offs.
3. To discuss cardiac anatomy.

**A-050** 16:30

**B. The coronary arteries: MDCT as the new standard?**

 C.R. Becker; *Munich/DE*
*Learning Objectives:*

1. To understand the current clinical application of cardiac CT.
2. To become familiar with limitations, artifacts and pitfalls in cardiac CT.
3. To learn about possible future application of plaque imaging.



**A-051** 17:00

**C. Beyond the coronaries**

H. Alkadhi; Zurich/CH

*Learning Objectives:*

1. To appreciate the role of MDCT for evaluating ventricular function, cardiac valves, and myocardium.
2. To describe MDCT protocols to rule out coronary artery disease, aortic dissection, and pulmonary embolism in one examination.
3. To review typical imaging findings of patients with acute chest pain.

**16:00 - 17:30**

**Room C**

**State-of-the-Art Symposium**

**SA 4**

**The radiologist as the therapist in liver tumors**

*Moderator: R. Lencioni; Pisa/IT*

**A-052** 16:00

**Chairman's introduction**

R. Lencioni; Pisa/IT

*Session Objectives:*

1. To become familiar with the spectrum of interventional radiology techniques used to treat liver tumors.
2. To understand indications, contraindications, results and complications of intra-arterial and percutaneous interventions in the treatment of primary and metastatic liver tumors.
3. To appreciate the role of interventional radiology in the therapeutic management of the patient with primary or metastatic liver cancer.

**A-053** 16:05

**Transarterial chemoembolisation**

T.F. Jakobs; Munich/DE

*Learning Objectives:*

1. To understand materials and techniques used for transarterial chemoembolisation of liver tumors, including novel drug-eluting beads.
2. To understand indications, contraindications, results and complications of transarterial chemoembolisation in the treatment of primary and metastatic liver tumors.
3. To appreciate the role of transarterial chemoembolisation in the therapeutic management of primary or metastatic liver cancer.

**A-054** 16:25

**Selective internal radiation therapy**

J.-I. Bilbao; Pamplona/ES

*Learning Objectives:*

1. To understand materials and techniques used for selective internal radiation therapy of liver tumors, including essentials of dosimetry.
2. To understand indications, contraindications, results and complications of selective internal radiation therapy in primary and metastatic liver tumors.
3. To appreciate the role of selective internal radiation therapy in the clinical management of the patient with primary or metastatic liver cancer.

**A-055** 16:45**Radiofrequency ablation and combination therapies**

R. Lencioni; Pisa/IT

*Learning Objectives:*

1. To understand materials and techniques used for radiofrequency ablation of liver tumors.
2. To understand indications, contraindications, results and complications of radiofrequency ablation in the treatment of primary and metastatic liver tumors.
3. To learn about the synergy of radiofrequency ablation and transarterial chemoembolisation in liver tumor treatment.
4. To appreciate the role of radiofrequency ablation and combined therapies in the therapeutic management of the patient with primary or metastatic liver cancer.

**Panel discussion:****Can interventional radiology replace surgery?** 17:05**16:00 - 17:30****Room E1****Breast: From Basics to Advanced Imaging****CC 418****From pathology to breast imaging: Radiologic-pathologic correlations***Moderator: C. El Khoury; Paris/FR***A-056** 16:00**A. Benign masses and invasive carcinomas**

T. Tot; Falun/SE

*Learning Objectives:*

1. To know the normal structures of the breast (anatomy, microscopy).
2. To become familiar with pathological definitions of benign and malignant masses.
3. To understand mammographic features (shape, margin) based on pathological findings.
4. To learn about pathological clues used for differential diagnostic options and prognostic implications.

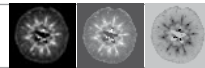
**A-057** 16:45**B. Benign and malignant calcifications**

D.R.G. Faverly; Brussels/BE

*Learning Objectives:*

1. To describe pathological findings for benign calcifications.
2. To learn about ductal carcinoma in situ (definition, microscopic features).
3. To understand morphological patterns seen at imaging based on pathological findings.
4. To learn about pathological clues used for differential diagnostic options and prognostic implications.





16:00 - 17:30

Room E2

**Foundation Course: Interventional Radiology**

**E<sup>3</sup> 420a**

**Genitourinary**

*Moderator: I.S. Kaskarelis; Athens/GR*

**A-058** 16:00

**A. Percutaneous nephrostomy**

O. Akhan; Ankara/TR

*Learning Objectives:*

1. To understand indications for percutaneous nephrostomy.
2. To review the various techniques for percutaneous nephrostomy.
3. To review possible complications of the procedures and how to deal with them.

**A-059** 16:45

**B. Uterine fibroids**

J.-P. Pelage; Boulogne/FR

*Learning Objectives:*

1. To describe the main anatomical and technical considerations relevant to uterine fibroid embolisation.
2. To be familiar with indications and contraindications of uterine fibroid embolisation with special emphasis on fertility.
3. To recognise complications associated with uterine fibroid embolisation and apply prevention and management options.
4. To understand respective indications for medical treatment, hysterectomy, myomectomy and uterine fibroid embolisation in women with symptomatic uterine fibroids.

16:00 - 17:30

Room F1

**Interactive Teaching Course: Useful Signs in Imaging**

**E<sup>3</sup> 420b**

**Signs in neuroradiology and in head and neck imaging**

*Moderator: J.A. Castelijns; Amsterdam/NL*

**A-060** 16:00

**A. Neuro**

I.M. Björkman-Burtscher; Lund/SE

*Learning Objectives:*

1. To become familiar with selected imaging signs in neuroradiology.
2. To understand their appearance in different imaging modalities.
3. To appreciate their diagnostic and clinical significance.

**A-061** 16:45**B. Head and neck**S.J. Golding; *Oxford/UK**Learning Objectives:*

1. To understand the importance of eliciting signs in the face and neck systematically, using an anatomical, compartment-based approach.
2. To recognise common signs in the sinuses, pharynx, salivary glands and cervical soft tissues and to be able to relate these to findings on clinical examination.
3. To understand the importance of diagnostic evaluation in the face and neck in relation to available treatment options.

**16:00 - 17:30****Room F2****Breast****RC 402****Digital mammography***Moderator: R. Salvador; Barcelona/ES***A-062** 16:00**A. Quality assurance and quality vs dose**H. Bosmans; *Leuven/BE**Learning Objectives:*

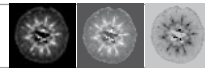
1. To introduce the European quality assurance guidelines for full field digital mammography (FFDM).
2. To review the relationship between image quality and dose.
3. To explain the different quality control requirements for FFDM.
4. To review the differences between phantom measurements and clinical needs.
5. To compare the results of measurements on DR and CR systems for digital mammography.

**A-063** 16:30**B. Computer-aided detection and diagnosis**L. Khoo; *London/UK**Learning Objectives:*

1. To introduce current technology used for CAD.
2. To review current evidence for use of CAD in population screening.
3. To describe future CAD applications.

**A-064** 17:00**C. Screening: Practical issues**N.M. Perry; *London/UK**Learning Objectives:*

1. To explain the increasing evidence for screening with full field digital mammography (FFDM).
2. To review process changes needed to convert to FFDM.
3. To review training needs of radiologists converting to full field digital screening.



16:00 - 17:30

Room 6/H

FRIDAY

**Special Focus Session**

**SF 4**

**Dual source CT/Dual energy CT: Doubly informative?**

*Moderator: W.A. Kalender; Erlangen/DE*

**A-065** 16:00

**Chairman's introduction**

W.A. Kalender; Erlangen/DE

*Session Objectives:*

1. To explain the technical and physical principles of dual source/dual energy CT.
2. To evaluate performance characteristics and potentials.
3. To discuss current and potential clinical and research applications.

**A-066** 16:03

**Technical considerations**

W.A. Kalender; Erlangen/DE

*Learning Objectives:*

1. To understand the technical and physical principles of dual source CT.
2. To understand the physical principles of dual energy CT.
3. To assess the performance and potential of dual source/dual energy CT.

**A-067** 16:27

**Current applications**

T.R. Johnson; Munich/DE

*Learning Objectives:*

1. To review established clinical applications of dual source CT.
2. To review established clinical applications of dual energy CT.
3. To assess the specific contributions of dual source/dual energy CT.

**A-068** 16:51

**Future applications**

I. Vlahos; New York, NY/US

*Learning Objectives:*

1. To review specific features of dual source CT relevant for future applications.
2. To review specific features of dual energy CT relevant for future applications.
3. To assess the specific features of dual source/dual energy CT for pre-clinical research.

**Panel discussion:**

**How much more information do we get?** 17:15

**16:00 - 17:30****Room I****Vascular****RC 415****Imaging in carotid disease***Moderator: A.L.J. Bojanovic; Nis/RS***A-069** 16:00**A. Ultrasound**N. Liasis; Athens/GR*Learning Objectives:*

1. To understand US techniques in carotid imaging.
2. To demonstrate the ultrasonographic characteristics of unstable atherosclerotic plaque.
3. To demonstrate new aspects and future developments.

**A-070** 16:30**B. MRA and CTA**N. Anzalone; Milan/IT*Learning Objectives:*

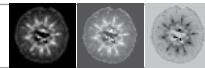
1. To learn how to perform CTA and MRA.
2. To demonstrate how to evaluate degree of stenosis.
3. To show results, advantages and limitations of each modality.

**A-071** 17:00**C. Plaque imaging**M. Lell; Erlangen/DE*Learning Objectives:*

1. To learn how to perform plaque imaging.
2. To demonstrate the clinical relevance of plaque imaging.
3. To show strengths and weaknesses of different modalities.

**16:00 - 17:30****Room K****Computer Applications****RC 405****PACS in evolution***Moderator: N.H. Strickland; London/UK***A-072** 16:00**A. Structured reporting**P. Mildenberger; Mainz/DE*Learning Objectives:*

1. To understand the principles of the computer basics behind the application.
2. To be able to critically appraise the potential value of this technique in different environments.
3. To be aware of the aspects involved in implementing this technique.
4. To recognise the necessity of this technique in a connected eHealth-future.



**A-073** 16:30

**B. Process management and quality assurance in PACS**

J.G. Blickman; *Nijmegen/NL*

*Learning Objectives:*

1. To understand the rationale and need for QA in PACS.
2. To appreciate the need to manage underlying PACS processes.
3. To be aware of the limitations relevant to QA and process management in PACS.
4. To appreciate the current state-of-the-art.

**A-074** 17:00

**C. Regional and national PACS and EPR**

R. Vogl; *Münster/DE*

*Learning Objectives:*

1. To appreciate the progress being made in regional and national PACS implementations in Europe.
2. To understand the various issues involved in deploying such projects.
3. To be aware of the potential to develop secure medical image data exchange.

---

**16:00 - 17:30**

**Room L/M**

**Women's Imaging: Female Pelvis**

**MC 425**

**Malignant tumors**

*Moderator: D. Grenier; Paris/FR*

**A-075** 16:00

**A. Cancer of the uterus: Primary and metastatic**

M.H. Fuchsjaeger; *Vienna/AT*

*Learning Objectives:*

1. To understand the roles of CT, PET/CT and MR imaging techniques in malignant tumors of the uterus.
2. To review the essential imaging findings in the evaluation of cancer of the uterus.
3. To understand the clinical relevance of imaging findings to patient management.

**A-076** 16:30

**B. Cancer of the cervix: Primary staging and detection of cancer recurrence**

B. Hamm; *Berlin/DE*

*Learning Objectives:*

1. To understand the roles of CT, PET/CT and MR imaging techniques in the evaluation of cancer of the cervix.
2. To review the essential imaging findings in the evaluation of cancer of the cervix.
3. To understand the clinical relevance of the imaging findings to patient management.

**A-077** 17:00

**C. Cancer of the ovary: Relevance of imaging to patient management**

H. Hricak; *New York, NY/US*

*Learning Objectives:*

1. To understand the roles of US, CT, PET/CT and MR imaging techniques in the evaluation of malignant tumors of the ovary.
2. To become familiar with the changes in the diagnostic imaging armamentarium for ovarian cancer.
3. To understand the clinical relevance of imaging findings to patient management.

**16:00 - 17:30****Room N/O****Head and Neck****RC 408****Head and neck imaging: A practical approach***Moderator: S. Robinson; Vienna/AT***A-078** 16:00**A. Inflammatory lesions**R. Maroldi; *Brescia/IT**Learning Objectives:*

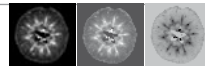
1. To familiarise with the concept of compartmental spreading of infection in the neck.
2. To learn the imaging findings in various head and neck infections.
3. To review the differential diagnosis of inflammatory pseudotumors.
4. To learn to report the pertinent findings to the clinician.

**A-079** 16:30**B. Traumatic lesions**M. Becker; *Geneva/CH**Learning Objectives:*

1. To become familiar with common types of craniocervical trauma and their effects on skull base and maxillofacial skeleton.
2. To be able to adapt the examination protocol depending on the type of injuries suspected.
3. To learn to describe the pertinent findings in fractures, and to identify the related soft tissue injuries.
4. To learn to report the pertinent findings to the clinician.

**A-080** 17:00**C. Tumors**R. Hermans; *Leuven/BE**Learning Objectives:*

1. To understand the importance of imaging in the management of head and neck tumors.
2. To learn how to optimise CT and MRI studies for evaluating head and neck tumors.
3. To learn the importance of anatomy in understanding and predicting local and regional tumor extent.
4. To familiarise with the imaging features of head and neck tumors on CT and MRI studies.



16:00 - 17:30

Room R1

**Chest**

**RC 404**

## A practical approach for interpreting the chest radiograph

*Moderator: K. Malagari; Athens/GR*

**A-081** 16:00

### A. General principles

A.A. Bankier; Boston, MA/US

*Learning Objectives:*

1. To define the medical and epidemiological background of conventional chest radiography.
2. To present the conventional and advanced technical features of this radiological modality.
3. To illustrate basic phenomena used in the interpretation of chest radiography.
4. To define indications and limitations of this method.

**A-082** 16:30

### B. The frontal view

N. Howarth; Chêne-Bougeries/CH

*Learning Objectives:*

1. To describe the potential and the limitations of the frontal chest-radiograph.
2. To illustrate normal anatomy and frequent pathological findings.
3. To detail the important morphological patterns of abnormalities.
4. To demonstrate typical signs helpful in the interpretation of frontal chest-radiographs.

**A-083** 17:00

### C. The lateral view

J. Cáceres; Barcelona/ES

*Learning Objectives:*

1. To describe the normal radiographic anatomy in the lateral projection of the chest.
2. To define which areas are not visible in the PA chest radiograph.
3. To describe structures which help to interpret findings in the PA chest radiograph.

16:00 - 17:30

Room R2

**Abdominal and Gastrointestinal**

**RC 401**

## Diseases of the mesentery and peritoneum

*Moderator: P.K. Prassopoulos; Alexandroupolis/GR*

**A-084** 16:00

### A. Radiologic anatomy of the mesentery and peritoneum

A. Ba-Ssalamah; Vienna/AT

*Learning Objectives:*

1. To illustrate the normal appearance of peritoneal ligaments and mesenteries on cross-sectional imaging.
2. To describe the interconnections between peritoneal organs along peritoneal reflections and the peritoneal cavity subdivisions.
3. To discuss the key role of anatomy in the extension of intra-abdominal diseases.

**A-085** 16:30

**B. Neoplastic diseases**

Y. Menu; *Le Kremlin-Bicêtre/FR*

*Learning Objectives:*

1. To know the usual presentation of peritoneal carcinomatosis on US, MRI and MDCT.
2. To know the accuracy of imaging methods including CT-PET.
3. To be able to detect subtle changes allowing to improve detection rate.
4. To know some basic features of primary peritoneal tumors.

**A-086** 17:00

**C. Infectious and inflammatory disease**

L. Crocetti; *Pisa/IT*

*Learning Objectives:*

1. To illustrate the radiological appearance of common and less common infectious and inflammatory diseases of the mesentery and peritoneum.
2. To discuss contribution of current imaging modalities to the diagnosis of these diseases.
3. To discuss the influence of imaging diagnosis on therapeutic decisions: Surgery vs intervention.

**16:00 - 17:30**

**Room R3**

**Interventional Radiology**

**RC 409**

**Endovascular treatment of aortoiliac occlusive disease: How far can interventional radiology go?**

*Moderator: A. Chatziioannou; Athens/GR*

**A-087** 16:00

**A. Aortic bifurcation disease**

G. O'Sullivan; *Galway/IE*



*Learning Objectives:*

1. To discuss about the indications for the treatment of aortic bifurcation disease.
2. To learn about the techniques of endovascular treatment at the aortic bifurcation.
3. To review the results of endovascular treatment of aortic bifurcation disease.

**A-088** 16:30

**B. Occlusions: Techniques, tips and tricks**

D. Scheinert; *Leipzig/DE*

*Learning Objectives:*

1. To review the techniques for the recanalisation and treatment of aortoiliac occlusions.
2. To review methods regarding the treatment of difficult patients.
3. To learn about the relative merits of angioplasty vs stents for aortoiliac occlusions.

**A-089** 17:00

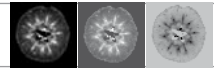
**C. Trial results and TASC recommendations**

J. Lammer; *Vienna/AT*

*Learning Objectives:*

1. To review the results of the endovascular treatment of aortoiliac disease.
2. To discuss the TASC recommendations.
3. To review about the indications for the treatment of aortoiliac disease.





**17:45 - 18:15**

**Room A**

**Plenary Session**

**II**

**Inaugural Lecture**

*Presiding: M.F. Reiser; Munich/DE*

**A-090** 17:45

**Images in the brain - pictures in the eyes**

*E. Pöppel; Munich/DE*

**FRIDAY**

---

**08:30 - 10:00****Room A****MRI****CC 516****Neuro: The brain as the centre of the world***Moderator: O. Flodmark; Stockholm/SE***A-091** 08:30**A. Stroke**M.A. van Buchem<sup>1</sup>, J. Hendrikse<sup>2</sup>; <sup>1</sup>Leiden/NL, <sup>2</sup>Utrecht/NL*Learning Objectives:*

1. To understand the basic protocol requirements for emergency imaging of stroke patients.
2. To become familiar with qualitative and quantitative image evaluation of stroke protocols.
3. To define different causes, extent and stages of stroke on MRI.
4. To derive therapeutic consequences and predict post-therapeutic outcome.

**A-092** 09:00**B. Tumors**

N. Colombo; Milan/IT

*Learning Objectives:*

1. To classify different tumor entities based on location and imaging features.
2. To understand the value of recent sequence developments for accurate detection and staging.
3. To become familiar with functional MR imaging techniques for tumor grading, treatment planning and prediction of therapeutic response.

**A-093** 09:30**C. Infections**

C.F. Andreula; Bari/IT

*Learning Objectives:*

1. To learn about important differential diagnoses based on characteristic MR imaging findings.
2. To describe minor and major complications from CNS infections.
3. To differentiate typical patterns of infectious diseases from non-infectious causes.
4. To define emergencies for medical and surgical treatment.

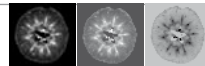
---

**08:30 - 10:00****Room B****Multidetector CT Made Easy****CC 517****The guts: Growing opportunities***Moderator: J. Puig Domingo; Sabadell/ES***A-094** 08:30**A. Small bowel CT: Try it, you'll like it!**

P. Rogalla; Berlin/DE

*Learning Objectives:*

1. To review anatomy and physiology of the small intestine as it relates to image interpretation.
2. To understand the differences between positive and negative contrast agents and their effects in CT imaging.
3. To review the most common diseases in the small bowel and how they appear in CT imaging.



**A-095** 09:00

**B. Bowel emergencies: The basic tool**

J. Stoker; *Amsterdam/NL*

*Learning Objectives:*

1. To learn about the typical CT imaging findings in bowel emergencies.
2. To become familiar with the strength and weaknesses of CT in bowel emergencies.
3. To understand the role of CT in the management of common bowel emergencies.

**A-096** 09:30

**C. Colon and rectum: Not only colonography**

A. Laghi; *Latina/IT*

*Learning Objectives:*

1. To learn about MDCT protocols for large bowel imaging.
2. To become familiar with different patterns of inflammatory colonic diseases.
3. To understand the role of MDCT in staging rectal cancer.
4. To learn about new innovative techniques (i.e. CT perfusion) and their role in colon studies.

---

**08:30 - 10:00**

**Room C**

**New Horizons Session**

**NH 5**

**The further minimisation of minimally invasive therapy**

*Moderator: A. Adam; London/UK*

**A-097** 08:30

**Chairman's introduction**

A. Adam; *London/UK*

*Session Objectives:*

1. To learn the principles underlying the techniques of percutaneous drug delivery, the Cyberknife and high-frequency focussed ultrasound therapy.
2. To understand the importance of multidisciplinary collaboration in minimally invasive therapy.

**A-098** 08:35

**MR-guided focussed ultrasound therapy**

W.M.W. Gedroyc; *London/UK*

*Learning Objectives:*

1. To understand potential of focussed ultrasound as an ablation modality.
2. To become familiar with the areas of existing applications.
3. To learn about areas of evolution of this technique.

**A-099** 09:00

**Interventional radiology in drug delivery and gene therapy**

B.J. Wood; *Bethesda, MD/US*

*Learning Objectives:*

1. To describe methods for using pre-procedural imaging during procedures.
2. To describe methods for registration and fusion of different modalities for use during procedures.
3. To understand how CT-integrated robotics could be applied to patient specific treatment planning for tumor ablation.
4. To better understand the barriers to drug delivery facing the IR physician.

**A-100** 09:25**Cyberknife: Its potential and its interaction with radiology**A. Muacevic; *Munich/DE**Learning Objectives:*

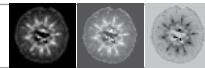
1. To learn about the principles and clinical applications of image guided robotic radiosurgery.
2. To understand the importance and requirements of multimodal imaging for dedicated 3D computerised planning for radiosurgical applications.

**Panel discussion** 09:50**08:30 - 10:00****Room E1****Breast: From Basics to Advanced Imaging****CC 518****Breast lesions at mammography: How to characterise?***Moderator: A. Fausto; Milan/IT***A-101** 08:30**A. Mass, focal asymmetry and architectural distortion**M. Michell; *London/UK**Learning Objectives:*

1. To become familiar with normal variants at mammography.
2. To learn how to detect and characterise abnormal findings detected at screening mammography.
3. To describe BI-RADS™ lexicon and assessment categories.

**A-102** 09:15**B. Clustered microcalcifications**G. Forrai; *Budapest/HU**Learning Objectives:*

1. To become familiar with artefacts mimicking calcifications at mammography.
2. To learn how to characterise calcifications detected at screening mammography.
3. To describe BI-RADS™ lexicon and assessment categories for calcifications.



08:30 - 10:00

Room E2

**Foundation Course: Interventional Radiology**

**E<sup>3</sup> 520a**

**Liver tumors**

*Moderator: R. Lencioni; Pisa/IT*

**A-103** 08:30

**A. Percutaneous treatments**

L. Solbiati; Busto Arsizio/IT

*Learning Objectives:*

1. To learn the basic technical principles of the different percutaneous ablative methods.
2. To learn the most important indications, contraindications and possible risks of percutaneous ablations.
3. To know the literature data about the results of percutaneous ablations: Rates of local control and recurrences, long-term survival rates of treated patients.
4. To learn the main tips and tricks needed to perform successful and safe ablative procedures.

**A-104** 09:15

**B. Endovascular treatments**

F. Orsi; Milan/IT

*Learning Objectives:*

1. To become familiar with the liver vascular anatomy.
2. To understand the need of exploring anatomical variations before any intra-arterial treatment is going to be performed.
3. To know how to plan arterial embolisation with coils for the occlusion of non-hepatic vessels.

08:30 - 10:00

Room F1

**Interactive Teaching Session**

**E<sup>3</sup> 520b**

**Prostate cancer: Meeting clinical needs by MRI at diagnosis and on follow-up**

*Moderator: E. Breatnach; Dublin/IE*

**A-105** 08:30

**Prostate cancer: Meeting clinical needs by MRI at diagnosis and on follow-up**

A.R. Padhani<sup>1</sup>, A. Graser<sup>2</sup>; <sup>1</sup>Northwood/UK, <sup>2</sup>Munich/DE

*Learning Objectives:*

1. To decide the clinical indications for and importance of MRI findings at initial diagnosis.
2. To learn that TNM staging and lesion localisation represent distinct goals both having management implications.
3. To learn how to deal with treated patients with rising serum PSA levels.
4. To note how advanced techniques including spectroscopy, dynamic MRI, MR lymphography and diffusion imaging contribute to imaging assessments.

SATURDAY

**08:30 - 10:00****Room F2****Special Focus Session****SF 5a****Nephrogenic systemic fibrosis: Current situation and future direction***Moderator: B. Hamm; Berlin/DE***A-106** 08:30**Chairman's introduction**B. Hamm; Berlin/DE*Session Objectives:*

1. To become familiar with the clinical symptoms of NSF.
2. To be updated on the incidence of NSF.
3. To discuss the possible causes of NSF and the latest research results.
4. To discuss possible strategies how to avoid NSF in the future.

**A-107** 08:33**What is it, and where does it come from?**S.E. Cowper; New Haven, CT/US*Learning Objectives:*

1. To understand how NSF was first recognised.
2. To become familiar with the clinical and histological presentation of NSF.
3. To understand the supporting arguments that lead to the conclusion that NSF is caused by gadolinium.

**A-108** 08:51**Fundamental mechanisms and their implications on clinical practice**P. Persson; Berlin/DE*Learning Objectives:*

1. To comprehend our current understanding on the mechanisms behind NSF.
2. To illustrate which patients are at risk and why they are at risk.
3. To outline the importance of the different physicochemical properties of various Gd-containing contrast media in promoting NSF.

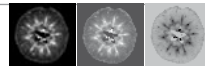
**A-109** 09:09**Clinical prevalence and risk factors**H.S. Thomsen; Herlev/DK*Learning Objectives:*

1. To become familiar with the incidence of NSF in the five renal function groups.
2. To become familiar with the incidence of NSF after exposure to the various gadolinium based agents.
3. To review the importance of the various risk factors other than end-stage-renal failure and gadolinium.

**A-110** 09:27**How to avoid NSF in the future**S.K. Morcos; Sheffield/UK*Learning Objectives:*

1. To present simple guidelines on how to reduce the risk of NSF.
2. To explain the important risk factors of NSF highlighting the importance of the stability of the gadolinium contrast agents.
3. To become familiar with important chemical principles that determine the stability of gadolinium contrast agents.

**Panel discussion:****Future aspects** 09:45



08:30 - 10:00

Room 6/H

**EFOMP Workshop**

**New technology in diagnostic radiology: High field MRI for clinical and pre-clinical studies**

**EF 1**

**State-of-the-art of high field MRI instrumentation**

*Moderators: W. Schlegel; Heidelberg/DE, M. Tosetti; Pisa/IT*

**Welcome address** 8:30

*M.F. Reiser; Munich/DE*

*W. Schlegel; Heidelberg/DE*

**A-111** 08:40

**High field clinical MRI: Instrumentation and methods**

*R. Turner; Leipzig/DE*

*Learning Objectives:*

1. To comprehend the importance of magnetic field strength in MR imaging of humans.
2. To understand the basic physical factors related to field strength that affect MR images.
3. To become familiar with the strategies that are currently employed to make the best use of these factors.

**A-112** 09:07

**Pre-clinical studies with high field and very high field MRI: What is available, what is needed?**

*S. Aime; Turin/IT*

*Learning Objectives:*

1. To become familiar with MRI and MRS studies carried out at high magnetic field on animal models.
2. To understand the pros' and cons' of the field strength in the major MRI applications, with and without the presence of contrast agents.

**A-113** 09:34

**PET-MRI combined modalities for pre-clinical and clinical studies**

*A. Carpenter; Cambridge/UK*

*Learning Objectives:*

1. To understand the motivation for PET/MR hybrid systems.
2. To appreciate the technical challenge to develop a PET/MR scanner.
3. To gain an understanding of the technical solutions for the development of PET/MR.

SATURDAY

**08:30 - 10:00****Room L/M****Special Focus Session****SF 5b****Comprehensive evaluation of the heart***Moderator: B. Marincek; Zurich/CH***A-114** 08:30**Chairman's introduction**B. [Marincek](#); Zurich/CH*Session Objectives:*

1. To show that cardiac imaging is recognised as an increasingly important area of radiology.
2. To become familiar with the essentials of cardiac pathophysiology and pathoanatomy when evaluating the heart with CT and/or MRI.
3. To present recent advances in cardiac CT and MR imaging.

**A-115** 08:33**What does MDCT offer?**H. [Alkadhi](#); Zurich/CH*Learning Objectives:*

1. To provide an overview of the current knowledge about CT imaging of the heart.
2. To describe the latest technical developments in multi-detector row CT which impact on the performance of cardiac imaging.
3. To understand the role of cardiac CT for a comprehensive cardiac evaluation including coronary arteries, myocardium, and cardiac valves.

**A-116** 08:57**What does MRI offer?**M. [Gutberlet](#); Berlin/DE*Learning Objectives:*

1. To learn what MRI can offer for functional assessment of the heart (e.g. CINE-MRI, myocardial tagging, flow quantification).
2. To learn what MRI can offer for tissue characterisation of the myocardium in different ischemic or non-ischemic heart diseases (e.g. differentiation between edema, fibrosis, scar and inflammation).
3. To learn how all these techniques can be improved according to acquisition time and spatial resolution to better compete with MDCT in the morphological assessment of the heart.

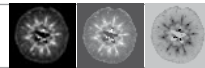
**A-117** 09:21**Integrating MDCT and MRI in the work-up of heart disease**V.E. [Sinitsyn](#); Moscow/RU*Learning Objectives:*

1. To compare advantages and limitations of modern MDCT and MRI in cardiac imaging.
2. To understand, how MRI and MDCT are complementary in solving common clinical problems.
3. To be familiar with major indications for performing integrated cardiac CT and MRI in the work-up of heart diseases.

**Panel discussion:****One-stop shopping with cardiac imaging: CT or MRI**

09:45





08:30 - 10:00

Room N/O

**Molecular Imaging**

**MC 519**

**Molecular imaging in cardiovascular diseases**

*Moderator: C. Pirich; Salzburg/AT*

**A-118** 08:30

**A. Atherosclerotic plaques**

E. Canet-Soulas; Lyon/FR

*Learning Objectives:*

1. To understand the features of atherosclerotic plaques on MRI.
2. To learn about the diagnostic impact of non specific contrast agents in atherosclerotic disease.
3. To understand the strategy for targeting the vulnerable plaque and inflammation.

**A-119** 09:00

**B. Myocardial infarction**

M. Bernsen; Rotterdam/NL

*Learning Objectives:*

1. To understand the challenges faced in implementing stem cell therapy as an effective treatment option for myocardial infarction.
2. To acquire an overview of imaging techniques that will improve the understanding of how cell therapy works.
3. To understand the challenges faced in generating robust imaging tools relevant for stem cell therapy development and treatment monitoring.

**A-120** 09:30

**C. Angiogenesis**

M. Neeman; Rehovot/IL

*Learning Objectives:*

1. To review the needs in basic biology, preclinical drug development and clinical imaging for imaging of angiogenesis.
2. To outline the mechanisms and potential imaging targets in the angiogenic process.
3. To review the functional imaging tools available for imaging angiogenesis.
4. To review the new emerging tools for molecular imaging of angiogenesis: Targeted contrast agents, imaging markers for gene expression and enzymatic activity and tracking recruitment of vascular cells, imaging markers for response to antiangiogenic and vascular targeted therapy.

SATURDAY

**08:30 - 10:00****Room R1****Chest****RC 504****Pulmonary embolism update***Moderator: J. Vilar; Valencia/ES***A-121** 08:30**A. How to optimise the examination technique**I. Hartmann; *Rotterdam/NL**Learning Objectives:*

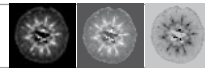
1. To understand the effect of CT equipment (4- to 64-row scanners) on the choice of the optimal image acquisition and contrast medium injection protocols.
2. To learn how dose can be minimised without compromising image quality.
3. To learn about the sources of misinterpretation with multi-detector CTA and to avoid pitfalls.
4. To become familiar with the different 3D-processing techniques that can be used to improve the interpretation of CTA for PE.

**A-122** 09:00**B. The dyspnoeic patient: Which diagnostic strategy?**L. Bonomo; *Rome/IT**Learning Objectives:*

1. To review the common causes of dyspnoea.
2. To understand the diagnostic work-up for dyspnoeic patients.
3. To review the recent publications on the performance of MDCT-PA in the evaluation of dyspnoeic patients.

**A-123** 09:30**C. Subsegmental emboli**C. Engelke; *Munich/DE**Learning Objectives:*

1. To learn about the frequency and prognostic significance of mild pulmonary embolism with one-year outcomes in high-risk patient cohorts.
2. To improve the diagnostic skills in detection and severity assessment of acute pulmonary embolism using CTA.
3. To stratify patients with acute PE according to high and low mortality risk using combined clinical and CT-based scoring techniques.



08:30 - 10:00

Room R2

## Abdominal and Gastrointestinal

### RC 501

#### Imaging in pancreatitis

Moderator: P. Soffia; Santiago/CL

**A-124** 08:30

##### A. Acute pancreatitis

N. Elmas; Izmir/TR

*Learning Objectives:*

1. To discuss the value of clinical and radiological prognostic indexes.
2. To present the role of CT, MRI, and ERCP in the acute setting and for follow-up.
3. To present unusual features of acute pancreatitis.

**A-125** 09:00

##### B. Chronic pancreatitis

W. Schima; Vienna/AT

*Learning Objectives:*

1. To review the imaging findings of chronic pancreatitis.
2. To describe the role of imaging for differentiation between chronic pancreatitis and tumor.
3. To present the imaging features of unusual types of chronic pancreatitis (i.e., groove pancreatitis).

**A-126** 09:30

##### C. Complications of pancreatitis

C. Triantopoulou; Athens/GR

*Learning Objectives:*

1. To assess the value of different imaging modalities in complicated pancreatitis.
2. To review the imaging finding of complications and the impact on prognosis.
3. To discuss radiological management of complications.



08:30 - 10:00

Room R3

## Genitourinary

### RC 507

#### Imaging of the pelvic floor

Moderator: R. Manfredi; Verona/IT

**A-127** 08:30

##### A. Assessment of anatomy and function with MRI

R.F.M. El Sayed; Cairo/EG

*Learning Objectives:*

1. To become familiar with normal anatomy of the pelvic floor supporting systems on MRI.
2. To identify the types of defects in each supporting system and how to classify them.
3. To understand how anatomical defects detected at static images can affect the type of functional abnormality of the pelvic floor supporting elements at dynamic images.
4. To discuss how the MR findings at static and dynamic images can be reported in an easy, systematic and comprehensive way.

SATURDAY

**A-128** 09:00**B. Functional MRI: When and how?**T. Fischer; *Munich/DE**Learning Objectives:*

1. To learn about the indications for functional MRI of the pelvic floor and how to perform it properly.
2. To understand the complex interactions of the pelvic floor and the pelvic organs.
3. To become familiar with common pathological conditions including cystocele, combined organ prolapse, enterocele and rectocele.

**A-129** 09:30**C. US in stress incontinence**C. Roy; *Strasbourg/FR**Learning Objectives:*

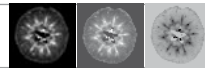
1. To review the spectrum of normal and pathologic imaging features of the sphincters with a special focus on US.
2. To learn an accurate technique for US of female pelvic floor relaxation.
3. To illustrate the clinical relevance of non-invasive diagnosis especially after unsuccessful treatment.
4. To learn how to diagnose complications after surgical treatment.

**10:30 - 12:00****Room A****“ESR meets Germany”****EM 1****Computer aided diagnosis (CAD)***Presiding:*A. Adam; *London/UK*M. Laniado; *Dresden/DE*M.F. Reiser; *Munich/DE***A-130** 10:30**Introduction**M. Laniado; *Dresden/DE**Learning Objectives:*

1. To present established programmes of CAD.
2. To review clinical applications of CAD.
3. To discuss research developments in CAD.

**A-131** 10:35**CAD in mammography**U. Bick; *Berlin/DE**Learning Objectives:*

1. To learn about the concept of computer-aided diagnosis (CAD) in mammography.
2. To understand the potential and risks of using CAD in screening mammography.
3. To realise the impact of CAD on soft-copy reading and work-flow.



**A-132** 10:53

**CAD of the lungs: Pulmonary nodules and beyond**

H.-U. Kauczor; Heidelberg/DE

*Learning Objectives:*

1. To consolidate knowledge of the benefit of software assistance to detect lung nodules.
2. To understand the rationale for CAD in airway disease and emphysema.
3. To learn about the advantages of quantification of lung disease severity for staging and monitoring.
4. To become familiar with multi dimensional imaging for the analysis of perfusion and respiratory motion.

**A-133** 11:11

**CAD in virtual colonography**

A.J. Aschoff; Ulm/DE

*Learning Objectives:*

1. To provide an overview over potential benefits of CAD in CT colonography and to understand how CAD may be used to improve diagnostic performance in the detection of polyps and masses.
2. To understand different CAD approaches in CTC and to learn about current detection performance for colorectal polyps.
3. To understand potential pitfalls in CAD.

**A-134** 11:29

**CAD of the liver: Imaging and intervention**

H.-O. Peitgen; Bremen/DE

*Learning Objectives:*

1. To learn how computer-aided volumetry can cut the errors in evaluating the response to treatment of solid liver tumors.
2. To learn how to assess the remnant function in complex liver surgery based on computer-aided risk evaluation and surgery planning.
3. To learn how to optimise the results of CT/MR-guided radio frequency ablation of liver lesions.

**Panel discussion** 11:47

---

**10:30 - 12:00**

**Room E2**

**Foundation Course: Interventional Radiology**

**E<sup>3</sup> 620**

**Musculoskeletal**

*Moderator: J.-I. Bilbao; Pamplona/ES*

**A-135** 10:30

**A. Traumatic hemorrhage**

A. Nicholson; Leeds/UK

*Learning Objectives:*

1. To be aware about the relevance of radiologists and radiographers as essential members of the trauma team.
2. To understand the importance of an accurate diagnosis since patients die from even the most innocuous vascular injuries because the principles of damage control are often ignored.
3. To be familiar with embolic agents in trauma and their methods of deployment which may depend on many factors including the patients clinical status, the amount of blood transfused and the collateral supply of the end organ that is bleeding.

**A-136** 11:15**B. Vertebroplasty**A. Gangi; *Strasbourg/FR**Learning Objectives:*

1. To explain the mechanism of action of vertebroplasty and the biomechanics of the vertebral body.
2. To discuss the indications and the exclusion criteria of percutaneous vertebroplasty.
3. To review the different types of cements and their advantages and disadvantages.
4. To explain the different access routes and different technique of vertebroplasty.
5. To review the results and the complications of vertebroplasty and how to avoid them.

**10:30 - 12:00****Room G/H****EFOMP Workshop****New technology in diagnostic radiology: High field MRI for clinical and pre-clinical studies****EF 2****Clinical applications, safety issues and regulations for very high field MRI***Moderators: S. Christofides; Nicosia/CY, G.P. Krestin; Rotterdam/NL***A-137** 10:30**Safety issues and regulations for high field MRI**M.E. Ladd; *Essen/DE**Learning Objectives:*

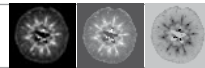
1. To learn about the physiologic effects associated with the electromagnetic fields of MR imagers.
2. To review the current standards and regulations governing the exposure of patients and workers to these electromagnetic fields.
3. To become familiar with the ethical prerequisites for performing studies in humans at very high field (7 Tesla).

**A-138** 11:00**Physical implications of a 7 Tesla MRI installation**O. Speck; *Magdeburg/DE**Learning Objectives:*

1. To comprehend the physical implications of higher magnetic field strength and thus reduced RF wave length with regard to imaging of human subjects.
2. To understand method to compensate for high RF-power absorption (SAR) and inhomogeneous radio frequency excitation and reception.
3. To become familiar with the possibilities and limitations of very high field imaging.

**A-139** 11:30**Future impact of the 7 Tesla MRI in the clinical applications**R.W. Bowtell; *Nottingham/UK**Learning Objectives:*

1. To understand the advantages that 7 T brings to MRI.
2. To comprehend the technical difficulties associated with MRI at very high magnetic field.
3. To become familiar with the areas where MRI at 7 T may provide benefits for pre-clinical and clinical studies.



12:15 - 12:45

Room B

**Plenary Session**

**HL 1**

**Wilhelm Conrad Röntgen - Honorary Lecture**

*Presiding: M.F. Reiser; Munich/DE*

**A-140** 12:15

**Pushing the speed limits in MR imaging**

J. Hennig; Freiburg/DE

*Learning Objectives:*

1. To understand the factors limiting the imaging speed in MR imaging.
2. To learn about ongoing research to overcome these limitations by new approaches to data acquisition.
3. To learn about ongoing research to overcome these limitations by new data sampling strategies.

14:00 - 15:30

Room E2

**Interactive Teaching Course: Useful Signs in Imaging**

**E<sup>3</sup> 720**

**Signs in abdominal imaging**

*Moderator: S.C. Efremidis; Ioannina/GR*

**A-141** 14:00

**A. Abdomen: Viscera**

F. Caseiro-Alves, L. Curvo-Semedo, J. Brito; Coimbra/PT

*Learning Objectives:*

1. To become familiar with the features of six imaging signs as seen on cross-sectional imaging of the liver and pancreas.
2. To understand the underlying physiopathological mechanism.
3. To be able to derive the main differential diagnosis.
4. To learn about further imaging investigations that may be useful to provide a final diagnosis.

**A-142** 14:45

**B. Abdomen: GI**

P. Rogalla; Berlin/DE

*Learning Objectives:*

1. To learn the morphologic and functional features of the GI tract and how they affect imaging.
2. To learn the principle imaging strategies of the lower alimentary tube.
3. To learn the imaging signs that help to distinguish between infectious, non-infectious and neoplastic diseases.

SATURDAY

**16:00 - 17:30**
**Room A**
**MRI**
**CC 816**
**Musculoskeletal: A step-by-step approach**
*Moderator: M. Zanetti; Zurich/CH*
**A-143** 16:00

**A. Trauma**

C. Glaser; Munich/DE

*Learning Objectives:*

1. To understand the different mechanisms of injuries and their impact on MR image interpretation.
2. To define the value of various MR sequences for implementation of robust clinical protocols.
3. To compare the value of MRI to other imaging modalities in trauma patients.
4. To describe the therapeutic consequences of positive imaging findings.

**A-144** 16:30

**B. Neoplasms**

A.M. Davies; Birmingham/UK

*Learning Objectives:*

1. To understand the typical signal and morphological features of different musculoskeletal tumors.
2. To understand the role of MRI for differential diagnosis, tumor staging and detection of recurrence.
3. To understand the additive value of combining various imaging modalities.

**A-145** 17:00

**C. Inflammatory and infectious diseases**

V.N. Cassar-Pullicino, B. Tins; Dswestry/UK

*Learning Objectives:*

1. To learn about the role of MRI for early detection and localisation of inflammatory diseases.
2. To correlate MRI findings to conventional imaging findings.
3. To assess the therapeutic effects of anti-inflammatory and antibiotic treatment.
4. To determine parameters for early response evaluation.

**16:00 - 17:30**
**Room B**
**Multidetector CT Made Easy**
**CC 817**
**The chest: A high resolution country**
*Moderator: Y. Pallardó; Valencia/ES*
**A-146** 16:00

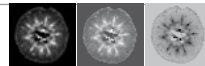
**A. Submillimetric imaging of lung parenchyma**

J.A. Verschakelen; Leuven/BE

*Learning Objectives:*

1. To compare MDCT generated high detail imaging of the lung with "classical" HRCT.
2. To become familiar with advantages and limitations of submillimetric imaging of the lung parenchyma using MDCT.
3. To understand the current clinical applications of high detail imaging of the lung parenchyma.





**A-147** 16:30

**B. Lung cancer screening: The new challenges**

T.E. Hartman; Rochester, MN/US

*Learning Objectives:*

1. To learn the current status of CT screening for lung cancer.
2. To identify the pros and cons of CT screening.
3. To identify imaging findings that allow differentiation of benign and malignant pulmonary nodules.

**A-148** 17:00

**C. Functional insights into lung and airways diseases using CT**

P.A. Grenier; Paris/FR

*Learning Objectives:*

1. To comprehend that pulmonary function test results do not reflect regional differences in disease severity, and, pathologic processes that tend to counteract each other are not reflected.
2. To understand how MDCT, providing accurate high resolution assessment of airway and lung disease at a regional level, may be a more sensitive input on clinical trials, and ultimately in a clinical management of individual asthmatic or COPD patients.
3. To become familiar with new post processing techniques permitting quantitative assessment of lung volumes, airway dimensions (airway reactivity, remodelling and collapsibility), and extent of lung disease (emphysema and small airway disease).

---

**16:00 - 17:30**

**Room C**

**"ESR meets General Practitioners"**

**EM 2**

**Manifestations of atherosclerosis: A common challenge in diagnosis and treatment**

*Presiding:*

A. Adam; London/UK

M.F. Reiser; Munich/DE

I. Svab; Ljubljana/RS

**A-149** 16:00

**Introduction**

M.F. Reiser<sup>1</sup>, I. Svab<sup>2</sup>; <sup>1</sup>Munich/DE, <sup>2</sup>Ljubljana/SI

*Learning Objectives:*

1. To compare points of view of general practitioners and radiologists in the assessment of coronary disease.
2. To discuss the relevance of guidelines.
3. To look at the potential use of coronary angiography in primary care in the future.

**A-150** 16:05

**Assessment of coronary artery disease (part I: General practitioner)**

C. Lionis; Iraklion/GR

*Learning Objectives:*

1. To be familiar with the approaches and methods used to assess the risk for development of cardiovascular disease.
2. To discuss procedural skills and diagnostic algorithms for evaluating patients at risk for coronary artery disease.
3. To discuss links on diagnostic approaches between general practitioners and radiologists.

**A-151** 16:22**Assessment of coronary artery disease (part II: Radiologist)**

N.R. Mollet; Rotterdam/NL

*Learning Objective:*

1. To discuss the potential of CT coronary angiography in the detection and classification of coronary plaques.

**A-152** 16:40**Patients with peripheral arterial obstructive disease (PAOD) in primary care (part I: General practitioner)**

M. Maier; Vienna/AT

*Learning Objectives:*

1. To appreciate the spectrum of competencies and skills required from the primary care physician in caring for patients with PAOD.
2. To recognise the special relationship between the patient and the GP.
3. To appreciate, that the GP in his/her decisions has to balance medical needs and their cost-efficiency.

**A-153** 16:57**Patients with peripheral arterial obstructive disease (PAOD) in primary care (part II: Radiologist)**

M. Treitl, M.F. Reiser; Munich/DE

*Learning Objectives:*

1. To comprehend state-of-the-art imaging modalities like whole body MRI and CT algorithms, their potentials and limitations, as well as invasive digital subtraction angiography and its role in outpatients treatment.
2. To comprehend state-of-the-art endovascular treatment options for peripheral arterial disease.
3. To become familiar with the premises for the discussed imaging modalities.
4. To become familiar with the premises and aftercare of the discussed endovascular treatment options.

**Panel discussion** 17:15**16:00 - 17:30****Room E1****Musculoskeletal****RC 810****Osteoporosis***Moderator: G. Krumina; Riga/LV***A-154** 16:00**A. Bone densitometry: The essentials**

G. Guglielmi; Foggia/IT

*Learning Objectives:*

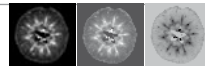
1. To describe what the radiologist ought to know about bone densitometry.
2. To analyse the pros and cons of the two most widely used techniques (DXA and QCT).
3. To describe the recently proposed criteria by the WHO regarding 10 year fracture risk assessment.

**A-155** 16:30**B. Vertebral fractures: Definition, classification and significance**

J.E. Adams; Manchester/UK

*Learning Objectives:*

1. To explain the necessity of reporting vertebral fractures.
2. To describe the radiological features that differentiate vertebral fracture from other causes of vertebral deformity.
3. To present methods of grading and quantitative morphometric assessment.



**A-156** 17:00

**C. MRI of osteoporotic insufficiency fractures**

T.M. Link; San Francisco, CA/US

*Learning Objectives:*

1. To understand the importance of correctly diagnosing osteoporotic insufficiency fractures.
2. To be familiar with the typical morphologic criteria of insufficiency fractures.
3. To know typical criteria of benign versus malignant disease.
4. To be familiar with strengths and weaknesses of MR versus CT imaging of insufficiency fractures.

---

**16:00 - 17:30**

**Room E2**

**Interactive Teaching Course: Useful Signs in Imaging**

**E<sup>3</sup> 820**

**Signs in genitourinary imaging**

*Moderator: G. Heinz-Peer; Vienna/AT*

**A-157** 16:00

**A. Retroperitoneum**

P. Soffia; Santiago/CL

*Learning Objectives:*

1. To learn some of the most important signs in genitourinary imaging.
2. To describe the pathophysiologic characteristics associated with the imaging findings.
3. To be able to recognise these signs on cross sectional imaging of the kidneys, adrenal glands and ureters.

**A-158** 16:45

**B. Pelvis**

R. Pozzi-Mucelli; Verona/IT

*Learning Objectives:*

1. To describe the characteristic imaging findings and significance of the most common radiologic signs.
2. To emphasize the importance of normal anatomy to understand pathology.
3. To show normal variants that may simulate disease.

---

**16:00 - 17:30**

**Room F1**

**Genitourinary**

**RC 807**

**What to do with all these small renal masses?**

*Moderator: D.E. Husband; London/UK*

**A-159** 16:00

**A. Detection and characterisation: How far can we reach with our imaging techniques?**

A. Cieszanowski; Warsaw/PL

*Learning Objectives:*

1. To appreciate advantages and disadvantages of different imaging techniques for the detection of renal tumors.
2. To present the imaging features of different renal masses.
3. To understand the role and limitations of imaging modalities for the differentiation of small renal masses.

**A-160** 16:30**B. Renal masses: When and why to biopsy them**

S.G. Silverman; Boston, MA/US

*Learning Objectives:*

1. To understand why percutaneous biopsy of renal masses is useful in clinical practice.
2. To learn the eight indications for percutaneous renal mass biopsy, and how results can be used to dictate clinical management.
3. To understand the role of cytology (including immunocytochemistry) in the diagnosis of renal neoplasms.

**A-161** 17:00**C. Alternative treatment: RF ablation**

B.J. Wood; Bethesda, MD/US

*Learning Objectives:*

1. To describe kidney-specific techniques for using tumor ablation in the kidney.
2. To describe methods to decrease the risk profile and increase indications for percutaneous kidney tumor ablation.
3. To understand how image guidance can facilitate kidney tumor ablation.
4. To understand the difference between liver ablation and kidney tumor ablation.
5. To be able to describe the expected outcomes and imaging for kidney tumor ablation.

**16:00 - 17:30****Room F2****Breast****RC 802****MRI of the breast***Moderator: F. Pediconi; Rome/IT***A-162** 16:00**A. Basics and new techniques**

T.H. Helbich; Toronto, ON/CA

*Learning Objectives:*

1. To review use of morphology and contrast media studies in breast MRI.
2. To introduce use of spectroscopy and diffusion imaging.
3. To understand how combining all four techniques improves performance.

**A-163** 16:30**B. Staging**

C.K. Kuhl; Bonn/DE

*Learning Objectives:*

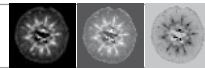
1. To understand the role of MRI in staging breast cancer.
2. To explore the impact of identifying multifocality on treatment.
3. To review if MRI is needed in every situation.

**A-164** 17:00**C. Monitoring response to neoadjuvant chemotherapy**

L. Ollivier; Paris/FR

*Learning Objectives:*

1. To understand the indication and expected results of neo adjuvant therapy in the treatment of breast cancer.
2. To review the techniques and timing of MRI in monitoring response.
3. To review the evidence for use of MRI in neo adjuvant treatment.



16:00 - 17:30

Room G/H

Neuro

RC 811

Basic MR

Moderator: P.H. Nakstad; Oslo/NO

A-165 16:00

**A. From signal to diagnosis: Basic interpretation of T1 and T2 behaviour of brain lesions**

G. Wilms; Leuven/BE

Learning Objectives:

1. To learn the types of the different signal intensities on conventional T1- and T2-weighted MR images.
2. To correlate the signal intensities with biochemical and pathological findings, with the implications of specific MR effects and artifacts.
3. To use the combination of T1- and T2-signal intensities to arrive at the diagnosis and differential diagnosis of brain lesions.

A-166 16:30

**B. Differential diagnosis of bright lesions on diffusion-weighted MR images**

M.M. Thurnher; Vienna/AT

Learning Objectives:

1. To recapitulate the basic principles of diffusion-weighted MR imaging (DWI).
2. To discuss the importance of DWI and ADC measurements in the diagnosis and differential diagnosis of brain lesions.
3. To report on uncommon causes of diffusion restriction.

A-167 17:00

**C. Cortical anatomy on MR**

T.A. Youstry; London/UK

Learning Objective:

1. To learn the different methods by which important eloquent areas of the cortex are localised on conventional MRI.  
These include:
  - a) The primary sensorimotor cortex, specifically the central sulcus
  - b) The motor and sensory speech areas
  - c) The primary auditory and visual areas.

16:00 - 17:30

Room I

Vascular

RC 815

Non-invasive imaging of the lower limb venous system

Moderator: P.M.T. Pattynama; Rotterdam/NL

A-168 16:00

**A. Anatomy and physiology: Correlation with imaging**

V. Bérczi; Budapest/HU

Learning Objectives:

1. To understand venous anatomy and physiology.
2. To demonstrate clinical relevance and indications.
3. To correlate anatomy and physiology with imaging.

**A-169** 16:30**B. Sonography: Clinical applications and results**

N. Grenier; Bordeaux/FR

*Learning Objectives:*

1. To describe the features and performances of acute and chronic venous thrombosis.
2. To discuss the place of sonography in the diagnostic strategy.
3. To describe the main features of venous insufficiency.

**A-170** 17:00**C. CTA and MRA: Is there a role?**

B. Ghaye; Liège/BE

*Learning Objectives:*

1. To learn how to perform CTA and MRA.
2. To understand why CTA and MRA can be of interest.
3. To learn what the future holds for the technique.

**16:00 - 17:30****Room K****RTF - Radiology Trainees Forum****TF 1****Highlighted Lectures***Moderators: P.R. Kornaat; Leiden/NL, C. Nyhsen; Newcastle upon Tyne/UK***A-171** 16:00**Always hypertension? What else can be the cause of intracerebral hemorrhage?**

M. Forsting; Essen/DE

*Learning Objectives:*

1. To comprehend the pathophysiology of intracerebral bleeding.
2. To understand that hypertension is just one of several causes of intracerebral bleeding.
3. To become familiar with certain vascular malformations, the diagnostic work-up and the endovascular therapy.

**A-172** 16:30**Vascular interventions today: Challenges and opportunities**

J.A. Reekers; Amsterdam/NL

*Learning Objectives:*

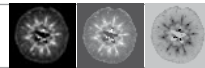
1. To comprehend the position of IR in Europe today.
2. To understand which vascular IR procedures will become important in the near future.
3. To become familiar with peripheral vascular disease and opportunities in diabetic patients.

**A-173** 17:00**Pitfalls in trauma imaging**

N. Raby; Glasgow/UK

*Learning Objectives:*

1. To show the significance of asymmetry of the peg in isolation.
2. To become familiar with additional signs to help in evaluation of the upper spine.



16:00 - 17:30

Room L/M

**Special Focus Session**

**SF 8a**

**Fat radiology: Imaging in obesity and metabolic syndrome**

*Moderator: W. Torreggiani; Dublin/IE*

**A-174** 16:00

**Chairman's introduction**

W. Torreggiani; Dublin/IE

*Session Objectives:*

1. To learn about the radiological implications of the growing problem of obesity.
2. To learn about diseases that are more frequent in the obese population and how to image them.
3. To review obesity related surgical procedures and their complications.

**A-175** 16:05

**The implications of obese patients for radiologists and clinicians**

D. Buckley; Dublin/IE

*Learning Objectives:*

1. To learn about the epidemiology of obesity.
2. To understand the aetiology of obesity.
3. To illustrate how radiology can help in the evaluation of obesity and how obesity can hinder the evaluation of an affected patient.

**A-176** 16:30

**Optimising imaging obese patients**

A.G. Ryan; Waterford City/IE



*Learning Objectives:*

1. To understand the challenges posed in imaging obese patients.
2. To understand how to diagnose diseases associated with obesity.
3. To have an awareness of the newer techniques used in the quantitative and qualitative analysis of obesity.

**A-177** 16:55

**Imaging of morbid obesity procedures and their complications**

S.W. Trenkner; Rochester, MN/US

*Learning Objectives:*

1. To understand the surgical procedures used to treat morbid obesity which includes: vertical banded gastroplasty, gastric bypass, adjustable gastric band and duodenal switch.
2. To understand the fluoroscopic and CT techniques used to study patients after the above procedures.
3. To understand the normal and pathological post-operative appearance of these procedures.

**Panel discussion:**

**Are we doing enough to optimise imaging of the obese patient?** 17:20

SATURDAY

**16:00 - 17:30**
**Room N/O**
**Head and Neck**
**RC 808**
**Imaging after treatment of head and neck tumors**
*Moderator: A. Trojanowska; Lublin/PL*
**A-178** 16:00

**A. Tissue changes after treatment: The expected ones**

R.D. Brüning; Hamburg/DE

*Learning Objectives:*

1. To explain the principal surgical and radiation techniques in head and neck cancer.
2. To learn the expected imaging features after surgery.
3. To learn the expected imaging features after radiation therapy.

**A-179** 16:30

**B. Tumor recurrence and treatment complications: The feared ones**

R.C. Sigal; G. Bonardel, F. Bidault; Villejuif/FR

*Learning Objectives:*

1. To describe the imaging findings in tumor recurrence and treatment complications, and how to differentiate them.
2. To assess the impact of PET and PET/CT.
3. To propose imaging strategies to follow-up patients, and to detect tumor recurrence at an early stage.

**A-180** 17:00

**C. Imaging alterations due to denervation**

A. Borges; Lisbon/PT

*Learning Objectives:*

1. To learn how to recognise imaging features of denervation atrophy to avoid confusion with other pathologies.
2. To recognise typical patterns of denervation muscular atrophy in the head and neck.
3. To provide imaging clues to lesion location and extent based on the atrophy pattern.
4. To become familiar with the most frequent causes of denervation in the face and neck.

**16:00 - 17:30**
**Room R1**
**Cardiac**
**RC 803**
**How to perform a complete CT/MR examination of the heart**
*Moderator: L. Natale; Rome/IT*
**A-181** 16:00

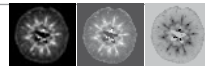
**A. CT examination of the heart**

F. Cademartini; Rotterdam/NL

*Learning Objectives:*

1. To learn how to conduct and report on a CT examination of the coronary arteries.
2. To learn how to assess ventricular function by CT.
3. To learn how to assess inflammatory diseases of the heart by CT.
4. To learn how to assess valve function by CT.





**A-182** 16:30

**B. MR examination of the heart**

J. Bogaert; *Leuven/BE*

*Learning Objectives:*

1. To learn how to perform a cardiac MRI examination, limitations and indications.
2. To understand the role of cardiac MRI in assessing ventricular function.
3. To understand the role of MRI in the diagnosis of inflammatory diseases of the heart.
4. To learn how to perform perfusion imaging of the heart in MRI in the assessment of ischemia.

**A-183** 17:00

**C. Examination of the heart in children**

A.J.B.S. *Madureira; Porto/PT*

*Learning Objectives:*

1. To understand the use of multislice CT in the examination of the heart in children, risks and indications compared to other imaging techniques.
2. To learn the use of multislice CT in the follow-up of children treated for heart disease.
3. To understand the role of MRI in imaging of the heart in children.

---

**16:00 - 17:30**

**Room R2**

**Abdominal and Gastrointestinal**

**RC 801**

**Imaging of the acute abdomen**

*Moderator: M. Marotti; Zagreb/HR*

**A-184** 16:00

**A. Diagnosis of acute abdomen: Any imaging prior to MDCT?**

P.-A. *Poletti; Geneva/CH*

*Learning Objectives:*

1. To review the contemporary role of plain abdominal films.
2. To discuss the added value of US.
3. To understand the limitations of plain abdominal films and how to choose between US and CT when necessary.

**A-185** 16:30

**B. CT as the first line examination**

P. *Taourel; Montpellier/FR*

*Learning Objectives:*

1. To present multislice CT protocols for examinations for acute abdomen based on working clinical diagnosis.
2. To present keys for interpretation of acute abdomen useful for emergency radiologists who are not always specialised in GI imaging.
3. To illustrate the most common CT pitfalls and diagnostic errors in the interpretation of acute abdomen.

**A-186** 17:00

**C. Increasing role for emergency MRI?**

K. *Schunk; Koblenz/DE*

*Learning Objectives:*

1. To discuss the spectrum of potential MRI indications in the acute abdomen.
2. To illustrate the role of MRI, especially hydro-MRI in acute inflammatory bowel disease.
3. To explain the requirements and examination techniques for abdominal MRI in the acute setting.

**16:00 - 17:30****Room R3****Interventional Radiology****RC 809****Percutaneous interventions in musculoskeletal disease***Moderator: L. Pierot; Reims/FR***A-187** 16:00**A. Vertebroplasty and kyphoplasty**

J. Blasco Andaluz; Barcelona/ES

*Learning Objectives:*

1. To discuss the indications and technique of percutaneous vertebroplasty and kyphoplasty.
2. To discuss the limitations and contraindications of percutaneous vertebroplasty and kyphoplasty.
3. To learn about the complications of percutaneous vertebroplasty and kyphoplasty.

**A-188** 16:30**B. Discs and facet joints**D.A. Rufenacht<sup>1</sup>, A. Cahana<sup>1</sup>, A.D. Kelekis<sup>2</sup>; <sup>1</sup>Geneva/CH, <sup>2</sup>Athens/GR*Learning Objectives:*

1. To learn about the limitations and contraindications of percutaneous degenerative disc treatment.
2. To review the indications, techniques, results and complications of percutaneous degenerative disc treatment.
3. To discuss the role of interventional radiology in the treatment of facet joint disease.

**A-189** 17:00**C. Bone biopsy and RF ablation**

A.D. Kelekis; Athens/GR

*Learning Objectives:*

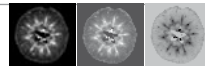
1. To discuss the indications, techniques, results and complications of bone biopsy.
2. To review the indications and techniques of RF ablation in the skeletal system.
3. To learn about the results and complications of RF ablation in the skeletal system.

**16:00 - 17:30****Room Z****Special Focus Session****SF 8b****Novel image analysis and modelling techniques to improve diagnosis and therapy of cancer** (an IMAGINE - the high-tech specialty exhibit - session)*Moderator: W.J. Niessen; Rotterdam/NL***A-190** 16:00**Chairman's introduction**

W.J. Niessen; Rotterdam/NL

*Session Objectives:*

1. To learn about novel imaging technology underlying advances in cancer diagnosis and therapy.
2. To be introduced to IMAGINE, the high-tech specialty exhibit at ECR which shows novel and exciting developments in diagnostic and interventional radiology.



**A-191** 16:05

**Tumor response imaging biomarkers: A practical framework for development**

A.R. Padhani; *Northwood/UK*

*Learning Objectives:*

1. To be able to distinguish biomarkers for surrogate markers.
2. To know how to choose a biomarker for development as a response variable.
3. To be able to describe in detail the steps needed for qualifying a biomarker as a response variable in individual patients.

**A-192** 16:23

**Cutting the errors in evaluating the response to treatment in solid tumor**

H.-O. Peitgen; *Bremen/DE*

*Learning Objectives:*

1. To learn how computer aided volumetry can cut the errors in evaluating the response to treatment of solid liver tumors.
2. To learn about fundamental benefits of 3D volumetry in contrast to 2D measurements for the estimation of tumor growth.
3. To understand that volumetric measurements provide subvoxel accurate lesion size assessment whereas diameter based classifications suffer from high degrees of interobserver variability.
4. To understand the influence of error propagation on the computation of change rates.

**A-193** 16:41

**Oncological image analysis: Medical and molecular imaging**

M. Brady; *Oxford/UK*

*Learning Objectives:*

1. To understand the issues involved in estimating the CRM.
2. To learn the use of image analysis for assessing tumour response to chemotherapy.
3. To understand how image analysis can provide assessment of ablation therapy non-invasively.

**A-194** 16:59

**Image guidance in interventional radiology and radiotherapy**

D.J. Hawkes; *London/UK*

*Learning Objectives:*

1. To introduce the workflow of image directed therapy and image guided interventions: Pre-operative planning, registration of plan to treatment coordinates, update of plan with real-time imaging during therapy, treatment monitoring and therapy assessment.
2. To understand the limitations of currently available technologies.
3. To become familiar with work in progress to address these limitations.

**Panel discussion:**

**Can new technology cut errors in cancer diagnosis and treatment?** 17:17

**08:30 - 10:00****Room A****Neuro****CC 916****Neuro: Conquering important territories***Moderator: D. Goldsher; Haifa/IL***A-195** 08:30**A. Spine: Degenerative disc disease***M. Gallucci; L'Aquila/IT**Learning Objectives:*

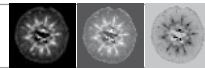
1. To define the various stages of degenerative disc disease.
2. To classify the different types of disc protrusion and prolapse.
3. To understand the predisposing conditions for degenerative changes.
4. To learn about new 3D sequences for assessment of spinal canal stenosis and compare them to CT myelography.

**A-196** 09:00**B. Demyelinating diseases and myelopathy***V. Dousset; Bordeaux/FR**Learning Objectives:*

1. To become familiar with the major differential diagnoses of demyelinating diseases.
2. To describe their typical distribution pattern.
3. To define the activity of disease with established and evolving MRI techniques.

**A-197** 09:30**C. Trauma and hemorrhage***M. Stajgis; Poznan/PL**Learning Objectives:*

1. To understand the value of current MRI sequences for detection of intracranial hemorrhage.
2. To compare their accuracy to CT for detection and classification of different subtypes.
3. To become familiar with new sequence developments for detection of micro-bleedings and diffuse axonal injury in trauma patients.
4. To define a routine MRI protocol for imaging of patients with acute spinal injury.



**Multidetector CT Made Easy**

**CC 917**

**Bones and joints: CT is still alive!**

*Moderator: G.B. Adam; Hamburg/DE*

**A-198** 08:30

**A. The spine: Valta CT/ MRI?**

D. Weishaupt; Zurich/CH

*Learning Objectives:*

1. To describe the technological advances of MDCT for spinal imaging.
2. To discuss the current CT and MR approaches to image the spine.
3. To discuss the value of CT and MR in imaging of traumatic, degenerative and neoplastic affections of the spine.
4. To demonstrate the advantages of integrated imaging of the spine using combined CT and MR imaging capabilities.

**A-199** 09:00

**B. Polytraumatized patient: CT as the first line technique**

R.A. Novelline; Boston, MA/US

*Learning Objectives:*

1. To learn the optimum MDCT protocols for imaging the polytraumatized patient, including protocols for single acquisition "total body" trauma MDCT scans.
2. To review with clinical examples the MDCT manifestations of common and uncommon traumatic conditions.
3. To understand the role of MDCT image post-processing in the diagnosis of polytrauma with emphasis on multiplanar and volume rendered (3DCT and CTA) reformations.

**A-200** 09:30

**C. Peripheral bones and joints: What is left for CT?**

T. Marshall; Norwich/UK

*Learning Objectives:*

1. To become familiar with the current main uses for MDCT of the peripheral skeleton.
2. To understand how MDCT compares to other imaging techniques.
3. To know how to optimise the scanning parameters for 3D reconstructions of the peripheral skeleton.

**08:30 - 10:00****Room C****New Horizons Session****NH 9****Above 3T: Clinical tool or toys for the boys?***Moderator: D.G. Norris; Nijmegen/NL***A-201** 08:30**Chairman's introduction**D.G. Norris; Nijmegen/NL*Session Objectives:*

1. To learn about the potential clinical value of 7 T systems for head and body.
2. To appreciate the challenges of imaging at 7 T and beyond.
3. To understand the current status of 7 T imaging.
4. To appreciate the resources required for a successful 7 T facility.

**A-202** 08:35**New perspectives on extremely high field applications**J. Hennig; Freiburg/DE*Learning Objectives:*

1. To understand the special imaging physics associated with 7 T.
2. To learn about how multi-coil technology can accelerate data acquisition.
3. To appreciate techniques for minimising RF power deposition whilst maintaining sensitivity.

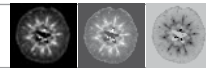
**A-203** 08:55**Neuroimaging: Potential clinical benefits**D.P. Auer; Nottingham/UK*Learning Objectives:*

1. To be able to recognise neuroanatomical detail in MRI scans at 7 T.
2. To understand the main diagnostic advantages and limitations of cerebral MRI at 7 T.
3. To appreciate the potential for neurometabolic assessment at 7 T.
4. To gain preliminary insight into clinical neuroapplications at 7 T.

**A-204** 09:15**Whole body imaging: A challenge apart**M.E. Ladd; Essen/DE*Learning Objectives:*

1. To understand the specific difficulties caused by radiofrequency inhomogeneity at 7 T.
2. To learn about radiofrequency coil design and special excitation techniques at 7 T.
3. To understand the potential gains in performing abdominal investigations at very high field.

**Panel discussion:****Acquiring a 7 T system: Are there short term gains or is this a long term investment?** 09:35



08:30 - 10:00

Room E1

## Musculoskeletal

### RC 910

#### Hip

Moderator: H. Imhof; Vienna/AT

**A-205** 08:30

#### A. Femoroacetabular impingement

S.E. Anderson<sup>1</sup>, M. Tannast<sup>2</sup>, K.A. Siebenrock<sup>2</sup>; <sup>1</sup>Melbourne/AU, <sup>2</sup>Berne/CH

#### Learning Objectives:

1. To review the clinical and surgical aspects of the main subtypes of femoroacetabular impingement.
2. To illustrate the classic radiographic and MRI imaging appearances of femoroacetabular impingement.
3. To discuss some imaging pitfalls and solutions.
4. To present future scientific areas of research.

**A-206** 09:00

#### B. Femoral head edema

B. Vande Berg; Brussels/BE

#### Learning Objectives:

1. To define the generic term of bone marrow edema of the femoral head as seen on MR imaging.
2. To remind the audience that bone marrow edema should be regarded as a sign of an ongoing abnormal process.
3. To emphasise the role of the radiologists in making a specific diagnosis, by focussing on ancillary MR findings.
4. To illustrate the importance of other imaging modalities.

**A-207** 09:30

#### C. Sports injuries

M. Padrón; Madrid/ES

#### Learning Objectives:

1. To review the impact of sports on the hip depending on loading and type of activity.
2. To discuss the role of different imaging modalities.
3. To classify injuries into three categories: Bone lesions, intraarticular derangements and musculotendinous unit lesions.
4. To emphasise how imaging findings can influence patient management.

SUNDAY

---

**08:30 - 10:00****Room E2****Interactive Teaching Session****E<sup>3</sup> 920a****Classifying breast lesions: The BI-RADS™ exercise***Moderator: M.G. Wallis; Cambridge/UK***A-208** 08:30**Classifying breast lesions: The BI-RADS™ exercise**I. Tocino<sup>1</sup>, C.S. Balleyguier<sup>2</sup>; <sup>1</sup>New Haven, CT/US, <sup>2</sup>Villejuif/FR*Learning Objectives:*

1. To understand the clinical role of an international classification of breast lesions.
2. To know that the classification was initially designed for mammography and recently extended to ultrasonography and MRI.
3. To be able to accurately classify a representative panel of 10 cases.
4. To understand the clinical applications of the BI-RADS classification with a special interest for BI-RADS 3 and 4.

---

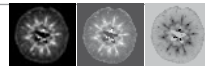
**08:30 - 10:00****Room F1****Interactive Teaching Session****E<sup>3</sup> 920b****Inflammatory small bowel diseases***Moderator: A. Laghi; Latina/IT***A-209** 08:30**Inflammatory small bowel diseases**

N. Gourtsoyannis, S.D. Yarmenitis; Iraklion/GR

*Learning Objectives:*

1. To review the pathology of small bowel Crohn's disease.
2. To describe its imaging characteristics vis-à-vis pathology correlation.
3. To discuss strengths and limitations of US, CT and MR imaging versus barium examinations in the differential diagnosis of Crohn's disease.





08:30 - 10:00

Room F2

**Special Focus Session**

**SF 9a**

**Cardiothoracic CT: One test solves all**

Moderator: M. Rémy-Jardin; Lille/FR

**A-210** 08:30

**Chairman's introduction**

M. Rémy-Jardin; Lille/FR

*Session Objectives:*

1. To understand the current concept of cardiothoracic imaging.
2. To become familiar with the scanning parameters and their clinical value for patients with respiratory problems.
3. To consolidate knowledge of low-dose ECG-gated CT examinations of the chest for general radiologists.

**A-211** 08:35

**Examination techniques**

K. Nikolaou; Munich/DE

*Learning Objectives:*

1. To learn about the different scanning parameters to analyse the heart.
2. To understand the principles of ECG-gated CT scans of the entire thorax.
3. To become familiar with the scanning conditions applicable to patients with respiratory problems.

**A-212** 08:57

**Should chest radiologists look at the heart?**

P.A. Grenier; Paris/FR

*Learning Objectives:*

1. To recognise the nonspecific nature of respiratory symptoms.
2. To review the cardiac consequences of respiratory diseases.
3. To understand lung and heart comorbidity.

**A-213** 09:19

**Acute chest pain**

C.S. White; Baltimore, MD/US

*Learning Objectives:*

1. To describe the stratification of patients who present to the emergency room with chest pain.
2. To review conventional imaging approaches to assessing chest pain including chest radiography and stress testing.
3. To discuss the potential utility of CTA in chest pain evaluation.

**Panel discussion:**

**ECG-gated CT angiography of the chest: An alternative or a complementary scanning protocol for chest diseases?** 09:41

SUNDAY

**08:30 - 10:00****Room G/H****Special Focus Session****SF 9b****Hybrid imaging: PET/CT, SPECT/CT, PET/MRI ..., where next?***Moderator: A. Bischof Delaloye; Lausanne/CH***A-214** 08:30**Chairman's introduction***A. Bischof Delaloye; Lausanne/CH**Session Objectives:*

1. To inform about current hybrid imaging techniques.
2. To inform about potential developments in instrumentation.
3. To present emerging new radiopharmaceuticals.
4. To discuss the added value of hybrid imaging in patient management.

**A-215** 08:35**PET/CT: Trends and future developments***L. Højgaard; Copenhagen/DK**Learning Objectives:*

1. To understand the concept of current PET/CT instruments and potential developments.
2. To learn about misalignments.
3. To understand the uptake mechanisms of <sup>18</sup>F-FDG.
4. To learn about the development of and indications for emerging radiopharmaceuticals.

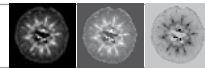
**A-216** 08:57**SPECT/CT: The new workhorse?***T. Kuwert; Erlangen/DE**Learning Objectives:*

1. To understand the concept of current SPECT/CT instruments and potential developments.
2. To learn what SPECT/CT adds to conventional radiological imaging.
3. To learn what SPECT/CT adds to conventional nuclear medicine imaging.

**A-217** 09:19**PET/MRI: The next racehorse?***R. Krieg<sup>1</sup>, R. Ladebeck<sup>1</sup>, N. Rietsch<sup>1</sup>, M. Schmand<sup>2</sup>; <sup>1</sup>Erlangen/DE, <sup>2</sup>Knoxville, TN/US**Learning Objectives:*

1. To understand the principal difficulties of bringing together these two different techniques in a single instrument.
2. To learn if SPECT/MRI is an option.
3. To learn about advantages (beyond dosimetry) of PET/MRI over PET/CT.
4. To learn when such instruments are expected to be available for clinical use.

**Panel discussion:****Is there a real need for more than PET/CT? Has PET(SPECT)/MRI the potential to ultimately replace PET-SPECT/CT?** 09:41



08:30 - 10:00

Room I

**Physics in Radiology**

**RC 913**

**MR-guided cardiovascular interventions**

*Moderators: J. Bittoun; Le Kremlin-Bicêtre/FR, C. Thomsen; Copenhagen/DK*

**A-218** 08:30

**A. Instrument visualisation techniques**

H.H. Quick; Essen/DE

*Learning Objectives:*

1. To explain the additional hardware and software components necessary for performing MR-guided cardiovascular interventions.
2. To explain the advantages and disadvantages of various strategies for visualising and following vascular instruments in MRI.
3. To provide examples of MR-guided interventional procedures performed with current interventional MR setups.

**A-219** 09:00

**B. Endovascular applications**

F.K. Wacker; Berlin/DE

*Learning Objectives:*

1. To provide an overview of potential clinical applications in the emerging field of MR guided intervention.
2. To introduce clinical, technical, and safety issues that will enable the participants to start thinking about MR-guided endoluminal and endovascular interventions at their home institutions.

**A-220** 09:30

**C. Cardiac applications**

E. Atalar; Ankara/TR

*Learning Objectives:*

1. To introduce real-time cardiac imaging techniques.
2. To explain the use of injection and puncture needles in MR-guided cardiac interventions.
3. To introduce MR-guided cardiac electrophysiology technology.

SUNDAY

**08:30 - 10:00****Room K****Special Focus Session****SF 9c****Imaging your youngest patients: Fetal MRI***Moderator: T.A.G.M. Huisman; Zurich/CH***A-221** 08:30**Chairman's introduction***T.A.G.M. Huisman; Zurich/CH**Session Objectives:*

1. To present all currently available and future state-of-the-art fetal MRI techniques.
2. To be familiar with the normal and pathological fetal anatomy of the central nervous system, thorax and abdomen.
3. To discuss imaging findings concerning their impact on pregnancy management, possible fetal treatment and peri- and postnatal care, as well as their value concerning parental counselling for future pregnancies.

**A-222** 08:35**Patient preparation and MRI technique***D. Prayer; Vienna/AT**Learning Objectives:*

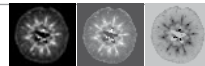
1. To understand patient preparation for fetal MRI.
2. To comprehend the importance of correct coil positioning.
3. To become familiar with sequence-selection with respect to the clinical question.

**A-223** 08:53**Central nervous system***T.A.G.M. Huisman; Zurich/CH**Learning Objectives:*

1. To learn the normal anatomy of the fetal CNS.
2. To understand the indications for fetal MRI of the CNS.
3. To understand the impact of findings on pregnancy management, fetal treatment and parental counselling.
4. To outline future perspectives.

**A-224** 09:11**Thorax***M. Hörmann; Vienna/AT**Learning Objectives:*

1. To learn the normal anatomy of the fetal thorax.
2. To understand the indications for fetal MRI of the thorax.
3. To understand the impact of findings on pregnancy management, fetal treatment and parental counselling.
4. To outline future perspectives.



**A-225** 09:29

**Abdomen**

F.E. Avni; *Brussels/BE*

*Learning Objectives:*

1. To learn the normal anatomy of the fetal abdomen.
2. To understand the indications for fetal MRI of the abdomen.
3. To understand the impact of findings on pregnancy management, fetal treatment and parental counselling.
4. To outline future perspectives.

**Panel discussion:**

**Does fetal MRI change pre-, peri- or postnatal management?** 09:47

---

**08:30 - 10:00**

**Room L/M**

**Radiographers**

**RC 914**

**MRI**

*Moderators: C. Garvey; Liverpool/UK, K. Thanassoulas; Athens/GR*

**A-226** 08:30

**A. Advanced neuro imaging**

N. Delikanakis; *Athens/GR*

*Learning Objectives:*

1. To understand the physical and physiological principles applied in functional magnetic resonance imaging, magnetic resonance spectroscopy and diffusion tensor imaging.
2. To become familiar with the implementation methods, the responsibilities of the technologist and the possible pitfalls.
3. To understand the areas of application and the additional clinical information that these techniques can provide for the detection and assessment of disorders of the central nervous system.

**A-227** 09:15

**B. Artifacts in clinical MRI: Identification and correction**

J. Castillo; *Msida/MT*

*Learning Objectives:*

1. To review the various types of artifacts in magnetic resonance imaging.
2. To learn how to identify them and suggest ways to correct them.

---

**08:30 - 10:00****Room N/O****Molecular Imaging****MC 919****Cancer and inflammation***Moderator: K. Åhlström Riklund; Umeå/SE***A-228** 08:30**A. Neurological diseases**

M. Hoehn; Cologne/DE

*Learning Objectives:*

1. To review the different optional routes of contrast agent application for selective cell labeling.
2. To outline the mechanisms of contrast agent incorporation and the cell viability consequences.
3. To review the present state-of-the-art of application of labeled cell imaging to neurological diseases in the animal experiment.
4. To discuss the options, limits and challenges for future developments and applications.

**A-229** 09:00**B. Diabetes**

M. Hájek; Prague/CZ

*Learning Objectives:*

1. To understand the needs of transplantation of pancreatic islets for the treatment of diabetes.
2. To review possibilities of molecular imaging for visualisation of pancreatic islets.
3. To comprehend principles of visualisation of pancreatic islets after their transplantation.
4. To review perspectives of molecular imaging in diabetes.

**A-230** 09:30**C. Clinical applications**

O. Clément; Paris/FR

*Learning Objectives:*

1. To review the possible clinical applications of cellular therapies.
2. To understand how cellular imaging can be useful for treatment evaluation.
3. To illustrate cellular imaging with examples in humans.

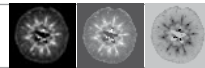
---

**08:30 - 10:00****Room R1****Cardiac****RC 903****The atherosclerotic plaque***Moderator: E. Spüntrup; Cologne/DE***A-231** 08:30**A. CT plaque imaging and characterisation**

A. Küttner; Erlangen/DE

*Learning Objectives:*

1. To understand the importance of plaque imaging in the diagnosis of coronary artery disease.
2. To explain the methods and equipment used in invasive and non-invasive coronary plaque imaging.
3. To understand the interpretation of results of non-invasive plaque imaging.



**A-232** 09:00

**B. MR plaque imaging and differentiation**

Z.A. Fayad; *New York, NY/US*

*Learning Objectives:*

1. To demonstrate the methods of plaque imaging with MRI.
2. To understand the advantages and limitations of plaque imaging using MRI.
3. To discuss the clinical relevance of plaque imaging by MRI.

**A-233** 09:30

**C. Calcium scoring and CT angiography in clinical practice**

G. Feuchtnner; *Innsbruck/AT*

*Learning Objectives:*

1. To understand the shortcomings of coronary risk assessment based on cardiovascular risk factors.
2. To discuss the current evidence on the predictive value of coronary events when calcium scoring is added to risk factor assessment.
3. To discuss the possible role of calcium scoring in cardiovascular risk assessment, its limitations and its role before coronary CT angiography.
4. To discuss the value of aortic valve calcium scoring as a risk factor and its potential in clinical practice.

---

**08:30 - 10:00**

**Room R2**

**Abdominal and Gastrointestinal**

**RC 901**

**Small nodules in the cirrhotic liver: What to do?**

*Moderator: C. Aubé; Angers/FR*

**A-234** 08:30

**A. Surveillance of the cirrhotic patient**

C. Bru; *Barcelona/ES*

*Learning Objectives:*

1. To describe the epidemiology and geographical distribution of hepatocellular carcinoma.
2. To identify the patient population at risk for the development of hepatocellular carcinoma.
3. To illustrate surveillance protocols used for early detection of hepatocellular carcinoma.

**A-235** 09:00

**B. How to characterise a small focal lesion in cirrhosis**

D. Cioni; *Pisa/IT*

*Learning Objectives:*

1. To illustrate the spectrum of hepatocellular nodular lesions emerging in a cirrhotic liver.
2. To present the imaging findings useful for the differentiation between dysplastic nodules and early-stage hepatocellular carcinoma.
3. To describe a rationale diagnostic management of small nodules detected by ultrasound surveillance in cirrhotic patients.

**A-236** 09:30**C. When and how to treat**C.D. Becker; *Geneva/CH**Learning Objectives:*

1. To describe the spectrum of therapeutic options for early-stage hepatocellular carcinoma.
2. To present imaging findings that are useful for proper therapeutic planning.
3. To describe the advantages and limitations of different therapeutic options.

**08:30 - 10:00****Room R3****Genitourinary****RC 907****Imaging of the male genitalia***Moderator: G. Malahias; Athens/GR***A-237** 08:30**A. The acute scrotum**L.E. Derchi; *Genoa/IT**Learning Objectives:*

1. To learn technical settings in ultrasound and MRI necessary to image the acute scrotum.
2. To understand imaging findings in patients with torsion, trauma and acute inflammatory disease.
3. To know rare causes of the acute scrotum.

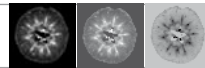
**A-238** 09:00**B. Testicular tumors**R.H. Oyen; *Leuven/BE**Learning Objectives:*

1. To stress that ultrasound remains the key imaging modality to assess testicular mass lesions.
2. To identify common and unusual testicular tumors, and to recognise US and MR imaging features allowing differentiation.
3. To recognise the most common pseudotumors.
4. To illustrate the feasibility of sparing testis surgery in selected cases like hypofertile men.

**A-239** 09:30**C. The penis**P. Pavlica; *Bologna/IT**Learning Objectives:*

1. To understand anatomic and functional imaging of the penis obtained with ultrasonography and MR imaging.
2. To know appropriate imaging techniques to detect and evaluate vascular disease.
3. To identify the main anatomic lesions of the penis and to classify the erectile dysfunction into appropriate categories.
4. To provide differential diagnoses of lesions in the penis and surrounding structures.





**“ESR meets Israel”**

**EM 3**

**Views and impressions from radiology in Israel**

*Presiding:*

A. Adam; London/UK

M. Graif; Tel Aviv/IL

M.F. Reiser; Munich/DE

**A-240** 10:30

**Introduction**

M. Graif; Tel Aviv/IL

*Learning Objective:*

1. To become familiar with the history, training programmes and utilisation patterns of the radiological profession in Israel.

**A-241** 10:35

**The hi-tech environment in Israel: Contribution of the radiological community to projects in medical imaging**

Y. Inbar<sup>1</sup>, T. Gaspar<sup>2</sup>; <sup>1</sup>Tel Hashomer/IL, <sup>2</sup>Haifa/IL

*Learning Objectives:*

1. To learn about the extension of hi-tech activity in Israel in the field of medical imaging.
2. To understand the role of the radiologist in research and development.
3. To appreciate the dynamics and impact of creative projects on the current and future of the radiological practice.

**A-242** 10:59

**Patterns of CT utilisation in emergency medicine: From the single patient to mass casualties**

A. Blachar<sup>1</sup>, A. Engel<sup>2</sup>; <sup>1</sup>Tel Aviv/IL, <sup>2</sup>Haifa/IL

*Learning Objectives:*

1. To learn about the pattern of usage of CT in daily emergencies and in mass casualty events.
2. To understand the role of radiologists and radiology departments in such situations.
3. To consolidate the knowledge of daily work flow routines and preparedness conceptions in diverse scales of emergency situations.

**A-243** 11:23

**Large scale radiological projects and surveys: Local data and comparison with international database**

D. Shaham, J. Sosna; Jerusalem/IL

*Learning Objectives:*

1. To learn about national and multi-centric radiological surveys in Israel.
2. To appreciate similarities and differences in comparison to other countries.

**Panel discussion** 11:47

---

**10:30 - 12:00****Room E2****Interactive Teaching Course: Useful Signs in Imaging****E<sup>3</sup> 1020****Signs in chest imaging***Moderator: J.A. Verschakelen; Leuven/BE***A-244** 10:30**A. Lungs***J. Cáceres; Barcelona/ES**Learning Objectives:*

1. To review a list of diagnostic signs in conventional radiography and CT.
2. To learn to recognise useful diagnostic signs in conventional radiography and CT.
3. To emphasise the role of conventional radiography in detecting valuable information.

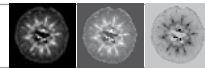
**A-245** 11:15**B. Mediastinum and pleura***C.J. Herold; Vienna/AT**Learning Objectives:*

1. To familiarise the audience with the most important signs in imaging the mediastinum and the pleura.
2. To explain the anatomic, pathophysiologic and radiologic basis for imaging signs in the mediastinum and the pleura
3. To demonstrate how these imaging signs impact on daily radiology practice.

---

**12:15 - 12:45****Room B****Plenary Session****HL 2****Josef Lissner - Honorary Lecture***Presiding: M.F. Reiser; Munich/DE***A-246** 12:15**The coming of age of imaging in biomedical research***J.H. Thrall; Boston, MA/US**Learning Objectives:*

1. To understand important directions in radiology research.
2. To understand how imaging methods are becoming applied in basic bioscientific research.
3. To learn how interdisciplinary teams can accelerate research progress.



16:00 - 17:30

Room A

**MRI**

**CC 1216**

**Vascular: From head to toe**

*Moderator: J.F.M. Meaney; Dublin/IE*

**A-247** 16:00

**A. Atherosclerosis**

H.J. Michaely; Mannheim/DE

*Learning Objectives:*

1. To understand how to optimise temporal and spatial resolution of contrast-enhanced MRA at different field strengths using different MR contrast agents.
2. To define the major sites of atherosclerotic disease and compare the different protocol requirements.
3. To learn the fundamental post-processing steps for accurate quantification of stenosis.
4. To compare the value of contrast-enhanced and non-contrast-enhanced MRA to DSA and CTA.

**A-248** 16:30

**B. Non-atherosclerotic arterial disease**

T. Leiner; Maastricht/NL

*Learning Objectives:*

1. To become familiar with the major differential diagnoses of non-atherosclerotic disease including vasculitis, congenital disease and dysplastic changes.
2. To define the role of contrast-enhanced and non-contrast-enhanced MRA for detection and differentiation in comparison with DSA and ultrasound.
3. To learn about the additive value of related MRI techniques for improved staging and characterisation of these diseases.

**A-249** 17:00

**C. Venous disease**

M.A. Aschauer; Graz/AT

*Learning Objectives:*

1. To learn about different anomalies of the venous system and their implications for disease.
2. To understand the value of MRA for imaging of venous thrombosis and pulmonary embolism.
3. To become familiar with new intravascular contrast agents for imaging of the venous system.
4. To describe the role of MRA for imaging of dialysis grafts in comparison with DSA.

SUNDAY

**16:00 - 17:30****Room B****Multidetector CT Made Easy****CC 1217****The abdomen: The realm of MDCT***Moderator: G. Marchal; Leuven/BE***A-250** 16:00**A. The liver: Is MDCT beating MRI?**R.C. Nelson; Durham, NC/US*Learning Objectives:*

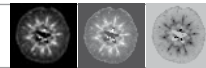
1. To understand role of liver imaging for lesion detection and characterisation in the oncologic population and in patients with cirrhosis.
2. To describe optimal techniques for liver MDCT and MRI.
3. To review typical imaging findings and results from literature regarding performance of MDCT and MRI.

**A-251** 16:30**B. The pancreas: MDCT stays the number one**M. Zins; Paris/FR*Learning Objectives:*

1. To detail MDCT technique in assessment of pancreatic disease.
2. To illustrate the role of 3D multiplanar reconstructions in assessment of the peripancreatic vessels in patients with pancreatic cancer.
3. To compare respective advantages of MDCT and MRI in assessment of pancreatic disease.

**A-252** 17:00**C. The kidneys and excretory system: Substituting IVU**F. Stacul; Trieste/IT*Learning Objectives:*

1. To become familiar with the role of MDCT of the urinary tract referring to the most frequent present day indications.
2. To learn about different CTU techniques and to understand their advantages and limitations.
3. To be fully aware of the radiation dose issue in CTU.



**State-of-the-Art Symposium**

**SA 12**

**Coronary CTA comes of age: Technical advances, decision modeling and cost effectiveness**

*Moderator: G.P. Krestin; Rotterdam/NL*

**A-253** 16:00

**Chairman's introduction**

G.P. Krestin; Rotterdam/NL

*Session Objectives:*

1. To present the most recent technical developments and future expectations in coronary CTA.
2. To discuss the most appropriate indications as well as limitations for performing coronary CTA from a clinical perspective.
3. To explain the economical impact of coronary CTA for the management of patients with (suspected) coronary artery disease.

**A-254** 16:03

**What's new in coronary CTA technology**

S. Leschka; Zurich/CH

*Learning Objectives:*

1. To present the most recent technical advances in coronary CTA.
2. To explain limitations of the method.
3. To give an overview of expected and desired future technical developments.

**A-255** 16:27

**Clinical selection of patients for coronary CTA**

S. Achenbach; Erlangen/DE

*Learning Objectives:*

1. To discuss the potential indications of coronary CTA in different patient populations.
2. To explain the position of coronary CTA among other diagnostic procedures in patients with (suspected) coronary artery disease.
3. To stress the limitations of coronary CTA in a clinical context.

**A-256** 16:51

**Economical impact of coronary CTA on patient management**

M.G.M. Hunink; Rotterdam/NL

*Learning Objectives:*

1. To explain different diagnostic strategies in patients with (suspected) coronary artery disease and their economic implications.
2. To discuss whether coronary CTA is cost-effective in the work-up for patients with (suspected) coronary artery disease.
3. To explain whether there is any clinical or economical necessity for further studies before implementing coronary CTA as a diagnostic tool in management of patients with coronary artery disease.

**Panel discussion:**

**Who should get a coronary CTA?** 17:15

---

**16:00 - 17:30****Room E1****Musculoskeletal****RC 1210****Spine***Moderator: F. Lecouvet; Brussels/BE***A-257** 16:00**A. Bone tumors**V.N. Cassar-Pullicino; *Oswestry/UK**Learning Objectives:*

1. To present the salient imaging hallmarks of spinal bone tumors.
2. To discuss the essential differential diagnosis from non-tumoral spinal conditions.
3. To outline an imaging approach to spinal bone tumors.

**A-258** 16:30**B. Infection**V. Jevtic; *Ljubljana/SI**Learning Objectives:*

1. To understand the pathogenesis of pyogenic and tuberculous spinal infection.
2. To review radiological findings in vertebral infection.
3. To understand the importance of different imaging modalities in the management of spinal infection.

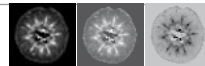
**A-259** 17:00**C. The post-operative spine**J.W.M. Van Goethem, L. van den Hauwe, P.M. Parizel; *Antwerp/BE**Learning Objectives:*

1. To review the different spinal surgical techniques and to learn their specific indications and complications.
2. To be able to differentiate (normal) epidural fibrosis from recurrent disc herniation.
3. To learn how to assess complications of spinal surgery with imaging.

---

**16:00 - 17:30****Room E2****Interactive Teaching Course: Useful Signs in Imaging****E<sup>3</sup> 1220****Signs in musculoskeletal imaging***Moderator: K. Bohndorf; Augsburg/DE***A-260** 16:00**A. Axial skeleton**A.H. Karantanas; *Iraklion/GR**Learning Objectives:*

1. To learn the most common signs in imaging of the axial skeleton.
2. To understand the mechanism that results in each sign presentation.
3. To become familiar with the particular imaging modality that demonstrates each sign.



**A-261** 16:45

**B. Extremities**

F.M.H.M. Vanhoenacker; *Antwerp/BE*

*Learning Objectives:*

1. To describe the signs, allowing the radiologist to make a specific diagnosis or reasonable differential diagnosis.
2. To illustrate these signs on different imaging methods (plain radiography, CT and MRI) and on diagrams.
3. To discuss the sensitivity and specificity of each sign.

---

**16:00 - 17:30**

**Room F1**

**Genitourinary**

**RC 1207**

**Imaging of the adnexal masses**

*Moderator: M. Basak; Istanbul/TR*

**A-262** 16:00

**A. What to do with an adnexal mass: Sonography**

M. Weston; *Leeds/UK*

*Learning Objectives:*

1. To recognise the characteristic ultrasound features of benign adnexal masses.
2. To appreciate ultrasound features that increase the likelihood of malignancy.
3. To learn what to do next, having found an adnexal lesion.
4. To become familiar with ultrasound guided techniques in biopsy, and when to offer them.

**A-263** 16:30

**B. How to characterise an indeterminate adnexal mass with MRI**

R. Forstner; *Salzburg/AT*

*Learning Objectives:*

1. To understand the role of MRI in the diagnosis and management of adnexal masses.
2. To learn imaging features of adnexal masses with emphasis on tissue characteristics.
3. To become familiar with differentiation of benign from malignant adnexal lesions on MRI.

**A-264** 17:00

**C. CT staging for sonographically malignant lesions**

C.S. Balleguier<sup>1</sup>, S. Taieb<sup>2</sup>, C. Lhomme<sup>1</sup>, P. Morice<sup>1</sup>; <sup>1</sup>*Villejuif/FR*, <sup>2</sup>*Lille/FR*

*Learning Objectives:*

1. To know the prognostic factors in ovarian cancer, FIGO and TNM classifications.
2. To understand the diagnostic and therapeutic strategies for malignant ovarian lesions.
3. To define the CT protocol for ovarian cancer staging.
4. To be familiar with the CT imaging criteria for non resectable tumors.
5. To know the role of CT to guide peritoneal sampling in case of peritoneal carcinomatosis.

**16:00 - 17:30****Room F2****Special Focus Session****SF 12****Whole body MR imaging: Valuable screening or life style choice for the worried rich?***Moderator: A.K. Dixon; Cambridge/UK***A-265** 16:00**Chairman's introduction***A.K. Dixon; Cambridge/UK**Session Objectives:*

1. To understand the controversy.
2. To appreciate differences between various health-care systems.

**A-266** 16:03**Methods and results***S.C. Ladd; Essen/DE**Learning Objectives:*

1. To understand different methods for MR screening.
2. To appreciate trade-offs between different approaches.
3. To gain knowledge of optimal results.

**A-267** 16:27**Cost effectiveness***S.J. Eustace; Dublin/IE**Learning Objectives:*

1. To become familiar with costs in comparison with other imaging techniques.
2. To appreciate the potential long term benefits.
3. To understand secondary costs and risks.

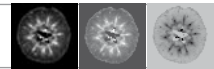
**A-268** 16:51**Ethical implications***S. Reiter-Theil; Basle/CH**Learning Objectives:*

1. To become aware of the concept of rationing MR resources.
2. To understand consent for MR screening.
3. To appreciate the patient's role for consent and research for MR screening.

**Panel discussion:****Would members of this audience buy a whole body MR scan on their 50th birthday?**

17:15





16:00 - 17:30

Room G/H

Neuro

RC 1211

## Imaging of vascular brain disease

Moderator: R. Gasparotti; Brescia/IT

**A-269** 16:00

### A. Spontaneous intracerebral haemorrhage

P.M. Parize; Antwerp/BE

*Learning Objectives:*

1. To learn about the imaging findings of intracerebral haemorrhage on CT and MR.
2. To comment on the possibility of determining the date of intracerebral haemorrhage with CT and MR.
3. To learn about the aetiological classification of haemorrhagic stroke.
4. To learn about the role of different imaging techniques in establishing the etiological subtype of haemorrhagic stroke.

**A-270** 16:30

### B. Chronic vascular diseases

M.A. van Buchem; Leiden/NL

*Learning Objectives:*

1. To learn the clinical presentation of chronic cerebral vascular disease.
2. To understand the advantages and drawbacks of the various radiological techniques for imaging the brain parenchyma and the intracranial and neck vessels.
3. To be able to establish a cost-effective diagnostic strategy for patients with suspected vascular brain disease.
4. To learn the differential diagnosis of chronic cerebral vascular diseases.

**A-271** 17:00

### C. Cerebral venous thrombosis

L. Biscoito; Lisbon/PT

*Learning Objectives:*

1. To discuss the incidence, causes and clinical presentation of cerebral venous thrombosis.
2. To learn the imaging protocol in the diagnosis of cerebral venous thrombosis.
3. To discuss the specific imaging findings of cerebral venous thrombosis on CT and MR.

SUNDAY

**16:00 - 17:30**
**Room I**
**Physics in Radiology**
**RC 1213**
**Physics and technology of multi-modality imaging systems**
*Moderators: A. Bockisch; Essen/DE, M. Gambaccini; Ferrara/IT*
**A-272** 16:00

**A. CT-PET**

 A.A. Lammertsma; Amsterdam/NL

*Learning Objectives:*

1. To provide an overview of the principles of PET and the potential benefits and limitations of a combined PET-CT system.
2. To understand the issues related to the use of CT for attenuation correction of PET images.
3. To learn about (the need for) quantification of PET data.
4. To provide an overview of potential clinical applications of a PET-CT system.

**A-273** 16:30

**B. CT-SPECT**

 T. Kuwert; Erlangen/DE

*Learning Objectives:*

1. To understand the principle of CT-based attenuation correction.
2. To understand the principle of SPECT-guided CT.
3. To provide examples of clinical indications for SPECT/CT.

**A-274** 17:00

**C. MR-PET**

 R. Krieg<sup>1</sup>, R. Ladebeck<sup>1</sup>, N. Rietsch<sup>1</sup>, M. Schmand<sup>2</sup>; <sup>1</sup>Erlangen/DE, <sup>2</sup>Knoxville, TN/US

*Learning Objectives:*

1. To appreciate the advantages of a combined MR-PET system capable of simultaneous acquisition.
2. To understand the technical approach and challenges of an isocentric system.

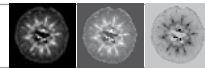
**16:00 - 17:30**
**Room K**
**Pediatric**
**RC 1212**
**Gastrointestinal tract**
*Moderator: M. Hiorns; London/UK*
**A-275** 16:00

**A. Gastrointestinal emergencies**

 E. Beek; Utrecht/NL

*Learning Objectives:*

1. To present an overview of emergencies of the GI tract in children.
2. To discuss clinical features of the most common emergencies of the GI tract at different ages.
3. To discuss the most appropriate imaging techniques for these emergencies.



**A-276** 16:30

**B. Inflammatory bowel disease**

J.-P. Pracros, E. Mekhloufi; Lyon/FR

*Learning Objectives:*

1. To provide a general overview of the common inflammatory bowel diseases in children.
2. To discuss the practical uses of the different imaging modalities and the advantages and disadvantages of ultrasound, CT and MRI.
3. To propose a practical approach for diagnosis and follow-up of children with inflammatory bowel disease using imaging techniques and non-imaging tools.

**A-277** 17:00

**C. Biliary tract**

M. Rasero; Madrid/ES

*Learning Objectives:*

1. To review the imaging techniques used to study jaundice in children.
2. To discuss the most common biliary tract disorders in the pediatric age group.
3. To review biliary complications after liver transplantation.

---

**16:00 - 17:30**

**Room L/M**

**Radiographers**

**RC 1214**

**Professional profile developments: The extended role of the radiographer**

*Moderators: G.A. Marshall; Lancaster/UK, C. Roche; Galway/IE*

**A-278** 16:00

**A. Changing roles in the 21st century: Reporting, research, management, consultants**

A. Paterson; London/UK

*Learning Objectives:*

1. To learn about the changing roles of radiographers in the UK in general terms.
2. To understand the factors that have been, and remain, important in supporting significant role change.
3. To share knowledge about three important areas of changing practice in the UK; specifically, radiographer reporting; consultant radiographer roles and contributions, and research.
4. To establish the importance of professional leadership and management in enabling radiographers roles to continue to develop, and new roles to be implemented on a wide-spread basis.

**A-279** 16:30

**B. The Norwegian Radiography Research Group**

B. Strøm<sup>1</sup>, E. Eikefjord<sup>1</sup>, B. Ween<sup>2</sup>, C. von Krogh Lid<sup>2</sup>, H. Solstad<sup>3</sup>; <sup>1</sup>Bergen/NO, <sup>2</sup>Oslo/NO, <sup>3</sup>Tromsø/NO

*Learning Objectives:*

1. To learn about The Norwegian Radiography Research Group.
2. To learn about the research activity among Norwegian radiographers.
3. To understand the potential to radiography research.
4. To become familiar with the term "science of radiography".
5. To appreciate radiography as a unique discipline with its own knowledge base.

**A-280** 17:00**C. Radiology informatics: A new research area**N. Lundberg; *Stockholm/SE**Learning Objectives:*

1. To become familiar with the radiology informatics research group from Karolinska Institute, Sweden.
2. To learn about the use of information and communication technologies.
3. To concentrate on the effects of ICT use with focus on changes in work practice, production and workflow.

**16:00 - 17:30****Room N/O****Molecular Imaging and Contrast Media****RC 1206****Angiogenesis imaging in clinical practice today***Moderator: W.A. Kaiser; Jena/DE***A-281** 16:00**A. Principles**K.A. Miles; *Brighton/UK**Learning Objectives:*

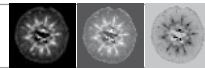
1. To summarise the biology of angiogenesis and its importance in tumor growth/metastasis.
2. To illustrate the relationship between angiogenesis and contrast enhancement.
3. To discuss the need for quantification.
4. To compare angiogenesis imaging with contrast agents to other methods for imaging angiogenesis and other metabolic/functional methods for imaging tumors.

**A-282** 16:30**B. How to do it**A.R. Padhani; *Northwood/UK**Learning Objectives:*

1. To show that empirical methods can be used successfully in clinical practice.
2. To discuss what software to use to quantify and display angiogenesis information.
3. To discuss factors that impedes quantitative assessments.
4. To learn how to assess therapy by parametric imaging methods.

**A-283** 17:00**C. Information you can get**J.O. Barentsz; *Nijmegen/NL**Learning Objectives:*

1. To illustrate three levels of clinical dynamic imaging: From simple to advanced.
2. To give clinical examples of the application of angiogenesis imaging.
3. To show some connections to MRS of the prostate and breast.



16:00 - 17:30

Room R1

**Chest**

**RC 1204**

**Bronchogenic carcinoma: Screening and staging**

*Moderator: M.-L. Storto; Chieti/IT*

**A-284** 16:00

**A. Screening: Guidelines for follow-up**

S. Diederich; Düsseldorf/DE

*Learning Objectives:*

1. To understand the epidemiology of pulmonary nodules in asymptomatic individuals smokers and non-smokers and patients with known malignancy.
2. To understand advantages and disadvantages the different diagnostic procedures for assessment of pulmonary nodules.
3. To learn about recommendations for the management of pulmonary nodules in different clinical settings.

**A-285** 16:30

**B. Staging with CT and MRI**

J. Frija; Paris/FR

*Learning Objectives:*

1. To review the method of CT staging.
2. To explain why staging has important therapeutic consequences.
3. To emphasise the important prognostic factors on survival which can be seen on a chest CT for a lung cancer.

**A-286** 17:00

**C. Staging with PET/CT**

W. De Wever; Leuven/BE

*Learning Objectives:*

1. To become familiar with some technical aspects of a new imaging modality: Integrated PET/CT.
2. To learn about advantages and limitations of integrated PET/CT.
3. To understand why integrated PET/CT is more sensitive and specific than CT alone, PET alone and visual correlation of CT and PET in the staging of bronchogenic carcinoma.

16:00 - 17:30

Room R2

**Breast: From Basics to Advanced Imaging**

**CC 1218**

**Characterisation of breast lesions by US and MRI**

*Moderator: E. Azavedo; Stockholm/SE*

**A-287** 16:00

**A. Breast lesions detected by US**

M. Locatelli; Gorizia/IT

*Learning Objectives:*

1. To know normal anatomical structures and artefacts.
2. To learn how to characterise abnormal findings detected by US.
3. To describe BI-RADS™ lexicon and assessment categories (US).

SUNDAY

**A-288** 16:45

**B. Breast lesions detected by MRI**

K. Kinke; *Chêne-Bougeries/CH*

*Learning Objectives:*

1. To know normal anatomical structures and artefacts.
2. To learn how to characterise abnormal findings detected by MRI.
3. To describe BI-RADS™ lexicon and assessment categories (MRI).

---

**16:00 - 17:30**

**Room R3**

**Professional Challenges Session**

**PC 12**

**Teleradiology: Film reading at the sea side?**

*Moderator: L. Donoso; Sabadell/ES*

**A-289** 16:00

**Chairman's introduction**

L. Donoso; *Sabadell/ES*

*Session Objectives:*

1. To become familiar with best practice in teleradiology.
2. To learn about the different practical applications.
3. To appreciate the influence of teleradiology on future trends in organising diagnostic imaging services.
4. To emphasise the benefits, potentials and risks of teleradiology.

**A-290** 16:05

**Quality standards**

J. Reponen; *Raahe/FI*

*Learning Objectives:*

1. To be familiar with the technical requirements for successful teleradiology.
2. To understand the main obstacles in maintaining adequate and seamless service.
3. To learn how to plan and specify a teleradiology business case to follow the same quality standards as existing hospital imaging services.
4. To discuss the practical experiences with teleradiology providers as a customer.

**A-291** 16:23

**Opportunities and risks**

J. Størmer; *Tromsø/NO*

*Learning Objectives:*

1. To get practical feedback from 15 years of large volume teleradiology experience.
2. To learn about legal challenges.
3. To evaluate the impact on rural medical services of different teleradiological models.
4. To learn that reality is sometimes different than what you plan for.

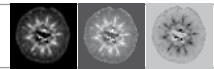
**A-292** 16:41

**Provider's point of view**

F.H. Barneveld Binkhuysen; *Mechelen/BE*

*Learning Objectives:*

1. To get an insight how a commercial teleradiology environment works.
2. To get an idea of the types of services that are offered in a commercial teleradiology enterprise.
3. To get an overview of the quality issues that are involved and need to be managed.



**A-293** 16:59

**Professional issues and international guidelines**

I.W. McCall; Dswestry/UK

*Learning Objectives:*

1. To describe the guidelines for teleradiology in different countries.
2. To understand the international variations in the use of teleradiology.
3. To discuss the implications of radiological services of international radiology.

**Panel discussion:**

**Is teleradiology good for our health?** 17:17

**08:30 - 10:00****Room A****MRI****CC 1316****Abdomen: Is MRI the ultimate tool?***Moderator: G. Brown; Sutton, Surrey/UK***A-294** 08:30**A. Liver**L. Marti-Bonmati; *Valencia/ES**Learning Objectives:*

1. To define the major differential diagnoses for benign and malignant liver lesions.
2. To learn about new sequence developments for increased robustness, spatial resolution and speed.
3. To understand the value of different extracellular, hepatobiliary and RES-specific contrast agents for lesion detection and characterisation.
4. To become familiar with the criteria for preoperative staging and pre-interventional therapy planning.

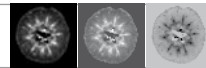
**A-295** 09:00**B. Pancreas**C. Matos; *Brussels/BE**Learning Objectives:*

1. To describe the technical developments in MRI and MRCP and to explain strategies to obtain morphological and functional information.
2. To explain the role of MRI in the evaluation of pancreatic carcinomas and cystic pancreatic neoplasms, including detection, differential diagnosis and staging.
3. To discuss the advantages and limitations of MRI versus CT and PET-CT for tumor and lymph node staging.

**A-296** 09:30**C. Small and large bowel**K.A. Herrmann; *Munich/DE**Learning Objectives:*

1. To become familiar with an optimised protocol for imaging of the small and large bowel.
2. To define the role of various dynamic 2D and 3D sequences and related post-processing.
3. To understand the value of these techniques for detection of inflammatory bowel disease and resulting complications.
4. To describe the accuracy for detection of colon polyps and staging of colon cancer.





08:30 - 10:00

Room B

**Multidetector CT Made Easy**

**CC 1317**

**CT of the brain, head and neck: Is there anything new?**

Moderator: E. T. Tali; Ankara/TR

**A-297** 08:30

**A. Acute and chronic ischemia: Combining CT with CTP**

P.M. Parize; Antwerp/BE

*Learning Objectives:*

1. To understand the impact of multidetector CT on imaging strategy in acute and chronic cerebral ischemia.
2. To discuss the optimal techniques for MDCT of the brain, with emphasis on CT perfusion and CT angiography.
3. To present typical MDCT imaging findings in acute and chronic ischemia.
4. To critically evaluate advantages and disadvantages of MDCT as compared to other imaging modalities.

**A-298** 09:00

**B. Aneurysms and AVMs: When is CT enough?**

M.M. Thurnher; Vienna/AT

*Learning Objectives:*

1. To learn about the current role and diagnostic accuracy of CT and CT angiography (CTA) in evaluating intracranial aneurysms and AVMs.
2. To discuss possible fields in which CTA might replace invasive DSA and even compete with MRI techniques in detecting aneurysms and AVMs.
3. To describe imaging protocol and strategy of using CT and CTA as the primary imaging method in aneurysmal subarachnoid hemorrhage.

**A-299** 09:30

**C. Head and neck lesions: A new role for CT?**

M. Annertz; Lund/SE

*Learning Objectives:*

1. To understand the role of MDCT-imaging for lesion detection and characterisation in the oncologic population and in patients with other diseases.
2. To describe guidelines for rational radiologic whole body investigation of patients with head and neck cancer, using MDCT, MRI, ultrasound and PET-CT.
3. To describe optimal techniques for head and neck MDCT.
4. To review typical imaging findings.

MONDAY

**08:30 - 10:00****Room C****Special Focus Session****SF 13****The radiologist in image-guided surgery: Just a tour guide?***Moderator: C. Bartolozzi; Pisa/IT***A-300** 08:30**Chairman's introduction**C. Bartolozzi; *Pisa/IT**Session Objectives:*

1. To discuss the integration of advanced imaging techniques for the assessment of intra-operative anatomy.
2. To emphasise the need for a close collaboration between radiologist and surgeon in order to prevent turf battle.
3. To present the advantages of the novel approach for planning and simulating the interventional procedures.

**A-301** 08:34**Intraoperative navigation using radiological data and software support**N. Navab; *Munich/DE**Learning Objectives:*

1. To learn about real-time fusion of pre-operative, anatomical and functional data with intra-operative, anatomical and functional data.
2. To emphasise on the integration of navigation and advanced visualisation techniques into the surgical workflow.
3. To discuss different techniques and solutions as well as clinical studies with the aim to demonstrate the efficiency of the proposed solutions.

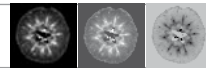
**A-302** 08:56**Image-guided therapy (IGT): Who carries it out?**H. Hricak; *New York, NY/US**Learning Objectives:*

1. To understand that serving mutual interests prevents turf battles.
2. To understand that collaboration in image-guided intervention will produce gains for everyone (academic, patient volume).
3. To discuss the need for a credentialing system and a curriculum that reflects institutional policy.
4. To consider models for an appropriate governing body.
5. To understand the importance of developing joint educational and research programs.

**A-303** 09:18**Radiology and surgery: A new integrated training environment**D. Caramella; *Pisa/IT**Learning Objectives:*

1. To present the opportunities of novel approaches in 3D interactive visualisation and manipulation of a "virtual patient".
2. To appreciate the advantages of an integrated electronic environment for planning and simulating interventional procedures and to forecast the response to treatment.
3. To learn about the changes introduced by these technologies in the training of both radiologists and surgeons.

**Panel discussion:****Imaging and interventions: The need for a new kind of radiologist** 09:40



08:30 - 10:00

Room E1

## Musculoskeletal

### RC 1310

#### Shoulder

Moderator: E. Llopis; Valencia/ES

**A-304** 08:30

#### A. Impingement

J. Kramer; Linz/AT

##### Learning Objectives:

1. To become familiar with MR imaging of the normal rotator cuff.
2. To understand aetiology and MR findings of rotator cuff lesions caused by or leading to subacromial impingement.
3. To recognise tendinosis vs partial and full thickness rotator cuff tears.
4. To recognise internal impingement (posterosuperior glenoid impingement).

**A-305** 09:00

#### B. Instability

P. Hughes; Plymouth/UK

##### Learning Objectives:

1. To understand anatomy relevant to instability.
2. To recognise common labral and ligamentous normal variants.
3. To identify lesions associated with dysfunction of the glenohumeral ligaments.
4. To select the appropriate imaging technique, tailored to surgical requirements.
5. To recognise the importance and signs of multidirectional instability.

**A-306** 09:30

#### C. Superior labrum and biceps tendon lesions

K. Wörtler; Munich/DE

##### Learning Objectives:

1. To become familiar with the anatomy of the superior labrum and biceps tendon.
2. To understand the pathomechanisms, classification, and therapeutic consequences of superior labral and biceps tendon lesions.
3. To recognise imaging findings of superior labral injuries and associated pathology.
4. To discuss advantages and disadvantages of different imaging techniques.

MONDAY

**08:30 - 10:00**
**Room E2**
**Interactive Teaching Session**
**E<sup>3</sup> 1320**
**The imaging management of lung cancer**
*Moderator: G.H. Mostbeck; Vienna/AT*
**A-307** 08:30

**The imaging management of lung cancer**

 J. Cáceres<sup>1</sup>, J. Vilar<sup>2</sup>; <sup>1</sup>Barcelona/ES, <sup>2</sup>Valencia/ES

*Learning Objectives:*

1. To optimise imaging procedures in diagnosing lung cancer.
2. To learn basic facts in staging lung cancer.
3. To detect complications and/or recurrence in treated lung cancer.

**08:30 - 10:00**
**Room F1**
**Head and Neck**
**RC 1308**
**Imaging the thyroid and parathyroid**
*Moderator: M.G. Mack; Frankfurt a. Main/DE*
**A-308** 08:30

**A. Clinical perspective and nuclear medicine**

A. Kurtaran; Vienna/AT

*Learning Objectives:*

1. To understand the clinical questions raised in patients with suspected thyroid or parathyroid disease.
2. To understand the possibilities, methodology and limitations of nuclear medicine in the work-up of thyroid and parathyroid diseases.

**A-309** 09:00

**B. Ultrasound and US-guided biopsy**

N. Gritzmann; Salzburg/AT

*Learning Objectives:*

1. To learn the normal sonographic anatomy of thyroid/parathyroid gland and sonographic technique.
2. To become familiar with diffuse pathologies and nodular disease of the thyroid.
3. To know thyroid carcinoma and parathyroid adenoma.
4. To learn about US guided interventions.

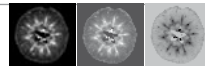
**A-310** 09:30

**C. CT and MRI**

J.E. Kabala; Bristol/UK

*Learning Objectives:*

1. To understand the role and limitations of CT and MRI in evaluating thyroid and parathyroid disease.
2. To familiarise with imaging features of benign thyroid pathology (multinodular goitre, thyroglossal cysts, etc).
3. To learn about MRI and CT features of thyroid and parathyroid tumors.
4. To understand the potential added value of MRI and CT in relation to ultrasound and/or cytology.



08:30 - 10:00

Room F2

**Breast**

**RC 1302**

**Changing approaches to breast diseases?**

*Moderator: P. Viehweg; Dresden/DE*

**A-311** 08:30

**A. Screening in high risk groups**

F.J. Gilbert; Aberdeen/UK

*Learning Objectives:*

1. To underline the definition of high risk groups.
2. To analyse what is being done to reach early diagnosis.
3. To illustrate guidelines adopted in UK.

**A-312** 09:00

**B. Interventional treatment**

M. Torres-Tabanera<sup>1</sup>, L. Apesteguía-Ciriza<sup>2</sup>; <sup>1</sup>Madrid/ES, <sup>2</sup>Pamplona/ES

*Learning Objectives:*

1. To illustrate the techniques available for lesion removal (including radiofrequency ablation).
2. To understand what technique is indicated for what type of lesion.
3. To summarise preliminary results of recent studies.

**A-313** 09:30

**C. Follow-up and surveillance**

S. Barter; Cambridge/UK

*Learning Objectives:*

1. To illustrate the evidence for mammographic follow up intervals.
2. To understand how frequently breast cancer patients should be followed up.
3. To illustrate the role of different imaging modalities for patient follow up.

08:30 - 10:00

Room 6/H

**Neuro**

**RC 1311**

**Pediatric neuroradiology**

*Moderator: Z. Merhemcic; Sarajevo/BA*

**A-314** 08:30

**A. Migration disorders**

P. Demaerel; Leuven/BE

*Learning Objectives:*

1. To learn the normal embryological course of neuronal migration and organisation of the cerebral cortex.
2. To discuss the different types of migration disorders and their typical imaging features.
3. To discuss the neuroradiological differential diagnoses.

MONDAY

**A-315** 09:00**B. CNS infections**P.C. Maly Sundgren; Ann Arbor, MI/US*Learning Objectives:*

1. To learn the typical clinical and aetiological features of CNS infections of childhood.
2. To discuss the imaging findings of CNS infections in childhood.
3. To discuss the differential diagnoses.

**A-316** 09:30**C. Congenital brain tumors**A. Rossi; Genoa/IT*Learning Objectives:*

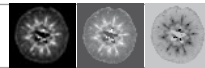
1. To learn about the concept, genetics and clinical features of congenital brain tumors.
2. To recognise the imaging patterns of the different types of congenital brain tumors.
3. To learn about the potential of new MRI techniques in the evaluation of congenital brain tumors.

**08:30 - 10:00****Room I****Physics in Radiology****RC 1313****Quality control and dose reduction in digital radiology***Moderators: A. Lisbona; Saint-Herblain/FR, O. Ratib; Geneva/CH***A-317** 08:30**A. Principles of flat panel detectors**N. Marshall; London/UK*Learning Objectives:*

1. To understand the basics of X-ray detection: What happens in the scintillators, what is the captured "signal" and which processes of signal deterioration exist (noise, flare etc.).
2. To learn the principles of available technological solutions (photostimulable plates, electro-direct flat panel detectors and opto-direct flat panel detectors).
3. To understand the differences in physical imaging performance. Practical considerations with respect to application fields will also be discussed.

**A-318** 09:00**B. Managing patient dose**E. Vañó; Madrid/ES*Learning Objectives:*

1. To realise that the International Commission on Radiological Protection (ICRP) has published recommendations on patient dose management in digital radiology.
2. To introduce the key points of the ICRP document especially those related with aspects influencing patient dose and image quality.
3. To highlight the role of the radiology industry to help in the protection of the patient for the new digital technologies.



**A-319** 09:30

**C. Quality assurance**

H.-P. Busch; Trier/DE

*Learning Objectives:*

1. To discuss European guidelines for quality assurance.
2. To explain new aspects for quality assurance, especially in digital radiography.
3. To describe experience and test phantoms for routine use (Which parameters are controlled in detail? What are objective quality criteria in the digital images?).
4. To give examples for optimisation of image quality.
5. To fit the concept of quality assurance into the new strategy of dose and quality management.

---

**08:30 - 10:00**

**Room K**

**Pediatric**

**RC 1312**

**Chest imaging**

*Moderator: P. Tomà; Genoa/IT*

**A-320** 08:30

**A. Neonatal chest diseases**

M.P. García-Peña; Barcelona/ES

*Learning Objectives:*

1. To analyse the normal findings on a neonatal chest X-ray.
2. To recognise acute conditions causing neonatal respiratory distress.
3. To recognise normal and abnormal evolution.

**A-321** 09:00

**B. Acute chest diseases**

J. Fonseca-Santos; Lisbon/PT

*Learning Objectives:*

1. To analyse the most frequent causes of acute chest diseases: Infection and trauma.
2. To review conditions causing respiratory distress, underlying congenital anomalies of respiratory tract.
3. To discuss non-respiratory causes of chest emergency.

**A-322** 09:30

**C. Foreign body aspiration and ingestion**

K. Darge; Würzburg/DE

*Learning Objectives:*

1. To describe the different types and patterns of foreign body aspiration and ingestion.
2. To discuss the relevant imaging modalities and ascertain their relative diagnostic value.
3. To highlight awareness of the various pitfalls involved in imaging foreign body aspiration and ingestion.

---

**08:30 - 10:00****Room L/M****Radiographers****RC 1314****Trauma**

*Moderators: A.M. Davies; Birmingham/UK, J. Nicklin; Poole/UK*

**A-323** 08:30**A. Introducing digital radiography into the trauma unit**

H. Harries-Jones; Poole/UK

*Learning Objectives:*

1. To become familiar with uses of DR technology in a trauma unit.
2. To explore the advantages and disadvantages and/or difficulties encountered in the introduction of DR systems in an acute hospital setting.
3. To appreciate different ways of working and affect on workflow with this system.

**A-324** 09:15**B. Emergency radiographer: An emerging role**

B. Snaith; Wakefield/UK

*Learning Objectives:*

1. To understand the current and future role of the radiographer in emergency care.
2. To learn about current international practice.
3. To appreciate the benefits and risks associated with evolving roles.
4. To become familiar with different levels of practice from assistant through to consultant.
5. To consolidate knowledge of emergency care and extended roles.

---

**08:30 - 10:00****Room N/O****Professional Challenges Session****PC 13****Capturing the market: How quality helps**

*Moderator: C.J. Herold; Vienna/AT*

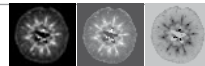
**A-325** 08:30**Chairman's introduction**

C.J. Herold; Vienna/AT

*Learning Objectives:*

1. To understand market forces important for building a successful radiology practice.
2. To learn the role of quality as a principle of good governance, and as driving factor in marketing.
3. To obtain practical tips in setting up a coherent and market oriented quality management program.





**A-326** 08:34

**A look at the market: Which factors make a radiology practice thrive?**

J.H. Thrall; Boston, MA/US

*Learning Objectives:*

1. To learn the elements involved in marketing a radiology practice.
2. To learn what stakeholders expect from a radiology practice.
3. To learn how to develop a market outreach program for a radiology practice.

**A-327** 08:56

**Quality as a success factor**

J.E. Husband; London/UK

*Learning Objectives:*

1. To understand the changing role of imaging in patient management.
2. To become familiar with core principles of good governance in providing a high quality service.
3. To become familiar with the Royal College of Radiologists/Society and College of Radiographers Radiology Accreditation Programme (RAP).

**A-328** 09:18

**Setting up a quality management, risk management and patient safety programme: Practical tips**

M. Breitenseher; Horn/AT

*Learning Objectives:*

1. To start top down with objective information about quality management (QM) and convince the pioneers.
2. To set up with electing QM manager and building a QM team, using self organisation as a bottom up strategy.
3. To calculate that running QM could be a law of nature as thinking in complexity.

**Panel discussion (with devil's advocate)** 09:40

---

**08:30 - 10:00**

**Room R1**

**Cardiac**

**RC 1303**

**Imaging of myocardial infarction**

*Moderator: M. Oudkerk; Groningen/NL*

**A-329** 08:30

**A. MR imaging of acute myocardial infarction**

J.-F. Paul; Le Plessis Robinson/FR

*Learning Objectives:*

1. To understand pathological changes in infarcted myocardium.
2. To differentiate acute from chronic myocardial infarction using MRI.
3. To understand prognostic significance of microvascular obstruction after myocardial infarction as defined by MRI.

**A-330** 09:00

**B. Prediction of myocardial viability with MR**

M.R. Rees; Gwynedd/UK

*Learning Objectives:*

1. To understand clinical importance of viability assessment.
2. To understand the principles and practice for the use of MR in the assessment of myocardial viability.
3. To learn how to use integrated information on viability, scar tissue and left ventricular remodelling.

**A-331** 09:30**C. MDCT for the detection and quantification of myocardial infarction**I. Mastorakou; Athens/GR*Learning Objectives:*

1. To understand the latest technical developments in CT imaging of the heart.
2. To understand the complementary role of CT imaging the coronary arteries and the myocardium.
3. To understand the role of CT in the diagnosis of myocardial infarction and perfusion defects.

**08:30 - 10:00****Room R2****Abdominal and Gastrointestinal****RC 1301****CT colonography: How to use it**

Moderator: S.A. Taylor; London/UK

**A-332** 08:30**A. How to do it**H. Fenlon; Dublin/IE*Learning Objectives:*

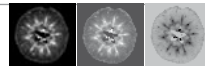
1. To review current bowel preparation techniques for CT colonography.
2. To understand principles of data acquisition at CT colonography.
3. To describe options for 2D and 3D image interpretation of CT colonography datasets.
4. To propose a policy of "good practice" for CT colonography implementation (i.e. standardised reporting, quality assurance, training and accreditation, etc.).

**A-333** 09:00**B. How to read it**T. Mang; Vienna/AT*Learning Objectives:*

1. To discuss the different reconstruction modes.
2. To describe typical findings.
3. To learn how to recognise artifacts and to avoid pitfalls.

**A-334** 09:30**C. Clinical value**P. Lefere; Roeselare/BE*Learning Objectives:*

1. To define the indications for CT colonography in the symptomatic and asymptomatic patient.
2. To review the performance of CT colonography in clinical studies.
3. To discuss significance of learning curve, extracolonic findings, adverse events, cost-effectiveness, relationship with the gastroenterologists.



08:30 - 10:00

Room R3

**Interventional Radiology**

**RC 1309**

**Interventions in non-malignant liver diseases**

*Moderator: K.A. Hausegger; Klagenfurt/AT*

**A-335** 08:30

**A. Benign biliary disease**

M. Glynos; Athens/GR

*Learning Objectives:*

1. To discuss the indications of percutaneous biliary interventions.
2. To learn about the technical developments of percutaneous biliary interventions.
3. To review the complications of percutaneous biliary interventions and their treatment.

**A-336** 09:00

**B. Management of complications post liver transplantations**

J.B. Karani; London/UK

*Learning Objectives:*

1. To review the post liver transplant complications and their imaging.
2. To learn about the indications and limitations for percutaneous treatment of liver transplant complications.
3. To discuss the techniques used for percutaneous treatment of liver transplant complications.

**A-337** 09:30

**C. Interventions in the portal system**

A. Krajina; Hradec Králové/CZ

*Learning Objectives:*

1. To review the endovascular methods for the treatment of portal hypertension.
2. To review other percutaneous procedures in the portal venous system.
3. To learn about the indications, techniques and results of portal vein embolisation to increase hepatic remnant volume prior to hepatectomy.

10:30 - 12:00

Room E2

**Interactive Teaching Session**

**E3 1420**

**The imaging management of stroke**

*Moderator: P.M. Parizel; Antwerp/BE*

**A-338** 10:30

**The imaging management of stroke**

A. Rovira-Cañellas<sup>1</sup>, T. Krings<sup>2</sup>; <sup>1</sup>Barcelona/ES, <sup>2</sup>Aachen/DE

*Learning Objectives:*

1. To learn about the role of imaging for establishing the etiological subtype of ischemic and hemorrhagic stroke.
2. To learn about the different imaging strategies for selecting acute stroke patients for thrombolytic therapy.
3. To be familiar with the indications, techniques and complications of endovascular procedures in ischemic and hemorrhagic strokes.

MONDAY

**12:15 - 12:45**
**Room B**
**Plenary Session**
**HL 3**
**Peter E. Peters - Honorary Lecture**
*Presiding: M.F. Reiser; Munich/DE*
**A-339** 12:15

**New paradigms in breast imaging**

C.K. Kuhl; Bonn/DE

*Learning Objectives:*

1. To comprehend current concepts of breast cancer screening and diagnosis.
2. To understand areas of debate regarding the use of non-mammographic imaging techniques.
3. To become familiar with the current level of evidence regarding the use of breast MRI for diagnosis and screening.

**14:00 - 15:30**
**Room A**
**"ESR meets India"**
**EM 4**
**Tuberculosis**
*Presiding:*

A. Adam; London/UK

N. Kulasekaran; Chennai/IN

M.F. Reiser; Munich/DE

**A-340** 14:00

**Introduction**

 S.S. Doda<sup>1</sup>, H. Satishchandra<sup>2</sup>; <sup>1</sup>New Delhi/IN, <sup>2</sup>Bangalore/IN

*Learning Objectives:*

1. To consolidate the knowledge of imaging features of tuberculosis in various parts of the body.
2. To understand the role of different imaging modalities in the diagnosis of tuberculosis in respective areas of the body.
3. To become familiar with unusual presentations and appearances of tuberculosis and to discuss the difficulties in differential diagnosis.

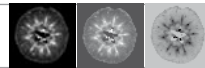
**A-341** 14:05

**Unusual appearances of intracranial tubercular infection**

D.P. Patkar; Mumbai/IN

*Learning Objectives:*

1. To become familiar with uncommon and sometimes difficult to diagnose appearances of intra-cranial tubercular infections on MR.
2. To learn about MR spectroscopic features in helping differentiation of giant tuberculoma from glioma, abscess, metastasis and meningioma.



**A-342** 14:23

**Spinal tuberculosis revisited**

R. Kapur; *New Delhi/IN*

*Learning Objectives:*

1. To become familiar with patterns of involvement of spinal and paravertebral structures in tuberculosis.
2. To understand the sequence of radiological changes during evolution and treatment of the disease.
3. To learn about limitations of imaging and mimics of spinal tuberculosis.

**A-343** 14:41

**Ultrasound features in peritoneal and intestinal tuberculosis**

S.S. Doda; *New Delhi/IN*

*Learning Objectives:*

1. To become familiar with ultrasound features of peritoneal and intestinal tuberculosis.
2. To understand the techniques to highlight the sonographic changes.

**A-344** 14:59

**Chest tuberculosis: Atypical radiological appearances**

P.R. Kundur; *Hyderabad/IN*

*Learning Objectives:*

1. To become familiar with atypical radiological manifestations of chest tuberculosis.
2. To understand the radiological changes in chest tuberculosis in diabetics.

**Panel discussion** 15:17

---

**14:00 - 15:30**

**Room B**

**Multidetector CT Made Easy**

**CC 1517**

**MDCT angiography: Do we need anything else?**

*Moderator: K.H. Tay; Singapore/SG*

**A-345** 14:00

**A. The pulmonary vessels**

M. Rémy-Jardin, J. Rémy; *Lille/FR*

*Learning Objectives:*

1. To review the image quality currently achievable for the evaluation of pulmonary vessels.
2. To describe the available options for significant dose reduction in MDCT angiography of the chest.
3. To illustrate the impacts of dual-source CT in imaging of the pulmonary circulation.

**A-346** 14:30

**B. The arterial highways**

G.D. Rubin; *Stanford, CA/US*

*Learning Objectives:*

1. To understand the role of CT angiography for imaging the major arteries of the body.
2. To learn important techniques for acquiring CT angiograms.
3. To learn the relative value of different types of CT scanners for performing specific arterial applications.

**A-347** 15:00

**C. Detours**

C. Catalano; *Rome/IT*

*Learning Objectives:*

1. To discuss acquisition and contrast administration protocols in CTA of run off and small calibre arteries.
2. To understand clinical applications of CTA in peripheral arteries diseases.
3. To become familiar with limitations and possible pitfalls in peripheral arteries CTA.

---

**14:00 - 15:30**

**Room C**

**State-of-the-Art Symposium**

**SA 15**

**Small bowel: Old problems, new tricks**

*Moderator: Y. Menu; Le Kremlin-Bicêtre/FR*

**A-348** 14:00

**Chairman's introduction**

Y. Menu; *Le Kremlin-Bicêtre/FR*

*Session Objective:*

1. To describe how modern imaging impacts the work-up of patients with suspected or known small bowel disease, and the complementary role of imaging with clinical, endoscopic and biological data.

**A-349** 14:05

**Computed tomography: The heavy worker**

G.A. Rollandi, E. Biscaldi; *Genoa/IT*

*Learning Objectives:*

1. To present the technique of computed tomography of the small bowel: Oral preparation (enteroclysis or not), intravenous contrast administration, technical settings, image post processing, interpretation method, logistics, radiation dose.
2. To understand the imaging patterns, and their correlation with pathology (wall thickening, contrast enhancement, peri-intestinal and mesenteric changes).
3. To learn how the analysis of imaging patterns allows differential diagnoses between tumor, inflammation and ischemia.
4. To detail the limitations of small bowel CT.

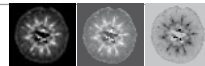
**A-350** 14:30

**Magnetic resonance: The ultimate?**

N. Gourtsoyannis; *Iraklion/GR*

*Learning Objectives:*

1. To present the technique of magnetic resonance of the small bowel: Oral preparation (enteroclysis or not), intravenous contrast administration, sequences, image post processing, interpretation method, logistics.
2. To understand the imaging patterns, and their correlation with pathology (wall thickening, contrast enhancement, peri-intestinal and mesenteric changes).
3. To learn how the analysis of imaging patterns may facilitate disease subtype classification.
4. To compare advantages and limitations of CT and MRI (spatial and contrast resolution, logistics, radiation, standardisation), and to determine which patients are candidates for CT and/or MRI.



**A-351** 14:55

**Videocapsule and ultrasound: A complementary approach**

J.-M. Bruel; *Montpellier/FR*

*Learning Objectives:*

1. To present the technique of videocapsule endoscopy of the small bowel and the future developments of endoscopy, including capsule improvement and double balloon endoscopy.
2. To identify the indications and contraindications, advantages and limits of videocapsule.
3. To detail the ideal technical conditions for ultrasonography of the small bowel, including high resolution, Doppler and contrast enhanced studies.
4. To learn the elementary ultrasound images in case of common diseases of the bowel.
5. To determine in which cases ultrasonography is indicated as a first or a second step examination, especially in case of follow up of inflammatory disease.

**Epilogue** 15:20

1. To summarise the ten take home points.
2. To determine if modern imaging of the small bowel is accessible to the general radiologist or dedicated to subspecialists.
3. To conclude if the role of small bowel imaging will increase or decrease in the foreseeable future, as compared with endoscopy and biology.

---

**14:00 - 15:30**

**Room E1**

**Special Focus Session**

**SF 15a**

**Frontiers in liver imaging**

*Moderator: E.J. Rummeny; Munich/DE*

**A-352** 14:00

**Chairman's introduction**

E.J. Rummeny; *Munich/DE*

*Session Objectives:*

1. To describe new CT and MRI techniques for accurate detection and differentiation of focal liver lesions.
2. To become familiar with the use of MR contrast agents and to discuss advantages and limitations of liver specific agents.
3. To explain the appearance of liver lesions on CT and MR images and to compare imaging findings with histopathological results.

**A-353** 14:05

**Optimising MDCT for the detection and characterisation of liver tumors**

F. Caseiro-Alves; *Coimbra/PT*

*Learning Objectives:*

1. To describe CT protocols to optimize the detection and characterization of liver lesions and explain advantages and disadvantages of different MDCT techniques (4-row to 64-row).
2. To provide protocols for optimal delivery of i.v. contrast media.
3. To explain the value of multiplanar reconstructions in the preoperative setting.

**A-354** 14:23**Maximising the accuracy of MRI for the detection and characterisation of liver tumors**J. Gaa; *Munich/DE**Learning Objectives:*

1. To describe recent advances in MR imaging of the liver; such as fast imaging and diffusion weighted MRI.
2. To provide protocols for optimal lesion detection and characterisation.

**A-355** 14:41**The role of contrast agents in liver MRI**P.J.A. Robinson; *Leeds/UK**Learning Objectives:*

1. To understand the basic pharmacodynamics and the enhancement characteristics of the contrast agents used in liver MRI.
2. To become familiar with the appropriate selection of acquisition parameters for each type of contrast agent.
3. To appreciate the advantages and limitations of each agent in specific clinical applications.

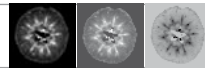
**A-356** 14:59**Why liver tumors appear as they do? Imaging-pathologic correlation**P.R. Ros; *Barcelona/ES**Learning Objectives:*

1. To compare CT- and MR imaging with histopathological findings in primary and secondary liver tumors.
2. To explain the appearance of uncommon liver lesions.

**Panel discussion:****When to use CT and when MR imaging for the diagnostic work up in patients with suspected liver tumors and what are the advantages and limitations of the use of liver specific MR contrast agents?** 15:17**14:00 - 15:30****Room E2****Interactive Teaching Session****E<sup>3</sup> 1520****The imaging management of back pain***Moderator: D.J. Wilson; Oxford/UK***A-357** 14:00**The imaging management of back pain**V.N. Cassar-Pullicino<sup>1</sup>, F. Aparisi<sup>2</sup>; <sup>1</sup>*Oswestry/UK*, <sup>2</sup>*Valencia/ES**Learning Objectives:*

1. To comprehend the clinical criteria that act as the basis of guidelines for referral to imaging departments, with particular reference to the clinical "red flag" indicators requiring urgent imaging.
2. To understand the strengths and weaknesses of the imaging modalities available for imaging back pain, how they are harnessed in an appropriate manner including the role of interventional diagnostic techniques.
3. To become familiar with the main differentiating imaging based diagnostic features that are the mainstay in making a diagnosis of degenerative, inflammatory, infectious and neoplastic disease.





14:00 - 15:30

Room F1

**Genitourinary**

**RC 1507**

**Percutaneous stone extraction: Success by team work**

*Moderator: M. Riccabona; Graz/AT*

**A-358** 14:00

**A. Which stones need a percutaneous extraction and how is it done?**

S. Moussa; *Edinburgh/UK*

*Learning Objectives:*

1. To learn the indications for percutaneous stone extraction.
2. To appreciate 3D anatomy and renal access.
3. To become familiar with tools: Needles and guide wires; methods of tack dilatation (telescopic dilators, teflon dilators, balloon).

**A-359** 14:30

**B. The role of the radiologist**

A. Magnusson; *Uppsala/SE*

*Learning Objectives:*

1. To understand the importance of preoperative radiological planning.
2. To become familiar with 3D CT imaging of complex renal stones.
3. To understand how to create an optimal track for percutaneous stone extraction.

**A-360** 15:00

**C. The role of the endourologist**

M. Brehmer; *Stockholm/SE*

*Learning Objectives:*

1. To understand when percutaneous stone extraction should be considered.
2. To become familiar with what the endourologist can do in patients with complex concretions in the renal pelvis.
3. To understand the importance and benefits of a good collaboration between the endourologist and the radiologist in percutaneous stone surgery.

14:00 - 15:30

Room F2

**Breast**

**RC 1502**

**Ultrasound and breast disease**

*Moderator: H.M. Zonderland; Amsterdam/NL*

**A-361** 14:00

**A. Understanding anatomy to detect disease**

G. Rizzatto; *Gorizia/IT*

*Learning Objectives:*

1. To show disease as typical echogenic and parenchymal changes.
2. To demonstrate high resolution breast anatomy.
3. To identify pathology by looking for anatomic changes.

MONDAY

**A-362** 14:30**B. 3D-4D breast ultrasound**C.F. Weismann; Salzburg/AT*Learning Objectives:*

1. To understand technical issues and differences in 3D and 4D sonography.
2. To explain images related to normal anatomy.
3. To show pathologic images (morphology, extent, staging).

**A-363** 15:00**C. Lesion characterisation**M. Locatelli; Gorizia/IT*Learning Objectives:*

1. To show B-mode and color-flow algorithms.
2. To understand BI-RADS categories.
3. To review updated approaches for characterisation.

**14:00 - 15:30****Room G/H****Neuro****RC 1511****Brain tumors***Moderator: J. Rusalleda; Barcelona/ES***A-364** 14:00**A. Pituitary lesions**F. Bonneville; Paris/FR*Learning Objectives:*

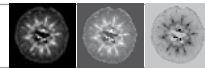
1. To learn the imaging protocol for the detection of pituitary lesions.
2. To discuss the clinical and imaging features of micro-adenoma of the hypophysis.
3. To discuss the clinical and imaging features of macro-adenoma of the hypophysis.
4. To discuss the differential diagnosis of micro- and macro-adenoma of the hypophysis.

**A-365** 14:30**B. Primary brain tumors**S. Karampekios; Iraklion/GR*Learning Objectives:*

1. To learn the incidence and neuropathology of primary brain tumors.
2. To learn the typical imaging features of primary brain tumors.
3. To report on the limitations of conventional contrast-enhanced MR imaging in the diagnosis and differential diagnosis of brain tumors.

**A-366** 15:00**C. Pseudo-tumoral lesions: Diagnosis and differential diagnosis**C.F. Andreula; Bari/IT*Learning Objectives:*

1. To discuss the most frequent brain lesions that can simulate a brain tumor.
2. To learn possible differential diagnostic signs on conventional neuroradiological examinations.
3. To discuss the impact of advanced techniques in the differential diagnosis of pseudo-tumoral lesions.



14:00 - 15:30

Room I

**Physics in Radiology**

**RC 1513**

**Managing patient dose**

*Moderators: W. Burkart; Vienna/AT, M. Raissaki; Iraklion/GR*

**A-367** 14:00

**A. In diagnostic radiology**

K. Faulkner; *Wallsend/UK*

*Learning Objectives:*

1. To review dose levels in diagnostic radiology.
2. To understand optimisation and justification.
3. To provide examples of dose reduction.

**A-368** 14:30

**B. In interventional radiology**

R. Padovani; *Udine/IT*

*Learning Objectives:*

1. To review dose levels.
2. To understand optimisation and justification.
3. To provide specific examples and guidance.

**A-369** 15:00

**C. In nuclear medicine**

S. Christofides; *Nicosia/CY*

*Learning Objectives:*

1. To review administration practice.
2. To understand optimisation and justification.
3. To provide specific data.



14:00 - 15:30

Room K

**Pediatric**

**RC 1512**

**Neuro imaging**

*Moderator: S. Cakirer; Istanbul/TR*

**A-370** 14:00

**A. State-of-the-art neurosonography**

C. Veyrac; *Montpellier/FR*

*Learning Objectives:*

1. To describe and illustrate the ultrasound pattern of brain lesions in premature infants.
2. To demonstrate how colour and pulsed Doppler provides additional information to the morphological assessment.
3. To discuss the timing of sonographic follow up in brain-damaged premature infants.

MONDAY

**A-371** 14:30**B. Neurotrauma**C. Christophe; *Brussels/BE**Learning Objectives:*

1. To emphasise the anatomical and physiological differences in young children.
2. To describe the primary and secondary lesions (intra-parenchymal and extra-axial lesions).
3. To illustrate the challenge in diagnosis of non-accidental injury (child abuse) and its characteristics.

**A-372** 15:00**C. MR of the hypothalamo-pituitary axis**M.I. Argyropoulou; *Ioannina/GR**Learning Objectives:*

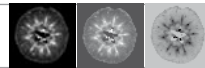
1. To evaluate the MR characteristics of the normal hypothalamo-pituitary axis in full-term and preterm children.
2. To determine study protocols.
3. To define the role of MR in the study of dysfunctional states.

**14:00 - 15:30****Room L/M****Radiographers****RC 1514****Computed tomography: CT and contrast media***Moderators: S. Huber; Munich/DE, H. Ringertz; Stanford, CA/US***A-373** 14:00**A. Optimising CM injection protocols in MDCT: Is faster always better?**E. Agadakos; *Athens/GR**Learning Objectives:*

1. To identify the factors affecting contrast media enhancement in MDCT.
2. To consolidate the knowledge of existing acquisition and injection parameters and the potential offered by most recent MDCT systems.
3. To modify the examination technique employing dose reduction methods and according to patient characteristics and diagnostic requirements.
4. To understand that diagnostic quality should override the speed available with rapid MDCT scanning.

**A-374** 14:45**B. The patterns of contrast enhancement of vessels and tissues related to the parameters of intravenous injection of CM**A. Lukken, E. Linnasmägi; *Tartu/EE**Learning Objectives:*

1. To give an overview of the specialized literature which describes the patterns of contrast enhancement of vessels and tissues related to the parameters of intravenous injection of contrast media based on routine CT investigation.
2. To give an overview of the investigation exact parameters (delay time, injection rate) for attaining the optimal contrast enhancement of vascular structures and tissues on computed tomography at Tartu University Clinics.
3. To understand what are the main issues of tissues and vessels enhancement.



14:00 - 15:30

Room N/O

**Special Focus Session**

**SF 15b**

**Advances in tumor ablation**

*Moderator: A. Gangji; Strasbourg/FR*

**A-375** 14:00

**Chairman's introduction**

A. Gangji; Strasbourg/FR

*Session Objectives:*

1. To review different techniques of tumor ablation.
2. To underline the advantages and drawbacks of each technology.
3. To understand the potential of each technique.

**A-376** 14:05

**Should thermal ablation replace partial nephrectomy?**

P.R. Mueller; Boston, MA/US

*Learning Objectives:*

1. To learn the differences between nephron sparing surgery and percutaneous RF ablation.
2. To understand the advantages and disadvantages of both techniques.

**A-377** 14:28

**Percutaneous cryotherapy: When should it be preferred to radiofrequency?**

X. Buy, A. Gangji; Strasbourg/FR

*Learning Objectives:*

1. To familiarise with the principles of cryotherapy.
2. To outline the advantages and the drawbacks of the cryotherapy, compared to other ablation techniques.
3. To describe the best indications.

**A-378** 14:51

**High frequency focused ultrasound: Is it a real clinical tool?**

G.R. ter Haar; Sutton/UK

*Learning Objectives:*

1. To become familiar with the requirements to which a new technique must conform before it can be accepted as a real, widely accepted and acceptable useful clinical tool.
2. To understand the technique of high intensity focused ultrasound (HIFU), and to comprehend what it has to offer as a cancer treatment.

**Panel discussion:**

**Evolution and progress in tumor ablation** 15:14

MONDAY

**14:00 - 15:30****Room R1****Chest****RC 1504****Diagnostic mimics in chest diseases***Moderator: E. Castañer; Sabadell/ES***A-379** 14:00**A. Focal opacity**

F. Gleeson; Oxford/UK

*Learning Objectives:*

1. To become familiar with the appearances of the different focal opacities seen on the CXR and chest CT.
2. To learn about the different causes of focal opacities on CXR.
3. To appreciate the different techniques that may be used to differentiate the causes of focal chest opacities.

**A-380** 14:30**B. Alveolar opacities**

C. Schaefer-Prokop; Amsterdam/NL

*Learning Objectives:*

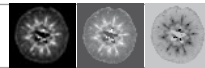
1. To become familiar with an alveolar pattern in CXR and CT.
2. To understand the underlying radiologic-pathologic correlations of alveolar opacities.
3. To review the spectrum of the common and unusual conditions presenting with an alveolar pattern.
4. To discuss an approach to the differential diagnosis based on clinical information, distribution of disease and additional morphological findings.

**A-381** 15:00**C. Interstitial opacities**

A. Oikonomou; Alexandroupolis/GR

*Learning Objectives:*

1. To learn about the different HRCT patterns, which are related to interstitial lung diseases and to understand the underlying pathologic-radiologic correlations that cause each HRCT pattern.
2. To be familiar with the more "classical" entities presenting with each HRCT pattern and to discuss the possible overlap of different HRCT patterns and the more common diagnostic mimics in each case.
3. To familiarise with potential pitfalls in diagnosing interstitial opacities on HRCT and learn about some clues that help differentiate the various diagnostic mimics.



14:00 - 15:30

Room R2

**Breast: From Basics to Advanced Imaging**

**CC 1518**

**Interventional procedures**

*Moderator: D. Flöry; Vienna/AT*

**A-382** 14:00

**A. Mammography guidance**

C. Del Frate; Udine/IT

*Learning Objectives:*

1. To become familiar with presurgical localisation procedures.
2. To understand basic principles and technical aspects of stereotactic technique.
3. To learn when and how to perform stereotactic vacuum-assisted biopsies.

**A-383** 14:30

**B. US guidance**

J. Camps-Herrero; Valencia/ES

*Learning Objectives:*

1. To know indications of US-guided interventional procedures.
2. To describe technical aspects of US-guided interventional procedures.
3. To discuss potential pitfalls and how to avoid them.

**A-384** 15:00

**C. MR guidance**

J. Veltman, C. Boetes; Nijmegen/NL

*Learning Objectives:*

1. To learn about patient selection for MR-guided interventional procedures.
2. To describe current techniques (preoperative localisation and biopsy).
3. To discuss potential pitfalls and how to avoid them.
4. To know the diagnostic accuracy achievable with these techniques.

14:00 - 15:30

Room R3

**Interventional Radiology**

**RC 1509**

**Treatment of acute hemorrhage**

*Moderator: J.E. Jackson; London/UK*

**A-385** 14:00

**A. Hemoptysis**

M. Szczerbo-Trojanowska; Lublin/PL

*Learning Objectives:*

1. To discuss the diagnosis and imaging of hemoptysis.
2. To review the techniques of bronchial angiography and embolisation.
3. To learn about tips and tricks for the embolisation of difficult cases.
4. To review about the results and complications of endovascular therapy.

**A-386** 14:30**B. Gastrointestinal hemorrhage**

O.M. van Delden; Amsterdam/NL

*Learning Objectives:*

1. To discuss the best method to image acute gastrointestinal hemorrhage.
2. To learn about the techniques for embolisation of acute gastrointestinal hemorrhage.
3. To review the techniques for the diagnosis of patients with chronic gastrointestinal hemorrhage.
4. To discuss the results and complications of the endovascular management of gastrointestinal hemorrhage.

**A-387** 15:00**C. Posttraumatic hemorrhage**

O. Pellerin; Paris/FR

*Learning Objectives:*

1. To review the imaging for hemorrhage related to trauma.
2. To discuss the logistics involved in providing an emergency embolisation service for acute traumatic hemorrhage.
3. To learn about the techniques for the embolisation of hemorrhage related to trauma.
4. To review the optimal materials to be used for the embolisation of trauma.

**16:00 - 17:30****Room A****MRI****CC 1616****Cardiac MRI: An affair of the heart***Moderator: V.E. Sinitsyn; Moscow/RU***A-388** 16:00**A. Ischemic disease**

A. de Roos; Leiden/NL

*Learning Objectives:*

1. To learn about the accuracy of different MR perfusion techniques for detection of significant coronary artery disease.
2. To understand the assessment of myocardial viability by delayed contrast enhancement techniques.
3. To implement a fast and robust clinical protocol for comprehensive assessment of ischemic heart disease.
4. To become familiar with new technical developments for MRA of the coronary arteries.

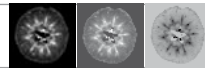
**A-389** 16:30**B. Non-ischemic diseases: Does MRI see them all?**

J. Bogaert; Leuven/BE

*Learning Objectives:*

1. To describe the differential diagnoses for non-ischemic heart diseases including cardiomyopathies, inflammatory disease and storage diseases.
2. To learn about the typical findings and patterns on contrast-enhanced and non-enhanced MRI.
3. To understand their impact on cardiac function.
4. To recognise the changes in imaging findings during the course of disease and under therapy.





**A-390** 17:00

**C. Congenital disease**

J. Bremerich; Basle/CH

*Learning Objectives:*

1. To understand the different types of congenital heart defects and relate the anatomical features to typical imaging findings.
2. To become familiar with the technical requirements for assessment by MRI.
3. To define specific protocols for a comprehensive evaluation of individual congenital defects.
4. To relate the MRI findings to those of ultrasound and CT.

---

**16:00 - 17:30**

**Room B**

**Professional Challenges Session**

**PC 16**

**Women in radiology: How to maximise their input**

*Moderator: H.M.L. Carty; Liverpool/UK*

**A-391** 16:00

**Chairman's introduction**

H.M.L. Carty; Liverpool/UK

*Session Objectives:*

1. To explore the issues arising from the employment of an increasing female workforce.
2. To stimulate thought about how traditional working patterns might be altered with benefit to all.
3. To increase awareness of the effect of European Legislation on Working Time Directives on radiologists.
4. To initiate discussion on the importance of balance between life and work.

**A-392** 16:05

**Life as a radiologist, before and after children**

B. Ertl-Wagner; Munich/DE

*Learning Objectives:*

1. To gain an understanding of the sociology of gender employment.
2. To see how the theory applies to radiology.
3. From theory to practice: A personal experience.

**A-393** 16:20

**Eastern Europe: Are the issues the same?**

K. Gruszczynska; Katowice/PL

*Learning Objectives:*

1. To provide information about the number of women radiologist in Eastern Europe, their present status and achievements, changes during last 20 years and future perspectives.
2. To present the working environment: Organisation of national radiology services, structure of radiology departments, legislation, financial conditions.
3. To explore relationship between work and family life from radiology training to retirement.
4. To highlight the main differences between Eastern and Western Europe.

**A-394** 16:35

**Can you be a good parent and a good academic radiologist?**

I.M. Björkman-Burtscher; Lund/SE

*Learning Objectives:*

1. To identify key conflicts in combining parenthood with academic work.
2. To relate different working conditions and lifestyles to these conflicts.
3. To reflect on possible problem solving strategies.

**A-395** 16:50**Family friendly work patterns: How to integrate them in radiology departments**

C. Roche; Galway/IE

*Learning Objectives:*

1. To explain how radiological work patterns will change over the next 10 years with an increasing proportion of female radiologists.
2. To understand the challenges facing radiology departments as they try to balance demands for flexible working hours with provision of service.
3. To illustrate how evolving technologies can help to create a better work-life balance.

**Panel discussion:****Surviving parenthood and radiology. Having it all. Doing it all. Missing it all?** 17:05**16:00 - 17:30****Room C****Special Focus Session****SF 16a****Emergency imaging: Avoiding serious mistakes!***Moderator: R.F. Dondelinger; Liège/BE***A-396** 16:00**Chairman's introduction**

R.F. Dondelinger; Liège/BE

*Session Objective:*

1. To understand the numerous factors generating serious mistakes in emergency radiology applied to the central nervous system, chest, abdomen and the musculoskeletal system.

**A-397** 16:05**Central nervous system**

D. Balériaux; Brussels/BE

*Learning Objectives:*

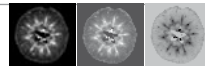
1. To comprehend clinical situations for which proper management and adequate choice of optimal imaging modalities is of utmost importance. This includes not only traumatic but also infectious, vascular and tumoral pathologies.
2. To understand how and why serious mistakes are sometimes made and how to avoid them by being more aware of the absolute necessity for a radiologist to be informed by the referring physician about the patient's clinical history, clinical examination and suspected pathology.
3. To become familiar with the latest technical performances of spiral CT and MRI enabling fast and accurate diagnosis of pathologies requiring rapid therapeutic actions.

**A-398** 16:23**Chest**

C. Beigelman-Aubry; Paris/FR

*Learning Objectives:*

1. To be familiar with technical factors including acquisition and reconstruction parameters potentially generating pitfalls in CT analysis in chest emergencies.
2. To be aware of potential pitfalls due to contrast media administration, including the site of injection, the quality and timing of vascular opacification or the window settings used.
3. To know when and how to use post-processing tools in specific conditions especially in polytrauma patients according to the underlying pathology researched.
4. To recognise the artefacts created by external devices or respiratory motion for final interpretation.



**A-399** 16:41

**Abdomen**

A.H. Freeman; Cambridge/UK

*Learning Objective:*

1. To become familiar with the potential causes of error in abdominal radiology and thus reduce the prospect of misinterpretation in the acute setting.

**A-400** 16:59

**Musculoskeletal**

K. Bohndorf; Augsburg/DE

*Learning Objectives:*

1. To understand the systematic nature of the majority of mistakes in radiology.
2. To review the most relevant sources of error in emergency radiology.
3. To discuss typical examples of errors.

**Panel discussion:**

**Highlights of imaging pitfalls and limits in emergency conditions** 17:17

---

**16:00 - 17:30**

**Room E1**

**Musculoskeletal**

**RC 1610**

**New trends in musculoskeletal radiology**

*Moderator: A. Baur-Melnyk; Munich/DE*

**A-401** 16:00

**A. Cartilage imaging**

C. Glaser; Munich/DE

*Learning Objectives:*

1. To understand the principles of mapping physiologic MRI parameters (T1, T2) of cartilage.
2. To discuss potential, limitations and current data of these techniques.
3. To describe the impact of increased field strength (3T) on cartilage imaging.
4. To demonstrate examples of MRI in cartilage repair.

**A-402** 16:30

**B. Diffusion imaging and tractography**

C. Khalil; Lille/FR

*Learning Objectives:*

1. To understand the basic principles of diffusion imaging.
2. To discuss the potential applications of these techniques in musculoskeletal diseases.
3. To discuss their limitations and how improvements may be made.

**A-403** 17:00

**C. MR contrast media**

D. Weishaupt; Zurich/CH

*Learning Objectives:*

1. To discuss the current role and applications of contrast agents with special focus on cellular imaging in musculoskeletal diseases.
2. To review the results obtained in cellular imaging of musculoskeletal diseases and to discuss their impact on therapies.
3. To provide an outlook of future developments in cellular MR imaging in the assessment of musculoskeletal diseases.

**16:00 - 17:30****Room E2****Interactive Teaching Session****E<sup>3</sup> 1620****Traps in imaging of cirrhosis and portal hypertension***Moderator: M. Escobar; Barcelona/ES***A-404** 16:00**Traps in imaging of cirrhosis and portal hypertension**Y. Menu<sup>1</sup>, A. Besim<sup>2</sup>; <sup>1</sup>Le Kremlin-Bicêtre/FR, <sup>2</sup>Ankara/TR*Learning Objectives:*

1. To learn the imaging signs of liver cirrhosis.
2. To discuss the possibility for imaging to detect and classify portal hypertension.
3. To understand the physiology of porto-caval and porto-portacollaterals.
4. To discuss the indications and results of intervention in case of cirrhosis and portal hypertension.

**16:00 - 17:30****Room F1****Special Focus Session***(In cooperation with the European Association of Nuclear Medicine)***SF 16b****Molecular imaging***Moderators: F. Berger; Munich/DE, U. Haberkorn; Heidelberg/DE***A-405** 16:00**Chairmen's introduction**U. Haberkorn<sup>1</sup>, F. Berger<sup>2</sup>; <sup>1</sup>Heidelberg/DE, <sup>2</sup>Munich/DE*Session Objectives:*

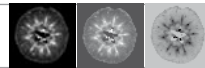
1. To introduce techniques for the non-invasive quantitation of tumor blood flow, vessel density and cellular/molecular markers of angiogenesis. This will be done for radio-isotope based methods and for magnetic resonance imaging.
2. To discuss the advantages and drawbacks of the methods presented with respect to their preclinical and clinical utility.
3. To present techniques for cell tracking for radio-isotope based methods and for magnetic resonance imaging.
4. To present preclinical and clinical evidence for the successful application of these methods in monitoring and optimising cellular therapies.

**Angiogenesis****A-406** 16:06**Imaging of angiogenesis with MRI**

M. Neeman; Rehovot/IL

*Learning Objectives:*

1. To outline the mechanisms and potential imaging targets in the angiogenic process that are accessible by MRI.
2. To review the functional MRI tools available for imaging angiogenesis.
3. To review the molecular and cellular MR methods for imaging angiogenesis.



**A-407** 16:24

**Imaging of angiogenesis using radiolabelled peptides**

R. Haubner; Innsbruck/AT

*Learning Objectives:*

1. To become familiar with possible molecular targets for imaging angiogenesis with nuclear medicine tracer techniques.
2. To understand some basic principles in tracer development.
3. To become familiar with new tracer for monitoring integrin  $\alpha\beta 3$  expression.

**Tracking stem cells**

**A-408** 16:42

**Tracking of stem cells by radioisotopes**

P.-Y. Marie<sup>1</sup>, W. Brenner<sup>2</sup>; <sup>1</sup>Vandoeuvre-lès-Nancy/FR, <sup>2</sup>Hamburg/DE

*Learning Objectives:*

1. To choose the more accurate radioisotopic imaging technique (SPECT or PET, hybrid systems involving CT).
2. To choose an adapted labeling process (minimal cells alteration and minimal leakage of the label; direct cells labeling or gene transfection prior to transplantation).
3. To list the useful information that may be expected to be collected in man and in experimental models.

**A-409** 17:00

**Following stem cells by MRI**

P. Jendelova; Prague/CZ

*Learning Objectives:*

1. To label stem cells with different intracellular and extracellular magnetic labels based on superparamagnetic iron-oxida nanoparticles.
2. To implant stem cells into living organism and to follow the implanted cells using MRI.
3. To point out the advantages and disadvantages of this method.

**Panel discussion** 17:18

---

**16:00 - 17:30**

**Room F2**

**Breast**

**RC 1602**

**Diagnosis and staging of breast cancer**

*Moderator: R. Schulz-Wendtland; Erlangen/DE*

**A-410** 16:00

**A. IDC and ILC: Diagnostic challenges**

C. Boetes; Nijmegen/NL

*Learning Objectives:*

1. To understand anatomic features affecting clinical and imaging behaviour.
2. To summarise mammographic, ultrasound and MR findings.
3. To alert recognition.

**A-411** 16:30

**B. Lymph-node evaluation**

M.H. Fuchsjaeger; Vienna/AT

*Learning Objectives:*

1. To describe the radioguided occult lesion localisation (ROLL) procedure.
2. To describe findings with mammography, ultrasound and sampling to avoid ROLL.
3. To explain MRI diagnostic parameters.

**A-412** 17:00

**C. Interventional procedures**

L. Steyaert; Bruges/BE

*Learning Objectives:*

1. To define the sampling technique.
2. To identify the appropriate guide.
3. To outline quality assurance.

**16:00 - 17:30**

**Room G/H**

**Neuro**

**RC 1611**

**Grey and white matter disease**

*Moderator: H.R. Jäger; London/UK*

**A-413** 16:00

**A. Demyelinating diseases**

E.-W. Radü; Basle/CH

*Learning Objectives:*

1. To learn the clinical presentation and classification of demyelinating disease of the brain.
2. To learn the imaging protocol for demyelinating diseases.
3. To learn the characteristic imaging features of different demyelinating diseases.

**A-414** 16:30

**B. Dementia**

B. Gómez-Ansón; Barcelona/ES

*Learning Objectives:*

1. To learn the different clinical and pathological types of dementia.
2. To learn the imaging protocol for dementia.
3. To learn the differential imaging features of dementia.

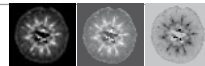
**A-415** 17:00

**C. Brain and meningeal infections**

E. Tali; Ankara/TR

*Learning Objectives:*

1. To recognise the different types, aetiology and clinical findings of brain and meningeal infections.
2. To learn about the various imaging techniques and protocols in the diagnosis of brain and meningeal infections.
3. To learn about the typical imaging findings in brain and meningeal infections.



16:00 - 17:30

Room I

**Physics in Radiology**

**RC 1613**

**Monitor reporting: Quality and diagnostic accuracy**

*Moderators: C. Leidecker; Malvern, PA/US, S. Wirth; Munich/DE*

**A-416** 16:00

**A. Display system requirements for full field digital mammography: FDA perspective**

K. Chakrabarti; Rockville, MD/US

*Learning Objectives:*

1. To review the image quality requirements.
2. To discuss the display requirements for review and reporting.
3. To provide specific guidance on monitor requirements.

**A-417** 16:30

**B. MoniQA: Software for monitor QA**

H. Bosmans; Leuven/BE

*Learning Objectives:*

1. To learn about monitor QA.
2. To present an approach to QA.
3. To discuss monitor QA.

**A-418** 17:00

**C. Cost effectiveness of monitor reporting**

M.G. Wallis; Cambridge/UK

*Learning Objectives:*

1. To review the cost effectiveness of monitor reporting.
2. To discuss the implications of monitor reporting.
3. To describe practical approaches.

16:00 - 17:30

Room K

**Pediatric**

**RC 1612**

**Safety considerations in imaging**

*Moderator: R. Fother; Graz/AT*

**A-419** 16:00

**A. Dose reduction**

C. Owens; London/UK

*Learning Objectives:*

1. To define the (often inappropriate) radiation burden to children as a result of medical imaging.
2. To describe the options for dose reduction and optimisation with particular reference to those techniques with the highest radiation burden.
3. To suggest a cooperative strategy for collaborative dose reduction protocols to be widely available to all units treating children throughout Europe.

**A-420** 16:30**B. MR friendly: Safety and techniques adapted to children**

O.E. Olsen; London/UK

*Learning Objectives:*

1. To understand the most important technical adaptations for paediatric body imaging.
2. To understand the most important biological differences (particularly of malignant tumors) that have consequences for MRI interpretation.

**A-421** 17:00**C. Anesthesia and sedation in pediatric imaging**

F. De Groot; Brussels/BE

*Learning Objectives:*

1. To describe conditions requiring sedation or anesthesia in children.
2. To show how to optimise anesthetic methods when using the various imaging techniques.

**16:00 - 17:30****Room L/M****Radiographers****RC 1614****Non medical applications***Moderators: I. Isherwood; Manchester/UK, M. Jökel; Hamburg/DE***A-422** 16:00**A. Imaging in archaeology**

P. Pipan; Trieste/IT

*Learning Objectives:*

1. To characterise the modern role of radiography within the archaeological field.
2. To demonstrate the possibilities offered from radiography in non-destructive testing.
3. To explain the possibilities of the virtual restoration.
4. To show an example of PACS based didactic platform.

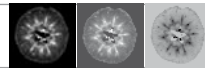
**A-423** 16:45**B. Imaging in art**

P. Gerson; Paris/FR

*Learning Objectives:*

1. To learn about radiology in works of art.
2. To appreciate why this technique is used and by which professionals.
3. To become familiar with the technique of radiology for paintings and sculpture.
4. To consolidate knowledge of history of paintings and sculpture.





16:00 - 17:30

Room N/O

## Molecular Imaging and Contrast Media

**RC 1606**

### US contrast agents

Moderator: O. Catalano; Naples/IT

**A-424** 16:00

#### A. Basics of US contrast agents

A.P. Wiecezorek; Lublin/PL

Learning Objectives:

1. To understand the basic physics and the mechanisms of action of US bubbles.
2. To become familiar with pharmacokinetics of US contrast agents.
3. To understand quantification of measured parameters.

**A-425** 16:30

#### B. Current and future applications

J.-M. Correas; Paris/FR

Learning Objectives:

1. To become familiar with clinical applications to date.
2. To learn in-vivo experimental application of US contrast agents.
3. To discuss factors that influence quantitative assessments.

**A-426** 17:00

#### C. Targeted US bubbles

M. Mäurer; Erlangen/DE

Learning Objectives:

1. To become familiar with molecular targets for US bubbles.
2. To become familiar with chemistry and pharmacokinetics of targeted US bubbles.
3. To learn about potential clinical applications of targeted US bubbles.
4. To learn about projected clinical developments for targeted ultrasound bubbles.

16:00 - 17:30

Room R1

## Chest

**RC 1604**

### Computer-aided diagnosis in the chest

Moderator: P.A. Grenier; Paris/FR

**A-427** 16:00

#### A. Techniques behind CAD

B. van Ginneken; Utrecht/NL

Learning Objectives:

1. To learn about computer-aided diagnosis application for chest radiography and chest CT that are currently available.
2. To learn about novel applications in development.
3. To appreciate the strengths and weaknesses of computer algorithms and how to avoid common pitfalls.
4. To learn how computerised matching and subtraction can help you in efficiently diagnosing follow up chest examinations.

**A-428** 16:30**B. Lung nodule: Detection and characterisation**D. Wormanns; *Berlin/DE**Learning Objectives:*

1. To learn about the limited sensitivity of radiologists for detection of pulmonary lesions like early stages of lung cancer and pulmonary metastases.
2. To appreciate the benefit of software assistance to detect lung lesions.
3. To understand current diagnostic strategies for workup of the solitary pulmonary nodule.
4. To become familiar with the advantages and limitations of computer applications for nodule characterisation, in particular for detection of growth and contrast enhancement.
5. To understand current problems to integrate CAD systems into the clinical workflow and to learn about possible solutions.

**A-429** 17:00**C. Advanced applications**H.-U. Kauczor; *Heidelberg/DE**Learning Objectives:*

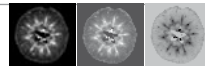
1. To understand the rationale for CAD in airway disease, emphysema and pulmonary embolism.
2. To learn about the reliability of software tools for quantification of disease severity.
3. To appreciate the potential and the limitations of structure-based parameters as surrogates for pulmonary function.
4. To become familiar with four dimensional imaging for the analysis of respiratory motion.

**16:00 - 17:30****Room R2****Breast: From Basics to Advanced Imaging****CC 1618****Advanced imaging: Full-field digital mammography (FFDM)/MRI***Moderator: N. Karssemeijer; Nijmegen/NL***A-430** 16:00**A. FFDM = CAD, angio-mammography**C. Dromain; *Villejuif/FR**Learning Objectives:*

1. To become familiar with the basic CAD technologies.
2. To understand how to use CAD in routine practice.
3. To learn about basic principles and technical aspects of angio-mammography.
4. To describe results and the additional value of angio-mammography.

**A-431** 16:30**B. FFDM = Tomosynthesis**R.A. Jong; *Toronto, ON/CA**Learning Objectives:*

1. To understand basic principles and technical aspects of tomosynthesis.
2. To learn how to read a breast tomosynthesis examination.
3. To highlight clinical indications and results.



**A-432** 17:00

**C. MRI: MR techniques for optimal diagnostic accuracy**

C.K. Kuhl; Bonn/DE

*Learning Objectives:*

1. To understand which MR parameters are important for diagnostic accuracy.
2. To describe how to choose pulse sequence parameters properly for improving diagnostic accuracy.
3. To describe new MR techniques providing additional information to standard MR imaging.

---

**16:00 - 17:30**

**Room R3**

## **Interventional Radiology**

### **RC 1609**

#### **Carotid interventions**

*Moderator: A. Basile; Catania/IT*

**A-433** 16:00

**A. Patient selection and preprocedure imaging**

S. MacDonald; Newcastle upon Tyne/UK

*Learning Objectives:*

1. To discuss the indications for treatment.
2. To learn about preprocedural imaging prior to intervention.
3. To review the evidence for non-invasive imaging vs conventional angiography.

**A-434** 16:30

**B. Stenting technique, tips and tricks**

L. Stockx; Genk/BE

*Learning Objectives:*

1. To discuss the techniques of carotid artery stenting.
2. To review the materials used for carotid artery stenting including protection devices.
3. To learn about tips and tricks used for difficult cases.

**A-435** 17:00

**C. Results of stenting vs surgery trials**

J.C. van den Berg; Lugano/CH

*Learning Objectives:*

1. To review the published results of carotid stenting vs carotid endarterectomy.
2. To review the evidence for the use of protection devices.
3. To discuss the current ongoing clinical trials of stenting vs surgery.

**MONDAY**

**08:30 - 10:00****Room A****MRI****CC 1716****The future is now!***Moderator: C. Loewe; Vienna/AT***A-436** 08:30**A. Faster! Accelerated MRI with parallel imaging**B.J. *Wintersperger; Munich/DE**Learning Objectives:*

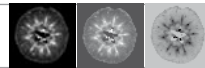
1. To understand the technical principles of parallel acquisition techniques and related methods for faster MR imaging.
2. To learn how to utilise the gain in speed for more robust and comprehensive MR protocols.
3. To become familiar with the clinical benefit for cardiac, vascular, abdominal and musculoskeletal MRI.
4. To describe the requirements for new coil designs.

**A-437** 09:00**B. Larger! Whole-body MRI: From morphology to disease**H.K. *Ahlström; Uppsala/SE**Learning Objectives:*

1. To learn about the technical implementation of a whole-body MRI protocol.
2. To apply whole-body imaging concepts to cardiovascular, oncologic and rheumatologic systemic diseases.
3. To become familiar with the typical findings compared with whole-body PET-CT and clinical manifestations.
4. To understand the application of these methods to secondary prevention and surveillance.

**A-438** 09:30**C. Better! Diffusion weighted MRI and MR-PETography**T. *La Folie; Marseille/FR**Learning Objectives:*

1. To become familiar with the principles of diffusion weighted imaging for tumor characterisation and lymph node detection.
2. To apply these methods to whole-body techniques.
3. To learn about their value compared with positron emission tomography.
4. To understand their role for assessment of therapeutic changes.



**Special Focus Session**

**SF 17a**

**CT and MR urography: Is intravenous urography dead?**

*Moderator: A.J. van der Molen; Leiden/NL*

**A-439** 08:30

**Chairman's introduction**

A.J. van der Molen; Leiden/NL

*Session Objectives:*

1. To review in justification and optimisation of cross-sectional urography methods.
2. To evaluate patient selection in available urography methods.
3. To discuss the future use of IVU in comparison with cross-sectional urography.

**A-440** 08:35

**CT urography**

N.C. Cowan; Oxford/UK

*Learning Objectives:*

1. To become familiar with protocol optimisation in CT urography.
2. To understand specific advantages and disadvantages of CTU.
3. To be able to select appropriate CTU indications (in comparison to MRU and IVU).

**A-441** 08:55

**MR urography**

C.C.A. Nolte-Ernsting; Hamburg/DE

*Learning Objectives:*

1. To become familiar with protocol optimisation in MR urography.
2. To understand specific advantages and disadvantages of MRU.
3. To be able to select appropriate MRU indications (in comparison to CTU and IVU).

**A-442** 09:15

**Cost-effectiveness of CTU vs MRU vs IVU**

H.S. Thomsen; Herlev/DK

*Learning Objectives:*

1. To understand the various costs of CTU and MRU vs IVU.
2. To understand the relative benefits of CTU, MRU and IVU.
3. To illustrate specific indications for CTU, MRU and IVU from an economic perspective.

**Panel discussion:**

**Is intravenous urography really dead?** 09:35

---

**08:30 - 10:00****Room C****Abdominal and Gastrointestinal****RC 1701****Liver vasculature: Radiologic anatomy and disorders***Moderator: R.W. Prokesch; Zell am See/AT***A-443** 08:30**A. Anatomy of liver vasculature: What the radiologist needs to know**

F. Caseiro-Alves; Coimbra/PT

*Learning Objectives:*

1. To describe the typical segmental anatomy of the liver.
2. To review vascular and biliary anatomy and anatomic variations.
3. To describe the clinical relevance of anatomic variations in patients undergoing surgery.

**A-444** 09:00**B. Portal hypertension: Imaging features**

M.-P. Vullierme; Clichy/FR

*Learning Objectives:*

1. To describe the imaging findings in liver disorders leading to portal hypertension.
2. To present the various imaging findings in portal hypertension.
3. To review the therapeutic options in patients with medically unstable portal hypertension.

**A-445** 09:30**C. Parenchymal disorders of vascular origin**

C.J. Zech; Munich/DE

*Learning Objectives:*

1. To review the imaging findings of diseases presenting with vascular shunting in the liver.
2. To demonstrate the spectrum of diseases with hepatic vein obstruction.
3. To present the parenchymal imaging findings of lobar and segmental vascular obstruction.

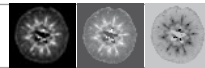
---

**08:30 - 10:00****Room E1****Musculoskeletal****RC 1710****Extra-spinal interventional procedures***Moderator: A. Chevrot; Paris/FR***A-446** 08:30**A. Basic interventional procedures**

G.K.O. Åström; Uppsala/SE

*Learning Objectives:*

1. To demonstrate therapeutic injections of nerves and joints.
2. To demonstrate treatment of calcifying tendinitis.
3. To review musculoskeletal biopsy procedures.
4. To instruct about the handling of biopsy specimens.



**A-447** 09:00

**B. Advanced interventional procedures**

J.-L. Drapé, A. Feydy, R. Campagna, H. Guerini; *Paris/FR*

*Learning Objectives:*

1. To inform of important considerations prior to biopsy of musculoskeletal tumors and to show complications.
2. To demonstrate percutaneous treatments of osteoid osteoma.
3. To discuss how and why one should perform percutaneous treatments of bone metastases.

**A-448** 09:30

**C. US-guided procedures**

C. Martinoli; *Genoa/IT*

*Learning Objectives:*

1. To learn how to locate the needle under US guidance, aspirate soft-tissue collections and inject joints.
2. To describe specific applications of US-guided interventional procedures in individual joints, tendons and nerves.
3. To understand the advantages and limitations of the US guidance in extraspinal interventional musculoskeletal radiology.

---

**08:30 - 10:00**

**Room E2**

**Interactive Teaching Session**

**E<sup>3</sup> 1720**

**Detection and diagnosis of interstitial lung diseases**

*Moderator: J. Andreu; Barcelona/ES*

**A-449** 08:30

**Detection and diagnosis of interstitial lung diseases**

S.R. Desai, S.P.G. Padley; *London/UK*

*Learning Objectives:*

1. To appreciate the diagnostic value of HRCT in the diffuse interstitial lung diseases (DILDs).
2. To learn some of the common patterns of DILDs on HRCT.
3. To understand the relationships between HRCT pattern and macroscopic pathological appearances.

**08:30 - 10:00****Room F1****Head and Neck****RC 1708****What you always wanted to hear about hearing loss***Moderator: B.F. Schuknecht; Zurich/CH***A-450** 08:30**A. What the ENT surgeon wants to know from the radiologist***W. Gstöttner; Frankfurt a. Main/DE**Learning Objectives:*

1. To explain implications of external auditory canal imaging results for the treatment of patients with hearing loss.
2. To delineate the importance of preoperative CT for surgery of large cholesteatomas of the temporal bone.
3. To demonstrate the clinical and radiological findings in the diagnosis and treatment of otosclerosis.
4. To show usefulness of imaging modalities in preoperative assessment of cochlear implant candidates and in postoperative search for complications.

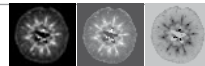
**A-451** 09:00**B. Pathology of the external and middle ear***F. Veillon; Strasbourg/FR**Learning Objectives:*

1. To learn different causes of hearing loss within external auditory canal and middle ear.
2. To know optimisation of imaging techniques used for assessment of external auditory canal and middle ear.
3. To familiarise with imaging findings within external auditory canal and middle ear in patients with conductive hearing loss.

**A-452** 09:30**C. Pathology of the inner ear***J.W. Casselman; Bruges/BE**Learning Objectives:*

1. To learn the imaging techniques used to depict pathology of the inner ear.
2. To know inner ear pathologies resulting in congenital hearing loss.
3. To become familiar with acquired non-neoplastic causes of hearing loss.
4. To know the tumoral lesions of the inner ear which will result in hearing loss.





08:30 - 10:00

Room F2

**Special Focus Session**

**SF 17b**

**New radiation risk estimation: Can we relax?**

*Moderator: J. Damilakis; Iraklion/GR*

**A-453** 08:30

**Chairman's introduction**

J. Damilakis; Iraklion/GR

*Session Objectives:*

1. To elucidate the concept of radiation risk for high and low doses.
2. To become familiar with risk coefficients for stochastic effects proposed by radiation protection organisations.
3. To discuss ethical issues associated with exposure to diagnostic X-rays and radiation protection.

**A-454** 08:35

**Does the ever increasing exposure of patients in diagnostic radiology really pose a problem?**

G. Brix; Neuherberg/DE

*Learning Objectives:*

1. To consolidate knowledge of factors determining radiation risks of patients undergoing X-ray procedures.
2. To become familiar with radiation exposure of seriously ill patients, in particular cancer patients.
3. To understand the necessity to focus risk assessment on the group of persons really exposed and not to use an average effective dose per inhabitant.

**A-455** 08:58

**Appropriate use of a modality with high diagnostic accuracy and high radiation exposure: Multidetector CT**

J.R. Mayo; Vancouver, BC/CA

*Learning Objectives:*

1. To give an overview of the diagnostic power of MDCT.
2. To become familiar with radiation dose reduction strategies in MDCT.
3. To understand the relationship between diagnostic accuracy and radiation exposure in CT.

**A-456** 09:21

**Radiation protection, ethics, law and public awareness: In harmony or out of tune?**

J. Malone; Dublin/IE

*Learning Objectives:*

1. To become familiar with ethical and/or legal issues related to the use of diagnostic X-rays.
2. To gain an understanding of the areas where the philosophy of radiation protection is out of step with the culture and to appreciate the nature of the ethical, legal and medico-legal risks that flow from this.
3. To understand some of the courses of action that are open to international bodies and the professions, if or when, they are challenged in this regard.

**Panel discussion:**

**Diagnostic X-rays and radiation risk assessment: Facts and controversies**

09:44

**08:30 - 10:00****Room G/H****Neuro****RC 1711****Interventional neuroradiology***Moderator: G. Pellicanò; Florence/IT***A-457** 08:30**A. Management of the non-ruptured intracranial aneurysm**

T. Krings; Aachen/DE

*Learning Objectives:*

1. To learn about the incidence, clinical manifestations and imaging findings in patients with non-ruptured intracranial aneurysms.
2. To discuss the risk for rupture of incidentally found intracranial aneurysms.
3. To learn about reliable imaging predictors of aneurysm rupture.
4. To illustrate the most cost-effective decision strategy for the management of non-ruptured intracranial aneurysms.

**A-458** 09:00**B. Intracranial stenting**

I. Szikora; Budapest/HU

*Learning Objectives:*

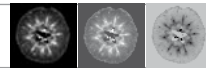
1. To discuss the specific technical requirements for intracranial stents.
2. To learn about the indication, technique, limitations and results of intracranial stenting in the treatment of intracranial aneurysms.
3. To learn about the indication, technique, limitations and results of intracranial stenting in the treatment of intracranial stenosis.

**A-459** 09:30**C. Intracranial thrombectomy**

R. Chapot; Essen/DE

*Learning Objectives:*

1. To learn about the imaging strategy for detecting intracranial thrombus.
2. To discuss the different types of devices for intracranial thrombectomy and compare their technical and clinical results.
3. To compare the results of intracranial thrombectomy with the results of intravenous and intra-arterial thrombolysis.



08:30 - 10:00

Room I

**Vascular**

**RC 1715**

**Imaging of critical limb ischemia**

*Moderator: M.-S. Grammenou-Pomoni; Athens/GR*

**A-460** 08:30

**A. Sonography: Just time consuming?**

R. Uberoi; Oxford/UK

*Learning Objectives:*

1. To understand US techniques in critical limb ischemia.
2. To demonstrate indications and results.
3. To demonstrate future developments.

**A-461** 09:00

**B. MRA: Tips to improve results**

J.F.M. Meaney; Dublin/IE

*Learning Objectives:*

1. To understand MRA techniques and protocols.
2. To understand the role of contrast agents.
3. To show clinical indications and results.

**A-462** 09:30

**C. MDCT: Just too many images?**

G.D. Rubin; Stanford, CA/US

*Learning Objectives:*

1. To understand CTA acquisition and contrast agent administration techniques and protocols.
2. To demonstrate the importance of image evaluation and post-processing techniques.
3. To show clinical indications and results.

08:30 - 10:00

Room K

**Pediatric**

**RC 1712**

**Trauma**

*Moderator: J.-F. Chateil; Bordeaux/FR*

**A-463** 08:30

**A. Abdominal trauma**

G. Staatz; Erlangen/DE

*Learning Objectives:*

1. To discuss the optimal imaging work-up of abdominal trauma in children.
2. To describe appropriate low-dose MDCT protocols in pediatric trauma patients.
3. To learn about typical injury patterns in blunt abdominal trauma.

TUESDAY

**A-464** 09:00**B. Renal trauma**J.-N. Dacher; *Rouen/FR**Learning Objectives:*

1. To describe imaging findings in cases of renal trauma.
2. To discuss the best management of patients with renal trauma.
3. To propose a flow chart.

**A-465** 09:30**C. The limping child**C.J. Kellenberger; *Zurich/CH**Learning Objectives:*

1. To review common causes for a limp in children and adolescents.
2. To discuss the indications, choice of modality and technique for imaging a child with a limp depending on the clinical presentation.
3. To propose a systematic diagnostic approach to the child presenting with an acute limp.

**08:30 - 10:00****Room L/M****Special Focus Session****SF 17c****The upcoming “geriatric tsunami” and its consequences to imaging services***Moderator: F. Laerum; Oslo/NO***A-466** 08:30**Chairman’s introduction**F. Laerum; *Oslo/NO**Session Objectives:*

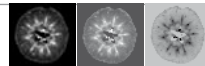
1. To learn about the changing demography and its consequences to the delivery of health care services.
2. To consolidate the knowledge of the disease panorama of the elderly population.
3. To understand the special ethics in treatment of the elderly.

**A-467** 08:35**Mobile, digital X-ray services for nursing homes**J.C. Hellund; *Oslo/NO**Learning Objectives:*

1. To appreciate the benefits of bedside X-ray examination in nursing homes.
2. To appreciate how image quality is preserved.
3. To learn about the organisation of a digital, mobile X-ray service.
4. To learn about possible savings due to improved patients logistics.

**A-468** 08:53**Imaging and the increasing incidence of cancer in geriatric populations**O. Ekberg; *Malmö/SE**Learning Objectives:*

1. To learn about the most common neoplasms in the elderly, and how their incidences are changing.
2. To understand the special considerations as to diagnosis and treatment in the vulnerable elderly with a suspected or diagnosed neoplasm.
3. To become familiar with predicted volumes and capacity problems in imaging of large numbers of elderly with cancer and how that affects the utilisation of the total health resources.



**A-469** 09:11

**Stroke**

J. Schenkel; Munich/DE

*Learning Objectives:*

1. To learn about the incidence and prevalence of stroke patients in the years to come.
2. To understand the importance of early diagnosis and treatment.
3. To learn how to organise highly competent stroke treatment reaching a larger part of the population.

**A-470** 09:29

**Dementia**

D.J. Brooks; London/UK

*Learning Objectives:*

1. To learn about the expected incidence and prevalence of dementia.
2. To understand the consequences to patient treatment of diagnosing dementia.
3. To appreciate new methods and approaches in diagnosing dementia in the ageing population, with special emphasis on imaging.

**Panel discussion:**

**The elderly population: Special radiological needs and demands** 09:47

---

**08:30 - 10:00**

**Room N/O**

**Special Focus Session**

**SF 17d**

**Undergraduate radiological education**

*Moderator: F. Kainberger; Vienna/AT*

**A-471** 08:30

**Chairman's introduction**

F. Kainberger; Vienna/AT

*Session Objectives:*

1. To become familiar with the key aspects of problem-based and integrated modern curricula and their relationship to evidence-based medicine.
2. To understand that integrated teaching is "more than the sum of all particles" and thus influences the daily practice of radiology with respect to communication, ethics and professionalism, anatomy, and statistics.
3. To learn about access to high quality e-learning resources suitable for being used in undergraduate teaching.

**A-472** 08:35

**Learning objectives and limitations**

F. Kainberger, A. Praschinger, S. Stieger, K. Kletter; Vienna/AT

*Learning Objectives:*

1. To become familiar with learning objectives as tools for steering and resource allocation in teaching.
2. To learn about refined techniques of diagnostic reasoning and transitional learning.
3. To understand case-based teaching with respect to other problem-oriented learning strategies.

**A-473** 08:58**Mentoring the enthusiastic student**M. Maas; *Amsterdam/NL**Learning Objectives:*

1. To learn about the important changes for radiology in undergraduate medical school.
2. To understand the opportunities that a mentoring programme provides.
3. To appreciate the importance of faculty dedication towards undergraduate medical school students.
4. To become familiar with possibilities how to get to know the medical student.

**A-474** 09:21**Analogue to digital learning tools**K. Verstraete; *Gent/BE**Learning Objectives:*

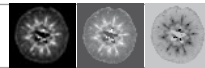
1. To become familiar with different types of analogue and digital undergraduate radiological education and their advantages and disadvantages.
2. To learn how to implement digital teaching in an undergraduate radiology curriculum.
3. To learn how to examine radiology in large groups of undergraduate students.

**Panel discussion:****What is the radiologist's role in a problem-based integrated curriculum?** 09:44**08:30 - 10:00****Room R1****Cardiac****RC 1703****CT vs MRI***Moderator: R. Maksimovic; Belgrade/RS***A-475** 08:30**A. Congenital heart disease**J. Glowacki; *Zabrze/PL**Learning Objectives:*

1. To show how MRI can be used to demonstrate cardiac anatomy and anatomical variants.
2. To show how CT can be used to demonstrate cardiac anatomy and normal variants.
3. To show which technique is better to use in various types of congenital heart disease depending on indications and different patient age groups.

**A-476** 09:00**B. Cardiomyopathies**J. Bremerich; *Basle/CH**Learning Objectives:*

1. To learn how to examine the heart with CT and MR in patients with cardiomyopathies.
2. To compare the advantages and disadvantages of both imaging modalities.
3. To understand the role of MRI and CT in differentiating various types of cardiomyopathy.



**A-477** 09:30

**C. Tumor and pericardial disease**

H. Scheffel; Zurich/CH

*Learning Objectives:*

1. To understand the advantages of CT imaging of the pericardium.
2. To learn how to use MRI to characterise pericardial masses.
3. To learn when to use CT and MRI and how to interpret the findings.

---

**08:30 - 10:00**

**Room R2**

**Breast: From Basics to Advanced Imaging**

**CC 1718**

**Advanced imaging**

*Moderator: L.S. Fournier; Paris/FR*

**A-478** 08:30

**A. PET imaging**

P. Rigo, M. Vergé, F. Fuerxer, M.-Y. Mourou; Monaco/MC

*Learning Objectives:*

1. To understand the basic PET imaging technology.
2. To describe the clinical validated indications of PET imaging for breast.
3. To learn about new radiotracers and potential new clinical applications.

**A-479** 09:00

**B. Optical imaging**

C. Bremer; Münster/DE

*Learning Objectives:*

1. To understand the basic optical imaging technologies.
2. To describe relevant optical tracers.
3. To give an overview of current status of clinical applications.
4. To highlight future developments relevant for clinical imaging.

**A-480** 09:30

**C. Functional imaging: MR spectroscopy and beyond**

T.H. Helbich; Toronto, ON/CA

*Learning Objectives:*

1. To understand the clinical interest for functional imaging.
2. To describe the different functional parameters found in breast cancers.
3. To present techniques available for functional imaging.
4. To provide potentials for new research opportunities and directions.

**08:30 - 10:00****Room R3****Interventional Radiology****RC 1709****Update on endovascular aortic interventions***Moderator: C.C. Basekim; Istanbul/TR***A-481** 08:30**A. Abdominal aortic aneurysm**

S. Müller-Hülsbeck; Kiel/DE

*Learning Objectives:*

1. To review the indications, techniques and complications of endovascular aneurysm repair.
2. To learn about the management of complications of endovascular aneurysm repair.
3. To review the evidence for endovascular aneurysm repair vs surgery.
4. To learn about new developments in endovascular aneurysm repair.

**A-482** 09:00**B. Thoracic aortic aneurysm**

G.J. Munneke; London/UK

*Learning Objectives:*

1. To review patient selection and preprocedural imaging for endovascular treatment.
2. To learn about the techniques of endovascular treatment and the management of complications.
3. To review the results of endovascular treatment.
4. To learn about new developments in endovascular aneurysm repair.

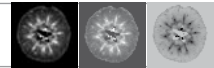
**A-483** 09:30**C. Aortic dissection**

F. Fanelli; Rome/IT

*Learning Objectives:*

1. To review patient selection and preprocedural imaging for endovascular treatment.
2. To learn about the techniques of endovascular treatment and the management of complications.
3. To review the results of endovascular treatment.
4. To learn about new developments in the treatment of aortic dissection.





10:30 - 12:00

Room E2

**E<sup>3</sup> - European Excellence in Education**

**E<sup>3</sup> 1820**

**BI-RADS™ - Olympics**

*Moderators: T.H. Helbich; Toronto, ON/CA, K. Kinkel; Chêne-Bougeries/CH*

**A-484** 10:30

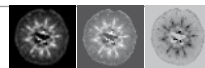
**BI-RADS™ - Olympics**

T.H. Helbich<sup>1</sup>, K. Kinkel<sup>2</sup>; <sup>1</sup>Toronto, ON/CA, <sup>2</sup>Chêne-Bougeries/CH

*Learning Objectives:*

1. To know more about BI-RADS™, particular about the breast imaging lexicon, the reporting system, and follow-up and outcome monitoring.
2. To know how to apply BI-RADS™ for mammography, ultrasound, and MR imaging.
3. To use BI-RADS™ in everyday practice and issue meaningful, unambiguous breast imaging reports.

**10:30 - 12:00****Room B****Musculoskeletal****SS 210****Peripheral nerves and muscle disorders***Moderators: R. Arkun; Izmir/TR, M. Baramia; Tbilisi/GE***B-001** 10:30**Phosphocreatine kinetics during incremental calf exercise in patient with diffuse atherosclerosis: A 31P MRS study***M.F.H. Schocke, R. Esterhammer, H. Messner, W.R. Jaschke, G. Fraedrich, A. Greiner; Innsbruck/AT***B-002** 10:39**Different patterns of involvement in myotilinopathy and desminopathy detected by a novel neuromuscular whole-body MRI protocol***N. Schramm, C. Born, S. Weckbach, P. Reilich, M.C. Walter, M.F. Reiser; Munich/DE***B-003** 10:48**Diffusion tensor imaging (DTI) and fiber tractography of skeletal muscle: Optimization of b-value for imaging at 1.5 Tesla***N. Saupe, L.M. White, J. Stainsby, G. Tomlinson, M.S. Sussman; Toronto, ON/CA***B-004** 10:57**Intracranial internal carotid artery calcifications: Association with vascular risk factors and cerebrovascular symptomatology***T.T. de Weert, H. Cakir, S. Rozie, S. Cretier, E. Meijering, D.W.J. Dippel, A. van der Lugt; Rotterdam/NL***B-005** 11:06**Chronic compartment syndrome of the forearm in motocross racers: Findings on MRI***J.L.M.A. Gielen<sup>1</sup>, B. Peersman<sup>1</sup>, G. Peersman<sup>2</sup>, P. Van Dyck<sup>1</sup>, F. Vanhoenacker<sup>1</sup>; <sup>1</sup>Edegem/BE, <sup>2</sup>Antwerp/BE***B-006** 11:15**Anatomy of vastus medialis obliquus: An MRI study***P.K.R. Merreddy, V. Roberts, S. Hakkalamani, P. Evans, N.J. Donnachie; Upton, Wirral/UK***B-007** 11:24**Meralgia paresthetica: Ultrasound findings and ultrasound guided therapy***G. Bodner, M. Bernathova, M. Felfernig, T. Boerger; Gibraltar/UK***B-008** 11:33**Value of an additional cross sectional area measurement of the median nerve in carpal tunnel syndrome patients compared to healthy volunteers: Assessment by ultrasound***T. De Zordo, D. Junker, G. Feuchtner, A. Mallouhi, M. Starzinger, A. Klauser; Innsbruck/AT***B-009** 11:42**Nerve ultrasound in acromegaly***A. Tagliafico, E. Resmini, R. Nizzo, F. Bianchi, D. Ferone, C. Martinoli; Genoa/IT***B-010** 11:51**Magnetic resonance imaging as a new method for monitoring nerve regeneration after median or ulnar nerve repair***A.R. Viddeleer<sup>1</sup>, P.E. Sijens<sup>1</sup>, P.M.A. van Ooijen<sup>1</sup>, S.E.R. Hovius<sup>2</sup>, M. Oudkerk<sup>1</sup>; <sup>1</sup>Groningen/NL, <sup>2</sup>Rotterdam/NL*



10:30 - 12:00

Room C

**GI Tract**

**SS 201b**

**Advances in abdominal imaging**

Moderators: E. Biscaldi; Genoa/IT, Y. Imai; Kanagawa/JP

**B-011** 10:30

**Significance of incidental focal FDG-uptake in the gastrointestinal tract: Correlation of PET/CT with endoscopic and histological findings**

P. Aschoff, T. Kratt, M.P. Lichy, M.Ö. Öksüz, C.D. Claussen, C. Pfannenber; *Tuebingen/DE*

**B-012** 10:39



**FDG uptake of GIST with the relatio to tumor size and mitosis**

T. Nakagawa, M. Yamada, T. Uno, Y. Suzuki, A. Yokota, K. Yoshida, I. Umehara, A. Toriihara; *Chiba/JP*

**B-013** 10:48

**Is further investigation justified for incidental unusual bowel uptake on PET-CT?**

H. Gupta, S. Olson; *Aberdeen/UK*

**B-014** 10:57



**Perfusion CT in the follow-up of patients with gastrointestinal stromal tumors under specific molecular pharmacotherapy**

F. Berger, M. Schlemmer, T. Saam, K. Nikolaou, C. Becker, M.F. Reiser; *Munich/DE*

**B-015** 11:06

**The role of DCE-MRI in the evaluation of response to angiogenesis inhibitors**

S. Bogaert<sup>1</sup>, P. Smeets<sup>1</sup>, J. Vercruyse<sup>1</sup>, P. Duyck<sup>1</sup>, P. Van Laer<sup>2</sup>; <sup>1</sup>*Gent/BE*, <sup>2</sup>*Brussels/BE*

**B-016** 11:15

**Diagnostic accuracy of 64-slice CT with isotropic multiplanar reconstructions (MPRs) in the pre-operative diagnosis of peritoneal carcinomatosis: Correlation with intraoperative and histopathologic findings**

M. Baski, D. Marin, C. Catalano, M. Di Martino, A. Guerrisi, G. De Filippis, S. Sibio, A. Di Giorgio, R. Passariello; *Rome/IT*

**B-017** 11:24

**Graded compression ultrasonography and computed tomography in acute colonic diverticulitis: A meta-analysis of test performance**

W. Laméris, A. van Randen, S. Bipat, P.M.M. Bossuyt, M.A. Boermeester, J. Stoker; *Amsterdam/NL*

**B-018** 11:33

**MSCT in arterial and portalvenous contrast phases for detection of intestinal bleeding**

M. Dobritz, A. Schneider, H.P. Engels, H. Wieder, E.J. Rummeny, J. Stollfuss; *Munich/DE*

**B-019** 11:42

**Minimal-preparation abdomino-pelvic CT in frail and elderly patients: Prognostic value of colonic and extracolonic findings**

C.S. Ng<sup>1</sup>, W. Wei<sup>1</sup>, T.C. Doyle<sup>2</sup>, H.M. Courtney<sup>3</sup>, A.K. Dixon<sup>4</sup>, A.H. Freeman<sup>4</sup>; <sup>1</sup>*Houston, TX/US*, <sup>2</sup>*Dunedin/NZ*, <sup>3</sup>*Bracknell/UK*, <sup>4</sup>*Cambridge/UK*

**B-020** 11:51

**Early detection of acute mesenteric ischemia with diffusion weighted MRI (DWI) using parallel imaging**

C.A. Schwartz<sup>1</sup>, P. Haage<sup>2</sup>, C. Ocklenburg<sup>1</sup>, G. Mühlenbruch<sup>1</sup>, G.A. Krombach<sup>1</sup>, T. Niendorf<sup>1</sup>, R.W. Günther<sup>1</sup>, C. Hohl<sup>1</sup>; <sup>1</sup>*Aachen/DE*, <sup>2</sup>*Wuppertal/DE*

**10:30 - 12:00****Room E1****Molecular Imaging****SS 206b****Preclinical studies***Moderators: I. Carrió; Barcelona/ES, F. Kiessling; Heidelberg/DE***B-021** 10:30**Targeted in vivo MRI of atherosclerosis with P947 and co-localization of fluorescent Europium-P947 with matrix metalloproteinases in atherosclerosis**

S. Amirbekian<sup>1</sup>, V. Amirbekian<sup>2</sup>, F. Hyafil<sup>3</sup>, E. Vucic<sup>3</sup>, J.S. Aguinaldo<sup>3</sup>, E. Lancelot<sup>4</sup>, C. Corot<sup>4</sup>, Z.A. Fayad<sup>3</sup>; <sup>1</sup>Atlanta, GA/US, <sup>2</sup>Boston, MA/US, <sup>3</sup>New York, NY/US, <sup>4</sup>Paris/FR

**B-022** 10:39**MRP-targeting in epidermal inflammation: A mouse-model**

M. Eisenblaetter; T.J. Vogl, A. Wall, W. Heindel, J. Roth, C. Bremer; Münster/DE

**B-023** 10:48**Diagnosis of granulation tissue after lumbar spine surgery with an ICG-enhanced integrated OI-/X-ray imaging system**

R. Meier<sup>1</sup>, S. Boddington<sup>1</sup>, C. Krug<sup>2</sup>, F.L. Acosta<sup>1</sup>, T.D. Henning<sup>1</sup>, S. Tavri<sup>1</sup>, E.J. Sutton<sup>3</sup>, E.J. Rummeny<sup>2</sup>, J.C. Lotz<sup>1</sup>, H.E. Daldrop-Link<sup>1</sup>; <sup>1</sup>San Francisco, CA/US, <sup>2</sup>Munich/DE, <sup>3</sup>Boston, MA/US

**B-024** 10:57**Utility of a herpes oncolytic virus for the detection and imaging of neural invasion by cancer**

P. Brader; Z. Gil, K. Kelly, J.P. Shah, Y. Fong, H. Hricak, R.G. Blasberg, R.J. Wong; New York, NY/US

**B-025** 11:06**Spatio-temporal control of the intra renal expression of a reporter gene, in vivo via a cellular vector: A feasibility study in rats**

O. Eker; F. Couillaud, B. Quesson, N. Frulio, J. Arsaut, C. Deminière, C.T. Moonen, N. Grenier; Bordeaux/FR

**B-026** 11:15**Detection of breast cancer with MR imaging using the folate-receptor targeted contrast agent P1133**

R. Meier<sup>1</sup>, T.D. Henning<sup>1</sup>, S. Tavri<sup>1</sup>, S. Arora<sup>1</sup>, E.J. Rummeny<sup>2</sup>, C. Corot<sup>3</sup>, H.E. Daldrop-Link<sup>1</sup>; <sup>1</sup>San Francisco, CA/US, <sup>2</sup>Munich/DE, <sup>3</sup>Paris/FR

**B-027** 11:24**1.5T and 7T in vivo magnetic resonance imaging of SP10-labeled pancreatic islets transplanted into streptozocin-induced mouse model of type-1-diabetes**

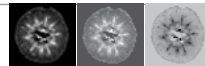
A. Esposito; F. De Cobelli, M.L. Malosio, A. Poletti, C. Losio, T. Canu, P. Maffi, A. Secchi, A. Del Maschio; Milan/IT

**B-028** 11:33**MRI assays for the evaluation of dimethyl sulfoxide (DMSO) effects on experimental human breast cancer vasculature**

C.C. Cyran; B. Sennino, B. Chaopathomkul, Y. Fu, V.S. Rogut, M.F. Wendland, D.M. Shames, D.M. McDonald, R.C. Brasch; San Francisco, CA/US

**B-029** 11:42**Monitoring E. coli Nissle 1917 colonization of tumors with PET and optical imaging**

P. Brader<sup>1</sup>, J. Stritzker<sup>2</sup>, C.C. Riedl<sup>1</sup>, J. Grimm<sup>1</sup>, A.A. Szalay<sup>2</sup>, Y. Fong<sup>1</sup>, R.G. Blasberg<sup>1</sup>, H. Hricak<sup>1</sup>; <sup>1</sup>New York, NY/US, <sup>2</sup>San Diego, CA/US



**B-030** 11:51

**Molecular profiling of tumor neovascularisation by multi-target molecular ultrasound imaging**

M. Palmowski<sup>1</sup>, J. Huppert<sup>1</sup>, G. Ladewig<sup>2</sup>, P. Hauff<sup>3</sup>, M. Reinhardt<sup>3</sup>, M.M. Mueller<sup>1</sup>, M. Maurer<sup>2</sup>, W. Semmler<sup>1</sup>, F. Kiessling<sup>1</sup>; <sup>1</sup>Heidelberg/DE, <sup>2</sup>Erlangen/DE, <sup>3</sup>Berlin/DE

**10:30 - 12:00**

**Room F1**

**Genitourinary**

**SS 207**

**The uterus**

*Moderators: E.J. Adam; London/UK, R. Girometti; Udine/IT*

**B-031** 10:30

**Dynamic MR-hysterosalpingography (dMR-HSG) replacing conventional X-ray HSG: First experience**

W. Pegios<sup>1</sup>, C. De Geyter<sup>1</sup>, S. Steimann<sup>1</sup>, J. Fröhlich<sup>2</sup>, W. Steinbrich<sup>1</sup>; <sup>1</sup>Basle/CH, <sup>2</sup>Zurich/CH

**B-032** 10:39

**Hysterosalpingogram, does the instrument used make a difference?**

W.R. Davis, S. Punwani, C. Allen; London/UK

**B-033** 10:48

**Contrast-enhanced ultrasound (CEUS) versus dynamic magnetic resonance (MR) in the assessment of outcomes and in the follow-up of uterine fibroids after superselective uterine fibroids embolization (SUFE)**

P. Gazzo<sup>1</sup>, F. Lacelli<sup>1</sup>, L.M. Sconfienza<sup>2</sup>, M. Gravano<sup>1</sup>, N.M. Gandolfo<sup>1</sup>, N. Perrone<sup>2</sup>, G. Serafini<sup>1</sup>; <sup>1</sup>Pietra Ligure/IT, <sup>2</sup>Genoa/IT

**B-034** 10:57

**Novel MRI techniques in advanced cervical cancer show early prediction of treatment outcome**

V.N. Harry, S.I.K. Semple, D.E. Parkin, F.J. Gilbert; Aberdeen/UK

**B-035** 11:06

**Diagnosis and evaluation of uterine cervical cancer using diffusion-weighted imaging**

Y. Ren, Q.Y. Guo, Z.M. Lu; Shenyang/CN

**B-036** 11:15

**Early stage endometrial carcinoma: Value of diffusion-weighted MR imaging in the assessment of myometrial tumor invasion**

F. Invernizzi, G. Rechicchi, A. Lissoni, P. Perego, D. Ippolito, C. Mangioni, S. Sironi; Monza/IT

**B-037** 11:24

**Differentiation between early endometrial carcinoma and endometrial hyperplasia using MR imaging: Emphasis on dynamic enhancement patterns and perfusion weighted images**

L. Xiang-Sheng, S. Yun-Long, Z. Wan-Shi, W. Dong; Beijing/CN

**B-038** 11:33

**Number of nodes and myometrial invasion better than tumor volume in predicting disease free survival in cervical cancer patients undergoing radiation therapy**

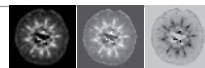
M.A. Haider, E. Maheshwari, A. Fyles, G. Lockwood, M. Milosevic; Toronto, ON/CA

**B-039** 11:42

**Lymph node involvement in uterine cervical cancer: A comparison between PET-CT and MRI with diffusion sequences**

P.-Y. Roudaut, M. Pouquet, J. Monteil, Y. Aubard, A.J.M. Maubon; Limoges/FR

**B-040** 11:51**Fusion of high b-value diffusion-weighted and T2-weighted MR images improves identification of lymph nodes in the pelvis**N. Mir, A. Sohaib, D. Collins, D.-M. Koh; *London/UK***10:30 - 12:00****Room F2****Breast****SS 202****Advances in digital mammography***Moderators: L. Khoo; London/UK, R.L. Lavayssiere; Sarcelles/FR***B-041** 10:30**Digital breast tomosynthesis versus mammography: Multireader study - first results**G. Gennaro, E. Baldan, E. Bezzon, M. La Grassa, L. Pescarini, C. di Maggio; *Padova/IT***B-042** 10:39**Performance of breast tomosynthesis as an adjunct imaging modality to digital mammography**A. Smith, L. Niklason, Z. Jing; *Bedford, MA/US***B-043** 10:48**HIGHREX, photon counting tomosynthesis: A new concept for X-ray imaging of the breast**M.G. Wallis<sup>1</sup>, C. Wright<sup>2</sup>, U. Bick<sup>3</sup>, M. Dalielsson<sup>4</sup>, F. Diekmann<sup>5</sup>, W. Heindel<sup>5</sup>, K. Leifland<sup>4</sup>, B. Seradour<sup>6</sup>, M. Aslund<sup>4</sup>; <sup>1</sup>*Cambridge/UK*, <sup>2</sup>*Birmingham/UK*, <sup>3</sup>*Berlin/DE*, <sup>4</sup>*Stockholm/SE*, <sup>5</sup>*Munster/DE*, <sup>6</sup>*Marseille/FR***B-044** 10:57**Digital mammographic tomosynthesis system: First clinical results**R. Schulz-Wendtland, E. Wenkel, L. Michael, B. Catrin, B. Werner, M. Thomas; *Erlangen/DE***B-045** 11:06**Challenges introduced by using telematics for soft copy 2nd reading of digital mammography images acquired in independent institutions**A. Van Steen, C. Van Ongeval, T. Deprez, E. Bellon, G. Marchal; *Leuven/BE***B-046** 11:15**Overlooked findings of computer-aided detection (CAD) applied to screening full-field digital mammograms previously obtained in women with breast cancer**N. Cho, W.K. Moon; *Seoul/KR***B-047** 11:24**Effect of introduction of digital mammography with CAD in a population based screening program**N. Karssemeijer<sup>1</sup>, D. Beijerinck<sup>2</sup>, R. Visser<sup>1</sup>, J. Deurenberg<sup>2</sup>, M. Beekman<sup>2</sup>, A. Bartels-Kortland<sup>2</sup>; <sup>1</sup>*Nijmegen/NL*, <sup>2</sup>*Utrecht/NL***B-048** 11:33**Electronic digital zooming vs geometric digital magnification of microcalcifications: A comparative study**E. Vianello, M. Lorenzon, V. Londero, A. Linda, B. Falcone, C. Zuiani, M. Bazzocchi; *Udine/IT***B-049** 11:42**A new generation algorithm for digital mammography designed to reproduce the performance of expert radiologists in detecting actionable clusters**P. Bamberger<sup>1</sup>, I. Leichter<sup>1</sup>, N. Merlet<sup>1</sup>, G. Fung<sup>2</sup>, R. Lederman<sup>1</sup>; <sup>1</sup>*Jerusalem/IL*, <sup>2</sup>*Malvern, PA/US*



**B-050** 11:51

**Monitor reading of lossy compressed digital mammograms**

R.W.R. Loose<sup>1</sup>, R. Simmler<sup>1</sup>, K. Detmar<sup>1</sup>, M. Wucherer<sup>1</sup>, R. Adamus<sup>1</sup>, A. Linke<sup>1</sup>, R. Schulz-Wendtland<sup>2</sup>; <sup>1</sup>Nuremberg/DE, <sup>2</sup>Erlangen/DE

**10:30 - 12:00**

**Room 6/H**

**Head and Neck**

**SS 208**

**Lesion detection and characterisation**

*Moderators: A. Borges; Lisbon/PT, V. Vandecaveye; Leuven/BE*

**B-051** 10:30

**Dynamic contrast-enhanced CT of head and neck tumors: Comparison of first-pass and permeability perfusion measurements using two different commercially available tracer kinetics models**

S. Bisdas<sup>1</sup>, M. Baghi<sup>1</sup>, J. Wagenblast<sup>1</sup>, T. Koh<sup>2</sup>, T.J. Vogl<sup>1</sup>, M.G. Mack<sup>1</sup>; <sup>1</sup>Frankfurt a. Main/DE, <sup>2</sup>Singapore/SG

**B-052** 10:39

**Diffusion-weighted echo-planar MRI: A valuable tool for differentiating primary parotid gland tumors?**

C.R. Habermann, P. Gossrau, C. Arndt, J. Graessner, F. Reitmeier, M. Jaehne, G. Adam; *Hamburg/DE*

**B-053** 10:48

**Tumour perfusion measured by dynamic multi slice detector computer tomography in head and neck cancer during and after combined radio- and chemotherapy**

F.M. Hinkmann<sup>1</sup>, M. Lell<sup>1</sup>, S. Lettmaier<sup>1</sup>, E. Klotz<sup>2</sup>, M. Geiger<sup>1</sup>, R. Sauer<sup>1</sup>, W. Bautz<sup>1</sup>; <sup>1</sup>Erlangen/DE, <sup>2</sup>Forchheim/DE

**B-054** 10:57

**Merkel cell carcinoma: Imaging findings of PET, sonography, CT, and MRI with clinicopathologic correlation in 16 patients**

P. Peloschek<sup>1</sup>, C. Novotny<sup>1</sup>, C. Mueller-Mang<sup>1</sup>, M. Weber<sup>1</sup>, J. Sailer<sup>1</sup>, C. Czerny<sup>1</sup>, R. Dudczak<sup>1</sup>, K. Kletter<sup>1</sup>, A. Becherer<sup>2</sup>; <sup>1</sup>Vienna/AT, <sup>2</sup>Feldkirch/AT

**B-055** 11:06

**Ultrafast MR-sialography: Comparison of two coil systems including a high resolution surface coil**

T.F. Weber<sup>1</sup>, M.C. Cramer<sup>2</sup>, D. Aldefeld<sup>2</sup>, F. Weiss<sup>2</sup>, G. Adam<sup>2</sup>, C.R. Habermann<sup>2</sup>; <sup>1</sup>Heidelberg/DE, <sup>2</sup>Hamburg/DE

**B-056** 11:15

**MRI of parotid lesions: Typical lesion characteristics in MR improve the discrimination between benign and malignant disease**

C. Waldherr, A. Christe, P. Zbaeren, H.C. Thoeny; *Berne/CH*

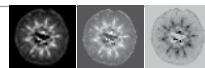
**B-057** 11:24

**Functional imaging of salivary glands using diffusion-weighted echo-planar MRI: Evaluation of different stimulation substances**

C.R. Habermann, T. Ries, J. Graessner, K. Nelting, J. Scheel, G. Adam; *Hamburg/DE*

**B-058** 11:33**MR-sialography at 1.5 and 3T: Quantification of salivary duct visualisation using an ultrafast imaging sequence**T.F. Weber<sup>1</sup>, M.C. Cramer<sup>2</sup>, D. Aldefeld<sup>2</sup>, F. Weiss<sup>2</sup>, G. Adam<sup>2</sup>, C.R. Habermann<sup>2</sup>; <sup>1</sup>Heidelberg/DE, <sup>2</sup>Hamburg/DE**B-059** 11:42**Prediction of malignancy in parotid tumor using diffusion weighted MR and dynamic contrast enhanced T2\*-weighted perfusion MR imaging**A.A.A. Abdel Razek, A. Kandeel, A. Motamed, N. Nada; *Mansoura/EG***B-060** 11:51**First-pass dynamic contrast-enhanced MR imaging of the squamous cell carcinoma in the upper aerodigestive tract: Initial results and comparison with first-pass dynamic contrast-enhanced CT imaging**S. Bisdas, L. Medov, M. Baghi, T. Koh, T.J. Vogl, M.G. Mack; *Frankfurt a. Main/DE***10:30 - 12:00****Room I****Vascular****SS 215****Carotid imaging***Moderators: R.A. Bucek; Vienna/AT, M.W. de Haan; Maastricht/NL***B-061** 10:30**Application of 64 multidetector-row CT angiography in the evaluation of carotid stenosis**Y.G. Gao, K.L. Li, X.D. Du, Y.S. Shen; *Beijing/CN***B-062** 10:39**Comparison between three different criteria for quantification of carotid stenosis by means of 64-slice multidetector CT: The role of the absolute area with respect to the percentage of vessel stenoses**G. Pontone, D. Andreini, A. Annoni, A. Formenti, E. Bertella, G. Ballerini, S. Galli, P. Ravagnani, M. Pepi, P. Montorsi; *Milan/IT***B-063** 10:48**ECG-gated dual source CT angiography (ECG-DSCTA) provides 4D-data to evaluate the distensibility of carotid arteries**S. Rozie, P.J. Homburg, M.L. Dijkshoorn, D.W.J. Dippel, A. van der Lugt; *Rotterdam/NL***B-064** 10:57**Utility of direct dual-energy hard plaque removal image using dual-source CT in quantification of calcified carotid artery stenosis: Correlation with digital subtraction angiography**K. Uotani<sup>1</sup>, Y. Watanabe<sup>1</sup>, T. Nakazawa<sup>1</sup>, M. Higashi<sup>1</sup>, Y. Hori<sup>1</sup>, T. Fukuda<sup>1</sup>, S. Kanzaki<sup>1</sup>, N. Yamada<sup>1</sup>, K. Otani<sup>2</sup>, T. Itoh<sup>2</sup>, K. Iihara<sup>1</sup>, H. Naito<sup>1</sup>; <sup>1</sup>Suita/JP, <sup>2</sup>Tokyo/JP**B-065** 11:06**Symptomatic carotid plaques have the same plaque volume and composition as the contra lateral asymptomatic carotid plaque: An analysis with MDCTA**S. Rozie, T.T. de Weert, P.J. Homburg, H.L.J. Tanghe, D.W.J. Dippel, A. van der Lugt; *Rotterdam/NL***B-066** 11:15**Carotid plaque ulceration assessed with multidetector computed tomography angiography**T.T. de Weert, S. Cretier, S. Rozie, H. Groen, J. Wentzel, D.W.J. Dippel, A. van der Lugt; *Rotterdam/NL*





**B-067** 11:24

**Increased carotid plaque echolucency predicts adverse cardiovascular events in high risk patients**

M. Reiter, I. Effenberger, R. Bucek, S. Puchner, M. Schillinger; *Vienna/AT*

**B-068** 11:33

**High resolution carotid black blood 3T MRI with parallel imaging: Initial experience**

T. Saam<sup>1</sup>, J.G. Raya<sup>1</sup>, K. Bochmann<sup>1</sup>, G. Meimarakis<sup>1</sup>, S. Sourbron<sup>1</sup>, U. Frey<sup>1</sup>, A. Werf<sup>2</sup>, H. Gerhards<sup>3</sup>, M.F. Reiser<sup>1</sup>, K. Nikolaou<sup>1</sup>; <sup>1</sup>Munich/DE, <sup>2</sup>TD Elde/AN, <sup>3</sup>Kerpen/DE

**B-069** 11:42

**Enhancement of the atherosclerotic plaque and the vessel wall of the carotid artery after injection of a blood pool agent**

S. Rozie, P.A. Wielopolski, M. Ouhlous, W. Niessen, T. van Walsum, A. van der Lugt; *Rotterdam/NL*

**B-070** 11:51

**Carotid plaque imaging: High-resolution MR imaging with 3-inch surface coil**

M. Li, Y. Zhu, F. Feng, H. You, L. Hu, Z. Jin; *Beijing/CN*

**10:30 - 12:00**

**Room K**

## Computer Applications

### SS 205

#### CAD and automated image analysis

*Moderators: D. Loeckx; Leuven/BE, R. Passariello; Rome/IT*

**B-071** 10:30

**Automated segmentation and volumetric, RECIST and WHO measurements of abdominal and pelvic lymph nodes in multi-slice CT**

V. Yaghmai<sup>1</sup>, M. Rezvani<sup>1</sup>, H. Soud<sup>2</sup>, R. Salem<sup>1</sup>, S. Berggruen<sup>1</sup>; <sup>1</sup>Chicago, IL/US, <sup>2</sup>Malvern, PA/US

**B-072** 10:39

**CT, PET and software-based-image-fusion: A comparison in patients with malignant lymphoma**

B. Henninger, E. Gunsilius, D. Kendler, C. Uprimny, I. Virgolini, W. Jaschke, R. Bale; *Innsbruck/AT*

**B-073** 10:48

**Software for analysis of tracheal lumen on cine-CT**

M. Ovsijewitsch, D. Simon, A. Mehndiratta, J. Ley-Zaporozhan, F.L. Giesel, H.-U. Kauczor, S. Ley; *Heidelberg/DE*

**B-074** 10:57

**Variability in repeated automatic measurements of left ventricular function on dual source computed tomography datasets using three different software packages**

G.J. de Jonge, P.M.A. van Ooijen, J.H. Kasemier, P.A. van der Vleuten, G.H. de Bock, M. Oudkerk; *Groningen/NL*

**B-075** 11:06

**Accuracy of individually adapted, interactive oblique multiplanar reconstructions vs. semiautomated coronary segmentation and rotated curved planar reformations for stenosis detection in coronary CT angiography**

K. Anders, S. Achenbach, A. Kuettner, U. Ropers, M. Wechsel, W.A. Bautz; *Erlangen/DE*

**B-076** 11:15

**Automated assessment of non-calcified atherosclerotic plaque burden at coronary CT angiography**

K.N. Blackmon, B. Ruzsics, J. Streck, C. Thilo, S.A. Nguyen, P. Costello, U.J. Schoepf; *Charleston, SC/US*

**B-077** 11:24**Computed tomographic quantification of coronary artery stenosis: Accuracy of different dedicated cardiac software packages**R. Dikkers<sup>1</sup>, H.A. Marquering<sup>2</sup>, H. Adams<sup>1</sup>, G.J. de Jonge<sup>1</sup>, P.M.A. van Ooijen<sup>1</sup>, T.P. Willems<sup>1</sup>, M. Oudkerk<sup>1</sup>; <sup>1</sup>Groningen/NL, <sup>2</sup>Leiden/NL**B-078** 11:33**Automatic detection of atherosclerotic carotid plaque from combined magnetic resonance angiography and vessel wall images**I. Isgum<sup>1</sup>, R. van t Klooster<sup>1</sup>, P.J.H. de Koning<sup>1</sup>, F. Jabi<sup>2</sup>, K. DeMarco<sup>2</sup>, J.H.C. Reiber<sup>1</sup>, R.J. van der Geest<sup>1</sup>; <sup>1</sup>Leiden/NL, <sup>2</sup>East Lansing, MI/US**B-079** 11:42**Semi-automatic measurement of left ventricular function on dual source computed tomography using four different software tools in comparison with magnetic resonance imaging**

G.J. de Jonge, P.A. van der Vleuten, D.D. Lubbers, H.J. van der Zaag-Loonen, P.M.A. van Ooijen, M. Oudkerk; Groningen/NL

**B-080** 11:51**Differentiation between normal and pathologic lung tissue in multi-detector-CT of patients with emphysema and lung-fibrosis using a novel texture metric based on the topology of CT-attenuation-values**H.F. Boehm<sup>1</sup>, C. Fink<sup>2</sup>, U. Attenberger<sup>1</sup>, C. Becker<sup>1</sup>, M.F. Reiser<sup>1</sup>; <sup>1</sup>Munich/DE, <sup>2</sup>Mannheim/DE**10:30 - 12:00****Room L/M****Neuro****SS 211****CT angiography and perfusion***Moderators: B. Lubicz; Brussels/BE, J. Walecki; Warsaw/PL***B-081** 10:30**Dual energy direct bone removal CT angiography for evaluation of intracranial aneurysm or stenosis: Comparison with conventional digital subtraction angiography**Y. Watanabe<sup>1</sup>, K. Uotani<sup>1</sup>, T. Nakazawa<sup>1</sup>, M. Higashi<sup>1</sup>, Y. Hori<sup>1</sup>, S. Kanzaki<sup>1</sup>, T. Fukuda<sup>1</sup>, N. Yamada<sup>1</sup>, T. Itoh<sup>2</sup>, K. Otani<sup>2</sup>, H. Naito<sup>1</sup>; <sup>1</sup>Suita/JP, <sup>2</sup>Tokyo/JP**B-082** 10:39**Comparison of two approaches for bone removal in intracranial CT angiography (CTA): Dual energy CT (DE-CT) and subtraction of a bone mask with "NeuroDSA"**

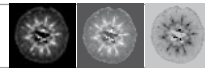
K. Papke, M. Pörner, D. Meila, F. Brassel; Duisburg/DE

**B-083** 10:48**Defining the shape of intracranial aneurysms with 16-row multidetector CT angiography (MDCTA): Comparison with 3D rotational angiography (3D-RA) in a phantom model**

K. Papke, F. Brassel; Duisburg/DE

**B-084** 10:57**The application of angiographic computed tomography in the peri-interventional cerebral diagnostic imaging**

M.-N. Psychogios, J.-H. Buhk, C. Sohns, A. Mohr, M. Knauth; Goettingen/DE



**B-085** 11:06

**Can dynamic CTA substitute for helical CTA of 64-row volume CT in diagnosing the stenosis of MCA in TIA patient?**

Y.G. Gao, L. Kuncheng, X.D. Du, Y.S. Shen; *Beijing/CN*

**B-086** 11:15

**Relation between vasospasm and cerebral perfusion after subarachnoid hemorrhage**

M. Rijdsdijk; *Utrecht/NL*

**B-087** 11:24

**Global and focal cerebral perfusion after aneurysmal subarachnoid haemorrhage in relation with delayed cerebral ischaemia**

M. Rijdsdijk; *Utrecht/NL*

**B-088** 11:33

**Comparative study of perfusion CT parameters to differentiate penumbra from infarct core in the acute stroke setting**

F.L.G. Borony, P.C. Seynaeve, H.H. Pottel, J.S. Meersschaert, E.E. Pattyn, S.S. Smet, P.M. Vanderdonckt, D.G. Peeters; *Kortrijk/BE*

**B-089** 11:42

**Changes in perfusion parameters of double CT perfusion studies as predictor of early mortality in ischemic stroke**

S. Langner, S. Stumpe, M. Kirsch, A.V. Khaw, N. Hosten; *Greifswald/DE*

**B-090** 11:51

**Cost-effectiveness of CT scanning in minor head injury: Selective strategies versus scanning all patients**

M. Smits<sup>1</sup>, D.W.J. Dippel<sup>1</sup>, D.A. van Rijssel<sup>1</sup>, H.M. Dekker<sup>2</sup>, P.E. Vos<sup>2</sup>, D.R. Kool<sup>2</sup>, P.J. Nederkoorn<sup>3</sup>, P.A.M. Hofman<sup>4</sup>, A. Twijnstra<sup>4</sup>, H.L.J. Tanghe<sup>1</sup>, M.M. Hunink<sup>1</sup>; <sup>1</sup>*Rotterdam/NL*, <sup>2</sup>*Nijmegen/NL*, <sup>3</sup>*Amsterdam/NL*, <sup>4</sup>*Maastricht/NL*

**10:30 - 12:00**

**Room N/O**

**Contrast Media**

**SS 206a**

**Side effects**

*Moderators: J. Grimm; New York, NY/US, S.K. Marcos; Sheffield/UK*

**B-091** 10:30

**Iodinated contrast media inhibit oxygen consumption in freshly isolated proximal tubular cells from humans and diabetic rats**

F. Palm, A. Fasching, P. Hansell, P. Liss; *Uppsala/SE*

**B-092** 10:39

**Proapoptotic and pronecrotic effects of iodinated contrast media on renal tubular cells following repeated and single exposure**

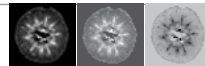
J.-M. Idée, K. Pallier, S. Ballet, P. Prigent, E. Lancelot, C. Corot; *Roissy/FR*

**B-093** 10:48

**A randomized, double-blind comparison of contrast-induced nephropathy in high-risk patients: The PREDICT study**

M.J. Kuhn<sup>1</sup>, N. Chen<sup>2</sup>, D. Sahani<sup>3</sup>, D. Reimer<sup>4</sup>, E.J.R. van Beek<sup>5</sup>, J.P. Heiken<sup>6</sup>, G.J. So<sup>7</sup>; <sup>1</sup>*Springfield, IL/US*, <sup>2</sup>*Shanghai/CN*, <sup>3</sup>*Boston, MA/US*, <sup>4</sup>*Mobile, AL/US*, <sup>5</sup>*Iowa City, IA/US*, <sup>6</sup>*St. Louis, MO/US*, <sup>7</sup>*Torrance, CA/US*

**B-094** 10:57**Preclinical studies to investigate the development of NSF: Experiments in renally impaired rats**H. Pietsch, J. Walter, P. Lengsfeld, T. Frenzel, J. Huetter, M.A. Sieber; *Berlin/DE***B-095** 11:06**Stability of gadolinium-based contrast agents in human serum**T. Frenzel; *Berlin/DE***B-096** 11:15**Long-term retention of gadolinium in the skin of rodents following the administration of gadolinium based contrast agents**M.A. Sieber, T. Frenzel, P. Lengsfeld, J. Hütter, H. Pietsch; *Berlin/DE***B-097** 11:24**A center case review of nephrogenic systemic fibrosis (NSF)**T.C. Lauenstein, K.N. Salman, R. Morreira, S. Tata, D.R. Martin; *Atlanta, GA/US***B-098** 11:33**Prevalence of nephrogenic systemic fibrosis in renal insufficiency patients: Results of the FINEST study**S. Karie<sup>1</sup>, N. Janus<sup>1</sup>, V. Launay-Vacher<sup>1</sup>, G. Choukroun<sup>2</sup>, C. Frances<sup>1</sup>, G. Deray<sup>1</sup>, D. Clément<sup>1</sup>; <sup>1</sup>*Paris/FR*, <sup>2</sup>*Amiens/FR***B-099** 11:42**Prevalence of NSF following administration of gadolinium-based contrast agents in patients with chronic renal failure**G. Heinz-Peer, A. Neruda, B. Watschinger, A. Vychytil, M. Haumer, A. Geusau, M. Weber; *Vienna/AT***B-100** 11:51**Survival of patients on renal replacement therapy diagnosed with nephrogenic systemic fibrosis compared to those without**G.H. Roditi, P. Thomson, T. Collidge, P. Mark; *Glasgow/UK***10:30 - 12:00****Room R1****Chest****SS 204****Advances in tumor imaging***Moderators: M. Boijesen; Gothenburg/SE, A. Dikonomou; Alexandroupolis/GR***B-101** 10:30**Compared efficacy for M-stage assessment between whole-body MR imaging and whole-body FDG-PET-CT in non-small cell lung cancer patients**Y. Ohno, H. Koyama, M. Nogami, D. Takenaka, Y. Onishi, K. Sugimura; *Kobe/JP***B-102** 10:39**Assessment of mediastinal lymphadenopathy with diffusion weighted MR imaging**A.A.A. Abdel Razek, A. Elmorsi, A. Elshafeai, T. Elhadedy, O. Hamza, N. Nada; *Mansoura/EG***B-103** 10:48**Characterization of mediastinal mass with diffusion weighted single shot echo planar MR imaging**A.A.A. Abdel Razek, A. Elmorsi, A. Elshafeai, T. Elhadedy, O. Hamza, N. Nada; *Mansoura/EG*



**B-104** 10:57

**Peripheral lung carcinoma: Correlation of angiogenesis and first-pass perfusion parameters of 64-detector row CT**  
Y. Li, Z.-G. Yang, T.-W. Chen, H.-J. Chen, J.-Y. Sun; *Chengdu/CN*

**B-105** 11:06

**BALI (BLAST Accelerated Lung Imaging) - Kt blast dynamic contrast enhanced multiphasic imaging of lung masses: A study of 22 cases**  
R.S.V. Vadapalli, J. Akkaraju, T. Mandapal; *Hyderabad/IN*

**B-106** 11:15

**Quantitative prediction of post-surgical recurrence in non-small cell lung cancer patients with integrated whole-body FDG-PET-CT**  
D. Takenaka, Y. Ohno, Y. Onishi, H. Koyama, M. Nogami, S. Matsumoto, M. Fujii, K. Sugimura; *Kobe/JP*

**B-107** 11:24

**Lung tumoral angiogenesis at dual-source CT: Technical approach with pathologic-CT correlations**  
N. Tacelli<sup>1</sup>, M. Rémy-Jardin<sup>1</sup>, A. Scherpereel<sup>1</sup>, E. Klotz<sup>2</sup>, M.-C. Copin<sup>1</sup>, J. Rémy<sup>1</sup>; <sup>1</sup>Lille/FR, <sup>2</sup>Forchheim/DE

**B-108** 11:33

**Quantitative assessment of perfusion of esophageal squamous cell carcinoma using 64-slice MDCT: Initial observation**  
Z.G. Yang, T.-W. Chen, Y. Li, Z.-J. Li, J. Yao, J.-Y. Sun; *Chengdu, Sichuan/CN*

**B-109** 11:42

**Quantitative CT perfusion measurements of solitary pulmonary nodules: Initial experience**  
M.A. Mazzei<sup>1</sup>, M. Scialpi<sup>2</sup>, M. Carcano<sup>3</sup>, M. Vincenti<sup>1</sup>, A. Mannini<sup>1</sup>, S.F. Carbone<sup>1</sup>, L. Volterrani<sup>1</sup>; <sup>1</sup>Siena/IT, <sup>2</sup>Perugia/IT, <sup>3</sup>Milan/IT

**B-110** 11:51

**First-pass CT perfusion imaging of solitary pulmonary nodules: Comparison of perfusion parameters of malignant and benign peripheral lung lesions**  
Y. Li, Z.-G. Yang, T.-W. Chen, J.-Q. Yu, Y.-K. Guo, Z.-L. Lin; *Chengdu/CN*

**10:30 - 12:00**

**Room R2**

**Cardiac**

**SS 203**

**Advances in cardiac CT**

*Moderators: G. Hadjidekov; Sofia/BG, C.S. White; Baltimore, MD/US*

**B-111** 10:30

**What are the realistic radiation risks to patients undergoing cardiac CT?**  
W. Huda, U.J. Schoepf, J.A. Abro, J.G. Ravenel, P. Costello, D.G. Frey; *Charleston, SC/US*

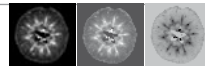
**B-112** 10:39

**Usefulness of dual source CT in preoperative evaluation of patients with aortic regurgitation**  
H.-J. Hwang, J.-W. Kang, J. Seo, E. Chae, Y. Jang, T. Lim; *Seoul/KR*

**B-113** 10:48

**Coronary CT angiography: Quantitative assessment of myocardial perfusion using test bolus data - Initial experience**  
A. Groves<sup>1</sup>, V.J. Goh<sup>2</sup>, S. Rajasekharan<sup>1</sup>, I. Kayani<sup>1</sup>, R. Endozo<sup>1</sup>, J. Dickson<sup>1</sup>, L. Menezes<sup>1</sup>, M. Shastri<sup>1</sup>, S. Habib<sup>3</sup>, P. Ell<sup>1</sup>, B. Hutton<sup>1</sup>; <sup>1</sup>London/UK, <sup>2</sup>Northwood/UK, <sup>3</sup>Nottingham/UK

**B-114** 10:57**Coronary MSCT angiography: Effect of experience and training on reader performance**F. Pugliese, K. Gruszczynska, M.G.M. Hunink, F. Alberghina, R. Malago<sup>1</sup>, N. Van Pelt, N.R. Mollet, P.J. de Feyter, G.P. Krestin; *Rotterdam/NL***B-115** 11:06**Non-invasive visualization of the coronary venous system using 64-slice spiral computed tomography and a comparison with conventional invasive angiography**Y. Hou<sup>1</sup>, Q.Y. Guo<sup>1</sup>, Y.X. Sun<sup>1</sup>, Y. Yue<sup>1</sup>, J.H. Chen<sup>2</sup>; <sup>1</sup>Shenyang/CN, <sup>2</sup>Beijing/CN**B-116** 11:15**Computerized patient-based dosing of contrast media delivery at dual-source CT coronary angiography**H. Lee<sup>1</sup>, P. Suranyi<sup>1</sup>, J.F. Kalafut<sup>2</sup>, C.A. Kemper<sup>2</sup>, J.A. Abro<sup>1</sup>, P.G. Kogos<sup>1</sup>, P. Costello<sup>1</sup>, U.J. Schoepf<sup>1</sup>; <sup>1</sup>Charleston, SC/US, <sup>2</sup>Pittsburgh, PA/US**B-117** 11:24**Comparison of X-ray radiation exposure during digital subtraction angiography (DSA) and multislice CT angiography (CTA)**B. Liu; *Beijing/CN***B-118** 11:33**Vessel wall hemodynamics and coronary artery plaque formation: Morphological analysis with coronary CT angiography**B. Enrico<sup>1</sup>, P. Suranyi<sup>1</sup>, C. Thilo<sup>1</sup>, L. Bonomo<sup>2</sup>, P. Costello<sup>1</sup>, U.J. Schoepf<sup>1</sup>; <sup>1</sup>Charleston, SC/US, <sup>2</sup>Rome/IT**B-119** 11:42**Cardiac-output based individualized contrast media injection protocol to minimize contrast volume at coronary dual-source CT angiography**P. Suranyi<sup>1</sup>, J.M. Kerl<sup>1</sup>, H. Lee<sup>1</sup>, J.F. Kalafut<sup>2</sup>, C.A. Kemper<sup>2</sup>, J.A. Abro<sup>1</sup>, G.E. Gilbert<sup>1</sup>, R.E. Carter<sup>1</sup>, P. Costello<sup>1</sup>, U.J. Schoepf<sup>1</sup>; <sup>1</sup>Charleston, SC/US, <sup>2</sup>Pittsburgh, PA/US**B-120** 11:51**Multi-detector CT coronary angiography: Sublingual nitroglycerine improves image quality significantly due to peripheral coronary vasodilatation**O. Klass, S. Mutlu, K. Hohl, S. Feuerlein, M. Jeltsch, H.J. Brambs, M.H.K. Hoffmann; *Ulm/DE***10:30 - 12:00****Room R3****Interventional Radiology****SS 209****Vascular interventions (1)***Moderators: B. Nemes; Budapest/HU, S. Soimakallio; Tampere/FI***B-121** 10:30**10-years follow-up of endovascular aneurysm treatment with talent stentgrafts**M.B. Pitton, T. Scheschkowski, S. Herber, R. Lachmann, A. Neufang, W. Schmiedt, C. Düber; *Mainz/DE***B-122** 10:39**Long-term follow-up after endovascular treatment of acute aortic emergencies**M.B. Pitton, W. Schmiedt, S. Herber, A. Neufang, B. Dorweiler, C. Düber; *Mainz/DE*



**B-123** 10:48

**Endovascular treatment of ruptured abdominal aortic aneurysm: 3-years experience**

G. Guzzardi, R. Fossaceca, P. Brustia, A. Carriero; *Novara/IT*

**B-124** 10:57

**Prospective, intraindividual comparison of MDCT and MRI for endoleak detection after endovascular repair of abdominal aortic aneurysms**

R. Wytttenbach, M. Oberson, A. Fogliata, M. Alerci; *Bellinzona/CH*

**B-125** 11:06

**Trans-caval endoleak embolization technique**

R. Gandini, L. Boi, T. Erdembileg, L. Di Vito, M. Di Primio, G. Angelopoulos, G. Simonetti; *Rome/IT*

**B-126** 11:15

**Vessel lumen diameter measurements and stenosis quantifications of the superficial femoral artery prior to interventional treatment: Comparison of angiography-based algorithms and visual estimation with measurements by intravascular ultrasound in vivo**

M. Treitel, J. Rieger, S. Wirth, M.F. Reiser; *Munich/DE*

**B-127** 11:24

**Endovascular treatment of critical limb ischemia in a diabetic population**

T. Zander, M. Rabellino, S. Baldi, M. Basaury, I. Zerolo, M. Maynar; *Santa Cruz de Tenerife/ES*

**B-128** 11:33

**Short-term intra-arterial administration of taxane for reduction of re-stenosis after PTA of femoropopliteal arteries: One year follow-up results of the THUNDER trial**

T. Albrecht<sup>1</sup>, G. Tepe<sup>2</sup>, T. Zeller<sup>3</sup>, S. Heller<sup>2</sup>, A. Oldenburg<sup>1</sup>, K.-J. Wolf<sup>1</sup>, C.D. Claussen<sup>2</sup>, U. Speck<sup>1</sup>;  
<sup>1</sup>Berlin/DE, <sup>2</sup>Tübingen/DE, <sup>3</sup>Bad Krozingen/DE

**B-129** 11:42

**Transfemoral and transtibial combined approach in treatment of obstructions extending on popliteal and distal vessels origin**

M. Stefanini, R. Gandini, V. Pipitone, L. Maresca, L. Di Vito, G. Simonetti; *Rome/IT*

**B-130** 11:51

**MR-guided angioplasty of peripheral arterial stenoses with a permeable balloon catheter with delivery of contrast-media doped solutions to the vessel wall and tracking of the distribution**

G.A. Krombach<sup>1</sup>, M. Wehner<sup>1</sup>, A. Perez-Bouza<sup>1</sup>, L. Kaimann<sup>1</sup>, S. Kinzel<sup>1</sup>, T. Plum<sup>1</sup>, M. Friebe<sup>2</sup>, R.W. Günther<sup>1</sup>, C. Hohl<sup>1</sup>; <sup>1</sup>Aachen/DE, <sup>2</sup>Castrop-Rauxel/DE

**14:00 - 15:30**

**Room B**

**Musculoskeletal**

**SS 310**

**Spine and shoulder**

*Moderators: M. Abd El Bagj; Riyadh/SA, A. Siemianowicz; Piekary Slaskie/PL*

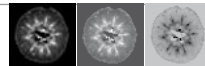
**B-131** 14:00

**To evaluate the application of DTI in cervical spondylosis with 3.0T MR**

X.S. Meng, J.W. Hou, C.F. Li, Y. Cui, J.H. Wei; *Jinan/CN*

**B-132** 14:09**Delayed gadolinium-enhanced magnetic resonance imaging (dGEMRIC) for the quantification of glycosaminoglycans depletion and regeneration in human intervertebral discs**S. Vaga, M.T. Raimondi, E.G. Caiani, F. Perona, M. Fornari; *Milan/IT***B-133** 14:18**Imaging the cervical spine in acute trauma: MRI vs CT**S.M. Shaikh; *Hyderabad/IN***B-134** 14:27**MR imaging in lumbar spinal stenosis: Prediction of surgical outcome**S. Hong, J. Lee, J.-S. Yeom, K. Park, J.-Y. Choi, N. Kim, H. Kang; *Seoul/KR***B-135** 14:36**Dural ectasia in Marfan syndrome**J. Desperramons, J.-P. Pelage, L. Gouya, A. Beauchet, S. Chagnon, P. Lacombe; *Boulogne/FR***B-136** 14:45**A potential clue in ultrasonographic diagnosis of adhesive capsulitis in shoulder joint: Limited subacromial gliding**J. Lee, I.-H. Jeon, C.-H. Kim; *Daegu/KR***B-137** 14:54**High resolution ultrasound (HRUS) in the calcifying tendonitis of the rotator cuff: Where does the calcium go in the resorptive phase?**L.M. Sconfienza<sup>1</sup>, F. Lacelli<sup>2</sup>, E. Silvestri<sup>1</sup>, G. Gartaschi<sup>1</sup>, C. Martinoli<sup>1</sup>, C. Murolo<sup>1</sup>, G. Serafini<sup>2</sup>; <sup>1</sup>Genoa/IT, <sup>2</sup>Pietra Ligure/IT**B-138** 15:03**Internal and external rotation combination on shoulder MR-arthrography in clinically suspected SLAP lesion**M.-T. Guedez<sup>1</sup>, E. Llopis<sup>2</sup>, E. Hernandez<sup>1</sup>, A. Cruz<sup>3</sup>, L. Cereza<sup>3</sup>; <sup>1</sup>Maracai/VE, <sup>2</sup>Valencia/ES, <sup>3</sup>Santander/ES**B-139** 15:12**Fast MR arthrography using VIBE sequences to evaluate the rotator cuff**J.E. Vandevenne<sup>1</sup>, J.M. Mahachie John<sup>2</sup>, G. Gelin<sup>1</sup>, P.M. Parizel<sup>3</sup>, F. Vanhoenacker<sup>4</sup>; <sup>1</sup>Genk/BE, <sup>2</sup>Hasselt/BE, <sup>3</sup>Antwerp/BE, <sup>4</sup>Duffel/BE**B-140** 15:21**Safety and tolerability of direct contrast-enhanced MR-arthrography: Assessment of infections and pain in 1083 patients**N. Saube<sup>1</sup>, M. Zanetti<sup>1</sup>, C.W.A. Pfirrmann<sup>1</sup>, T. Wels<sup>2</sup>, C. Schwenke<sup>3</sup>, J. Hodler<sup>1</sup>; <sup>1</sup>Zurich/CH, <sup>2</sup>Rotkreuz/CH, <sup>3</sup>Berlin/DE





**Abdominal Viscera (Solid Organs)**

**SS 301a**

**Challenges in hepatobiliary diseases**

*Moderators: J.S. Laméris; Amsterdam/NL, A. Lubienski; Lübeck/DE*

**B-141** 14:00

**Qualitative and quantitative comparison of 3.0T and 1.5T MRI for the liver with chronic liver disease**

M. Ramalhó, M. Tsurusaki, V. Heredia, E. Altun, R. Semelka; *Chapel Hill, NC/US*

**B-142** 14:09

**Non-alcoholic hepatosteatosis: Correlation of unenhanced CT and liver fat content**

P. Narayanan, F. Coyle, W. Drake, A. Rockall, R. Feakins, G.R. Foster, R. Reznick; *London/UK*

**B-143** 14:18

**CT laparoscopy for detecting small superficial metastases of the liver surface**

Y. Maetani, H. Isoda, Y. Hirokawa, S. Arizono, K. Shimada, K. Togashi; *Kyoto/JP*

**B-144** 14:27

**Intra-individual comparison of gadobenate dimeglumine (Gd-BOPTA) enhanced MR imaging and multiphase 64-slice CT for the detection of hepatocellular carcinoma (HCC) in patients with cirrhosis: Correlation with explanted liver**

M. Di Martino, D. Marin, C. Catalano, A. Guerri, M. Rossi, S.G. Corradini, R. Passariello; *Rome/IT*

**B-145** 14:36

**Automatic postprocessing of multi-breath hold 3D DCI MRI of the liver for precise anatomical alignment**

M.P. Lichy<sup>1</sup>, C. Plathow<sup>1</sup>, C. Chefdhotel<sup>2</sup>, D. Plathow<sup>1</sup>, W. Horger<sup>3</sup>, M. Horger<sup>1</sup>, P. Aschoff<sup>1</sup>, B. Kiefer<sup>3</sup>, C.D. Claussen<sup>1</sup>, H.-P. Schlemmer<sup>1</sup>; <sup>1</sup>Tübingen/DE, <sup>2</sup>Princeton, NJ/US, <sup>3</sup>Erlangen/DE

**B-146** 14:45

**MRI for quantification of hepatic steatosis with histopathologic correlation**

T. Chen<sup>1</sup>, R.-C. Chen<sup>1</sup>, C.-T. Chou<sup>2</sup>, J.-M. Chou<sup>1</sup>, C.-S. Li<sup>3</sup>, W.-T. Chen<sup>1</sup>, K.-C. Ding<sup>1</sup>; <sup>1</sup>Taipei/CN, <sup>2</sup>Changhua/CN

**B-147** 14:54

**Diagnostic performances of MDCT, SPIO-enhanced MRI, and double contrast MRI in predicting the appropriateness of a transplant recipient based on Milan criteria: Correlation with histopathologic findings**

D. Lee, S. Kim, J. Lee, H. Park, J. Lee, N.-J. Yi, K.-S. Suh, J. Jang, J. Han, B. Choi; *Seoul/KR*

**B-148** 15:03

**Hypochoic focal fatty infiltration in liver steatosis at US: Fast and definitive assessment with contrast enhanced ultrasound**

L. Tarantino<sup>1</sup>, I.F.M. Sordelli<sup>2</sup>, V. Nocera<sup>1</sup>, A. Schiano<sup>1</sup>, C. Ripa<sup>2</sup>; <sup>1</sup>Frattamaggiore/IT, <sup>2</sup>Naples/IT

**B-149** 15:12

**Color-doppler ultrasonography (CDU), multidetector computed tomography (MDCT) and endoscopic ultrasonography (EUS) in periampullary tumors: Evaluation of vascular involvement of major peripancreatic vessels**

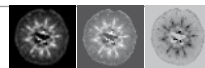
S. Gusmini, R. Nicoletti, C. Martinenghi, C. Soldati, C. Caborni, M. Salvioni, M. Venturini, S. Rocchetti, G. Balzano, A. Zerbi, P. Arcidiacono, V. Di Carlo, A. Del Maschio; *Milan/IT*

**B-150** 15:21

**Detection and determination of advanced hepatocellular carcinoma: Prospective comparison of MR imaging and PET/CT**

J. Baek, J. Lee, S. Kim, J. Lee, J. Han, B.-I. Choi; *Seoul/KR*

**14:00 - 15:30****Room F1****Genitourinary****SS 307****Imaging of the pelvis***Moderators: P. Aspelin; Stockholm/SE, A. Bianek-Bodzak; Gdansk/PL***B-151** 14:00**Magnetic resonance imaging (MRI) in the presurgery assessment of Mayer-Rokitansky-Kuster-Hauser (MRKH) syndrome***G. Pompili<sup>1</sup>, R. Meroni<sup>2</sup>, G. Franceschelli<sup>1</sup>, A. Munari<sup>1</sup>, G. Frontino<sup>1</sup>, G. Cornalba<sup>1</sup>, L. Fedele<sup>1</sup>; <sup>1</sup>Milan/IT, <sup>2</sup>Bergamo/IT***B-152** 14:09**HistoScanning: A new computer aided diagnostic tool for non invasive detection of malignant ovarian masses. A European clinical study report***O. Lucidarme<sup>1</sup>, J. Akakpo<sup>1</sup>, B. Lauratet<sup>1</sup>, S. Granberg<sup>2</sup>, M. Sideri<sup>3</sup>, R. Mashlach<sup>4</sup>, H. Bleiberg<sup>5</sup>, D. Nir<sup>5</sup>, P. Autier<sup>6</sup>, J. Lefranc<sup>1</sup>, P. Grenier<sup>1</sup>; <sup>1</sup>Paris/FR, <sup>2</sup>Stockholm/SE, <sup>3</sup>Milan/IT, <sup>4</sup>Tel Aviv/IL, <sup>5</sup>Waterloo/BE, <sup>6</sup>Lyon/FR***B-153** 14:18**Differential diagnosis of suspected ovarian cancer in pre-menopausal women***J.M. Hawnaur, A. Talwalkar; Manchester/UK***B-154** 14:27**Role of a computed tomography derived score (Plrad) for the prediction of optimal cytoreduction at primary surgery in patients with ovarian cancer***E. Cucci, G. Restaino, G. Garganese, G. Scambia, G. Sallustio; Campobasso/IT***B-155** 14:36**Value of MR imaging for the diagnosis of borderline ovarian tumors: Correlation with pathology***M. Bazot, D. Haouy, I. Thomassin-Naggara, A. Cortez, E. Daraï, C. Marsault; Paris/FR***B-156** 14:45**The tail sign: New sign for differentiation of hydrosalpinx from other adnexal cysts on three-dimensionally displayed MR imaging***A.E. Mahfouz, H. Sherif; Doha/QA***B-157** 14:54**Role of diffusion-weighted MR imaging in the assessment of lymphadenopathies in patients with pelvic disease***L. Ballesio, S. Savelli, M. Angeletti, M. Di Maurizio, A. Perrone, A. Francioso, L. Manganaro; Rome/IT***B-158** 15:03**Role of MR imaging and 3D sonography in the preoperative work out of deep infiltrating endometriosis***E. Faiella, R. Del Vescovo, C.C. Guattrocchi, V. Di Giacomo, R.F. Grasso, B. Beomonte Zobel; Rome/IT***B-159** 15:12**Testicular microlithiasis and macrocalcification: Prevalence of tumors and follow-up in a single center over 10 years***I. Amaechi, P. Sidhu; London/UK***B-160** 15:21**Role of 18F-FDG PET-CT in detection of recurrence of ovarian carcinoma with low tumor markers***S.M. Shaikh; Hyderabad/IN*



14:00 - 15:30

Room F2

**Breast**

**SS 302**

**Innovation in breast diagnosis**

Moderators: G. Rizzatto; Gorizia/IT, S. Weum; Tromsø/NO

**B-161** 14:00

**Six years of real time breast ultrasound elasticity imaging**

W.E. Svensson, N. Zaman, N.K. Barrett, G. Ralleigh, K. Satchithananda, S. Comitis, V. Gada, J. Dunn, C. Vajdi; London/UK

**B-162** 14:09

**Ultrasound elastography: Results of a European multicentric study of 429 breast lesions**

F. Schaefer<sup>1</sup>, A. Athanasiou<sup>2</sup>, I. Leconte<sup>3</sup>, R. Salvador<sup>4</sup>, S. Ganau Macias<sup>5</sup>, M. Wallis<sup>6</sup>, C. Plancher<sup>2</sup>, A.A. Tardivon<sup>2</sup>; <sup>1</sup>Kiel/DE, <sup>2</sup>Paris/FR, <sup>3</sup>Brussels/BE, <sup>4</sup>Barcelona/ES, <sup>5</sup>Sabadell/ES, <sup>6</sup>Cambridge/UK

**B-163** 14:18

**Quantitative assessment of breast lesions' visco-elasticity: Initial clinical experience using supersonic shear wave imaging**

A. Athanasiou<sup>1</sup>, A. Tardivon<sup>1</sup>, M. Tanter<sup>1</sup>, B. Sigal-Zafrani<sup>1</sup>, T. Deffieux<sup>1</sup>, J. Bercoff<sup>2</sup>, J.-L. Gennisson<sup>1</sup>, M. Fink<sup>1</sup>, S. Neuenschwander<sup>1</sup>; <sup>1</sup>Paris/FR, <sup>2</sup>Aix-en-Provence/FR

**B-164** 14:27

**Is sonoelastography helpful in BI-RADS III-IV (probably benign-probably malignant) lesions?**

N.M. Abdel Razeq, L. Ezzat, M. Shaalan; Cairo/EG

**B-165** 14:36

**Breast ultrasound elastography: Results of 193 breast lesions in a prospective study with histopathologic correlation**

F.K.W. Schaefer, S. Osterholz, B. Order, D. Fuerst, P.J. Schaefer, N. Hofheinz, J. Hedderich, W. Jonat, I. Schreer; Kiel/DE

**B-166** 14:45

**Ultrasound (US) elastography of breast lesions associated with mammographically detected suspicious microcalcifications**

J. Choi, N. Cho, W.K. Moon; Seoul/KR

**B-167** 14:54

**Computer-aided classification of breast masses detected at ultrasound according to ACR BI-RADS**

S.-Y. Kim<sup>1</sup>, R.-F. Chang<sup>2</sup>, W.-C. Shen<sup>3</sup>, W.K. Moon<sup>1</sup>; <sup>1</sup>Seoul/KR, <sup>2</sup>Taipei/CN, <sup>3</sup>Chiayi/CN

**B-168** 15:03

**Slip imaging: Reducing ambiguity in elasticity imaging of breast lesions**

R.F. Adams, M.J. Kadour, R.E. English, V. Parulekar, S. Christopher, J.A. Noble; Oxford/UK

**B-169** 15:12



**Initial evaluation of a semi-automated whole-breast ultrasound system in 6244 studies in 4369 asymptomatic women**

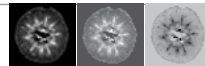
K.M. Kelly<sup>1</sup>, J.C. Dean<sup>2</sup>; <sup>1</sup>Venice, CA/US, <sup>2</sup>Santa Barbara, CA/US

**B-170** 15:21

**A dedicated CT scanner for breast imaging**

J.M. Boone, K. Yang, N. Packard, S.-Y. Huang, K.K. Lindfors, W. Monsky; Sacramento, CA/US

**14:00 - 15:30****Room G/H****Head and Neck****SS 308****Tumors: Metastases and imaging in therapy***Moderators: H.B. Eggesbø; Oslo/NO, P. Piñero; Sevilla/ES***B-171** 14:00**Level-based lymph node staging in head and neck cancer: Value of repeated CME-based training**C.R. [Habermann](#), F. Andree, A. Koops, M. Cramer, G. Adam, G. Krupski-Berdien; *Hamburg/DE***B-172** 14:09**Diffusion-weighted MRI for nodal staging in patients with head and neck squamous cell carcinoma: A comparison with conventional MRI in correlation to histopathology**V. [Vandecaveye](#), F. De Keyser, V. Vander Poorten, E. Verbeken, P. Dirix, S. Nuyts, R. Hermans; *Leuven/BE***B-173** 14:18**New MRI criteria improve the detection of lymph node metastases in head and neck squamous cell carcinoma: Multivariate logistic regression analysis of MRI features of cervical lymph nodes**R.B.J. [de Bondt](#), P.J. Nelemans, F. Bakers, C. Peutz-Kootstra, B. Kremer, P.A.M. Hofman, J.M.A. van Engelshoven, R.G.H. Beeets-Tan; *Maastricht/NL***B-174** 14:27**Malignant and reactive cervical lymph nodes in computed tomography perfusion (CTP) examination: Can we differentiate them?**A. [Trojanowska](#), A. Drop, P. Trojanowski, G. Staskiewicz, L. Grzycka-Kowalczyk, K. Rosinska-Bogusiewicz; *Lublin/PL***B-175** 14:36**Value of diffusion-weighted MR imaging in the differentiation between benign and malignant cervical lymph nodes**K. [Holzapfel](#), S. Duetsch, E.J. Rummeny, C. Fauser, J. Gaa; *Munich/DE***B-176** 14:45**Computed tomography perfusion (CTP) studies are useless in the determination of bone infiltration by malignant tumors: True or false?**A. [Trojanowska](#), A. Drop, P. Trojanowski, J. Klatka, K. Rosinska-Bogusiewicz; *Lublin/PL***B-177** 14:54**Comparison of F18-FDG PET/CT scan and bone scintigraphy in detecting bone metastasis in head and neck tumors**N. [Al-Bulushi](#)<sup>1</sup>, H. Almeer<sup>1</sup>, A. Alrifai<sup>1</sup>, A. Alsugair<sup>1</sup>, M. Abouzied<sup>2</sup>; <sup>1</sup>Riyadh/SA, <sup>2</sup>Buffalo, NY/US**B-178** 15:03**Accuracy of PETCT in diagnosis and exclusion of recurrent head and neck squamous cell carcinoma**A. [Nasoodi](#), R. De Freitas, C. Fahy, B. Primrose, S. Hughes; *Belfast/UK***B-179** 15:12**Tumor R2\* as a prognostic indicator of acute radiotherapeutic response in human cervical cancer**B. [Wu](#), W. Peng, Y. Gu; *Shanghai/CN***B-180** 15:21**Usefulness of magnetic resonance volumetric evaluation in predicting response to induction chemotherapy in patients with advanced head and neck cancers**M.G. [Mack](#), M. Baghi, R. Knecht, M. Hambek, S. Bisdas, T.J. Vogl; *Frankfurt a. Main/DE*



14:00 - 15:30

Room I

**Vascular**

**SS 315**

**CT angiography**

Moderators: L. Boyer; Clermont Ferrand/FR, J. Ferda; Plzen/CZ

**B-181** 14:00



**Comparison of different concentration of contrast medium for aortic enhancement**

D. Wu; Shanghai/CN

**B-182** 14:09

**Multi-detector CT angiography of the aorta: Do we benefit from high concentration iodine and bolus tracking?**

A.S. Ernst, P. Friedrich, M. Jeltsch, M.H.K. Hoffmann, H.-J. Brambs, A.J. Aschoff; Ulm/DE

**B-183** 14:18

**Determination of optimal scan delay for routine abdominal dual source CT with body weight adapted application of contrast material**

A. Tschugunow, K. Juergens, M. Puesken, W. Heindel, J. Wessling; Muenster/DE

**B-184** 14:27

**Peripheral multi-detector CT angiography (MDCTA): Influence of a compact bolus injection at high iodine concentration on arterial contrast enhancement and image quality**

T. Albrecht<sup>1</sup>, B. Meyer<sup>1</sup>, A.J. Aschoff<sup>2</sup>, J. Skrok<sup>1</sup>, T. Nentwig<sup>1</sup>, B.L. Schmitz<sup>2</sup>, K.-J. Wolf<sup>1</sup>, S. Klein<sup>2</sup>; <sup>1</sup>Berlin/DE, <sup>2</sup>Ulm/DE

**B-185** 14:36

**Identification of vulnerable plaque: A clinical, radiological and surgical study**

L. Saba, R. Sanfilippo, G. Caddeo, R. Montisci, G. Mallarini; Cagliari/IT

**B-186** 14:45

**Evaluation of symptomatic atherosclerotic carotid plaques: Relationship between MDCT-assessed plaque volume and brain infarcts**

P.J. Homburg, S. Rozie, T.T. de Weert, C. de Monyé, D.W.J. Dippel, A. van der Lugt; Rotterdam/NL

**B-187** 14:54

**Comparative study between 64 multi-detector row CT spinal angiography and DSA in diagnosing spinal cord vascular malformation**

Y.G. Gao, K.L. Li, X.D. Du, Y.Y. Yang, S. Shen; Beijing/CN

**B-188** 15:03

**The role of CT angiography in preoperative assessment of deep inferior epigastric perforator flaps in breast reconstruction**

A. Dimopoulou, R. Acosta, A. Liss, A. Magnusson; Uppsala/SE

**B-189** 15:12

**Active bleeding with MDCT: Can we say more?**

A. Alcala-Galiano, P. Diez, P. Martin, A. Hilario, E. Salvador, E. Garcia-Hidalgo, S. Borruel; Madrid/ES

**B-190** 15:21

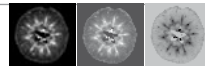
**Automatic bone and plaque subtraction in runoff-CTA using dual energy acquisition**

B.C. Meyer, T. Werncke, K.J. Wolf, T. Albrecht; Berlin/DE

**14:00 - 15:30****Room K****Computer Applications****SS 305****Image viewing and PACS**

Moderators: J. Fernandez-Bayó; Sabadell/ES, R.W.R. Loose; Nuremberg/DE

**B-191** 14:00**Open-source platform for remote teleradiology in mobile PET-CT unit**O. [Ratib](#), A. Rosset, J. Heuberger, J. Willi, M. Velazquez; Geneva/CH**B-192** 14:09**A research PACS system with extensible by end-users image processing and scientific visualization capabilities**K.P. [Karolemeas](#)<sup>1</sup>, T.G. Maris<sup>2</sup>, N. Gourtsoyannis<sup>2</sup>; <sup>1</sup>Athens/GR, <sup>2</sup>Iraklion/GR**B-193** 14:18**The value of grid technology in building regional and national medical image archives**J. [Crawford](#)<sup>1</sup>, S. Ohlsson<sup>2</sup>; <sup>1</sup>London/UK, <sup>2</sup>Stockholm/SE**B-194** 14:27**DICOM-CDs for communicating radiological images: Needs for a composite CD containing the radiological history of the patient improve user accessibility to data**A. [Nitrosi](#)<sup>1</sup>, F. Nicoli<sup>1</sup>, G. Borasi<sup>1</sup>, P. Pattacini<sup>1</sup>, A. Botti<sup>1</sup>, M. Bertolini<sup>1</sup>, S. Marzani<sup>1</sup>, G. Modigliani<sup>2</sup>; <sup>1</sup>Reggio Emilia/IT, <sup>2</sup>Cinisello Balsamo/IT**B-195** 14:36**Volume rendering and maximum-intensity projection techniques in sixteen-row multidetector computed tomography angiography. A comparative study**A. [Mishra](#), E.F. Ehtuish; Tripoli/LY**B-196** 14:45**Semi-manual quantitative right and left ventricular analysis: Comparison with automatic delineation**E.E.J.G. [Coche](#)<sup>1</sup>, M. Vembar<sup>2</sup>, M. Walker<sup>2</sup>, A. Vlassenbroek<sup>1</sup>; <sup>1</sup>Brussels/BE, <sup>2</sup>Cleveland, OH/US**B-197** 14:54**Semi-automatic multi planar reformatting of the coronary arteries from computed tomography angiography data**C.T. [Metz](#), M. Schaap, T. van Walsum, N.R.A. Mollet, W.J. Niessen; Rotterdam/NL**B-198** 15:03**3-way multimodality image registration for PET/CT and MRI fusion in clinical practice**J. Heuberger, A. Rosset, O. [Ratib](#); Geneva/CH**B-199** 15:12**OSIRIX: Open-source extension to PACS for multi-modality image analysis**A. Rosset, J. Heuberger, D. Bandon, O. [Ratib](#); Geneva/CH**B-200** 15:21**Development of a new resolution enhancement technology for medical liquid crystal displays**M. [Hasegawa](#)<sup>1</sup>, Y. Tanaka<sup>1</sup>, S. Hayashi<sup>1</sup>, Y. Nishi<sup>1</sup>, N. Kimura<sup>1</sup>, K. Ichikawa<sup>2</sup>; <sup>1</sup>Ueda/JP, <sup>2</sup>Kanazawa/JP



14:00 - 15:30

Room L/M

Neuro

SS 311a

**Advanced spinal MRI**

Moderators: M. Sasiadek; Wroclaw/PL, A. Urbanik; Krakow/PL

**B-202** 14:00

**32 directions DTI of cervical spinal cord in patients with multiple sclerosis**

M. Ukmar, E. Makuc, G. Garbin, X. Santarelli, A. Bratina, M.A. Cova; Trieste/IT

**B-203** 14:09

**Diffusion tensor imaging (DTI) in HIV-positive patients at 3.0 T MRI: Assessment of regional differences in the axial plane within normal-appearing cervical spinal cord**

C. Mueller-Mang<sup>1</sup>, T. Mang<sup>1</sup>, C. Plank<sup>1</sup>, A. Rieger<sup>1</sup>, E.-M. Law<sup>2</sup>, M.M. Thurnher<sup>1</sup>; <sup>1</sup>Vienna/AT, <sup>2</sup>New York, NY/US

**B-204** 14:18

**Spinal cord intramedullary tumor microstructure assesment using high B value diffusion tensor imaging and fiber tractography for characterization: A study of 22 cases**

R.S.V. Vadapalli<sup>1</sup>, V. N<sup>2</sup>, M. Naidu<sup>1</sup>, P. Ravuri<sup>1</sup>, R. Mangasree<sup>1</sup>; <sup>1</sup>Hyderabad/IN, <sup>2</sup>Bangalore/IN

**B-205** 14:27

**MR diffusion tensor imaging in evaluation of morphological changes of acute spinal cord injury in rats**

N. Chen; Beijing/CN

**B-206** 14:36

**Can MR diffusion tensor imaging predict the function recovery of spinal cord injured in vivo in the rat?**

N. Chen, L. Kuncheng; Beijing/CN

**B-207** 14:45

**MR diffusion tensor imaging and fiber tracking in acute spinal cord injury in humans**

N. Chen, L. Kuncheng; Beijing/CN

**B-208** 14:54

**The diagnostic value of three dimensional dynamic contrast-enhanced MR angiography in spinal vascular malformations**

Y. Yang, K. Li, Y. Liu, W. Shi, P. Yang, H. Zhang, X. Zhi; Beijing/CN

**B-209** 15:03

**3T MR neurography of sciatic nerve and lumbosacral plexus using DWIBS sequence in patients with spinal and extra spinal sciatica: A study of 41 patients**

R.S.V. Vadapalli, R. Mulukutla; Hyderabad/IN

**B-210** 15:12

**Upright MRI of disk herniation: Status and changes of its size under physiological loading**

M. Di Fabio, C. Bultrini, R. Masi, R. De Amicis, A. Splendiani, M. Gallucci; L'Aquila/IT

**14:00 - 15:30****Room N/O****Neuro****SS 311b****Brain tumors**

Moderators: P.C. Maly Sundgren; Ann Arbor, MI/US, T.A. Yousry; London/UK

**B-211** 14:00

**High-resolution contrast-enhanced, susceptibility-weighted MR imaging at 3T in patients with brain metastasis tumors: Correlation with histopathologic findings**

T. Gu; Beijing/CN

**B-212** 14:09

**MR/PET of the human brain: Feasibility of simultaneous imaging for scientific and clinical applications**

H.-P.W. Schlemmer<sup>1</sup>, B. Pichler<sup>1</sup>, D.W. Townsend<sup>2</sup>, C. Nahmias<sup>2</sup>, W.-D. Heiss<sup>3</sup>, C.D. Claussen<sup>1</sup>; <sup>1</sup>Tuebingen/DE, <sup>2</sup>Knoxville, TN/US, <sup>3</sup>Cologne/DE

**B-213** 14:18

**Perfusion weighted MRI in differential diagnosis between primary central nervous system lymphomas and high grade gliomas**

L. Rizzo<sup>1</sup>, S. Greco Crasto<sup>2</sup>, D. Sardo<sup>1</sup>, D. Gned<sup>1</sup>, D. Lanfranchini<sup>1</sup>, A. Veltri<sup>1</sup>, C. Fava<sup>1</sup>; <sup>1</sup>Orbassano/IT, <sup>2</sup>Turin/IT

**B-214** 14:27

**Multi-center comparison of cerebral blood volume and vascular permeability measurements with tumor volume measurements following anti-angiogenesis therapy with Avastin in human gliomas**

L. de Villiers, E.-M. Law, S. Chheang, J. Babb, N. Peccerelli, G. Fatterpekar, N. Leeds, M.V.V. Aragão, M. Fowkes, A. Narayana, R. Aiken, G. Johnson; New York, NY/US

**B-215** 14:36

**Biopsy targeting in gliomas: Which imaging technique should be used?**

M.-A. Weber<sup>1</sup>, M. Henze<sup>1</sup>, J. Tüttenberg<sup>2</sup>, B. Stieltjes<sup>1</sup>, S.E. Combs<sup>1</sup>, M. Vogt-Schaden<sup>1</sup>, H. Remme<sup>1</sup>, M. Meissner<sup>1</sup>, H.-U. Kauczow<sup>1</sup>, M. Essig<sup>1</sup>; <sup>1</sup>Heidelberg/DE, <sup>2</sup>Mannheim/DE

**B-216** 14:45

**SPECT/CT or SPECT/MR image fusion for the evaluation of primary or metastatic brain tumors and assessment of tumor grade**

V.S. Dekan, G. Trufanov, G. Romanov, V. Fokin, B. Martynov; St. Petersburg/RU

**B-217** 14:54

**Left frontal lobe tumors: What the neurosurgeon needs to know**

C.-V. Salvan, J.L. Ulmer, W.M. Mueller, D.L. Daniels, R.W. Prost; Milwaukee, WI/US

**B-218** 15:03

**Tumor volume estimation from MR images in patients with malignant glioma. Results from the American College of Radiology imaging network (ACRIN) 6662 trial**

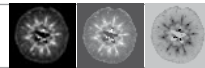
B. Ertl-Wagner<sup>1</sup>, J.D. Blume<sup>2</sup>, D. Peck<sup>3</sup>, J. Udupa<sup>4</sup>, I. Schmalpus<sup>5</sup>, B. Herman<sup>2</sup>, A. Levering<sup>4</sup>; <sup>1</sup>Munich/DE, <sup>2</sup>Providence, RI/US, <sup>3</sup>Detroit, MI/US, <sup>4</sup>Philadelphia, PA/US, <sup>5</sup>Gainesville, FL/US

**B-220** 15:12

**Neuroimaging of cerebral and facial involvement in Erdheim-Chester disease**

A. Vendrely, F. Bonneville, J. Savatovsky, J. Haroche, J.-C. Piette, D. Dormont, J. Chiras; Paris/FR





14:00 - 15:30

Room R1

Chest

SS 304

Screening/Pulmonary nodule

Moderators: G. Bastarrika; Pamplona/ES, J. Votrubová; Prague/CZ

**B-221** 14:00

Screening prior asbestos workers with low-dose computed tomography

H.C. Roberts<sup>1</sup>, D. Patsios<sup>1</sup>, H. Bayanati<sup>1</sup>, A. Pereira<sup>1</sup>, Z. Dong<sup>1</sup>, M. Johnston<sup>2</sup>; <sup>1</sup>Toronto, ON/CA, <sup>2</sup>Halifax, NS/CA

**B-222** 14:09

Early lung cancer detection using spiral computed tomography (CT) and fluorescence bronchoscopy

G. Serra-Tosio, L. Felix, C. Brambilla, J.-F. Timsit, M. Coulomb, G. Ferretti; Grenoble/FR

**B-223** 14:18

Localized ground-glass opacities in a CT screening for lung cancer

L. Felix, G. Serra-Tosio, S. Lantuejoul, C. Brambilla, J.-F. Timsit, M. Coulomb, G. Ferretti; Grenoble/FR

**B-224** 14:27

Natural course of pure ground-glass opacity nodules: 5-year follow-up

H. Kim, K. Lim, S. Lee, J. Lee, J. Zo, J. Lee; Goyang-si, Gyeonggi-do/KR

**B-225** 14:36

Persistent pure nodular ground-glass opacity in the lung: Comparison of malignancy and benignity

C. Park<sup>1</sup>, J. Goo<sup>1</sup>, H. Lee<sup>1</sup>, C. Lee<sup>1</sup>, K. Kim<sup>2</sup>, J.-G. Im<sup>1</sup>; <sup>1</sup>Seoul/KR, <sup>2</sup>Ilsan/KR

**B-226** 14:45

Increase in density is associated with malignancy in solid nodules detected at baseline screening of the Dutch-Belgian lung cancer screening trial (NELSON)

D. Xu<sup>1</sup>, R.J. van Klaveren<sup>2</sup>, G.H. de Bock<sup>1</sup>, A. Leusveld<sup>1</sup>, M.D. Dorrius<sup>1</sup>, Y. Zhao<sup>1</sup>, Y. Wang<sup>1</sup>, H.J. de Koning<sup>2</sup>, E.T. Scholten<sup>3</sup>, J. Verschakelen<sup>4</sup>, M. Prokop<sup>5</sup>, M. Oudkerk<sup>1</sup>; <sup>1</sup>Groningen/NL, <sup>2</sup>Rotterdam/NL, <sup>3</sup>Haarlem/NL, <sup>4</sup>Leuven/BE, <sup>5</sup>Utrecht/NL

**B-227** 14:54

The added value of consensus double reading in baseline phase of a lung cancer screening

Y. Wang<sup>1</sup>, R.J. van Klaveren<sup>2</sup>, H.J. van der Zaag-Loonen<sup>1</sup>, Y. Zhao<sup>1</sup>, A. Leusveld<sup>1</sup>, D. Xu<sup>1</sup>, H. de Koning<sup>2</sup>, E. Scholten<sup>3</sup>, J. Verschakelen<sup>4</sup>, M. Prokop<sup>5</sup>, M. Oudkerk<sup>1</sup>; <sup>1</sup>Groningen/NL, <sup>2</sup>Rotterdam/NL, <sup>3</sup>Haarlem/NL, <sup>4</sup>Leuven/BE, <sup>5</sup>Utrecht/NL

**B-228** 15:03

Clinical utility of a virtual non-enhanced image of a dual-energy CT in the evaluation of solitary pulmonary nodule: Initial experience

E. Chae<sup>1</sup>, J.-W. Song<sup>1</sup>, J. Seo<sup>1</sup>, B. Krauss<sup>2</sup>, K.-S. Song<sup>1</sup>; <sup>1</sup>Seoul/KR, <sup>2</sup>Forchheim/DE

**B-229** 15:12

Solitary pulmonary nodules: A meta-analysis of the diagnostic utility of alternative imaging tests

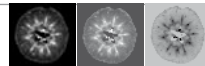
P. Cronin, B.A. Dwamena, A.M. Kelly, R.C. Carlos; Ann Arbor, MI/US

**B-230** 15:21

CT-guided percutaneous core biopsy of small (<1-cm) pulmonary nodules: Diagnostic accuracy and complication rate

M.C. Freund, C. Wolf, T. Schmid, M. Hackl, B. Zelger, W.R. Jaschke; Innsbruck/AT

**14:00 - 15:30****Room R2****Cardiac****SS 303****Advances in cardiac MR***Moderators: E. Di Cesare; L'Aquila/IT, C. Saraiva; Lisbon/PT***B-231** 14:00**Safety and efficacy of MR imaging at 1.5 T in patients with pacemakers and defibrillators***G.D.E. Papini, F. Secchi, A. Esseridou, P. Lupo, R. Cappato, S. Tiralongo, F. Sardanelli, G.P. Cornalba; Milan/IT***B-232** 14:09**MRI-related heating at 1.5 Tesla of a non-ferromagnetic catheter designed for interventional intracardial ablation of arrhythmia***A. Kooops, B. Lutomsky, M. Steinke, R. Karst, J. Graessner, S. Willems, G. Adam; Hamburg/DE***B-233** 14:18**Diagnostic accuracy of single breath-hold, contrast enhanced whole heart cine MRI using k-t BLAST in measuring LV volumes and function***S. Takase, H. Sakuma, K. Inoue, M. Nagata, Y. Mikami, N. Ishida, K. Takeda; Tsu, Mie/JP***B-234** 14:27**Apolipoprotein-E (ApoE) gadolinium nanoparticles for specific magnetic resonance imaging of atherosclerosis***V. Amirbekian<sup>1</sup>, S. Amirbekian<sup>2</sup>, E. Vucic<sup>3</sup>, K.C. Briley-Saebo<sup>3</sup>, J.S. Aguinaldo<sup>3</sup>, Z.A. Fayad<sup>3</sup>; <sup>1</sup>Boston, MA/US, <sup>2</sup>Atlanta, GA/US, <sup>3</sup>New York, NY/US***B-235** 14:36**Myocardial magnetic resonance stress perfusion imaging at 3T using a 1-molar contrast agent***B. Klumpp, C. Doesch, A. Seeger, J. Doering, T. Hoevelborn, U. Kramer, M. Fenchel, A. May, M. Gawaz, C. Claussen, S. Müller; Tübingen/DE***B-236** 14:45**Cardiac 31P-MRS compared to echocardiographic findings in patients with hypertensive heart disease without overt systolic dysfunction: Preliminary results***T. Burkhard, C. Herzog, S. Linzbach, I. Spyridopoulos, F. Huebner, T. Vogl; Frankfurt a. Main/DE***B-237** 14:54**Contrast-enhanced MRI in the acute phase after experimentally induced myocardial ischemia and reperfusion: Can it determine the area at risk?***K.-F. Kreitner, M. Vosseler, N. Abegunewardene, K.-H. Schmidt, N. Hoffmann, W.G. Schreiber, G. Horstick; Mainz/DE***B-238** 15:03**Multimodality MR imaging in detecting coronary microembolization: An animal experiment correlating with MR features and pathological findings***H. Jin, M.-S. Zeng; Shanghai/CN*



**B-239** 15:12

**Is delayed myocardial enhancement imaging in addition to MR-angiography useful in patients with peripheral artery disease? A longitudinal study of cardiac events**

A. Seeger, J. Doering, U. Kramer, F. Grimm, M. Fenchel, B. Klumpp, A.E. May, C.D. Claussen, S. Miller; *Tübingen/DE*

**B-240** 15:21

**Cardiac MRI at 7-Tesla: Initial experiments in pigs**

H.H. Quick, F. Breuckmann, K. Nassenstein, L. Schäfer, S. Maderwald, M.E. Ladd, J. Barkhausen; *Essen/DE*

**14:00 - 15:30**

**Room R3**

**Interventional Radiology**

**SS 309**

**Thoracic interventions**

*Moderators: B.V. Czermak; Innsbruck/AT, M. Köcher; Olomouc/CZ*

**B-241** 14:00

**Risk factors involved in the development of pneumothorax during radiofrequency ablation in lung neoplasms**

N.A.N. Mohammed, N.N.N. Naguib, M.G. Mack, T.J. Vogl; *Frankfurt a. Main/DE*

**B-242** 14:09

**Transpulmonary chemoembolization (TPCE) as a treatment for nonresectable lung metastases**

T.J. Vogl, K. Eichler, T. Lehnert, R. Hammerstingl, S. Lindemayr; *Frankfurt a. Main/DE*

**B-243** 14:18



**Circumferential ground glass opacification with a margin of at least 3 mm on CT predicts complete ablation in RFA of lung metastases**

E.M. Anderson, A.R. Gillams, W.R. Lees; *London/UK*

**B-244** 14:27

**Percutaneous cryoablation for normal lung of rabbits: Radiologic and pathologic correlation**

G.-Y. Jin, Y. Kim, Y. Han; *Jeon-ju/KR*

**B-245** 14:36

**Thermal ablation of the lung: In vivo experimental comparison of microwave and radiofrequency**

L. Crocetti, E. Bozzi, A. Sbrana, R. Lencioni, C. Bartolozzi; *Pisa/IT*

**B-246** 14:45

**Transpulmonary chemoembolization (TPCE) as a palliative treatment for non resectable primary tumors of the lung**

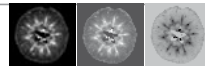
S.G. Lindemayr, T. Lehnert, K. Eichler, H. Korkusuz, R. Hammerstingl, S. Zangos, T.J. Vogl; *Frankfurt a. Main/DE*

**B-247** 14:54

**Role of 64-slice CT in pre-embolization evaluation of hemoptysis: Our initial experience**

S.S. Hedgine, P. Gupta, J. Sathenjeri Rajendra, V. Ilayaraja, T. Kalyanpur, M. Cherian, P. Mehta, R. Karwal; *Coimbatore/IN*

**B-248** 15:03**Bronchial artery embolisation, an effective procedure for treatment of massive hemoptysis in pulmonary tuberculosis**K. Taori, B.K. Saha; *Nagpur/IN***B-249** 15:12**Accuracy of CT-guided transthoracic needle biopsy (TNB) of lung lesions: Results of 828 consecutive procedures**A.M. Priola, S.M. Priola, A. Cataldi, G. Garofalo, P. Ricca, V. Marci, C. Fava; *Turin/IT***B-250** 15:21**Factors affecting risk of pneumothorax in CT-guided transthoracic needle biopsy (TNB) of lung lesions: Results of 892 consecutive procedures**A.M. Priola, S.M. Priola, A. Cataldi, G. Garofalo, F. Pazè, S. Durando, V. Marci, C. Fava; *Turin/IT*



**Musculoskeletal**

**SS 610**

**Hand, knee, feet**

*Moderators: B. Forgács; Rotherham/UK, C. Masciocchi; L'Aquila/IT*

**B-251** 10:30

**Cost-effectiveness of general practitioner direct access to magnetic resonance imaging for assessment of patients with suspected internal derangement of the knee: A randomised controlled trial**

S.D. Brealey, D. King; *York/UK*

**B-252** 10:39

**Which oblique plane is more helpful in diagnosing the anterior cruciate ligament tear?**

Y. Yoon, J. Kwon, I. Lee; *Seoul/KR*

**B-253** 10:48

**Osteochondrosis dissecans of the knee: The evolution of MR morphology during treatment**

P.D. Palczewski, P. Strzelczyk, M. Golebiowski; *Warsaw/PL*

**B-254** 10:57

**Iliotibial band friction syndrome in patients with medial compartment knee osteoarthritis**

V.J.N. Vasilevska<sup>1</sup>, U. Szeimies<sup>2</sup>, A. Staebler<sup>2</sup>; <sup>1</sup>Skopje/MK, <sup>2</sup>Munich/DE

**B-255** 11:06

**Contrast-enhanced MRI for the assessment of bone viability in scaphoid nonunion**

R.R. Schmitt, S. Fodor, S. Froehner, K. Megele, G. Christopoulos, H. Krimmer; *Bad Neustadt a.d. Saale/DE*

**B-256** 11:15

**Finger flexor annular pulley reconstruction: Assessment by US**

A. Klausner, R. Arora, P. Soegner, T. De Zordo, G. Feuchtner, M. Gabl; *Innsbruck/AT*

**B-257** 11:24

**Midcarpal instability: A diagnostic role for dynamic carpal ultrasound?**

A.P. Toms, A. Chojnowski, J. Cahir; *Norwich/UK*

**B-258** 11:33

**High field MR imaging at 7 T of ankles after marathon: Preliminary results**

P.C. Kokulinisky, O. Kraff, S. Maderwald, J.M. Theysohn, M.E. Ladd, J. Barkhausen, S.C. Ladd; *Essen/DE*

**B-259** 11:42

**Dynamic assessment of plantar plate: The role of high resolution ultrasound**

L.M. Sconfienza, F. Lacelli, V. Raimondi, G. Grillo, E. Silvestri, G. Garlaschi; *Genoa/IT*

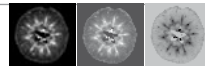
**B-260** 11:51

**The plantar fasciitis: A percutaneous ultrasound (US) guided approach to its treatment**

M. D'Auria, L.M. Sconfienza, D. Morcaldi, F. Paparo, E. Silvestri, G. Garlaschi; *Genoa/IT*

SATURDAY

**10:30 - 12:00****Room C****Abdominal Viscera (Solid Organs)****SS 601a****Functional imaging of the abdomen: Are we there yet?***Moderators: F. Arredondo; Guatemala City/GT, M.A. Müller; Zurich/CH***B-261** 10:30**Application of whole body diffusion weighted MR imaging for diagnosis and staging of malignant lymphoma***S. Li, H.D. Xue, F. Sun, Z.Y. Jin; Beijing/CN***B-262** 10:39**Diffusion weighted MR imaging in patients with chronic hepatitis: Grading and response to therapy***A.A.A. Abdel Razek, E. Omran, M. Elbendary, K. Zalata, M. Shady; Mansoura/EG***B-263** 10:48**Apparent restricted diffusion in cirrhotic liver likely reflects changes in perfusion***A. Furlan<sup>1</sup>, R. Girometti<sup>1</sup>, K.T. Bae<sup>2</sup>, C. Zuiani<sup>1</sup>, M. Bazzocchi<sup>1</sup>; <sup>1</sup>Udine/IT, <sup>2</sup>Pittsburgh, PA/US***B-264** 10:57**Detection of liver metastases: Diffusion-weighted respiratory triggered EPI versus dynamic gadolinium-enhanced MR imaging***M. Bruegel, K. Holzapfel, J. Gaa, K. Woertler, S. Waldt, C. Ganter, E.J. Rummeny; Munich/DE***B-265** 11:06**Respiratory-triggered echo-planar diffusion-weighted MR imaging for the differentiation between benign and malignant focal liver lesions with a diameter of up to 10 mm***K. Holzapfel, M. Eiber, M. Bruegel, E.J. Rummeny, J. Gaa; Munich/DE***B-266** 11:15**Diffusion-weighted echo-planar MRI in normal vs pathologic pancreas parenchyma: A promising additional tool for differentiation of pancreatic diseases***H. Hoff, K. Ullrich, I. Platzek, R. Grützmann, A. Engel, M. Laniado, C. Stroszczyński; Dresden/DE***B-267** 11:24**Magnetic resonance elastography: A new quantitative tissue characterization parameter for differentiating benign and malignant primary liver tumors***S.K. Venkatesh<sup>1</sup>, M. Yin<sup>2</sup>, N. Takahashi<sup>2</sup>, J.F. Glockner<sup>2</sup>, J.A. Talwalkar<sup>2</sup>, P.A. Araoz<sup>2</sup>, R.L. Ehman<sup>2</sup>; <sup>1</sup>Singapore/SG, <sup>2</sup>Rochester, MN/US***B-268** 11:33**MR elastography of liver fibrosis: Comparison of spin-echo and echo-planar imaging***L. Huwart<sup>1</sup>, N. Salameh<sup>1</sup>, L. ter Beek<sup>2</sup>, E. Vicaut<sup>3</sup>, R. Sinkus<sup>3</sup>, B. Van Beers<sup>1</sup>; <sup>1</sup>Brussels/BE, <sup>2</sup>Best/NL, <sup>3</sup>Paris/FR***B-269** 11:42**Enhancement patterns at contrast-enhanced ultrasonography (CEUS) as a prognostic factor for resectable ductal adenocarcinoma of the pancreas***M. D'Onofrio, R. Malagó, T. Gubello, G. Zamboni, N. Faccioli, F. Principe, R. Pozzi Mucelli; Verona/IT***B-270** 11:51**Whole-body FDG-PET/CT with integrated CT-perfusion for liver metastases evaluation. Initial results on technical feasibility***P. Veit-Haibach, V. Treyer, J. Soyka, K. Strobel, M. Pérez Lago, K. Mende, T.F. Hany; Zurich/CH*



**Interventional Radiology**

**SS 609a**

**Spine**

Moderators: D. Bilecen; Basle/CH, A. Dimopoulou; Uppsala/SE

**B-271** 10:30

**Technical results, extraosseous cement leakages, and complications in 500 vertebroplasty procedures**

M.B. Pitton, S. Herber, C. Ahlers, B. Röhl, P. Drees, B. Böhm, K. Oberholzer, C. Düber; Mainz/DE

**B-272** 10:39

**Symptomatic vertebra plana: A primary indication to vertebroplasty**

A. Pedicelli, M. Rollo, R. Polito, M. Piano, C. Colosimo, L. Bonomo; Rome/IT



**B-273** 10:48

**Two years follow-up after percutaneous vertebroplasty of osteoporotic vertebral fractures: Height gain of vertebral bodies and stabilization of vertebral geometry**

U. Koch, N. Morgen, S. Herber, P. Drees, J. Heine, C. Düber, M.B. Pitton; Mainz/DE

**B-274** 10:57

**Incidence of symptomatic vertebral fractures in patients after percutaneous vertebroplasty**

J. Hierholzer, K. Westphalen, H. Fuchs, C. Baumann; Potsdam/DE

**B-275** 11:06

**Vertebroplasty and kyphoplasty of vertebral compression fractures: Height gain of vertebral bodies during one year following PMMA cement augmentation**

B. Röhl, N. Morgen, S. Herber, M. Sadick, C. Düber, M.B. Pitton; Mainz/DE

**B-276** 11:15

**Multiple level vertebroplasty: Feasibility, safety and efficacy**

G.C. Anselmetti<sup>1</sup>, P. Carpeggiani<sup>2</sup>, A. Manca<sup>1</sup>, G. Chiara<sup>1</sup>, D. Regge<sup>1</sup>; <sup>1</sup>Candiolo/IT, <sup>2</sup>Pisa/IT

**B-277** 11:24

**Percutaneous vertebroplasty (PVP) for osteolytic breast cancer metastases: Cement leaks in 59 procedures**

C.G. Trumm, T.F. Jakobs, C. Glaser, M.F. Reiser, R.-T. Hoffmann; Munich/DE

**B-278** 11:33

**Percutaneous management of aggressive vertebral haemangiomas: A series of 32 cases**

A. Gangi, X. Buy, T. Moser, J.-L. Dietemann; Strasbourg/FR

**B-279** 11:42

**Percutaneous nucleoplasty: Our experience in 215 patients**

S. Marcia, S. Marini, U. Codella, G. Mallarini; Cagliari/IT

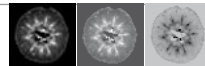
**B-280** 11:51

**Quantitative approach for diagnosis of cystic lesions of pancreas: Diffusion-weighted MRI and 1H MRS study**

Z.Z. Rozhkova, J.Z. Lifshits, E.O. Ipatova, V.A. Sychov; Kiev/UA

**10:30 - 12:00****Room F2****Breast****SS 602****Intervention***Moderators: P. Petrow; Paris/FR, M. Sentis; Sabadell/ES***B-281** 10:30**Non-operative diagnosis in the UK national health service breast screening programme (NHSBSP) and impact on number of operations: An historical perspective**M.G. Wallis<sup>1</sup>, D. Kearins<sup>2</sup>, S. Cheng<sup>2</sup>, G. Lawrence<sup>2</sup>; <sup>1</sup>Cambridge/UK, <sup>2</sup>Birmingham/UK**B-282** 10:39**Breast cancer screening in The Netherlands: Trends in utilization and cost of diagnostic imaging and biopsies following positive screening mammography**L.E.M. Duijm<sup>1</sup>, J.H. Groenewoud<sup>2</sup>, J. Fracheboud<sup>2</sup>, M.L. Plaisier<sup>3</sup>, R.M.H. Roumen<sup>3</sup>, M. van Beek<sup>1</sup>, T.F. Le Maire<sup>1</sup>, H.J. de Koning<sup>2</sup>; <sup>1</sup>Eindhoven/NL, <sup>2</sup>Rotterdam/NL, <sup>3</sup>Veldhoven/NL**B-283** 10:48**Preoperative axillary ultrasound (US) and US-guided needle localization in the patients with breast cancer undergoing sentinel lymph node biopsy (SLNB)**W.K. Moon, N. Cho; *Seoul/KR***B-284** 10:57**Prospective randomized comparison of intratumoral versus peritumoral injection of radiocolloid for sentinel node identification and biopsy in non-palpable breast cancer**A. Pérez de Tudela, A. Mariscal, S. Vizcaya, J. Julián, M. Solà, L. Catro; *Badalona/ES***B-285** 11:06**Ultrasound (US)-guided vacuum-assisted removal of intraductal single mass in patient with pathologic nipple discharge: Is it an alternative to open surgery?**J. Chang, W.K. Moon, N. Cho; *Seoul/KR***B-286** 11:15**Vacuum-assisted breast biopsy of non-mass calcifications: How many calcifications are necessary for diagnosis?**S.-H. Mun, G.-W. Park, E.-Y. Ko, J.-H. Shin, S.-J. Kim, B.-K. Han; *Seoul/KR***B-287** 11:24**Lobular neoplasia: Malignancy underestimation rate of core-needle breast biopsy in relation to radiologic and pathologic features**V. Londero, A. Linda, C. Zuiani, E. Vianello, M. Bazzocchi; *Udine/IT***B-288** 11:33**MR-guided stereotactic breast biopsy using a low-cost mixed ferromagnetic-nonmagnetic coaxial system with small caliber needles (16-18 gauge): Feasibility, efficacy and safety**E. Belloni, P. Panizza, F. De Cobelli, S. Gusmini, I. Fedele, I. Sassi, C. Losio, N. Verardi, A. Del Maschio; *Milan/IT*





**B-289** 11:42

**3.0-T MRI-guided focused ultrasound ablation versus MRI-guided needle-wire placement for the pre-operative localization of non-palpable breast tumors**

A.C. Schmitz<sup>1</sup>, M.A.A.J. van den Bosch<sup>1</sup>, V. Rieke<sup>1</sup>, F.M. Dirbas<sup>1</sup>, K. Butts Pauly<sup>1</sup>, W.P.T.M. Mali<sup>2</sup>, B.L. Daniel<sup>1</sup>; <sup>1</sup>Stanford, CA/US, <sup>2</sup>Utrecht/NL

**B-290** 11:51

**Interdisciplinary consensus on the uses and technique of MR-guided vacuum assisted breast biopsy (VAB): Results of a European consensus meeting**

S.H. Heywang-Köbrunner<sup>1</sup>, R. Sinnantaby<sup>2</sup>, A. Lebeau<sup>3</sup>, A. Lebrecht<sup>4</sup>, P.B. Britton<sup>2</sup>, I. Schreer<sup>5</sup>; <sup>1</sup>Munich/DE, <sup>2</sup>Cambridge/UK, <sup>3</sup>Hamburg/DE, <sup>4</sup>Mainz/DE, <sup>5</sup>Kiel/DE

**10:30 - 12:00**

**Room I**

**Physics in Radiology**

**SS 613**

**Radiation dose in CT**

*Moderators: N. Marshall; London/UK, P. Vock; Berne/CH*

**B-291** 10:30

**Z over-scan dose reduction in cone-beam CT scanners**

S. Glasberg, G. Shechter; Haifa/IL

**B-292** 10:39

**Practice in multi-slice computed tomography: How do we perform?**

S.J. Golding<sup>1</sup>, Y.L. O<sup>2</sup>, C. Alvey<sup>1</sup>, E. Benjamins<sup>2</sup>, K. Chlapoutakis<sup>3</sup>, E. Fraile Moreno<sup>4</sup>, J. Hansen<sup>5</sup>, S. Meeson<sup>1</sup>, A. Meijer<sup>2</sup>, T. Niemann<sup>6</sup>, R. Patel<sup>1</sup>, L. Ruiz Lopez<sup>4</sup>, I. Salmeron<sup>4</sup>, N. Theocharopoulos<sup>3</sup>, G. Bongartz<sup>6</sup>, A. Calzado<sup>4</sup>, J. Damilakis<sup>3</sup>, J. Geleijns<sup>2</sup>, A. Jurik<sup>5</sup>, V. Alonso Ferreira<sup>4</sup>, C. Cordeiro Alves<sup>4</sup>; <sup>1</sup>Oxford/UK, <sup>2</sup>Leiden/NL, <sup>3</sup>Iraklion/GR, <sup>4</sup>Madrid/ES, <sup>5</sup>Aarhus/DK, <sup>6</sup>Basle/CH

**B-293** 10:48

**A novel robust and dose efficient tube current modulation for ECG-gated cardiac spiral CT imaging**

R. Raupach<sup>1</sup>, H. Bruder<sup>1</sup>, C. Becker<sup>2</sup>, B. Schmidt<sup>1</sup>, T.G. Flohr<sup>1</sup>; <sup>1</sup>Forchheim/DE, <sup>2</sup>Munich/DE

**B-294** 10:57

**Establishment of a biological phantom model for dose estimation in cardiac CT**

M.A. Kuefner<sup>1</sup>, K. Anders<sup>1</sup>, J. Hamann<sup>1</sup>, S.A. Schwab<sup>1</sup>, S. Achenbach<sup>1</sup>, W. Bautz<sup>1</sup>, M. Lobrich<sup>2</sup>, M. Uder<sup>1</sup>; <sup>1</sup>Erlangen/DE, <sup>2</sup>Homburg a.d. Saar/DE

**B-295** 11:06



**Monte Carlo simulation to assess organ radiation dose from coronary CT angiography (CTA) exams using patient-based voxelized models**

E. Angel<sup>1</sup>, N. Yaghmai<sup>1</sup>, J.J. DeMarco<sup>1</sup>, C.H. Cagnon<sup>1</sup>, J.G. Goldin<sup>1</sup>, A.N. Primak<sup>2</sup>, D.M. Stevens<sup>3</sup>, D.D. Cody<sup>3</sup>, C.H. McCollough<sup>2</sup>, M.F. McNitt-Gray<sup>1</sup>; <sup>1</sup>Los Angeles, CA/US, <sup>2</sup>Rochester, MN/US, <sup>3</sup>Houston, TX/US

**B-296** 11:15

**Optimized tube current selection for consistent image quality and dose reduction in MDCT cardiac imaging**

W. Qi, X. Du, J. Li, Y. Shen; Beijing/CN

**SATURDAY**

**B-297** 11:24**Novel tube current modulation algorithms for reducing radiation dose to breasts in thoracic CT**

E. Angel<sup>1</sup>, F. Noo<sup>2</sup>, J.J. DeMarco<sup>1</sup>, C.H. Cagnon<sup>1</sup>, N. Yaghmai<sup>1</sup>, J.G. Goldin<sup>1</sup>, M.F. McNitt-Gray<sup>1</sup>;  
<sup>1</sup>Los Angeles, CA/US, <sup>2</sup>Salt Lake City, UT/US

**B-298** 11:33**Measurements of CT dose profiles with a new liquid ionization chamber**

O. Langner<sup>1</sup>, R. Kranzer<sup>2</sup>, Y. Kyriakou<sup>1</sup>, W.A. Kalender<sup>1</sup>; <sup>1</sup>Erlangen/DE, <sup>2</sup>Freiburg/DE

**B-299** 11:42**Dose assessment for a multicenter study on diagnostic performance of cardiac 64-slice CT**

J. Geleijns<sup>1</sup>, A. Calzado<sup>2</sup>, M. Dewey<sup>3</sup>, R.M.S. Joemai<sup>1</sup>, R. Mather<sup>4</sup>, A. de Roos<sup>1</sup>, M. Salvado<sup>5</sup>; <sup>1</sup>Leiden/NL,  
<sup>2</sup>Madrid/ES, <sup>3</sup>Berlin/DE, <sup>4</sup>Tustin, CA/US, <sup>5</sup>Reus/ES

**B-300** 11:51**DSCT versus 64-slice spiral CT: Comparison of radiation dose**

H.-T. Qi<sup>1</sup>, R. Merges<sup>2</sup>, J. Chen<sup>2</sup>, W. Qin<sup>1</sup>; <sup>1</sup>Jinan/CN, <sup>2</sup>Beijing/CN

**10:30 - 12:00****Room L/M****Neuro****SS 611****New vascular MR techniques**

Moderators: X. Leclerc; Lille/FR, M.A. Lucic; Novi Sad/RS

**B-301** 10:30**Perfusion territory imaging of intracranial branching arteries using continuous artery-selective spin labeling**

M. Helle<sup>1</sup>, K. Alfke<sup>1</sup>, D.G. Norris<sup>2</sup>, O. Jansen<sup>1</sup>; <sup>1</sup>Kiel/DE, <sup>2</sup>Nijmegen/NL

**B-302** 10:39**Perfusion heterogeneity in the infarct core and ischemic penumbra: Utilizing the novel "dynamic histogram analysis" in perfusion weighted MRI**

M. El Koussy, P. Schenk, A. Spreng, L. Remonda, L. Kappeler, R. Wiest, G. Schroth, J. Slotboom;  
Berne/CH

**B-303** 10:48**Delay insensitive singular value decomposition algorithm for brain perfusion analysis using shifted artery curves and preconditioning techniques**

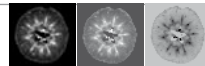
J. Wang<sup>1</sup>, O. Masoud<sup>1</sup>, B. Frake<sup>1</sup>, T. Naoko<sup>2</sup>, O. Miwa<sup>2</sup>; <sup>1</sup>Minnetonka, MN/US, <sup>2</sup>Tochigi/JP

**B-304** 10:57**Sensitivity of susceptibility weighted imaging (SWI) towards BOLD-signal changes induced with low CO<sub>2</sub> concentrations**

J. Sedlacik<sup>1</sup>, A. Deistung<sup>1</sup>, S. Witoszynskij<sup>1</sup>, R. Alexander<sup>2</sup>, H.-J. Menzel<sup>1</sup>, C. Kutschbach<sup>1</sup>, W.A. Kaiser<sup>1</sup>,  
J.R. Reichenbach<sup>1</sup>; <sup>1</sup>Jena/DE, <sup>2</sup>Vancouver BC/CA

**B-305** 11:06**Demonstration of the central cerebral veins by susceptibility-weighted imaging (SWI)**

C.M. Plank, G. Kasprlan, C. Mueller-Mang, P. Brugger, D. Prayer; Vienna/AT



**B-306** 11:15

**Dural sinus disease: Comparison of MR venography (MRV) and CTV**

S. Xia, J. Qi; Tianjin/CN

**B-307** 11:24

**Time-of-flight magnetic resonance venography at 3T: Comparison of a 12- versus 32-channel head coil**

F.L. Giesel<sup>1</sup>, V.M. Runge<sup>2</sup>, E.L. Lowther<sup>2</sup>, B.J. Correll<sup>2</sup>, M. Essig<sup>1</sup>; <sup>1</sup>Heidelberg/DE, <sup>2</sup>Temple, TX/US



**B-308** 11:33

**A comparison between susceptibility-weighted imaging (SWI), T2-weighted fast spin-echo and gradient-echo sequences for the evaluation of patients with familial cerebral cavernous malformations**

L.C.H. da Cruz Jr, E.L. Gasparetto, R.C. Domingues, J.P.M. de Souza, F.S. Domingues, R.C. Domingues; Rio de Janeiro/BR

**B-309** 11:42

**In-vivo visualization of flow in intracranial aneurysms with 4D flow-sensitized MR imaging**

S. Meckel<sup>1</sup>, A.F. Stalder<sup>2</sup>, F. Santini<sup>1</sup>, K. Scheffler<sup>1</sup>, E.-W. Radu<sup>1</sup>, M. Markl<sup>2</sup>, S.G. Wetzel<sup>1</sup>; <sup>1</sup>Basle/CH, <sup>2</sup>Freiburg/DE

**B-310** 11:51

**Time-resolved three-dimensional magnetic resonance digital subtraction angiography without contrast material**

M. Hori<sup>1</sup>, N. Shiraga<sup>1</sup>, M. Shimada<sup>1</sup>, A. Yamaguchi<sup>1</sup>, K. Miyamoto<sup>1</sup>, K. Suzuki<sup>1</sup>, H. Terada<sup>1</sup>, K. Goto<sup>1</sup>, S. Isono<sup>1</sup>, Y. Masao<sup>2</sup>; <sup>1</sup>Tokyo/JP, <sup>2</sup>Tochigi/JP

**10:30 - 12:00**

**Room N/O**

**Chest**

**SS 604**

**Reporting and CAD (CXR and CT)**

Moderators: K. Marten; Wuerzburg/DE, M.G. Skilakaki; Athens/GR

**B-311** 10:30

**Do radiologists still need to report chest X-rays?**

T. Bosemani, P. Mehrotra, J. Cox; Durham/UK

**B-312** 10:39

**Computer-aided detection (CAD) of pulmonary nodules in chest CT: Do radiologists benefit equally from CAD?**

J.E. Roos, D.A. Olsen, D.S. Paik, S. Napel, G.D. Rubin; Stanford, CA/US

**B-313** 10:48

**Comparison of performance of radiologists and a novel CAD system in the detection of pulmonary nodules on digital chest radiographs**

E. Kotter<sup>1</sup>, T.A. Bley<sup>1</sup>, T. Baumann<sup>1</sup>, U. Saueressig<sup>1</sup>, G. Pache<sup>1</sup>, M. Treier<sup>1</sup>, O. Schäfer<sup>1</sup>, U. Neitzel<sup>2</sup>, M. Langer<sup>1</sup>; <sup>1</sup>Freiburg/DE, <sup>2</sup>Hamburg/DE

**B-314** 10:57

**Is the computer-aided detection of lung lesions also effective in chest radiography?**

M. Uffmann<sup>1</sup>, M. Weber<sup>1</sup>, M. Scheerder<sup>2</sup>, E. Boorsma<sup>2</sup>, C.M. Schaefer-Prokop<sup>2</sup>; <sup>1</sup>Vienna/AT, <sup>2</sup>Amsterdam/NL

SATURDAY

**B-315** 11:06**Part-solid pulmonary nodule detection in MDCT images: Evaluation of a CAD system**A.K. Jerebko<sup>1</sup>, M. Salganicoff<sup>1</sup>, T. Itoh<sup>2</sup>, S. Periaswamy<sup>1</sup>, M. Wolf<sup>1</sup>, S. Yu<sup>1</sup>, V. Anand<sup>1</sup>, S. Park<sup>1</sup>, L. Bogoni<sup>1</sup>, M. Ujita<sup>2</sup>; <sup>1</sup>Malvern, PA/US, <sup>2</sup>Tokyo/JP**B-316** 11:15**Incidental major non-cardiac findings on coronary computed tomography. A meta-analysis**

N. Flor, C. Mazzocchi, F. Sardanelli, G. Cornalba; Milan/IT

**B-317** 11:24**Volume measurement of pulmonary nodules using two types of volumetric nodule-sizing software: A comparison of reproducibility of volumes of purely intraparenchymal, juxtavascular, and pleural-based nodules**A.L.M. Leusveld<sup>1</sup>, P.M. van Ooijen<sup>1</sup>, D.M. Xu<sup>1</sup>, Y.R. Zhao<sup>1</sup>, R.J. van Klaveren<sup>2</sup>, H. van de Zaag-Loonen<sup>1</sup>, Y. Wang<sup>1</sup>, M. Oudkerk<sup>1</sup>; <sup>1</sup>Groningen/NL, <sup>2</sup>Rotterdam/NL**B-318** 11:33**Segmentation of solid and non solid lung nodules: A phantom study**A. Larici<sup>1</sup>, L. Menchini<sup>1</sup>, F. Maggi<sup>1</sup>, F. Molinari<sup>1</sup>, A. Matkovich<sup>2</sup>, L. Bonomo<sup>1</sup>; <sup>1</sup>Rome/IT, <sup>2</sup>Milwaukee, WI/US**B-319** 11:42**Subtraction imaging for improved detection of change in ground glass nodules in chest computed tomography**

M. Staring, J.P.W. Pluim, B. de Hoop, S. Klein, M. Prokop; Utrecht/NL

**B-320** 11:51**Impact of patient pose differences on subtle interval change detection by temporal subtraction in chest radiographs. A phantom study**J. von Berg<sup>1</sup>, D. Manke<sup>1</sup>, C. Schaefer-Prokop<sup>2</sup>, U. Neitzel<sup>1</sup>; <sup>1</sup>Hamburg/DE, <sup>2</sup>Amsterdam/NL**10:30 - 12:00****Room R2****Cardiac****SS 603****Imaging of the right heart***Moderators: M. Gardarsdottir; Reykjavik/IS, F. Sardanelli; Milan/IT***B-321** 10:30**Tricuspid anular displacement: A new indicator of right ventricular function on MDCT scans**

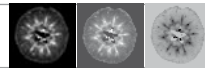
D. Delhaye, M. Rémy-Jardin, J.-B. Faivre, V. Deken, A. Duhamel, J. Rémy; Lille/FR

**B-322** 10:39**Right ventricular late enhancement in contrast-enhanced cardiac MRI: An important feature in the differential diagnosis of cardiac disease**

P. Hunold, O. Bruder, T. Schlosser, K. Nassenstein, M. Jochims, J. Barkhausen; Essen/DE

**B-323** 10:48**Right ventricular delayed enhancement in patients with pulmonary arterial hypertension (PAH)**

F.A. Calabrese, M. Francone, I. Iacucci, F. Vasselli, D. Vizza, I. Carbone, C. Catalano, R. Passariello; Rome/IT



**B-324** 10:57

**Value of regional and global right ventricular function analysis using cardiac magnetic resonance compared to the Task Force criteria for the diagnosis of arrhythmogenic right ventricular dysplasia/cardiomyopathy**

A.A. Azarine<sup>1</sup>, X. Lyon<sup>2</sup>, F. Hidden-Lucet<sup>1</sup>, A. Redheuil<sup>1</sup>, P. Ou<sup>1</sup>, E. Mousseaux<sup>1</sup>; <sup>1</sup>Paris/FR, <sup>2</sup>Lausanne/CH

**B-325** 11:06

**Right ventricle kinetic analysis by a radial steady state approach on patients with ARVC suspicion**

C. Bultrini, S. Scipione, S. Battisti, E. di Cesare, C. Masciocchi, M.V. di Fabio; *LAquila/IT*

**B-326** 11:15

**Quantitative assessment of right ventricular function and size in patients with mitral regurgitation using 64-section multi-detector row CT: Comparison with real-time three-dimensional echocardiography and magnetic resonance imaging**

Y. Guo, Z.-G. Yang, Y. Li, X.-C. Zhang, Y. Wu, T.-M. Zhang; *Chengdu/CN*

**B-327** 11:24

**Impact of right ventricular contrast enhancement on the accuracy of right heart function analysis at coronary CT angiography**

H. Lee, M.R. Aho, P. Suranyi, J.M. Kerl, P. Costello, U.J. Schoepf; *Charleston, SC/US*

**B-328** 11:33

**Intra-individual comparison of 0.5 and 1.0 M contrast agents in MR angiography of chronic thromboembolic pulmonary hypertension**

N. Woodhouse<sup>1</sup>, J.M. Wild<sup>1</sup>, E.J.R. van Beek<sup>2</sup>, P.D. Griffiths<sup>1</sup>, D. Kiely<sup>1</sup>; <sup>1</sup>Sheffield/UK, <sup>2</sup>Iowa City, IA/US

**B-329** 11:42

**Noninvasive Qp/Qs ratio measurement with phase-contrast cine MRI in patients with atrial septal defect: Comparison with heart catheterization**

L. Rizzo<sup>1</sup>, A. Chiribini<sup>2</sup>, M. Marocco<sup>2</sup>, F. Orzan<sup>2</sup>, M. Allasia<sup>1</sup>, F. Solitro<sup>1</sup>, C. Fava<sup>1</sup>; <sup>1</sup>Orbassano/IT, <sup>2</sup>Turin/IT

**B-330** 11:51

**Detection of myocardial fibrosis in patients with suspicion of arrhythmogenic right ventricular cardiomyopathy in contrast-enhanced magnetic resonance imaging**

P. Klimeczek, R. Banys, B. Laskowicz, M. Pasowicz; *Krakow/PL*

**10:30 - 12:00**

**Room R3**

**Interventional Radiology**

**SS 609b**

**Liver: Embolisation**

*Moderators: V. Bérczi; Budapest/HU, T.J. Popiela; Kraków/PL*

**B-331** 10:30

**Long term results of transcatheter chemoembolisation (TACE) with doxorubicin loaded DC Bead in the treatment of HCC not eligible to curative treatments**

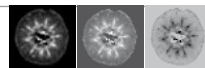
K. Malagari, E. Emmanouil, V. Vergadis, D. Letsou, D. Antonopoulos, E. Alexopoulou, K. Chatzimichail, A. Gouliamos, D. Kelekis; *Athens/GR*

**B-332** 10:39

**Transarterial chemoembolization in down-staging program for hepatocellular carcinoma prior to liver transplantation: The Bologna work-in-progress experience**

A. Cappelli, A. Bazzocchi, E. Giampalma, R. Golfieri; *Bologna/IT*

**B-333** 10:48**Regional <sup>90</sup>Yttrium microsphere treatment of chemotherapy-refractory colorectal cancer liver metastases**T.F. Jakobs, R.-T. Hoffmann, K. Dehm, C. Trumm, H.-J. Stemmler, K. Tatsch, T.K. Helmberger, M.F. Reiser; *Munich/DE***B-334** 10:57**Development of diaphragmatic weakness after transcatheter arterial chemoembolization of right inferior phrenic artery: Its frequency and determinant factors**D. Lee, J. Chung, H. Jae, W. Lee, J. Park; *Seoul/KR***B-335** 11:06**Addition of pirarubicin and amidarone in transarterial chemoembolization of unresectable hepatocellular carcinoma: A pilot study**B. Guiu<sup>1</sup>, R. Loffroy<sup>1</sup>, S. Guiu<sup>1</sup>, C. Colin<sup>2</sup>, C. Deville<sup>1</sup>, F. Bonnetain<sup>1</sup>, J.-L. Jouve<sup>1</sup>, L. Bedenne<sup>1</sup>, B. Chauffert<sup>1</sup>, J.-P. Cercueil<sup>1</sup>, D. Krausé<sup>1</sup>; <sup>1</sup>Dijon/FR, <sup>2</sup>Lyon/FR**B-336** 11:15**Post chemoembolization treatment of liver metastases from neuroendocrine tumors, survival rate and local control following Nobel protocol treatment using mitomycin C and gemcitabine as therapeutic agents**N.A.N. Mohammed, N.N.N. Naguib, K. Eichler, T. Lehnert, T.J. Vogl; *Frankfurt a. Main/DE***B-337** 11:24**Regional transarterial chemoperfusion with combined gemcitabine and mitomycin C in unresectable liver metastases: Tumor response and survival**T.J. Vogl<sup>1</sup>, S. Zangos<sup>1</sup>, U. Jacob<sup>2</sup>, R. Bauer<sup>1</sup>; <sup>1</sup>Frankfurt a. Main/DE, <sup>2</sup>Bad Heilbrunn/DE**B-338** 11:33**Prospective study on the use of transarterial chemoembolization (TACE) in liver metastases of colorectal carcinoma**T.J. Vogl<sup>1</sup>, T. Gruber<sup>1</sup>, S. Zangos<sup>1</sup>, J. Balzer<sup>2</sup>; <sup>1</sup>Frankfurt a. Main/DE, <sup>2</sup>Mainz/DE**B-339** 11:42**Transarterial chemoembolization in hepatocellular carcinoma: Role of diffusion weighted imaging and subtracted imaging in necrosis assessment**L. Mannelli<sup>1</sup>, S. Kim<sup>1</sup>, C. Hajdu<sup>1</sup>, M. Losada<sup>1</sup>, T. Clarke<sup>1</sup>, S. Colagrande<sup>2</sup>, B. Taouli<sup>1</sup>; <sup>1</sup>New York, NY/US, <sup>2</sup>Florence/IT**B-340** 11:51**Pneumatically driven robotic system for MR-guided interventions: First clinical experiences in Vienna**J. Kettenbach, K. Kubin, A. Stadler, J. Lammer; *Vienna/AT***14:00 - 15:30****Room A****Musculoskeletal****SS 710****Arthritis***Moderators: W.C.G. Peh; Singapore/SG, P. Peloschek; Vienna/AT***B-341** 14:00**The impact of age, sex, body mass index and handedness on finger joint space widths measured by computer-aided joint space analysis (CAJSA) in patients with rheumatoid arthritis (RA)**A. Pfeil, J. Böttcher, M.L. Schäfer, A. Hansch, H.-J. Mentzel, A. Petrovitch, W.A. Kaiser; *Jena/DE*



**B-342** 14:09

**Phase-contrast radiography in a clinical setting, using high-resolution digital imaging system with a small-focus X-ray tube instead of synchrotron radiation: II. Quantitative evaluation of bone trabeculae area on early-stage rheumatoid arthritis**  
 J. Tanaka<sup>1</sup>, T. Mimura<sup>1</sup>, H. Oda<sup>1</sup>, C. Honda<sup>2</sup>, M. Tazaki<sup>2</sup>, Y. Shinden<sup>2</sup>, T. Unezawa<sup>1</sup>, N. Funakoshi<sup>1</sup>, H. Kawasaki<sup>1</sup>, Y. Wada<sup>1</sup>; <sup>1</sup>Iruma-gun/JP, <sup>2</sup>Hachioji/JP

**B-343** 14:18

**3T-MRI compared to multidetector-row CT in the evaluation of erosions of both hands in patients with suspected rheumatoid arthritis**  
 C.R. Krestan, S. Nemeč, T. Kapral, S. Mehrain, C. Czerny; *Vienna/AT*

**B-344** 14:27

**Intra-articular distribution pattern after ultrasound guided injections in wrist joints of patients with rheumatoid arthritis**  
 M. Boesen<sup>1</sup>, K.E. Jensen<sup>2</sup>, S. Torp-Pedersen<sup>1</sup>, M.A. Cimmino<sup>3</sup>, B. Danneskiold-Samsøe<sup>1</sup>, H. Bliddal<sup>1</sup>; <sup>1</sup>Frederiksberg, Copenhagen/DK, <sup>2</sup>Copenhagen/DK, <sup>3</sup>Genoa/IT

**B-345** 14:36

**Value of contrast enhanced grey-scale ultrasound: Assessment of joint vascularity in therapeutic follow-up of rheumatoid arthritis**  
 T. De Zordo, D. Junker, P. Soegner, G. Feuchtner, J. Gruber, A. Klauser; *Innsbruck/AT*

**B-346** 14:45

**Quantification of perfusion and endothelial permeability in inflammatory joint diseases: First results**  
 S. Weckbach, S.P. Sourbron, M. Notohamiprodjo, J. Raya, A. Horng, M.F. Reiser, C. Glaser; *Munich/DE*

**B-347** 14:54

**MR characterisation of synovial fluid ex vivo: Is it possible to differentiate between septic and non-septic arthritis?**  
 E. Wiener, M. Zanetti, J. Hodler, C.W.A. Pfirrmann; *Zurich/CH*

**B-348** 15:03

**Arthritic changes in patients with ankylosing spondylitis: Scoring at whole-body thin-section low-dose MDCT. Initial experience**  
 M.C. Freund, F. Hartig, B. Glodny, E. Mur, K.M. Unsinn, W. Jaschke; *Innsbruck/AT*

**B-349** 15:12

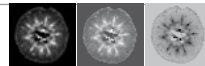
**Diagnostic imaging of gout: Comparison of high resolution US versus conventional X-ray**  
 T. Rettenbacher, S. Ennemoser, H. Ulmer, F. Hartig, M. Herold, W. Jaschke; *Innsbruck/AT*

**B-350** 15:21

**USPIO-enhanced magnetic resonance imaging of the knee in asymptomatic volunteers**  
 C.S. Reiner<sup>1</sup>, A.M. Lutz<sup>1</sup>, F. Tschirch<sup>1</sup>, J. Froehlich<sup>1</sup>, B. Bonnemain<sup>2</sup>, B. Marincek<sup>1</sup>, D. Weishaupt<sup>1</sup>; <sup>1</sup>Zurich/CH, <sup>2</sup>Roissy/FR

**14:00 - 15:30****Room B****Abdominal Viscera (Solid Organs)****SS 701a****Magical bullets for hepatic lesions***Moderators: B.I. Choi; Seoul/KR, L. Curvo-Semedo; Coimbra/PT***B-351** 14:00**Detection of liver metastases from neuroendocrine tumors: [68Ga]-DOTATOC-PET/CT and/or liver MRI?**C. Pfannenberger, P. Aschoff, M. Lichy, H. Schlemmer, M. Reimold, C.D. Claussen; *Tuebingen/DE***B-352** 14:09**Health economic evaluation of three imaging strategies in patients with suspected colorectal liver metastases: Gd-EOB-DTPA (Primovist)-enhanced MRI vs. extracellular contrast media-enhanced MRI and 3-phase MDCT in Germany, Italy and Sweden**C.J. Zech<sup>1</sup>, L. Grazioli<sup>2</sup>, E. Jonas<sup>3</sup>, M. Ekman<sup>3</sup>, R. Niebecker<sup>4</sup>, S. Gschwend<sup>4</sup>, J. Breuer<sup>4</sup>, L. Jönsson<sup>3</sup>, S. Kienbaum<sup>4</sup>, A. Guo<sup>5</sup>; <sup>1</sup>Munich/DE, <sup>2</sup>Brescia/IT, <sup>3</sup>Stockholm/SE, <sup>4</sup>Berlin/DE, <sup>5</sup>Montville, NJ/US**B-353** 14:18**Differentiation of well-differentiated hepatocellular carcinomas from other hepatocellular nodules in cirrhotic liver: Value of SPIO-enhanced MR imaging at 3.0T**H. Park, J. Lee, S. Kim, J. Han, B. Choi; *Seoul/KR***B-354** 14:27**Comparison of two fat suppression techniques for MRI regarding image quality and conspicuity of liver lesions**T.C. Lauenstein<sup>1</sup>, P. Sharma<sup>1</sup>, T. Hughes<sup>2</sup>, K. Heberlein<sup>2</sup>, D.R. Martin<sup>1</sup>; <sup>1</sup>Atlanta, GA/US, <sup>2</sup>Erlangen/DE**B-355** 14:36**Gadobenate dimeglumine (Gd-BOPTA) enhanced MR imaging of small (<20-mm) hepatic nodules seen on arterial phase: Usefulness of the hepatobiliary phase**A. Guerrisi, D. Marin, C. Catalano, M. Di Martino, M. Baski, G. De Filippis, R. Passariello; *Rome/IT***B-356** 14:45**Tumor-liver contrast and subjective tumor conspicuity of respiratory-triggered T2-weighted fast spin-echo sequence compared with T2\*-weighted gradient recalled-echo sequence for ferucarbotran-enhanced magnetic resonance imaging of hepatic malignant tumors**K. Ishiyama, M. Hashimoto, T. Sato, J. Watarai; *Akita City/JP***B-357** 14:54**A prospective multicenter trial of contrast-enhanced ultrasound for the differential diagnosis of hepatic tumors in Germany: Results on 1349 liver lesions**D. Strobel<sup>1</sup>, K.-P. Seitz<sup>2</sup>, W. Blank<sup>3</sup>, A. Schuler<sup>4</sup>, C. Dietrich<sup>5</sup>, A. von Herbay<sup>6</sup>, C. Greis<sup>7</sup>, H. Strunk<sup>3</sup>, T. Bernatik<sup>1</sup>; <sup>1</sup>Erlangen/DE, <sup>2</sup>Sigmaringen/DE, <sup>3</sup>Reutlingen/DE, <sup>4</sup>Geislingen/DE, <sup>5</sup>Bad Merengtheim/DE, <sup>6</sup>Tübingen/DE, <sup>7</sup>Konstanz/DE, <sup>8</sup>Bonn/DE**B-358** 15:03**Hepatic transit time analysis using contrast enhanced ultrasound: Evaluation of quantitative analysis and "visual" blinded reading in patients with liver metastases and healthy volunteers**J. Hohmann<sup>1</sup>, C. Müller<sup>2</sup>, A. Oldenburg<sup>2</sup>, J. Skrok<sup>2</sup>, B. Frericks<sup>2</sup>, K.-J. Wolf<sup>2</sup>, T. Albrecht<sup>2</sup>; <sup>1</sup>Basle/CH, <sup>2</sup>Berlin/DE





**B-359** 15:12

**Value of contrast-enhanced ultrasound (CEUS) in cancer patients with subcentimetric focal liver lesions (FLLs) detected at multislice CT (MSCT)**

F. Sandomenico, O. Catalano, A. Nunziata, E. de Lutio di Castelguidone, A. Siani; *Naples/IT*

**B-360** 15:21

**Contrast enhanced ultrasonography in benign focal liver lesion characterization: Activity-based cost analysis**

N. Faccioli, M. D'Onofrio, A. Comai, R. Pozzi Mucelli; *Verona/IT*

**14:00 - 15:30**

**Room C**

**GI Tract**

**SS 701b**

**Colon and rectum**

*Moderators: G. Maskell; Truro/UK, S. Schmidt; Lausanne/CH*

**B-361** 14:00

**Is algorithm designed to pair corresponding regions in prone and supine helpful for interpretation in CT colonography?**

M. Cadi, I. Chartier-Huynh, D. Chen, P. Grenier, O. Lucidarme; *Paris/FR*

**B-362** 14:09

**Two different doses of iodinated fecal tagging agent for CT colonography: Evaluation of tagging quality, homogeneity, patient acceptance and diagnostic accuracy**

M.H. Liedenbaum, C.I.B.F. Gouw, A.H. de Vries, A.F. van Rijn, S. Bipat, P. Fockens, E. Dekker, J. Stoker; *Amsterdam/NL*

**B-363** 14:18

**Quantitative quality assessment of different faecal tagging (FT) CT colonography (CTC) preparations**

D. Campanella<sup>1</sup>, L. Morra<sup>2</sup>, S. Delsanto<sup>2</sup>, T.M. Gallo<sup>1</sup>, V. Tartaglia<sup>1</sup>, D. Regge<sup>1</sup>; <sup>1</sup>Candiolo/IT, <sup>2</sup>Turin/IT

**B-364** 14:27

**Fecal-tagging CT colonography with structure-analysis electronic cleansing for detection of colorectal flat lesions**

Y. Xu<sup>1</sup>, W. Cai<sup>1</sup>, J. Nappi<sup>1</sup>, M. Matoba<sup>2</sup>, H. Yoshida<sup>1</sup>; <sup>1</sup>Boston, MA/US, <sup>2</sup>Kanagawa/JP

**B-365** 14:36

**Pilot study of dynamic PET/CT in the study of rectal cancer**

E.M. Anderson, D. Morofke, N.P. Hughes, M. Brady, N.M. Mortensen, D. Kerr, K. Bradley, F.V. Gleeson; *Oxford/UK*

**B-366** 14:45

**The feasibility study of MSCT perfusion evaluating intratumoral microvessel density of colorectal cancer**

X. Xu, Y. Liu, K. Chen; *Shanghai/CN*

**B-367** 14:54

**Comparison of accuracy of CT and MRI in predicting circumferential resection margin with histologic correlation in rectal cancer after preoperative chemoradiotherapy**

S. Lee<sup>1</sup>, Y. Kim<sup>2</sup>, K. Lee<sup>2</sup>; <sup>1</sup>Seoul/KR, <sup>2</sup>Seongnam-si/KR

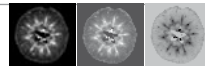
**B-368** 15:03

**Transrectal ultrasonography and magnetic resonance imaging in the N-staging of rectal cancer**

S.R. Rafaelsen, T. Sørensen, A. Jakobsen, C. Bisgaard, J. Lindebjerg; *Veje/DK*

**SATURDAY**

**B-369** 15:12**Spectrum of MR-defecography findings in patients with anismus**A.E. Solopova, C.S. Reiner, R. Tutuian, B. Marincek, D. Weishaupt; *Zurich/CH***B-370** 15:21**MR-defecography: Prospective comparison between two different rectal enema compositions**A.E. Solopova<sup>1</sup>, F.H. Hetzer<sup>2</sup>, B. Marincek<sup>1</sup>, D. Weishaupt<sup>1</sup>; <sup>1</sup>Zurich/CH, <sup>2</sup>St. Gallen/CH**14:00 - 15:30****Room F1****Interventional Radiology****SS 709a****Radiofrequency ablation***Moderators: T. de Baère; Villejuif/FR, D. Kuhelj; Ljubljana/SI***B-371** 14:00**Efficacy and safety of radiofrequency thermal ablation in the treatment of toxic and non-toxic thyroid nodules with pressure symptoms in elderly patients**S. Spiezia<sup>1</sup>, A. Faggiano<sup>1</sup>, F. Milone<sup>1</sup>, V. Ramundo<sup>1</sup>, R. Garberoglio<sup>2</sup>, A.P. Assanti<sup>1</sup>, M. D'Andrea<sup>1</sup>, C. Di Somma<sup>1</sup>, G. Lombardi<sup>1</sup>, A. Colao<sup>1</sup>; <sup>1</sup>Naples/IT, <sup>2</sup>Turin/IT**B-372** 14:09**Growth rate of new hepatocellular carcinomas after percutaneous radiofrequency ablation: Evaluation with multiphase CT**D. Choi; *Seoul/KR***B-373** 14:18**Outcome of PET/CT assisted RF ablation in HCC nodules and colorectal liver metastases: Mid-term results**H. Kuehl, J. Stattaus, S. Hertel, P. Hunold, G. Kaiser, G. Antoch, A. Bockisch, M. Forsting; *Essen/DE***B-374** 14:27**Early detection of residual viable tumour after radiofrequency ablation of colorectal liver metastases: Diffusion-weighted MRI versus unenhanced and gadolinium-enhanced MRI**S. Zaid, L. Crespi, P. Marelli, T. Ierace, L. Solbiati; *Busto Arsizio/IT***B-375** 14:36**Multipolar radiofrequency ablation (RFA) of liver tumours: Frequency and causes of local recurrences**T. Albrecht, B. Frericks, S. Valdeig, J.P. Ritz, K.-J. Wolf; *Berlin/DE***B-376** 14:45**Effect of blood perfusion on coagulation zone size during radiofrequency tumor ablation**W. Schramm, D. Haemmerich; *Charleston, SC/US***B-377** 14:54**Variability in effect of radiofrequency ablation in different tissues: Ex vivo and in vivo comparative studies**Y. Kim, D. Choi, H. Rhim, Y.-S. Kim; *Seoul/KR***B-378** 15:03**Percutaneous radiofrequency ablation of hepatocellular carcinoma with assistance of artificial ascites: Safety and technical efficacy in 143 patients.**I. Song, H. Rhim, Y.-S. Kim, D. Choi, W. Lee, H. Lim; *Seoul/KR*



**B-379** 15:12

**Fluid-modulated bipolar radiofrequency ablation: An ex vivo evaluation study**

P. Bruners, H. Mueller, R.W. Guenther, T. Schmitz-Rode, A.H. Mahnken; *Aachen/DE*

**B-380** 15:21

**Colorectal liver metastases treated with radiofrequency ablation: Evaluation of FDG-PET/CT for follow-up**

H. Kuehl, G. Antoch, S. Rosenbaum-Krumme, H. Stergar, G. Kaiser, M. Forsting, A. Bockisch; *Essen/DE*

**14:00 - 15:30**

**Room 6/H**

**Head and Neck**

**SS 708**

**New approaches to examination techniques**

*Moderators: V. Chong; Singapore/SG, A. Trojanowska; Lublin/PL*

**B-381** 14:00

**Influence of different mAs-products on image quality in MSCT of the head and neck region**

U. Baum, K. Anders, C. Ruedel, M. Lell, W.A. Bautz; *Erlangen/DE*

**B-382** 14:09

**Determining optimized scan parameters of multidetector CT of the head and neck: Comparison of different scan delay and total volumes of contrast material**

Y. Lee, B.-K. Je, S. Yeom, W.-J. Lee, B. Seo, B. Kim; *Ansan/KR*

**B-383** 14:18

**Dose comparison of dental MSCT and dental cone beam CT**

E.M. Coppentrath<sup>1</sup>, F. Draenert<sup>1</sup>, U. Lechel<sup>2</sup>, R. Veit<sup>2</sup>, T. Meindl<sup>1</sup>, M.F. Reiser<sup>1</sup>, U.L. Mueller-Lisse<sup>1</sup>;

<sup>1</sup>Munich/DE, <sup>2</sup>Neuherberg/DE

**B-384** 14:27

**3D-CTA in the head and neck using a new software to remove bony structures: Evaluation of the images and clinical role**

T. Otani, N. Tomura, S. Takahashi, I. Sakuma, K. Yasuda, J. Watarai; *Akita/JP*

**B-385** 14:36

**Comparison of MRI combined with diffusion-weighted imaging and triphasic dynamic contrast enhanced multislice spiral CT for the diagnosis of parotid tumors**

H. Yerli<sup>1</sup>, A.M. Agildere<sup>2</sup>, E. Aydin<sup>2</sup>, M. Coskun<sup>2</sup>, N. Haberal<sup>2</sup>; <sup>1</sup>Izmir/TR, <sup>2</sup>Ankara/TR

**B-386** 14:45

**Gadolinium-enhanced T2\*-weighted MR imaging of tumors in the extracranial head and neck: Feasibility study and preliminary results using a distributed-parameter tracer kinetic analysis**

S. Bisdas<sup>1</sup>, M. Baghi<sup>1</sup>, I. Burck<sup>1</sup>, M. Kerl<sup>1</sup>, J. Wagenblast<sup>1</sup>, C. Thng<sup>2</sup>, M.G. Mack<sup>1</sup>, T.J. Vogl<sup>1</sup>, T. Koh<sup>2</sup>;

<sup>1</sup>Frankfurt a. Main/DE, <sup>2</sup>Singapore/SG

**B-387** 14:54



**Assessment of nasal mass with diffusion weighted single shot echoplanar MR imaging**

A.A.A. Abdel Razek, N. Soliman, A. Haroun, N. Nada; *Mansoura/EG*

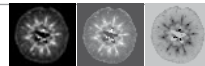
**B-388** 15:03

**Clinical evaluation of elastography for the differential diagnosis of thyroid follicular tumors**

N. Fukunari<sup>1</sup>, K. Arai<sup>1</sup>, A. Nakamura<sup>1</sup>, S. Sakaue<sup>1</sup>, T. Mitake<sup>2</sup>; <sup>1</sup>Yokohama/JP, <sup>2</sup>Chiba/JP

SATURDAY

**B-389** 15:12**Prediction of malignancy in thyroid nodule: Diffusion weighted echoplanar MR imaging**A.A.A. Abdel Razek, A. Farouk, A. Tawfik, A. Denewer, N. Nada; *Mansoura/EG***B-390** 15:21**Radio-guided localization of neck masses: A new approach**A. Salmasslioglu, M. Tunaci, G. Acunas, B. Bakir, A. Ucar, K. Guven, I. Adalet, Y. Erbil; *Istanbul/TR***14:00 - 15:30****Room I****Physics in Radiology****SS 713****New approaches in MRI***Moderators: A. Del Guerra; Pisa/IT, D. Dietrich; Munich/DE***B-391** 14:00**Prospective navigator-echo-based real-time triggering of fetal head movement for the reduction of artifacts**H.M. Bonel, K.A. Frei, M. Meyer-Wittkopf, L. Raio, L. Remonda, R. Wiest; *Berne/CH***B-392** 14:09**A multimodality assessment of global left ventricular function using a moving heart phantom**J.M. Groen, M.J.W. Greuter, P.A. van der Vleuten, D.D. Lubbers, M. Oudkerk; *Groningen/NL***B-393** 14:18**MRI (VIPAR) gel dosimetry: Comparison of two methods for the construction of 2D color radiation dose maps using data obtained directly from a newly designed research PACS system**T.G. Maris<sup>1</sup>, F. Zacharopoulou<sup>1</sup>, K. Karolemeas<sup>2</sup>, E. Pappas<sup>1</sup>, A. Papadakis<sup>1</sup>, J. Damilakis<sup>1</sup>; <sup>1</sup>*Iraklion/GR*, <sup>2</sup>*Athens/GR***B-394** 14:27**A switchable, low field multi-channel broadband MRI system for hyperpolarized gas and dynamic nuclear polarization (DNP) research**M. Paley, E. Krjukov, E. Whitby, J. Wild; *Sheffield/UK***B-395** 14:36**Principle and performance of a time-resolving scan procedure with a zigzag spiral**K. Stierstorfer, E. Klotz, K. Schwarz, C. Süß, B. Schmidt, T. Flohr; *Forchheim/DE***B-396** 14:45**Determination of relaxivities of nanosomes doped with monodisperse superparamagnetic nanoparticles of various core sizes**M.G. Kaul, O.T. Bruns, U.I. Tromsdorf, N. Bigall, H. Weller, U. Beisigel, G. Adam; *Hamburg/DE***B-397** 14:54**A novel magnetic field inhomogeneity correction for ultra-high field MR: A demonstration on phase contrast MRA of the brain vasculature**S. Vitabile<sup>1</sup>, S. Sammet<sup>2</sup>, M.V. Knopp<sup>2</sup>; <sup>1</sup>*Palermo/IT*, <sup>2</sup>*Columbus, OH/US***B-398** 15:03**Interactive scan-control with online reconstruction improves axial breath-hold imaging for continuously moving table MRI**T. Baumann, U. Ludwig, G. Pache, O. Schaefer, M. Langer; *Freiburg/DE*



**B-399** 15:12

**Scan time reduction in diffusion-weighted imaging of the upper abdomen: Use of tracking only navigator echo (TRON)**

T. Takahara<sup>1</sup>, T. Ogino<sup>2</sup>, M. van Leeuwen<sup>1</sup>, J. de Jong<sup>1</sup>, T. Kwee<sup>1</sup>, P. Luijten<sup>1</sup>, W.P.H. Mali<sup>1</sup>; <sup>1</sup>*Utrecht/NL*, <sup>2</sup>*Tokyo/JP*

**B-400** 15:21

**Dynamic MRI evaluation of obstructive sleep apnea (OSA) in patients treated with continuous positive airway pressure (CPAP): Early experiences**

G. Pelle, V. Panebianco, R. Roma, V. Vergari, E. Santucci, R. Passariello; *Rome/IT*

**14:00 - 15:30**

**Room K**

**Pediatric**

**SS 712**

**Fetal imaging**

*Moderators: C. Balassy; Vienna/AT, V. Donoghue; Dublin/IE*

**B-401** 14:00

**Logistic regression analysis based on MRI lung volume measurement in fetuses with CDH before and after 30 weeks' gestation: Prediction of mortality and the need for ECMO therapy**

K.A. Büsing, K. Kilian, T. Schaible, D. Dinter, W. Neff; *Mannheim/DE*

**B-402** 14:09

**MR relative fetal lung volume in congenital diaphragmatic hernia: An evaluation of seven formulas for predicting survival and the need for extracorporeal membrane oxygenation (ECMO) therapy**

K.A. Büsing, K. Kilian, T. Schaible, C. Endler, R. Schaffelder, W. Neff; *Mannheim/DE*

**B-403** 14:18

**Assessment of various applications of fetal cine MRI in prenatal evaluation**

T. Feygin, A. Vossough, L.T. Bilaniuk, L.J. States, M. Epelman, R.A. Zimmerman; *Philadelphia, PA/US*

**B-404** 14:27

**In utero magnetic resonance imaging and spectroscopy in women with diabetes complicating pregnancy**

E.H. Whitby, M. Paley, A. Chetwood, T. Farrell, R. Fraser; *Sheffield/UK*

**B-405** 14:36

**Magnetic resonance imaging of the fetal posterior fossa**

T. Lavanya, R. Batty, P. Griffiths, J. Eames, M. Paley, E.H. Whitby; *Sheffield/UK*

**B-406** 14:45

**In utero tractography of fetal brain pathologies**

G.J. Kasprjan, P.C. Brugger, E. Krampl, C. Lindner, F. Stuhr, D. Prayer; *Vienna/AT*

**B-407** 14:54

**Prerequisites for in utero tractography of the fetal brain**

G.J. Kasprjan, P.C. Brugger, M. Weber, F. Stuhr, C. Lindner, D. Prayer; *Vienna/AT*

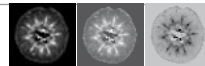
**B-408** 15:03

**Maturational changes of the olfactory bulbs on MRI**

F. Floemer, O. Magerkurth, C. Jauckus, J.F.L. Schneider; *Basle/CH*

**SATURDAY**

**B-409** 15:12**Inner ear malformations in the 22q11 deletion syndrome**C. Cellier, J.P. Marie, V. Drouin-Garraud, F. Callonnec, D. Dehesdin, P. Le Dosseur; *Rouen/FR***B-410** 15:21**Magnetic resonance imaging of the developing efferent lacrimal pathways and pathogenesis of congenital dacryocystoceles**P.C. Brugger, D. Prayer; *Vienna/AT***14:00 - 15:30****Room L/M****Vascular****SS 715****MR angiography***Moderators: I. Bargellini; Pisa/IT, S.G. Ruehm; Los Angeles, CA/US***B-411** 14:00**High spatial and temporal resolution MRA of the entire peripheral vascular system using a new 3D time-resolved MRA technique (TWIST)**F.M. Vogt<sup>1</sup>, S. Maderwald<sup>1</sup>, H.H. Quick<sup>1</sup>, R. Kroeker<sup>2</sup>, M. Schmidt<sup>2</sup>, J. Barkhausen<sup>1</sup>; <sup>1</sup>Essen/DE, <sup>2</sup>Erlangen/DE**B-412** 14:09**How to measure SNR and CNR in modern CE-MRA using image postprocessing: Are SNR and CNR calculations reliable?**B. Buerke<sup>1</sup>, T. Allkemper<sup>1</sup>, H. Kugel<sup>1</sup>, C. Bremer<sup>1</sup>, S. Evers<sup>1</sup>, H. Kooijmann<sup>2</sup>, W. Heindel<sup>1</sup>, B. Tombach<sup>1</sup>; <sup>1</sup>Muenster/DE, <sup>2</sup>Hamburg/DE**B-413** 14:18**Diagnostic accuracy of contrast-enhanced MR angiography with gadobenate dimeglumine**G.K. Schneider<sup>1</sup>, C. Ballarati<sup>2</sup>, L. Grazioli<sup>3</sup>, R. Manfredi<sup>4</sup>, S. Thurnher<sup>5</sup>, M.A. Kirchin<sup>6</sup>; <sup>1</sup>Homburg a. Saar/DE, <sup>2</sup>Como/IT, <sup>3</sup>Brescia/IT, <sup>4</sup>Verona/IT, <sup>5</sup>Vienna/AT, <sup>6</sup>Milan/IT**B-414** 14:27**Intra-individual open-label international multicenter study of magnetic resonance angiography (MRA) with the blood pool contrast agent gadofosveset and conventional extracellular contrast agents with intra-arterial digital subtraction angiography as standard of reference in patients with peripheral artery disease**F.M. Vogt<sup>1</sup>, W.A. Willinek<sup>2</sup>, M. Campos Coy<sup>3</sup>, F. Ogresta<sup>4</sup>, E. Salomonowitz<sup>5</sup>, J. Sánchez Cortazar<sup>6</sup>, K.-F. Kreitner<sup>7</sup>, H.J. Stahke Junior<sup>8</sup>, T. Voigtländer<sup>9</sup>, A. Beresnak<sup>4</sup>, S. Rossi<sup>4</sup>; <sup>1</sup>Essen/DE, <sup>2</sup>Bonn/DE, <sup>3</sup>Monterrey/MX, <sup>4</sup>Buenos Aires/AR, <sup>5</sup>St. Pölten/AT, <sup>6</sup>Mexico/MX, <sup>7</sup>Mainz/DE, <sup>8</sup>Curitiba/BR, <sup>9</sup>Frankfurt/DE**B-415** 14:36**MR angiography with gadobenate dimeglumine (MultiHance): Results of multi-institutional phase III program**G. Pirovano<sup>1</sup>, M.A. Kirchin<sup>2</sup>, S. Thurnher<sup>3</sup>, G. Soulez<sup>4</sup>, N. Anzalone<sup>2</sup>, G. Schneider<sup>5</sup>, R. Iezzi<sup>6</sup>, G. Bongartz<sup>7</sup>, P. Douek<sup>8</sup>, S. Miller<sup>9</sup>; <sup>1</sup>Princeton, NJ/US, <sup>2</sup>Milan/IT, <sup>3</sup>Vienna/AT, <sup>4</sup>Montreal, QC/CA, <sup>5</sup>Homburg/Saar/DE, <sup>6</sup>Chieti/IT, <sup>7</sup>Basle/CH, <sup>8</sup>Lyon/FR, <sup>9</sup>Tuebingen/DE**B-416** 14:45**High resolution 4D-MRA of the brain using a centra keyhole approach**B. Tombach<sup>1</sup>, B. Buerke<sup>2</sup>, T. Allkemper<sup>2</sup>, T. Niederstadt<sup>2</sup>, D. Kooijmann<sup>3</sup>, R. Hoogeveen<sup>4</sup>, W. Heindel<sup>2</sup>; <sup>1</sup>Osnabrück/DE, <sup>2</sup>Münster/DE, <sup>3</sup>Hamburg/DE, <sup>4</sup>Best/NL



**B-417** 14:54

**Whole-body contrast-enhanced MR angiography with gadobenate dimeglumine: Evaluation of subclinical atherosclerotic burden in patients with steno-occlusive disease**

A. Napoli, M. Anzidei, B. Cavallo Marincola, C. Zini, P.L. Di Paolo, K. Lanciotti, C. Catalano, R. Passariello; *Rome/IT*

**B-418** 15:03

**High-resolution peripheral MRA featuring a new blood-pool contrast agent and venous signal suppression due to k-space segmentation**

S. Kinner<sup>1</sup>, M.O. Zenge<sup>2</sup>, F.M. Vogt<sup>1</sup>, M.E. Ladd<sup>1</sup>, J. Barkhausen<sup>1</sup>, H.H. Quick<sup>1</sup>; <sup>1</sup>Essen/DE, <sup>2</sup>Erlangen/DE

**B-419** 15:12

**Foot angiography in PAOD patients: Blood pool contrast media (Vasovist®) CE-MRA vs standard DSA**

S. Kos, C. Reisinger, A.L. Jacob, G. Bongartz, D. Bielecen; *Basle/CH*

**B-420** 15:21

**MR angiography in rabbits: Comparison of a new blood pool contrast agent with Dotarem®**

S. Kinner<sup>1</sup>, S. Maderwald<sup>1</sup>, N. Parol<sup>1</sup>, S.L. Göricke<sup>1</sup>, J. Albert<sup>1</sup>, C. Corot<sup>2</sup>, P. Robert<sup>2</sup>, J. Barkhausen<sup>1</sup>; <sup>1</sup>Essen/DE, <sup>2</sup>Aulnay sous Bois/FR

**14:00 - 15:30**

**Room N/0**

**Neuro**

**SS 711**

**Grey and white matter**

*Moderators: S.P. Morozov; Moscow/RU, Z. Patay; Memphis, TN/US*

**B-421** 14:00

**Voxel based morphometry and voxel based relaxometry in Parkinsonian variant of multiple system atrophy**

L.C. Tzarouhi, L.G. Astrakas, S. Konitsiotis, P.N. Margariti, S. Tsouli, M.I. Argyropoulou; *Ioannina/GR*

**B-422** 14:09



**Differentiation of idiopathic Parkinson's disease from multi system atrophy with routine MR imaging and diffusion weighted MR imaging**

A.A.A. Abdel Razeq, A. Elmongy, M. Hazem, W. Gabr; *Mansoura/EG*

**B-423** 14:18

**Changes of white matter in aging and early Alzheimer's disease detected by diffusion tensor imaging**

H. Ni<sup>1</sup>, V. Kavcic<sup>2</sup>, J. Zhong<sup>2</sup>, J. Qi<sup>1</sup>; <sup>1</sup>Tianjin/CN, <sup>2</sup>Rochester, NY/US

**B-424** 14:27



**The potential role of diffusion tensor MR imaging in assessing the differential diagnosis between mild cognitive impairment and Alzheimer's disease**

D.B. Parente, L.C.H. da Cruz Jr, E.L. Gasparetto, R.C. Domingues, T. Doring, R.S. Borges, R.C. Domingues; *Rio de Janeiro/BR*

**B-425** 14:36

**Proton MR spectroscopy and diffusion tensor imaging in the posterior cingulated regions of patients with Alzheimer's disease: A preliminary study**

B. Ding, H.-W. Ling, H. Zhang, W.-M. Chai, K.-M. Chen; *Shanghai/CN*

**B-426** 14:45**The role of diffusion tensor imaging (DTI) in the detection of white matter lesions in patients with mild cognitive impairment**

D. Sali<sup>1</sup>, D.A. Verganelakis<sup>2</sup>, J. Papatriantafyllou<sup>1</sup>, C. Karageorghiou<sup>1</sup>, T. Thomaidis<sup>1</sup>, E. Kapsalaki<sup>3</sup>, G. Hadjigeorgiou<sup>3</sup>, A. Papadimitriou<sup>3</sup>; <sup>1</sup>Athens/GR, <sup>2</sup>Halandri/GR, <sup>3</sup>Larissa/GR

**B-427** 14:54**Brain lesions in septic shock: A magnetic resonance imaging (MRI) study**

D. Mompoint, E. Kocheida, S. Mokhtari, M. Louvet, T. Sharshar, C.A. Vallée, R.Y. Carlier; *Garches/FR*

**B-428** 15:03**Posterior reversible encephalopathy syndrome: A preliminary study of the relationships between its cause, radiologic feature and clinical outcome**

B. Gao; *Yantai/CN*

**B-429** 15:12**Quantification of intracerebral GABA by 1H-MRS: How reproducible are results?**

W. Bogner<sup>1</sup>, S. Gruber<sup>1</sup>, A. Stadlbauer<sup>2</sup>, M. Doelken<sup>2</sup>, S. Trattng<sup>1</sup>, A. Doerfler<sup>2</sup>, H. Stefan<sup>2</sup>, T. Hammen<sup>2</sup>; <sup>1</sup>Vienna/AT, <sup>2</sup>Erlangen/DE

**B-430** 15:21**Brain metabolic changes in hypertensive patients: An MR spectroscopy study**

S. Torres del Rio, J.M. Garcia Santos, L.J. Fuentes, C. Antúnez, J.B. Vidal, G. Ortega, M.M. Antequera, J.G. Sevilla; *Murcia/ES*



---

**14:00 - 15:30****Room R1****Chest****SS 704****Pulmonary embolism**

*Moderators: A.P. Parkar; Bergen/NO, E.J. Stern; Seattle, WA/US*

**B-431** 14:00**The use of radio protective bismuth breast shields does not impair image quality in CT pulmonary angiogram examinations in adult females**

C.P.J. Murray; *Perth/AU*

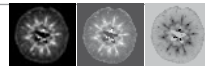
**B-432** 14:09**Comparative study on scintigraphic algorithms for the diagnosis of acute pulmonary thromboembolism based on computed tomographic pulmonary angiography: Multi-centre study for IAEA coordinated research project**

N. Watanabe<sup>1</sup>, N. Kucuk<sup>2</sup>, J. Fettich<sup>3</sup>, P. Choudhury<sup>4</sup>, F. Mut<sup>5</sup>, O. Kraft<sup>6</sup>, K. Endo<sup>7</sup>, S. Sharma<sup>8</sup>, M. Dondi<sup>1</sup>; <sup>1</sup>Vienna/AT, <sup>2</sup>Ankara/TR, <sup>3</sup>Ljubljana/SI, <sup>4</sup>Delhi/IN, <sup>5</sup>Montevideo/UY, <sup>6</sup>Ostrava/CZ, <sup>7</sup>Maebashi/JP, <sup>8</sup>New Delhi/IN

**B-433** 14:18**Computer-aided detection of acute pulmonary embolism with dual-source CT: Impact of the scanning conditions and overall image quality in the detection of peripheral clots**

M. Dewailly<sup>1</sup>, M. Rémy-Jardin<sup>1</sup>, J.-B. Faivre<sup>1</sup>, A.-M. Bakai<sup>2</sup>, V. Pansini<sup>1</sup>, J. Rémy<sup>1</sup>; <sup>1</sup>Lille/FR, <sup>2</sup>Forchheim/DE





**B-434** 14:27

**Incidence and radiological characteristics of falsely highlighted lesions using CAD to detect lung embolism**

A. Malich<sup>1</sup>, D. Henrich<sup>1</sup>, A. Ulrich<sup>1</sup>, P. Hannemann<sup>2</sup>, M. Ibe<sup>1</sup>, S. Mikulik<sup>1</sup>, A. Kott<sup>1</sup>, A. Hansch<sup>3</sup>; <sup>1</sup>Nordhausen/DE, <sup>2</sup>Neustadt/DE, <sup>3</sup>Jena/DE

**B-435** 14:36

**MDCT venography in patients with suspected pulmonary embolism: Diagnostic impact of pelvic veins evaluation in thromboembolic disease detection**

B. Feragalli, B. Seccia, V. Di Mizio, P. D'Ambrosio, R. Patea, M.L. Storto; *Chieti/IT*

**B-436** 14:45

**Unsuspected pulmonary emboli in oncology inpatients detected on chest multidetector computed tomography (MDCT): Influence of clinical data on disease prevalence**

L. Menchini, A. Larici, L. Calandriello, F. Maggi, M. Torge, L. Bonomo; *Rome/IT*

**B-437** 14:54

**Assessment of pulmonary perfusion defect with dual energy CT in acute pulmonary embolism and correlation with CT angiographic obstruction score and RV/LV diameter ratio**

J. Seo, Y. Jang, E. Chae, J. Song; *Seoul/KR*

**B-438** 15:03

**Lung perfusion with dual-energy multidetector-row CT (MDCT): Application to the management of acute pulmonary embolism**

F. Pontana<sup>1</sup>, J.-B. Faivre<sup>1</sup>, M. Rémy-Jardin<sup>1</sup>, T. Flohr<sup>2</sup>, V. Pansini<sup>1</sup>, J. Rémy<sup>1</sup>; <sup>1</sup>Lille/FR, <sup>2</sup>Forchheim/DE

**B-439** 15:12

**Dual-energy CTA of pulmonary embolism: Initial results**

C. Fink<sup>1</sup>, T.R. Johnson<sup>2</sup>, K. Nikolaou<sup>2</sup>, B. Krauss<sup>3</sup>, M. Sedlmair<sup>2</sup>, M.F. Reiser<sup>2</sup>, C. Becker<sup>2</sup>; <sup>1</sup>Mannheim/DE, <sup>2</sup>Munich/DE, <sup>3</sup>Forchheim/DE

**B-440** 15:21

**Dual source CT for chest pain assessment**

T.R.C. Johnson, C.R. Becker, A. Becker, C. Rist, M.F. Reiser, K. Nikolaou; *Munich/DE*

**14:00 - 15:30**

**Room R2**

**Cardiac**

**SS 703**

**CT/MR in cardiovascular risk assessment**

*Moderators: A. Bucker; Homburg a.d. Saar/DE, R. Vliegthart; Groningen/NL*

**B-441** 14:00

**NIMIS-CAD study: Influence of CAD risk, BMI, and coronary artery calcium deposits over the negative predictive value of MDCT in patients scheduled for coronary angiography**

F. De Cobelli<sup>1</sup>, R. Marano<sup>2</sup>, I. Florian<sup>1</sup>, T. Nimiscad Study Group<sup>1</sup>, L. Bonomo<sup>2</sup>, A. Del Maschio<sup>1</sup>; <sup>1</sup>Milan/IT, <sup>2</sup>Rome/IT

**B-442** 14:09

**Coronary calcium scoring in cardiac asymptomatic patients with peripheral arterial disease: Is it useful?**

A. Rutten<sup>1</sup>, A.M. de Vos<sup>1</sup>, H. van der Zaag<sup>2</sup>, F. Zijlstra<sup>2</sup>, B. Rensing<sup>3</sup>, A. Mosterd<sup>4</sup>, W.P.T.M. Mali<sup>1</sup>, M. Prokop<sup>1</sup>, M.L. Bots<sup>1</sup>, M. Oudkerk<sup>2</sup>; <sup>1</sup>Utrecht/NL, <sup>2</sup>Groningen/NL, <sup>3</sup>Nieuwegein/NL, <sup>4</sup>Amersfoort/NL

**B-443** 14:18**Predictive value of stenosis severity and atherosclerotic plaque burden at coronary CT angiography for major adverse cardiac events (MACE): A population based outcome study**

H.-R. Kim<sup>1</sup>, C. Thilo<sup>1</sup>, A. Flauaus<sup>1</sup>, B. Ruzsics<sup>1</sup>, H. Lee<sup>1</sup>, J.A. Abro<sup>1</sup>, S.A. Nguyen<sup>1</sup>, T.J. Vogl<sup>2</sup>, P. Costello<sup>1</sup>, U.J. Schoepf<sup>1</sup>; <sup>1</sup>Charleston, SC/US, <sup>2</sup>Frankfurt a. Main/DE

**B-444** 14:27**The relationship between coronary artery atherosclerosis evaluated by MDCT and carotid plaque by carotid ultrasound**

J.I. Jung, S.K. Yoon, Y.S. Choi, H.J. Yoon, S.T. Hahn; *Seoul/KR*

**B-445** 14:36**Plaque burden assessment with 64-slice computed tomography coronary angiography in diabetic patients compared with nondiabetic patients**

F. Cademartiri<sup>1</sup>, S. Seitun<sup>2</sup>, M. Romano<sup>2</sup>, G. Messalli<sup>3</sup>, S. Tresoldi<sup>4</sup>, E. Maffei<sup>1</sup>, A. Palumbo<sup>1</sup>, M. Fusaro<sup>1</sup>, N.R. Mollet<sup>5</sup>; <sup>1</sup>Parma/IT, <sup>2</sup>Genoa/IT, <sup>3</sup>Naples/IT, <sup>4</sup>Milan/IT, <sup>5</sup>Rotterdam/NL

**B-446** 14:45**Prognostic value of 64-slice coronary angiography in patients with diabetes mellitus with known or suspected coronary artery disease compared with nondiabetic population**

F. Cademartiri<sup>1</sup>, S. Seitun<sup>2</sup>, M. Romano<sup>2</sup>, S. Tresoldi<sup>3</sup>, G. Messalli<sup>4</sup>, E. Maffei<sup>1</sup>, A. Palumbo<sup>1</sup>, M. Fusaro<sup>1</sup>, N.R. Mollet<sup>5</sup>; <sup>1</sup>Parma/IT, <sup>2</sup>Genoa/IT, <sup>3</sup>Milan/IT, <sup>4</sup>Naples/IT, <sup>5</sup>Rotterdam/NL

**B-447** 14:54**Can MDCT be useful in diagnosing CHD in patients with low pre-test probability of disease?**

F. Cademartiri<sup>1</sup>, S. Tresoldi<sup>2</sup>, G. Messalli<sup>3</sup>, M. Romano<sup>4</sup>, S. Seitun<sup>4</sup>, E. Maffei<sup>1</sup>, A. Palumbo<sup>1</sup>, M. Fusaro<sup>1</sup>, N.R. Mollet<sup>5</sup>; <sup>1</sup>Parma/IT, <sup>2</sup>Milan/IT, <sup>3</sup>Naples/IT, <sup>4</sup>Genoa/IT, <sup>5</sup>Rotterdam/NL

**B-448** 15:03**Role of myocardial MR stress perfusion imaging in risk stratification of patients with intermediate grade coronary artery stenoses**

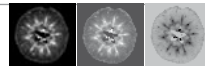
J.S. Döring, C. Dösch, A.H. Seeger, B. Klumpp, U. Kramer, M. Fenchel, A. May, C.D. Claussen, S. Miller; *Tübingen/DE*

**B-449** 15:12**Non-calcified atherosclerotic plaque burden at coronary CTA: A better predictor of ischemia at myocardial perfusion imaging than calcium score and stenosis severity**

R.W. Bauer<sup>1</sup>, C. Thilo<sup>2</sup>, S.A. Chiaramida<sup>2</sup>, T.J. Vogl<sup>1</sup>, P. Costello<sup>2</sup>, U.J. Schoepf<sup>2</sup>; <sup>1</sup>Frankfurt a. Main/DE, <sup>2</sup>Charleston, SC/US

**B-450** 15:21**Diagnostic accuracy of 64-slice computed tomography coronary angiography in patients with different pre-test-probabilities and prevalences of coronary artery disease**

L. Husmann, I. Valenta, P.T. Siegrist, O. Gaemperli, T. Schepis, H. Scheffel, P. Stolzmann, S. Leschka, H. Alkadhi, P.A. Kaufmann; *Zurich/CH*



**Interventional Radiology**

**SS 709b**

**Musculoskeletal intervention**

Moderators: M. Matson; London/UK, P. Reimer; Karlsruhe/DE

**B-451** 14:00

**Percutaneous fixation of unstable sacroiliac fractures in trauma patients using CT guidance**

M.G. Mack, B. Maier, J. Frank, K. Eichler, A. Thalhammer, F. Walcher, I. Marzi, T.J. Vogl; Frankfurt a. Main/DE

**B-452** 14:09

**Final results of combined intradiscal and periganglionic injection of medical ozone and periganglionic administration of steroids and anesthetic for the treatment of lumbar disk herniation: Effects on disk size and lumbar radiculopathy**

T. Lehnert<sup>1</sup>, F. Berg-Schlosser<sup>1</sup>, J.D. Balzer<sup>2</sup>, V. Jacobi<sup>1</sup>, M.G. Mack<sup>1</sup>, T.J. Vogl<sup>1</sup>; <sup>1</sup>Frankfurt a. Main/DE, <sup>2</sup>Mainz/DE

**B-453** 14:18

**Bipolar percutaneous radiofrequency ablation (RF) of osteoid osteomas**

M.G. Mack, K. Eichler, S. Zangos, T. Lehnert, D. Proschek, K. Hochmuth, T.J. Vogl; Frankfurt a. Main/DE

**B-454** 14:27

**Initial experience of concurrent image-guided intramuscular botulinum toxin injection in patients with idiopathic cervical dystonia**

Y. Yoon, I. Lee; Seoul/KR

**B-455** 14:36

**Osteoid osteoma of the spine: CT-guided radiofrequency ablation**

J. Martel, Á. Bueno, E.J. Ortiz; Alcorcón/ES

**B-456** 14:45



**Interventional radiology with transoral approach on the 2° cervical vertebra (C2): Result and complications in different pathologies on 15 patients**

G.C. Anselmetti, A. Manca, S. Cirillo, G. Chiara, F. Russo, D. Regge; Candiolo/IT

**B-457** 14:54

**Pedicle screw placement in trauma patients with unstable fractures of the thoracic spine using CT assistance**

M.G. Mack, B. Maier, C. Ploss, K. Eichler, J. Frank, I. Marzi, T.J. Vogl; Frankfurt a. Main/DE

**B-458** 15:03

**Long-term follow-up of arterial embolization of aneurismal bone cysts: A single center experience**

M. Cellneri, S. Mangiafico, G. Roselli, G. Beltrami, D. Campanacci, R. Capanna; Florence/IT

**B-459** 15:12

**Percutaneous echo-guided treatment of calcified tendonitis of the shoulder: Clinical response and radiological findings**

G. De Conti, U. Marchioro, A. Dorigo, F. Angelini; Padova/IT

**B-460** 15:21



**Guided removal of soft tissues foreign bodies: Personal experience**

L. Callegari, G. Sturniolo, A. Leonardi, D. Mariani, C. Sabato, E. Genovese, C. Fugazzola; Varese/IT

**10:30 - 12:00****Room B****Musculoskeletal****SS 1010****Osteoporosis and hip disorders**

Moderators: J.L. Bloem; Leiden/NL, A. Klauser; Innsbruck/AT

**B-461** 10:30**Diffusion weighted MRI and 1H-MR-spectroscopy at 3 T applied to patients with osteoporosis: Preliminary data supporting a new procedure to evaluate bone fracture risk**

S. Capuani, M. Rebuzzi, F. Fasano, G.H. Hagberg, B. Maraviglia; Rome/IT

**B-462** 10:39**MDCT evaluation of lumbar pedicles in osteoporotic spines**

A. Papadakis, A. Karantanas, G. Papadokostakis, A. Voloudaki, J. Damilakis, N. Gourtsoyiannis; Iraklion/GR

**B-463** 10:48**Automated trabecular bone structure analysis of the proximal femur: A comparison with BMD in assessment of osteoporosis**J.S. Bauer<sup>1</sup>, T. Baum<sup>1</sup>, M. Huber<sup>2</sup>, J. Carballido-Gamio<sup>2</sup>, D. Müller<sup>1</sup>, F. Eckstein<sup>3</sup>, T.M. Link<sup>2</sup>, E.J. Rummeny<sup>1</sup>; <sup>1</sup>Munich/DE, <sup>2</sup>San Francisco, CA/US, <sup>3</sup>Salzburg/AT**B-464** 10:57**Can routine abdominal multi-detector CT diagnose spinal osteoporosis?**

A. Papadakis, J. Damilakis, K. Perisinakis, A. Karantanas, N. Gourtsoyiannis; Iraklion/GR

**B-465** 11:06**Relationship between RANKL/OPG system and bone mineral density in children with inflammatory bowel disease: A DXA study**

C.V. Albanese, M. Paganelli, F. Civitelli, M. Osimani, R. Passariello; Rome/IT

**B-466** 11:15**Trabecular bone architecture of the calcaneus measured using nonlinear structure parameters: Comparison of high resolution MR imaging at 3.0 and 1.5 Tesla using noise simulations**J.S. Bauer<sup>1</sup>, D. Müller<sup>1</sup>, C. R ath<sup>2</sup>, R. Monetti<sup>2</sup>, M. Matsuura<sup>1</sup>, F. Eckstein<sup>3</sup>, T.M. Link<sup>4</sup>, E.J. Rummeny<sup>1</sup>; <sup>1</sup>Munich/DE, <sup>2</sup>Garching/DE, <sup>3</sup>Salzburg/AT, <sup>4</sup>San Francisco, CA/US**B-467** 11:24**Physical load-associated differences in femoral neck MRI texture**

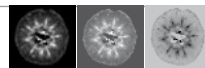
L.C.V. Harrison, R. Nikander, H. Siev anen, H. Eskola, P. Dastidar, S. Soimakallio; Tampere/FI

**B-468** 11:33**Line-scan diffusion MR imaging in ischemic epiphysis of femoral head: Experimental study**X. Li<sup>1</sup>, J. Qi<sup>1</sup>, L. Xia<sup>1</sup>, S. Maier<sup>2</sup>; <sup>1</sup>Wuhan/CN, <sup>2</sup>Boston, MA/US**B-469** 11:42**An abnormal vessel supply of an affected lower extremity in patients with proximal femoral focal deficiency**

M. Horak, Z. Ryznarova, M. Kaspar, M. Masek, J. Chomiak, M. Frydrychova; Prague/CZ

**B-470** 11:51**Herniation pits of the femoral neck: A radiographic indicator of femoroacetabular impingement?**

J.A. Kim, J.H. Choi, J.S. Park, W. Jin, K.N. Ryu; Seoul/KR



**GI Tract**

**SS 1001b**

**CT colonography**

Moderators: E. Neri; Pisa/IT, S. Somers; Dundas, ON/CA

**B-471** 10:30

**CT colonography with limited bowel preparation: Diagnostic performance in a FOBT positive screening population**

M.H. Liedenbaum<sup>1</sup>, A.F. van Rijn<sup>1</sup>, A.H. de Vries<sup>1</sup>, H.M. Dekker<sup>2</sup>, P. Fockens<sup>1</sup>, E. Dekker<sup>1</sup>, J. Stoker<sup>1</sup>; <sup>1</sup>Amsterdam/NL, <sup>2</sup>Nijmegen/NL

**B-472** 10:39

**Prospective comparison of colonoscopy, CT colonography, and stool tests in an average risk population: Results from the Munich colorectal cancer prevention trial**

A. Graser, P. Stieber, D. Nagel, C.R. Becker, H. Kramer, S. Geisbuesch, C. Schaefer, H. Diepolder, A. Lottes, A. Wagner, M.F. Reiser, B. Goeke, F.T. Kolligs; *Munich/DE*

**B-473** 10:48

**Screening CT colonography in an asymptomatic average-risk Asian population: A two-year experience in a single institution**

S. An<sup>1</sup>, K. Lee<sup>2</sup>, Y. Kim<sup>2</sup>, S. Park<sup>1</sup>, H. Kim<sup>2</sup>, S. Kim<sup>2</sup>, S. Kim<sup>1</sup>, N. Kim<sup>2</sup>; <sup>1</sup>Seoul/KR, <sup>2</sup>Seongnam-si/KR

**B-474** 10:57



**Evaluation of potential advantages of computer-aided diagnosis (CAD) in reporting CT colonography with a primary 2D approach**

R. Ferrari, M. Rengo, P. Paolantonio, F. Iafrate, P. Lucchesi, C. De Cecco, A. Laghi; *Rome/IT*

**B-475** 11:06



**Evaluation of computer-aided detection for CT colonography with multiple bowel preparation regimens**

J. Nappi<sup>1</sup>, H. Yoshida<sup>1</sup>, P. Lefere<sup>2</sup>, W. Cai<sup>1</sup>, M.E. Zalis<sup>1</sup>; <sup>1</sup>Boston, MA/US, <sup>2</sup>Roeselare/BE

**B-476** 11:15

**Evaluation of a prototype colon CAD system on polyps submerged in tagged material**

S. Lakare, M. Wolf, M. Dundar, L. Bogoni, M. Salganicoff; *Malvern, PA/US*

**B-477** 11:24

**CT colonography: Computer-aided detection of morphologically flat early (T1) colonic carcinoma**

S.A. Taylor<sup>1</sup>, G. Iinuma<sup>2</sup>, J. Zhang<sup>3</sup>, S. Halligan<sup>1</sup>; <sup>1</sup>London/UK, <sup>2</sup>Tokyo/JP, <sup>3</sup>Beijing/CN

**B-478** 11:33

**Performance analysis of a CAD system on flat, sessile, and pedunculated polyps**

M. Wolf, S. Lakare, M. Dundar, L. Bogoni, M. Salganicoff; *Malvern, PA/US*

**B-479** 11:42

**Comparative performance assessment of CAD and unaided human reading in multicenter clinical trials of CT colonography**

H. Yoshida<sup>1</sup>, J. Nappi<sup>1</sup>, D.C. Rockey<sup>2</sup>, R. Choi<sup>3</sup>, M. Zalis<sup>1</sup>, A.K. Singh<sup>1</sup>; <sup>1</sup>Boston, MA/US, <sup>2</sup>Dallas, TX/US, <sup>3</sup>Washington D.C., AE/US

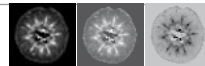
**B-480** 11:51

**CT colonography and computer-aided detection: Effect of false positives on reader specificity and reading efficiency in a low prevalence screening population**

S.A. Taylor<sup>1</sup>, R. Greenhalgh<sup>1</sup>, R. Ilangovan<sup>2</sup>, E. Tam<sup>2</sup>, V.A. Sahni<sup>2</sup>, D. Burling<sup>2</sup>, J. Zhang<sup>3</sup>, P. Pickhardt<sup>4</sup>, S. Halligan<sup>1</sup>; <sup>1</sup>London/UK, <sup>2</sup>Harrow/UK, <sup>3</sup>Beijing/UK, <sup>4</sup>Madison, WI/US

SUNDAY

**10:30 - 12:00****Room F1****Genitourinary****SS 1007****Imaging of the urinary tract: Do new techniques give new answers?***Moderators: J.J. Fütterer; Nijmegen/NL, S. Hanna; Cairo/EG***B-481** 10:30**ESUR CT urography practice guidelines 2008: The latest**A.J. van der Molen<sup>1</sup>, N.C. Cowan<sup>2</sup>, U.G. Mueller-Lisse<sup>3</sup>, C.C.A. Nolte-Ernsting<sup>4</sup>, S. Takahashi<sup>5</sup>, R.H. Cohan<sup>6</sup>, C.T.U. Working Group of the ESUR<sup>1</sup>; <sup>1</sup>Leiden/NL, <sup>2</sup>Oxford/UK, <sup>3</sup>Munich/DE, <sup>4</sup>Hamburg/DE, <sup>5</sup>Nijmegen/NL, <sup>6</sup>Ann Arbor, MI/US**B-482** 10:39**Influence of bladder distension on opacification of urinary collecting system during CT urography**B. Brkljacic, J. Curic, M. Vukelic-Markovic, P. Marusic, A. Hrkac-Pustahija; *Zagreb/HR***B-483** 10:48**Contrast-enhanced dual-energy computed tomography for detection of urinary stone disease**H. Scheffel, P. Stolzmann, T. Frauenfelder, T. Schertler, L. Desbiolles, S. Leschka, B. Marincek, H. Alkadhi; *Zurich/CH***B-484** 10:57**Differentiation of uric acid stones using dual-energy computed tomography: An ex-vivo evaluation**P. Stolzmann, H. Scheffel, K. Rentsch, T. Schertler, T. Frauenfelder, S. Leschka, T. Sulser, B. Marincek, H. Alkadhi; *Zurich/CH***B-485** 11:06**Monitoring response to treatment after acute ureteral obstruction by functional magnetic resonance imaging**H.C. Thoeny, T.M. Kessler, S.C. Simon-Zoula, T. Binser, U.E. Studer, P. Vermathen; *Berne/CH***B-486** 11:15**Intraindividual comparison of image quality in MR-urography at 1.5 and 3 Tesla using an animal model**M. Regier, C. Nolte-Ernsting, G. Adam, J. Kemper; *Hamburg/DE***B-487** 11:24**Excretory MR-urography at 1.5 and 3 Tesla: Comparison with MDCT-urography**M. Regier, C. Nolte-Ernsting, G. Adam, J. Kemper; *Hamburg/DE***B-488** 11:33**Age dependence of T1 perfusion MRI based hemodynamic parameters in normal human kidneys**M.I. Dujardin<sup>1</sup>, R. Luybaert<sup>1</sup>, P. Van der Niepen<sup>1</sup>, S. Sourbron<sup>2</sup>, D. Verbeelen<sup>1</sup>, T. Stadnik<sup>1</sup>, J. de Mey<sup>1</sup>; <sup>1</sup>Brussels/BE, <sup>2</sup>Munich/DE**B-489** 11:42**Feasibility of intraluminal optical coherence tomography of the human upper urinary tract in vivo: Preliminary experience**U.L. Mueller-Lisse, M. Bader, Y. Hocaoglu, M. Pühls, C.G. Stief, M.F. Reiser, U.G. Mueller-Lisse; *Munich/DE***B-490** 11:51**Can dual energy virtually unenhanced images replace non contrast scans in patients with renal masses?**A. Graser, T.R.C. Johnson, M. Staehler, C.G. Stief, M.F. Reiser, K. Nikolaou, C.R. Becker; *Munich/DE*



**Breast**

**SS 1002**

**MR: New clinical findings**

Moderators: R.A. Jong; Toronto, ON/CA, J. Veltman; Nijmegen/NL

**B-491** 10:30

**Analysis of fluid in MR-mammography: What kind of additional information can the T2-weighted sequences provide?**  
D.M. Renz, P.A.T. Baltzer, M. Herold, A.B. Herzog, M. Dietzel, M. Gajda, O. Camara, W.A. Kaiser; Jena/DE

**B-492** 10:39

**Role of magnetic resonance mammography to detect DCIS-associated invasive component underestimated at percutaneous biopsy**  
N. Martini, V. Londero, A. Dal Col, M. Bazzocchi, C. Zuiani; Udine/IT

**B-493** 10:48

**The adjacent-vessel-sign in MR-mammography: New data from a study of 366 cases**  
M. Dietzel, P.A.T. Baltzer, D.M. Renz, A.B. Herzog, M. Gajda, O. Camara, W.A. Kaiser; Jena/DE

**B-494** 10:57

**Ductal carcinoma in-situ (DCIS): Symmetric or asymmetric whole breast vascularity on contrast-enhanced MR imaging (CE-MRI)? A multicenter study**  
F. Sardanelli<sup>1</sup>, G. Di Leo<sup>1</sup>, A. Fausto<sup>1</sup>, A. Esseridou<sup>1</sup>, C. Zuiani<sup>2</sup>, S. Corcione<sup>3</sup>, E. Zanon<sup>4</sup>, M. Calabrese<sup>5</sup>, L. Preda<sup>1</sup>, J. Noni<sup>6</sup>, G. Valeri<sup>7</sup>, G. Rescinito<sup>5</sup>, A. Pecchi<sup>8</sup>, L. Pescarini<sup>9</sup>, M. Bazzocchi<sup>1</sup>; <sup>1</sup>Milan/IT, <sup>2</sup>Udine/IT, <sup>3</sup>Ferrara/IT, <sup>4</sup>Turin/IT, <sup>5</sup>Genoa/IT, <sup>6</sup>Firenze/IT, <sup>7</sup>Ancona/IT, <sup>8</sup>Modena/IT, <sup>9</sup>Padova/IT

**B-495** 11:06

**Magnetic resonance in the evaluation of pure ductal carcinoma in situ of the breast**  
M. Forment Navarro, J. Camps Herrero, V. Ricart Selma, J. Cano Gimeno, A. Caño Gómez, A. Escobar Hoyos, C. Martínez Rubio, A. Torregrosa Andres; Alzira/ES

**B-496** 11:15

**Inflammatory breast carcinoma in MR-mammography: Characteristic findings for dynamic and morphological parameters in comparison with locally advanced breast cancer**  
D.M. Renz, P.A.T. Baltzer, J. Böttcher, S.O.R. Pfeleiderer, M. Gajda, O. Camara, W.A. Kaiser; Jena/DE

**B-497** 11:24

**The evaluation of the characteristic findings of ductal carcinoma in situ on delayed contrast-enhanced coronal images with fat-suppression of MRI**  
S. Kobayashi, H. Sugimoto; Shimotsuke/JP

**B-498** 11:33

**Feasibility of T2-weighted sequences in the differential diagnosis of mass-like enhancements at magnetic resonance imaging of the breast**  
L. Ballesio, S. Savelli, M. Angeletti, I. D'Ambrosio, A. Francioso, C. De Felice, L. Manganaro; Rome/IT

**B-499** 11:42

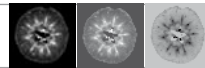
**Breast lesions: Correlation of contrast medium enhancement parameters with histopathologic findings and tumor angiogenesis**  
F.-H. Li; Shanghai/CN



SUNDAY

**B-500** 11:51**Does the destroyed ligament sign provide further information for differential diagnosis in MR-mammography?**M. Dietzel, P.A.T. Baltzer, A.B. Herzog, M. Gajda, D.M. Renz, O. Camara, W.A. Kaiser; *Jena/DE***10:30 - 12:00****Room G/H****Computer Applications****SS 1005****Radiological reporting and teaching***Moderators: G. Pärtan; Vienna/AT, G. Turóczy; Budapest/HU***B-501** 10:30**Evaluating the impact of voice-recognition reporting on radiology training**V. Shah, J.L. Hart, D. Blunt; *London/UK***B-502** 10:39**Cross language interpretation of spine imaging based on structured reporting**M. Fatehi<sup>1</sup>, S. Akhlaghpour<sup>1</sup>, A. Arjmand Shabestari<sup>1</sup>, M. Bagheri<sup>2</sup>, A. Marashi<sup>3</sup>, A. Poli<sup>4</sup>, H. Alizadeh<sup>1</sup>; <sup>1</sup>Tehran/IR, <sup>2</sup>Shiraz/IR, <sup>3</sup>Darmstadt/DE, <sup>4</sup>Trieste/IT**B-503** 10:48**Added value of structured reporting for ePACS concept: A model for lung HRCT interpretation**M. Fatehi<sup>1</sup>, A. Arjmand Shabestari<sup>1</sup>, S. Akhlaghpour<sup>1</sup>, M. Bagheri<sup>2</sup>, K. Yazdanifard<sup>1</sup>; <sup>1</sup>Tehran/IR, <sup>2</sup>Shiraz/IR**B-504** 10:57**Virtual anatomy enabled by high resolution computed tomography and magnetic resonance imaging and post processing tools: A new way of teaching and learning?**F.L. Giesel<sup>1</sup>, S. Doll<sup>1</sup>, J. Mews<sup>2</sup>, A. Mehndiratta<sup>1</sup>, H. von Tengg-Kobligk<sup>1</sup>, M. Owsijewitsch<sup>1</sup>, J. Kirsch<sup>1</sup>, H.-U. Kauczor<sup>1</sup>; <sup>1</sup>Heidelberg/DE, <sup>2</sup>Neuss/DE**B-505** 11:06**The multimedia, virtual MR imaging department**P.B. Marthinsen<sup>1</sup>, J. Hald<sup>1</sup>, R. Bergstrøm<sup>2</sup>, J. Jakobsen<sup>1</sup>, D. Christensen<sup>1</sup>, H. Roterud<sup>1</sup>, F. Lærum<sup>1</sup>; <sup>1</sup>Oslo/NO, <sup>2</sup>Trondheim/NO**B-506** 11:15**Podcasts for radiology teaching: Initial experience**E.E.J.G. Coche, P. Meurrens; *Brussels/BE***B-507** 11:24**Seamless integration of the radiological teaching database MIRC with PACS clients according to IHE TCE**C.M. Ahlers, K. Wunder, J. Schneider, C. Düber, P. Mildenerger; *Mainz/DE***B-508** 11:33**Tele-medicine and tele-collaboration: How MDCT is changing the rules of the workflow game**H.E. Gregersen; *Aalborg/DK***B-509** 11:42**Singapore-India teleradiology link: Our experience in the primary health care setting**A. Kalyanpur<sup>1</sup>, N. Sreenivasan<sup>1</sup>, J. Singh<sup>1</sup>, L. Tan<sup>2</sup>, T. Goh<sup>2</sup>; <sup>1</sup>Bangalore/IN, <sup>2</sup>Singapore/SG





**B-510** 11:51

**Are mobile home-radiology workplaces as good as fixed radiology workplaces? Analysis after one year of experience**  
P.F.W. Soegner; R. Frank, A. Klausner, H. Zunterer, C. Cihak, F. Koppelstaetter, D. zur Nedden;  
*Innsbruck/AT*

**10:30 - 12:00**

**Room I**

**Physics in Radiology**

**SS 1013**

**Dose, risk assessment and optimisation**

*Moderators: F.R. Verdun; Lausanne/CH, U. Zdesar; Ljubljana/SI*

**B-511** 10:30

**A comprehensive risk assessment method in diagnostic X-ray imaging by means of multiple-decrement life tables**  
J. Geleijns<sup>1</sup>, M. Dewey<sup>2</sup>, J. Kievit<sup>1</sup>, J. Sont<sup>1</sup>, Y.L. O<sup>1</sup>; <sup>1</sup>Leiden/NL, <sup>2</sup>Berlin/DE

**B-512** 10:39

**Dedicated breast CT at the same exposure level as two-view mammography: Influence of detector pixel size and focal spot size on image quality**  
S.V. Vollmar, W.A. Kalender; *Erlangen/DE*

**B-513** 10:48

**Usefulness of computed tomography dose index (CTDI) and practical dosimetry for flat-detector CT**  
Y. Kyriakou, P. Deak, O. Langner, W.A. Kalender; *Erlangen/DE*

**B-514** 10:57

**Real-time capability of an optimal reconstruction phase determination during cardiac CT scanning**  
D. Ertel<sup>1</sup>, T. Pflederer<sup>1</sup>, S. Ertel<sup>2</sup>, S. Achenbach<sup>1</sup>, W.A. Kalender<sup>1</sup>; <sup>1</sup>Erlangen/DE, <sup>2</sup>Bayreuth/DE

**B-515** 11:06

**Measured and calculated tissue air ratios in CT**  
W. Huda<sup>1</sup>, K.M. Ogden<sup>2</sup>, S. Edyvean<sup>3</sup>, D.G. Frey<sup>1</sup>; <sup>1</sup>Charleston, SC/US, <sup>2</sup>Syracuse, NY/US, <sup>3</sup>London/UK

**B-516** 11:15

**Measuring blood flow speed in CT raw data**  
S. Prevrhal, J. Rinkel, B. Yeh, J. Leach, R.S. Gould; *San Francisco, CA/US*

**B-517** 11:24

**Reduction of dose to the female breast as a side-effect of spectral optimization for thoracic CT**  
S.V. Vollmar, W.A. Kalender; *Erlangen/DE*

**B-518** 11:33

**Clinical applications of dual energy CT**  
T.R.C. Johnson, A. Graser, D. Morhard, C. Fink, H. Michaely, S. Weckbach, M. Sedlmair, M.F. Reiser, C.R. Becker; *Munich/DE*

**B-519** 11:42



**Quality control and dose optimisations for computed radiography: A five year experience in Luxembourg**  
A. Schreiner, A. Jahnen, M. Grelot, C. Bokou, D. Kaphammel, C. Back; *Luxembourg/LU*

**B-520** 11:51

**Kerma-area products (KAP) in head CT**

 W. Huda<sup>1</sup>, K.M. Ogden<sup>2</sup>, Z. Rumboldt<sup>1</sup>, R. Coursey<sup>1</sup>; <sup>1</sup>Charleston, SC/US, <sup>2</sup>Syracuse, NY/US

**10:30 - 12:00**
**Room K**
**Pediatric**
**SS 1012**
**Chest and abdomen**
*Moderators: A. Paterson; Belfast/UK, B. Silberman; Paris/FR*
**B-521** 10:30

**Outcome after mechanical aortic valve replacement in children and adolescents: Long term results evaluated by echocardiography and magnetic resonance tomography**

 J. Ley-Zaporozhan<sup>1</sup>, R. Arnold<sup>2</sup>, S. Ley<sup>1</sup>, T. Loukanov<sup>1</sup>, C. Sebening<sup>1</sup>, J.-B. Kleber<sup>1</sup>, M. Gorenflo<sup>1</sup>, H.-U. Kauczor<sup>1</sup>; <sup>1</sup>Heidelberg/DE, <sup>2</sup>Freiburg/DE

**B-522** 10:39

**Role of contrast enhanced MR angiography of pulmonary artery in patients with pulmonary atresia**

A.A.A. Abdel Razek, G. Gaballa, H. Almarsafawy; Mansoura/EG

**B-523** 10:48

**The importance of DSCT in the diagnosis of congenital heart disease**

X.-M. Wang, L.-B. Wu, C. Sun, C. Liu; Jinan/CN


**B-524** 10:57

**Chest tuberculosis in children: CT findings in active and post-treatment cases**

R. Gupta, A.K. Gupta, A. Seith, S. Kabra, M. Gupta; Delhi/IN

**B-525** 11:06

**Usefulness of 64-slice MDCT for follow-up of young children with coronary artery aneurysm due to Kawasaki disease: Initial experience**

Y. Peng, J. Zeng; Beijing/CN

**B-526** 11:15

**Tumour volume doubling times of paediatric metastatic pulmonary nodules**

E.J. Helm, L. Vidarsson, P.S. Babyn; Toronto, ON/CA

**B-527** 11:24

**Contrast enhanced ultrasound in children with blunt abdominal trauma: Diagnostic performance**

M. Valentino, L. Barozzi, P. Pavlica, M. Lima, S. Baroncini; Bologna/IT

**B-528** 11:33

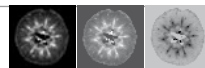
**Role of diffusion-weighted MR imaging in quantification of hepatic fibrosis in pediatric patients with chronic hepatitis**

A.A.A. Abdel Razek, A. Abdalla, E. Omran, K. Zalata; Mansoura/EG

**B-529** 11:42

**Color Doppler imaging of the liver in the neonates with biliary atresia**

M. Lee, M.-J. Kim, C. Yoon, S. Han, J. Oh, Y. Park; Seoul/KR



**B-530** 11:51

**The use of dynamic MR renography for the evaluation of congenital urinary tract dilatation**

A.Y. Kandeel<sup>1</sup>, M. Bazeed<sup>1</sup>, W. Abd Elghaffar<sup>1</sup>, A. Mohamram<sup>2</sup>, S. El Halwagy<sup>1</sup>; <sup>1</sup>Mansoura/EG, <sup>2</sup>Cairo/EG

**10:30 - 12:00**

**Room L/M**

**Radiographers**

**SS 1014**

**Development of the professional role**

*Moderators: L. Dalla Palma; Trieste/IT, I.-H. Tassiopoulos; Athens/GR*

**B-531** 10:30

**Routine T2 relaxometry measurement by MR radiographers**

G. Darwent, D.A. Capener, R.A. Grunewald, L.I. Wallis, N. Hoggard, P.D. Griffiths, I.D. Wilkinson; *Sheffield/UK*

**B-532** 10:39



**Radiographers' role in the development of MR-guided transperineal brachytherapy protocol**

C. Vandulek, F. Lakosi, G. Antal, O. Petnehazy, P. Bogner, J. Hadjiev, I. Repa; *Kaposvar/HU*

**B-533** 10:48

**Commenting on trauma radiographs: Developing and formalising the radiographer's role**

M. Hardy<sup>1</sup>, B. Snaith<sup>2</sup>; <sup>1</sup>Bradford/UK, <sup>2</sup>Wakefield/UK

**B-534** 10:57

**Cranial computed tomography reporting by radiographers: The impact on service delivery and professional development**

L.M. Clarkson; *Bradford/UK*

**B-535** 11:06

**Radiographer reporting in the UK: Education to support changes in radiographer roles and responsibilities**

M. Hardy<sup>1</sup>, B. Snaith<sup>2</sup>; <sup>1</sup>Bradford/UK, <sup>2</sup>Wakefield/UK

**B-536** 11:15

**PGMI classification of full-field digital mammograms in the Norwegian population-based breast cancer screening program according to the radiographers' experience**

R. Gullien, A.E. Haakull, J.G. Andersen, P. Skaane, E. Rostad; *Oslo/NO*

**B-537** 11:24

**Findings from a community based study on radiological procedures for people with cancer**

S.A. Mathers, R.A. Chesson, G.A. McKenzie, E.M. Robertson; *Aberdeen/UK*

**B-538** 11:33

**Retrospective analysis of radiographer QA in digital chest radiography**

W.J. Sehnert<sup>1</sup>, D.H. Fooks<sup>1</sup>, B. Reiner<sup>2</sup>, E. Siegel<sup>2</sup>; <sup>1</sup>Rochester, NY/US, <sup>2</sup>Baltimore, MD/US

**B-539** 11:42

**Emergency department workflow: Portable vs. stationary digital radiography**

A. Scherrer, E. Mathieu; *Suresnes/FR*

**B-540** 11:51

**Technical feasibility of 18F-FDG PET/CT with integrated CT-perfusion**

 T. Berthold, S. Knöfel, M. de Bloeme, M. Leuze, P. Veit-Haibach, V. Treyer; *Zurich/CH*
**10:30 - 12:00**
**Room N/O**
**Neuro**
**SS 1011**
**Functional MRI**
*Moderators: B. Góraj; Nijmegen/NL, S. Sunaert; Leuven/BE*
**B-541** 10:30

**Detailed fMRI investigation of multiple cognitive domains in patients with amnesic MCI**

 D. Lenzi<sup>1</sup>, L. Serra<sup>1</sup>, P. Pantano<sup>1</sup>, E. Paulesu<sup>2</sup>, F. Giubilei<sup>1</sup>, R. Perri<sup>1</sup>, G. Lenzi<sup>1</sup>, C. Caltagirone<sup>1</sup>, E. Macaluso<sup>1</sup>, M. Bozzali<sup>1</sup>; <sup>1</sup>Rome/IT, <sup>2</sup>Milan/IT

**B-542** 10:39

**Brain spatial characteristics of human numerical inductive reasoning process: An fMRI study**

 Y. Yang, K. Li, P. Liang, N. Zhong, S. Lu; *Beijing/CN*
**B-543** 10:48

**Neurocognitive processing of socially relevant negative emotions: An fMRI study**

 S. Modi, S. Khushu, M. Bhattacharya, S.B. Raj, M.K. Mandal; *Delhi/IN*
**B-544** 10:57

**Functional magnetic resonance imaging study investigating mechanisms of memory suppression in stress-related psychiatric disorders: Preliminary results**

 N. Agarwal, G. Como, P. Brambilla, M. Baiano, M. Maieron, M. Balestrieri, L. Perini, R. Zuliani, R. Ciano, M. Bazzocchi; *Udine/IT*
**B-545** 11:06

**The study of functional MRI in first episode depressed patients with reversible affective defect**

 H. Liu, X. Feng, J. Sun; *Shanghai/CN*
**B-546** 11:15

**Assessment of visuospatial symmetry judgment deficit in alcohol dependants through fMRI and voxel based morphometry**

 R.P. Tripathi, M. Bhattacharya, S. Modi, M. Devi, S.N. Deshpande, S. Khushu; *Delhi/IN*
**B-547** 11:24

**Functional neuroimaging in treatment evaluation of "malignant" anxiety-obsessive disorders (AOD)**

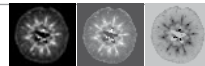
 A.A. Stanzhevsky, A.V. Korzenev, L. Tyutin, A. Pozdnyakov, V.K. Shamrey, R.A. Shalek; *St. Petersburg/RU*
**B-548** 11:33

**A direct demonstration of both structure and function of motor and sensor after hemispherectomy combining diffusion tensor imaging with functional magnetic resonance imaging**

 J. Qu, S. Li, J. Dai, X. Zhang; *Beijing/CN*
**B-549** 11:42

**The pre- and post-operative assessment of SM1 area in patients with brain tumor using DTI and FMRI on a 3.0T MRI scanner**

 E.J. Lin, Q.F. Meng, L.J. Mao, B.N. Luo; *GuangZhou/CN*



**B-550** 11:51

**Motor related brain activity in the restless legs syndrome**

L.G. Astrakas, P.N. Margariti, S. Konitsiotis, S. Tsouli, L.C. Tzarouhi, M.I. Argyropoulou; *Ioannina/GR*

**10:30 - 12:00**

**Room R2**

**Cardiac**

**SS 1003**

**Myocardial and pericardial diseases**

*Moderators: Z.M. Metafratzi; Ioannina/GR, D. Piotrowska-Kownacka; Warsaw/PL*

**B-551** 10:30

**Variables associated with gadolinium-enhanced cardiovascular magnetic resonance in hypertrophic cardiomyopathy**

E. Feliu<sup>1</sup>, F. Marín<sup>2</sup>, J. González-Carrillo<sup>2</sup>, E. Payá<sup>1</sup>, V. Climent<sup>1</sup>, V. Roldán<sup>2</sup>, I. Al-Assir<sup>1</sup>; <sup>1</sup>*Alicante/ES*, <sup>2</sup>*Murcia/ES*

**B-552** 10:39

**Value of cardiac magnetic resonance imaging in patients with suspected acute myocarditis with a follow-up period of 1 year**

K.-F. Kreitner, K. Koch, F. Steyns, N. Abegunewardene, M. Todt, G. Horstick, C. Dueber; *Mainz/DE*

**B-553** 10:48

**Systemic sclerosis: Detection of myocardial fibrosis by contrast-enhanced magnetic resonance imaging**

F. Breuckmann<sup>1</sup>, K. Nassenstein<sup>1</sup>, A. Kreuter<sup>2</sup>, P. Altmeyer<sup>2</sup>, R. Erbel<sup>1</sup>, J. Barkhausen<sup>1</sup>; <sup>1</sup>*Essen/DE*, <sup>2</sup>*Bochum/DE*

**B-554** 10:57

**Role of coronary MR angiography as a non-invasive imaging modality for sequential follow-up of a paediatric population with Kawasaki disease**

I. Carbone, E. Algeri, H. Grazhdani, F. Ciolina, M. Basood, N. Galea, C. Catalano, R. Passariello; *Rome/IT*

**B-555** 11:06

**Isolated left ventricular noncompaction: MRI findings**

P. Klimczek, R. Banys, M. Pasowicz; *Krakow/PL*

**B-556** 11:15

**Dual-energy CT of the heart for coronary CTA and myocardial blood pool analysis: Initial experience**

B. Ruzsics<sup>1</sup>, P. Suranyi<sup>1</sup>, H. Lee<sup>1</sup>, S. Nguyen<sup>1</sup>, P. Zwerner<sup>1</sup>, T.G. Flohr<sup>2</sup>, P. Costello<sup>1</sup>, U.J. Schoepf<sup>1</sup>; <sup>1</sup>*Charleston, SC/US*, <sup>2</sup>*Tübingen/DE*

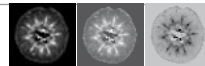
**B-557** 11:24

**Three dimensional cine MRI in infants and children with congenital heart disease**

M. Fenchel, A. Seeger, G.F. Greil, P. Martirosian, J. Doering, L. Sieverding, U. Kramer, B. Klumpp, C.D. Claussen, S. Miller; *Tübingen/DE*

**SUNDAY**

**B-558** 11:33**Cardiac magnetic resonance imaging of marathon runners in the elderly: Prevalence of myocardial late enhancement**F. Breuckmann, K. Nassenstein, B. Sievers, T. Schlosser, D. Kiefer, R. Erbel, S. Möhlenkamp, J. Barkhausen; *Essen/DE***B-559** 11:42**Differences in perfusion of malignant and benign cardiac tumors**K.U. Bauner, S. Sourbron, M. Schmoedel, M.F. Reiser, A.M. Huber; *Munich/DE***B-560** 11:51**Myocardial late gadolinium enhancement cardiovascular magnetic resonance in the assessment of exercise capacity in hypertrophic cardiomyopathy**E. Feliu<sup>1</sup>, F. Marin<sup>2</sup>, J. Gonzalez-Carrillo<sup>2</sup>, A. Garcia-Honrubia<sup>1</sup>, M. Garcia-Carbonell<sup>1</sup>, S. López-Celada<sup>1</sup>; <sup>1</sup>Alicante/ES, <sup>2</sup>Murcia/ES**10:30 - 12:00****Room R3****Interventional Radiology****SS 1009****Abdomen and pelvis***Moderators: S. Fabiano; Rome/IT, H.-M. Hoogewoud; Fribourg/CH***B-561** 10:30**ePTFE/FEP-covered metallic stents versus uncovered mesh stents for palliation of malignant jaundice due to cholangiocarcinoma. Clinical results in 50 patients**M. Krokidis<sup>1</sup>, F. Fanelli<sup>2</sup>, A. Hatzidakis<sup>1</sup>, G. Orgera<sup>2</sup>, M. Bezzi<sup>2</sup>, N. Gourtsoyannis<sup>1</sup>, R. Passariello<sup>2</sup>; <sup>1</sup>Iraklion/GR, <sup>2</sup>Rome/IT**B-562** 10:39**Whole liver drainage versus partial liver drainage: A survival analysis of patients with malignant biliary strictures treated by percutaneous metallic stenting**N. Ptohis, E. Brountzos, I. Panagiotou, K. Malagari, E. Alexopoulou, A. Kelekis, N. Kelekis, A. Gouliamos; *Athens/GR***B-563** 10:48**Malignant biliary strictures palliation: clinical results in 155 patients using e-PTFE covered metallic stents**G. Orgera<sup>1</sup>, F. Fanelli<sup>1</sup>, A. Hatzidakis<sup>2</sup>, M. Krokidis<sup>2</sup>, M. Bezzi<sup>1</sup>, R. Passariello<sup>1</sup>, N. Gourtsoyannis<sup>2</sup>; <sup>1</sup>Rome/IT, <sup>2</sup>Iraklion/GR**B-564** 10:57**Intrahepatic bile duct transection: Long-term follow-up of percutaneous transhepatic management**G. Orgera, F. Salvadori, F. Fanelli, G. Nardis, E. Boatta, P. Rabuffi, R. Passariello; *Rome/IT***B-565** 11:06**Percutaneous transluminal angioplasty and stent placement in patients with hepatic artery stenosis or thrombosis after liver transplantation**F. Boyvat<sup>1</sup>, A. Harman<sup>1</sup>, C. Aytakin<sup>1</sup>, B. Gümüş<sup>2</sup>, M. Haberal<sup>1</sup>; <sup>1</sup>Ankara/TR, <sup>2</sup>Istanbul/TR



**B-566** 11:15

**Hepatic encephalopathy in patients treated with e-PTFE covered stent-grafts: Initial results of a randomized trial of 8 mm versus 10 mm VIATORR stent-graft**

G. Orgera, F. Fanelli, G. Luppi, P. Nardis, M. Corona, M. Allegritti, R. Passariello; *Rome/IT*

**B-567** 11:24



**TIPS with e-PTFE-stentgrafts in patients with refractory ascites or recurrent variceal bleeding**

C. Schneider, S. Herber, G. Otto, J. Schattenberg, M. Schuchmann, K. Oberholzer, C. Düber, M.B. Pitton; *Mainz/DE*

**B-568** 11:33

**Endovascular treatment of vascular complications of acute pancreatitis: 6 year experience of a tertiary referral centre**

S. Athreya, N. Mathias, G. Roditi; *Glasgow/UK*

**B-569** 11:42

**Imaging of complications after percutaneous intrahepatic islet transplantation: Long-term monitoring after 112 transplants**

C. Losio, M. Venturini, A. Zanasi, P. Maffi, F. De Taddeo, R. Nano, A. Secchi, A. Del Maschio; *Milan/IT*

**B-570** 11:51

**Uterine fibroid embolization: First results from the Embozene™ microsphere study**

J. Kettenbach<sup>1</sup>, J. Moss<sup>2</sup>, L. Lampmann<sup>3</sup>, J. Falco-Fages<sup>4</sup>, R.W. Günther<sup>5</sup>, A. Rampoldi<sup>6</sup>, E.-P. Strecker<sup>7</sup>, F. Orsi<sup>8</sup>, T. Helmberger<sup>9</sup>, D. Vorwerk<sup>9</sup>, G.M. Richter<sup>10</sup>, J. Moyses<sup>1</sup>, J. Lammer<sup>1</sup>; <sup>1</sup>Vienna/AT, <sup>2</sup>Glasgow/UK, <sup>3</sup>Tilburg/NL, <sup>4</sup>Sabadell/ES, <sup>5</sup>Aachen/DE, <sup>6</sup>Milan/IT, <sup>7</sup>Karlsruhe/DE, <sup>8</sup>Munich/DE, <sup>9</sup>Ingolstadt/DE, <sup>10</sup>Heidelberg/DE

**10:30 - 12:00**

**Room A**

**Musculoskeletal**

**SS 1410**

**Cartilage**

*Moderators: M.A. Cova; Trieste/IT, V. Jevtic; Ljubljana/SI*

**B-571** 10:30

**Evaluation of biomechanical properties of articular cartilage with quantitative magnetic resonance imaging at two different field strengths**

X. Li, J. Qi, L. Xia, D. Hu; *Wuhan/CN*

**B-572** 10:39

**Regional measurements of T1 $\rho$  and T2 relaxation for detecting onset degeneration of articular cartilage**

Z. Zhou<sup>1</sup>, X. Zou<sup>1</sup>, S. Ringgaard<sup>1</sup>, H. Li<sup>1</sup>, L. Zou<sup>1</sup>, M. Bendtsen<sup>1</sup>, H. Stødtkilde-Jørgensen<sup>1</sup>, H. Shan<sup>2</sup>, C. Bünger<sup>1</sup>; <sup>1</sup>Aarhus/DK, <sup>2</sup>Guangzhou/CN

**B-573** 10:48

**Accuracy and precision of cartilage T2-relaxation time quantification: Impact of the fitting algorithm**

J.G. Raya, D. Dietrich, A. Horng, J. Dinges, M.F. Reiser, C. Glaser; *Munich/DE*

**B-574** 10:57

**4.7 T MR microimaging of single chondrocyte labeled with SP10**

X. Li, H. Li, J. Guo, J. Qi; *Wuhan/CN*

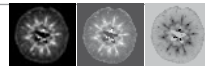
**SUNDAY**

**B-575** 11:06**Evaluation of repair cartilage after micro fracturing procedure using dGEMRIC and T2 mapping**A. Watanabe<sup>1</sup>, C. Boesch<sup>2</sup>, P.M. Varlet<sup>2</sup>, S.E. Anderson<sup>3</sup>; <sup>1</sup>Ichihara/JP, <sup>2</sup>Berne/CH, <sup>3</sup>Melbourne/AU**B-576** 11:15**Three-dimensional delayed gadolinium enhanced MRI of cartilage (dGEMRIC) at 3 Tesla for in vivo differentiation of normal hyaline cartilage and reparative tissue in patients after different cartilage repair procedures: Preliminary results**S. Trattinig<sup>1</sup>, T.C. Mamisch<sup>2</sup>, K. Pinker<sup>1</sup>, P. Szomolanyi<sup>1</sup>, S. Marlovits<sup>1</sup>, S. Kutscha-Lissberg<sup>1</sup>, G. Welsch<sup>1</sup>; <sup>1</sup>Vienna/AT, <sup>2</sup>Berne/CH**B-577** 11:24**3D GRE sequence with two different flip angle excitation pulses for zonal T1- mapping of articular cartilage at 3T: One-year follow-up in patients after matrix-associated autologous chondrocyte transplantation (MACT) of the knee joint**K. Pinker<sup>1</sup>, P. Szomolanyi<sup>2</sup>, G. Welsch<sup>1</sup>, T.C. Mamisch<sup>3</sup>, S. Marlovits<sup>1</sup>, S. Trattinig<sup>1</sup>; <sup>1</sup>Vienna/AT, <sup>2</sup>Bratislava/SK, <sup>3</sup>Berne/CH**B-578** 11:33**Collagenous fibre architecture of articular cartilage: Comparison between high field DTI and scanning electron microscopy**L. Filidoro<sup>1</sup>, D.L. Weber<sup>2</sup>, A.P. Arnoldi<sup>1</sup>, J. Weber<sup>1</sup>, J.G. Raya<sup>1</sup>, P.M. Jakob<sup>2</sup>, M.F. Reiser<sup>1</sup>, R. Putz<sup>1</sup>, E. Muetzel<sup>1</sup>, C. Glaser<sup>1</sup>; <sup>1</sup>Munich/DE, <sup>2</sup>Würzburg/DE**B-579** 11:42**Diffusion-weighted imaging of knee cartilage at 3.0T: Follow-up of patients after matrix-associated autologous chondrocyte transplantation**K.M. Friedrich<sup>1</sup>, C. Plank<sup>1</sup>, G. Welsch<sup>1</sup>, G. Langs<sup>1</sup>, E. Salomonowitz<sup>2</sup>, S. Trattinig<sup>1</sup>, T.C. Mamisch<sup>3</sup>; <sup>1</sup>Vienna/AT, <sup>2</sup>St. Poelten/AT, <sup>3</sup>Berne/CH**B-580** 11:51**T2-mapping versus diffusion-weighted imaging for the assessment of cartilage repair tissue after matrix-associated autologous chondrocyte transplantation at 3.0 T**C.M. Plank<sup>1</sup>, K. Friedrich<sup>1</sup>, G. Langs<sup>1</sup>, G.H. Welsch<sup>1</sup>, T.C. Mamisch<sup>2</sup>, S. Trattinig<sup>1</sup>; <sup>1</sup>Vienna/AT, <sup>2</sup>Berne/CH

---

**10:30 - 12:00****Room B****Abdominal Viscera (Solid Organs)****SS 1401a****Checking out the pancreato-biliary system***Moderators: P.E. Huppert; Darmstadt/DE, F. Takis; Keratea/GR***B-581** 10:30**Evaluation of potential living liver donor's biliary anatomy: Comparison of optimized high-resolution magnetic resonance cholangiography and contrast-enhanced multislice-CT cholangiography**S. Kinner, J. Barkhausen, A. Radtke, S. Lunkeit, C. Valentin-Gamazo, T. Schröder; Essen/DE**B-582** 10:39**MR differentiation between  $\geq$ T1b and  $\leq$ T1a lesions in early gallbladder carcinomas: Significance of "loss of low signal intensity" on T2 weighted HASTE images**S. Kim, J. Lee, J. Lee, S. Kim, J. Han, B. Choi; Seoul/KR





**B-583** 10:48

**MR imaging for diagnosing cystobiliary fistulas in cystic echinococcosis**

T. Heye<sup>1</sup>, M. Stojkovic<sup>1</sup>, T. Jänisch<sup>1</sup>, J. Werner<sup>1</sup>, H. Friess<sup>2</sup>, G.W. Kauffmann<sup>1</sup>, T. Junghans<sup>1</sup>, W. Hosch<sup>1</sup>; <sup>1</sup>Heidelberg/DE, <sup>2</sup>Munich/DE

**B-584** 10:57

**Quantitative assessment of pancreatic exocrine reserve, in patients with chronic pancreatitis, by means of MRCP during secretin stimulation, compared to fecal elastase-1**

R. Manfredi, S. Perandini, M. Motton, S. Mehrabi, W. Mantovani, R. Pozzi Mucelli; Verona/IT

**B-585** 11:06

**Asymptomatic serum hyperamylasemia and hyperlipasemia: Spectrum of findings on secretin-stimulated MRCP**

F. Donati, P. Boraschi, R. Gigoni, S. Salemi, M. Cossu, F. Falaschi, C. Bartolozzi; Pisa/IT

**B-586** 11:15

**CT patterns of autoimmune pancreatitis, and their changes after steroid treatment**

R. Manfredi, R. Graziani, C. Cicero, M. Motton, S. Mehrabi, R. Pozzi Mucelli; Verona/IT

**B-587** 11:24

**Evaluation of intra-papillary mucinous neoplasms by movies of CT pancreatogram images obtained around the duct as center axis: Can it help in characterization of IPMNs?**

A.K. Singh, W. Cai, D.V. Sahani, O. Catalano, G. Harris, H. Yoshida; Boston, MA/US

**B-588** 11:33

**Magnetic resonance imaging (MRI) and MR cholangiopancreatography (MRCP) of multifocal intraductal papillary mucinous tumors (IPMT) of the side branches: MR pattern and its evolution**

R. Manfredi, S. Mehrabi, M. Motton, R. Graziani, S. Perandini, R. Pozzi Mucelli; Verona/IT

**B-589** 11:42

**Patients with suspected pancreatic malignancy: 64-row MDCT vs. gadobenate-enhanced 3.0T MRI**

C. Kölblinger, A. Ba-Ssalamah, C. Kulinna-Cosentini, G. Schüller, P. Götzinger, W. Schima; Vienna/AT

**B-590** 11:51

**Diagnostic impact of F-18 FDG-PET-CT evaluating solid pancreatic lesions versus endosonography, ERCP with intraductal ultrasonography, and abdominal ultrasound**

K.U. Juergens, V. Schick, C. Franzius, O. Schober, T. Pohle, W. Heindel; Münster/DE

**10:30 - 12:00**
**Room C**
**GI Tract**
**SS 1401b**
**Esophageal and gastric cancer: New approaches**
*Moderators: M.A. Bali; Brussels/BE, N. Papanicolaou; Philadelphia, PA/US*
**B-591** 10:30

**Historical evaluation of N-staging of esophageal cancer by diffusion-weighted magnetic resonance imaging in comparison with PET**

 K. Shuto, T. Aoyagi, G. Ohira, K. Narushima, H. Saito, A. Sato, T. Ota, T. Kazama, S. Okazumi; *Chiba/JP*
**B-592** 10:39

**MR-fluoroscopy as follow-up examination in patients with narrow gastric tube reconstruction after total oesophagectomy**

 V. Panebianco, M. Osimani, M. Di Martino, D. Lisi, S. Bernardo, R. Passariello; *Rome/IT*
**B-593** 10:48

**Staging of gastric cancer: A comparison between 64-MDCT and MRI**

 M. Anzidei, A. Napoli, B. Cavallo Marincola, C. Zini, P.L. Di Paolo, K. Lanciotti, C. Catalano, R. Passariello; *Rome/IT*
**B-594** 10:57

**Preoperative local staging of gastric cancer: Comparison of 3D multi-detector row CT with air versus water distension**

 H. Park, J. Lee, S. Kim, J. Lee, J. Han, B. Choi; *Seoul/KR*
**B-595** 11:06

**Lymph nodes metastasis of gastric cancer: A comparison study of CT with pathological N staging**

 L. Tang, X.P. Zhang, Y.S. Sun, J. Li, N. Wang, K. Cao; *Beijing/CN*
**B-596** 11:15

**Diffusion-weighted MR imaging of gastric cancer: Preliminary studies**

 X.P. Zhang, L. Tang, Y.S. Sun, K. Cao, J. Li, N. Wang; *Beijing/CN*
**B-597** 11:24

**Is there an incremental value for CT direct multiplanar reconstruction in T staging of gastric cancer? A comparison with conventional axial images**

 M. Anzidei, A. Napoli, B. Cavallo Marincola, C. Zini, P.L. Di Paolo, K. Lanciotti, C. Catalano, R. Passariello; *Rome/IT*
**B-598** 11:33

**Efficacy of HMDCT in differentiation between normal and pathologic wall thickening of the gastric antrum**

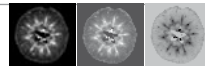
 W.K. Matzek, N. Fakhrai, N. Bastati, J. Zacherl, C.J. Herold, A. Ba-Ssalamah; *Vienna/AT*
**B-599** 11:42

**Comparison of tumor blood flow with histological structure of gastric cancer by perfusion CT: An initial study**

 A. Satoh, K. Shuto, G. Ohira, T. Aoyagi, K. Narushima, H. Saito, T. Ohta, Y. Nabeya, N. Yanagawa, S. Okazumi; *Chiba/JP*
**B-600** 11:51

**Features of tumor perfusion of gastric adenocarcinoma with 64-MDCT: Pilot study**

 J. Yao, Z.-G. Yang, T.-W. Chen; *Chengdu/CN*



Genitourinary

SS 1407

Imaging of renal lesions: Perfusion, diffusion and more

Moderators: M. Claudon; Vandoeuvre-les-Nancy/FR, T. Meindl; Munich/DE

**B-601** 10:30

**MR diffusion tensor imaging of the kidneys: Clinical feasibility study**

M. Notohamiprodjo<sup>1</sup>, U.I. Attenberger<sup>1</sup>, J.G. Raya<sup>1</sup>, C. Glaser<sup>1</sup>, M.F. Reiser<sup>1</sup>, S.O. Schönberg<sup>2</sup>, H.J. Michaely<sup>2</sup>; <sup>1</sup>Munich/DE, <sup>2</sup>Mannheim/DE

**B-602** 10:39

**DCE-CT can predict and rapidly confirm the response of metastatic renal carcinoma to anti-angiogenic drugs**

L.S. Fournier, R. Thiam, J. Medioni, L. Trinquart, D. Balvay, G. Frija, S. Oudard, C.A. Cuenod; Paris/FR

**B-603** 10:48

**CT perfusion in follow-up of antiangiogenic drugs in patients with renal cell carcinoma: Preliminary experience**

A. Tognolini, O. Pianykh, R. Bhatt, S.N. Goldberg, M.B. Atkins, V. Raptopoulos; Boston, MA/US

**B-604** 10:57

**Segmental inversion of enhancement on biphasic MDCT: A characteristic finding of small renal oncocytoma**

J. Kim<sup>1</sup>, J. Cho<sup>1</sup>, H. Lee<sup>2</sup>, S. Kim<sup>1</sup>; <sup>1</sup>Seoul/KR, <sup>2</sup>Seong Nam/KR



**B-605** 11:06

**Evaluation of renal focal lesions by contrast-enhanced ultrasonography (CEUS): Correlation with computed tomography and magnetic resonance imaging**

M. Diezhandino Gallo-Ruiz, T. Fontanilla Echeveste, R. Pérez Aranguena, C. González Hernández, C. Cortés León, M. Pastrana Ledesma; Madrid/ES

**B-606** 11:15

**3T MR correlation between ADC values of diffusion weighted imaging and cellularity in malignant renal tumors**

E. Squillaci, G. Manenti, S. Mancino, R. Mastrangeli, C. Ciccio, G. Simonetti; Rome/IT

**B-607** 11:24

**Value of FLASH-STAR MRI in the diagnostic evaluation of renal masses**

M.M.H. Abd Ellah, L. Pallwein, C. Kremser, G. Göbel, G. Bartsch, F. Frauscher; Innsbruck/AT

**B-608** 11:33

**Correlation between RECIST, WHO and volume measurement on CT in patients with renal cell carcinoma**

W.H. Gayed, A. Salah, A. Sahdev, J. Shamesh, T. Powles, R.H. Reznak; London/UK

**B-609** 11:42

**Diffusion tensor imaging of the transplanted kidney, first experience**

J. Fenda, T. Reischig, O. Hes, H. Mirka, M. Matejovic, B. Kreuzberg; Plzen/CZ

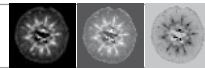
**B-610** 11:51

**Non-invasive assessment and quantitation of renal parenchyma perfusion by using contrast-enhanced ultrasound after sulfur hexafluoride-filled microbubble injection: A proposal for a new mathematical model**

E. Quaia, L. Torelli, A. Nocentini, M.A. Cova; Trieste/IT

MONDAY

**10:30 - 12:00****Room F2****Breast****SS 1402****MR: Know-how for new approaches***Moderators: M. Müller-Schimpfle; Frankfurt a. Main/DE, K. Vassiou; Larissa/GR***B-611** 10:30**Single USPIO-enhanced MR imaging in the assessment of axillary lymph node metastases in patients with breast carcinomas**  
M. Memarsadeghi<sup>1</sup>, C.C. Riedl<sup>1</sup>, A. Kaneider<sup>2</sup>, A. Galid<sup>1</sup>, M. Rudas<sup>1</sup>, M. Weber<sup>1</sup>, T.H. Helbich<sup>3</sup>; <sup>1</sup>Vienna/AT, <sup>2</sup>Horn/AT, <sup>3</sup>Toronto, ON/CA**B-612** 10:39**A novel class of macromolecular MRI contrast media: Evaluation of their potential to differentiate breast cancer from benign soft tissues**C.C. Cyran<sup>1</sup>, Y. Fu<sup>1</sup>, B. Chaopathomkul<sup>1</sup>, H.J. Raatschen<sup>2</sup>, B. Sennino<sup>1</sup>, V.S. Rogut<sup>1</sup>, D.M. Shames<sup>1</sup>, M.F. Wendland<sup>1</sup>, R.C. Brasch<sup>1</sup>; <sup>1</sup>San Francisco, CA/US, <sup>2</sup>Berlin/DE**B-613** 10:48**Contrast-enhanced magnetic resonance mammography (MRM): Improvement in breast lesion detection and characterization with gadobenate dimeglumine (Gd-BOPTA) compared to gadopentate dimeglumine (Gd-DTPA)**F. Pediconi, C. Catalano, S. Padula, A. Roselli, V. Dominelli, S. Cagioli, R. Passariello; Rome/IT**B-614** 10:57**Diffusion weighted imaging (DWI) in MR-mammography (MRM): Comparison of echo planar imaging (EPI) and half-Fourier single-shot turbo spin echo (HASTE) diffusion techniques**P.A.T. Baltzer, D.M. Renz, K.-H. Herrmann, J. Böttcher, J.R. Reichenbach, W.A. Kaiser; Jena/DE**B-615** 11:06**Role of diffusion weighted imaging (DWI) in monitoring patients with locally advanced breast cancer (LABC) undergoing primary chemotherapy (PCT)**L. Martincich, I. Bertotto, F. Montemurro, C. Bussolino Peretto, L. Cellini, D. Regge; Candiolo/IT**B-616** 11:15**Feasibility and utility of magnetization transfer ratio in breast lesions**V.F. Muglia, R.H.M. Bonini, D.M. Zeotti, J. Elias, Jr, C.S. Trad, J.M. Sarmiento Filho, H.H.A. Carrara, J.M. Andrade, A.C. Santos; Ribeirao Preto/BR**B-617** 11:24**Analysis of apparent diffusion coefficient (ADC) values of malignant and benign pathology of the breast**L. Balleio, L. Manganaro, S. Savelli, M. Angeletti, I. D'Ambrosio, N. Ravazzolo, A. Francioso; Rome/IT**B-618** 11:33**Quantification of total choline compound in in-vivo breast cancer with external standard with <sup>1</sup>H magnetic resonance spectrum**L. Jiang, C. Zhou, X. Du; Beijing/CN**B-619** 11:42**Do we really need CAD? A comparison between visual, region-of-interest (ROI) and computer-assisted-diagnosis (CAD) measurement methods for time curve data analysis in MR-mammography**P.A.T. Baltzer, D.M. Renz, C. Freiberg, S. Beger, J. Böttcher, M. Gajda, O. Camara, W.A. Kaiser; Jena/DE



**B-620** 11:51



**Correlation of apparent diffusion coefficient value of cancer breast with prognostic factors**

A.A.A. Abdel Razek, G. Gaballa, A. Denewer, N. Nada; *Mansoura/EG*

**10:30 - 12:00**

**Room G/H**

**Molecular Imaging**

**SS 1406b**

**Clinical applications**

*Moderators: C.A. Cuénod; Paris/FR, C.C. Riedl; New York, NY/US*

**B-621** 10:30

**Comparison of whole-body FDG-PET/CT and whole body MRI at 3 T for tumor staging in oncology**

E. Squillaci, O. Schillaci, S. Mancino, F. Ciccio, G. Manenti, G. Simonetti; *Rome/IT*

**B-622** 10:39

**Detecting bone metastases in melanoma and lung cancer: Whole-body MRI or whole-body FDG-PET/CT?**

T. Heusner, P. Göllitz, F. Vogt, J. Barkhausen, A. Bockisch, G. Antoch; *Essen/DE*

**B-623** 10:48

**Whole body diffusion weighted MR imaging and positron emission tomography for tumor staging in oncology**

S. Li, H.D. Xue, F. Sun, Z.Y. Jin; *Beijing/CN*

**B-624** 10:57

**Comparison of DCE-MRI, [18F]galacto-RGD- and [18F]FDG-PET in metastatic cancer patients**

S. Metz, C. Ganter, S. Lorenzen, G. Brix, M. Schwaiger, E.J. Rummeny, A.J. Beer; *Munich/DE*

**B-625** 11:06

**The clinical value of 18F-FDG-PET/CT and mediastinoscopy in initial staging in non-small cell lung cancer**

D. Putzer, D. Kendler, C. Uprimny, R. Madleitner, R. Bale, P. Kovacs, T. Schmid, I.J. Virgolini; *Innsbruck/AT*

**B-626** 11:15

**11C-metomidate-PET, CT and MRI for characterisation of adrenal incidentalomas**

A.E. Sundin, J. Hennings, H. Ahlström, P. Hellman; *Uppsala/SE*

**B-627** 11:24

**FDG-PET/CT for detection and therapy monitoring of granulocytic sarcoma (chloroma)**

P. Aschoff, M. Häntschel, M.P. Lichy, M.Ö. Öksüz, C.D. Claussen, W. Vogel, C. Pfannenberg; *Tuebingen/DE*

**B-628** 11:33

**Detection of brain metastasis by routine contrast-enhanced PET-CT of the head**

J.B. McCain, G.D. Marano, J.S. Carpenter; *Morgantown, WV/US*

**B-629** 11:42

**Residual lymphoma masses in PET/CT in patients with complete metabolic remission: An early prognostic factor for relapse?**

P. Veit-Haibach, K. Strobel, J. Soyka, N. Schäfer, M. Pérez Lago, K. Mende, T.F. Hany; *Zurich/CH*

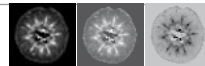
**B-630** 11:51

**Detection of macrophage activity in infected areas by USPIO-enhanced MRI in an experimental vertebral osteomyelitis model**

G. Biery, F. Jehl, N. Boehm, G. Prévost, J.-L. Diemann, S. Kremer; *Strasbourg/FR*

**MONDAY**

**10:30 - 12:00****Room I****Physics in Radiology****SS 1413****New advances in imaging techniques and applications***Moderators: T.G. Maris; Iraklion/GR, W.J.M. van der Putten; Galway/IE***B-631** 10:30**Phase-contrast radiography in a clinical setting, using high-resolution digital imaging system with a small-focus X-ray tube instead of synchrotron radiation: I. A prerequisite study for its clinical application***J. Tanaka<sup>1</sup>, H. Oda<sup>1</sup>, T. Mimura<sup>1</sup>, H. Ohara<sup>2</sup>, C. Honda<sup>2</sup>, Y. Wada<sup>1</sup>, H. Kawasaki<sup>1</sup>; <sup>1</sup>Iruma-gun/JP, <sup>2</sup>Hachioji/JP***B-632** 10:39**Image- and rawdata-based metal artifact reduction methods for flat-detector CT***D. Prell, Y. Kyriakou, M. Knaup, W. Kalender; Erlangen/DE***B-633** 10:48**High resolution phase contrast microtomography of human cartilage***P. Coan<sup>1</sup>, A. Bravin<sup>1</sup>, E. Mützel<sup>2</sup>, D. Habs<sup>3</sup>, M.F. Reiser<sup>2</sup>, C. Glaser<sup>2</sup>; <sup>1</sup>Grenoble/FR, <sup>2</sup>Munich/DE, <sup>3</sup>Garching/DE***B-634** 10:57**Development of a software package for radiation dose calculation outside therapeutic photon beams***M. Mazonakis, F. Zacharopoulou, J. Damilakis, N. Gourtsoyiannis; Iraklion/GR***B-635** 11:06**Single-source dual-energy MDCT: Effect on density and contrast volume in an experimental CTA model***J. Sosna<sup>1</sup>, S. Amin Spector<sup>2</sup>, D. Planer<sup>1</sup>, A. Altman<sup>2</sup>, E. Libson<sup>1</sup>; <sup>1</sup>Jerusalem/IL, <sup>2</sup>Haifa/IL***B-636** 11:15**Musculoskeletal imaging by a prototype of a digital imaging X-ray machine based on direct capture of X-ray photons with pixel detectors coupled to photon counting readout electronics***M. Gruber<sup>1</sup>, P. Homolka<sup>1</sup>, M. Tortajada<sup>2</sup>, R. Martinez<sup>2</sup>, M. Pretterklieber<sup>1</sup>, F. Kainberger<sup>1</sup>; <sup>1</sup>Vienna/AT, <sup>2</sup>Barcelona/ES***B-637** 11:24**CT perfusion evaluation: Accuracy of physiological parameters in tumors determined with different pharmacologic models***V. Hietschold, P. Gohl, A. Abramyyuk, A. Koch, M. Laniado, N. Abolmaali; Dresden/DE***B-638** 11:33**Correlation based noise reduction for CT data***R. Raupach, A. Borsdorf, B. Schmidt, T.G. Flohr; Forchheim/DE***B-639** 11:42**Ratio dosimetry: A practical method for the assessment of radiation exposure to medical staff during interventional procedures***F. de Lange, W.P. Moerman, K.J. Renema, L.J. Oostveen, P.A.J. Jonkergouw, H. van Langen, L.J. Schultze Kool, R.L. Kamman; Nijmegen/NL*



**B-640** 11:51

**Motion-compensated reconstruction for rotational X-ray coronary angiography**

D. Schaefer<sup>1</sup>, U. Jandt<sup>1</sup>, B. Movassaghi<sup>2</sup>, J. Garcia<sup>3</sup>, J.D. Carroll<sup>3</sup>, M. Grass<sup>1</sup>; <sup>1</sup>Hamburg/DE, <sup>2</sup>Bothell, WA/US, <sup>3</sup>Denver, CO/US

**10:30 - 12:00**

**Room K**

**Vascular**

**SS 1415**

**MR: Angiography, microcirculation and lymphography**

*Moderators: F. De Cobelli; Milan/IT, R.W. Günther; Aachen/DE*

**B-641** 10:30

**Assessment of the thoracic aorta: Intraindividual comparison between contrast-enhanced and non-contrast-enhanced ECG-triggered MR angiography**

H. von Tengg-Kobligh, J. Ley-Zaporozhan, V. Henninger, K. Ruf, H.-U. Kauczor, S. Ley; Heidelberg/DE

**B-642** 10:39

**Contrast enhanced MR angiography for detection of pulmonary arterio-venous malformations in patients with hereditary hemorrhagic telangiectasia (HHT)**

G.K. Schneider<sup>1</sup>, A. Massmann<sup>1</sup>, P. Fries<sup>1</sup>, M.A. Kirchin<sup>2</sup>, U.W. Geithoff<sup>1</sup>, A. Bücken<sup>1</sup>; <sup>1</sup>Homburg a. d. Saar/DE, <sup>2</sup>Milan/IT

**B-643** 10:48

**Diagnostic accuracy of high-spatial resolution renal MRA at 3.0T**

H.J. Michaely<sup>1</sup>, U.I. Attenberger<sup>2</sup>, H. Kramer<sup>2</sup>, K.-P. Lodemann<sup>3</sup>, M.F. Reiser<sup>2</sup>, S.O. Schönberg<sup>1</sup>; <sup>1</sup>Mannheim/DE, <sup>2</sup>Munich/DE, <sup>3</sup>Konstanz/DE

**B-644** 10:57



**Peripheral vascular malformations: Imaging with high resolution three dimensional contrast enhanced MR angiography**

A.A.A. Abdel Razek, S. Samir, H. Sharaf, A. Megahed; Mansoura/EG

**B-645** 11:06

**Peripheral magnetic resonance angiography (MRA) with parallel imaging and a dedicated 36 element matrix-coil at 3 Tesla**

H. Kramer<sup>1</sup>, H.J. Michaely<sup>2</sup>, B.J. Wintersperger<sup>1</sup>, C. Glaser<sup>1</sup>, M.F. Reiser<sup>1</sup>; <sup>1</sup>Munich/DE, <sup>2</sup>Mannheim/DE

**B-646** 11:15

**Time-resolved contrast enhanced MR angiography (CE-MRA) in diabetic patients: Improved accuracy and time saving in the infrapopliteal district**

G. Savino, A. Cina, A. Moscariello, R. Iezzi, R. Marano, L. Natale, L. Bonomo; Rome/IT

**B-647** 11:24

**MRA of the hands using a blood pool agent, in evaluation of the cold immersion test**

M. Olszycki, B. Wozniakowski, P. Pietrzak, P. Grzelak, M. Sapieha, L. Stefanczyk; Lodz/PL

**B-648** 11:33

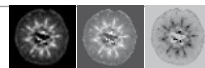
**MRI is a predictive biomarker for tumor angiogenesis response to Avastin™**

H.-J. Raatschen<sup>1</sup>, G.H. Simon<sup>2</sup>, Y. Fu<sup>2</sup>, D.M. Shames<sup>2</sup>, K.-J. Wolf<sup>1</sup>, R.C. Brasch<sup>2</sup>; <sup>1</sup>Berlin/DE, <sup>2</sup>San Francisco, CA/US

**MONDAY**

**B-649** 11:42**Longitudinal evaluation matrix metalloproteinases (MMPs) to monitor atherosclerosis progression and regression in vivo using molecular MRI**V. Amirbekian<sup>1</sup>, F. Hyafil<sup>2</sup>, S. Amirbekian<sup>3</sup>, E. Vucic<sup>2</sup>, E. Lancelot<sup>4</sup>, C. Corot<sup>4</sup>, Z.A. Fayad<sup>2</sup>; <sup>1</sup>Boston, MA/US, <sup>2</sup>New York, NY/US, <sup>3</sup>Atlanta, GA/US, <sup>4</sup>Paris/FR**B-650** 11:51**MR lymphangiography at 3 T: Feasibility study**M. Notohamiprodjo<sup>1</sup>, K.A. Herrmann<sup>1</sup>, S.O. Schoenberg<sup>2</sup>, R. Baumeister<sup>1</sup>, C. Glaser<sup>1</sup>, M.F. Reiser<sup>1</sup>, T.F. Jakobs<sup>1</sup>; <sup>1</sup>Munich/DE, <sup>2</sup>Mannheim/DE**10:30 - 12:00****Room L/M****Radiographers****SS 1414****Dose reduction strategies***Moderators: L. Lönn; Copenhagen/DK, S. Willis; Exeter/UK***B-651** 10:30**The influence of exposure parameters and beam filtration in ESD: A phantom study using a CR system**L. Lanca, J.F. Serra, J.M. Serra, R. Pereira, T. Gomes; *Lisbon/PT***B-652** 10:39**Balancing diagnostic image quality with entrance dose and filtration in computed radiography: A European perspective**T. Lehnert, H. Korkusuz, F. Khan, V. Jacobi, M.G. Mack, T.J. Vogl, N.N.N. Naguib; *Frankfurt a. Main/DE***B-653** 10:48**Exposure parameters and ESD in chest radiography: A comparative study from two DR systems**L. Lanca, D. Sousa, M. Freitas, O. Felicio, M.I. Ramalho; *Lisbon/PT***B-654** 10:57**Dose reduction strategies for CT cardiac imaging**R. Raupach<sup>1</sup>, H. Bruder<sup>1</sup>, A.N. Primak<sup>2</sup>, X. Liu<sup>2</sup>, C.H. McCollough<sup>2</sup>, T.G. Flohr<sup>1</sup>; <sup>1</sup>Forchheim/DE, <sup>2</sup>Rochester, MN/US**B-655** 11:06**DAP in patients submitted to interventional cardiac catheterization procedures**G. Paulo, M. Costa, C. Gama, M. Rocha, P. Lavandeira, L. Marques; *Coimbra/PT***B-656** 11:15**Snapshot pulse: Low-dose cardiac imaging with prospective ECG-triggering**P. Spagnolo, M. Giglio, M. Romano, A. Mazzarola, T. Khouri, S. Sironi; *Monza/IT***B-657** 11:24**Patient dose survey from coronary angiography and percutaneous transluminal coronary angioplasty in a Chinese cardiac centre**B. Liu; *Beijing/CN***B-658** 11:33**Impact of heart rate on radiation dose in dual source cardiac CT**U. Saueressig, G. Pache, A. Frydrychowicz, A. Eberl, M. Langer, T.A. Bley; *Freiburg/DE*





**B-659** 11:42

**Dual-source coronary artery computed tomography angiography: Positioning of pulsing windows determined by heart rate dependent shift of the optimal reconstruction window within the cardiac cycle**

K. Anders, S. Achenbach, U. Ropers, D. Ropers, A. Kuettner, W.A. Bautz; *Erlangen/DE*

**B-660** 11:51

**Rotational tomography of the normal and reconstructed middle ear**

J. Kromeier, C. Offergeld, M. Langer; *Freiburg/DE*

---

**10:30 - 12:00**

**Room N/O**

**Neuro**

**SS 1411**

**MRI at 7 T**

*Moderators: M. Cirillo; Naples/IT, E.-M.B. Larsson; Aalborg/DK*

**B-661** 10:30

**First clinical study on high field MRI in patients with multiple sclerosis: Comparison of 1.5 T and 7.0 T**

K. Kollie, S. Maderwald, N. Putzki, M. Forsting, M.E. Ladd, I. Wanke; *Essen/DE*

**B-662** 10:39

**Promising insights into patients' hippocampi at 7 Tesla**

J.M. Theyssohn, O. Kraff, S. Maderwald, A. de Greiff, L. Schäfer, S. Lohbeck, M. Forsting, M.E. Ladd, S.C. Ladd, E.R. Gizewski; *Essen/DE*

**B-663** 10:48

**Vascular dementia at 7 Tesla: New insights into microbleeds?**

J.M. Theyssohn, O. Kraff, M. Barth, S. Maderwald, W.P. Becker, M. Forsting, M.E. Ladd, S.C. Ladd, E.R. Gizewski; *Essen/DE*

**B-664** 10:57

**New approaches for MS lesions assessment with ultrahigh field MRI: Comparison of T2\*/phase susceptibility weighted images, with T2- and inversion recovery fast spin echo sequences**

J. Shah, K. Rammohan, S. Sammet, E. Bourekas, D.W. Chakeres, M.V. Knopp, P. Schmalbrock; *Columbus, OH/US*

**B-665** 11:06

**Evaluation of intracranial aneurysms with 7 T versus 1.5 T MR angiography**

C. Moeninghoff; *Essen/DE*

**B-666** 11:15

**Assessment of brain iron in MS patients and healthy controls by field dependent R2 increase at 7 T compared to 3 T MRI**

J. Shah, G. Mihai, K. Rammohan, S. Sammet, M.V. Knopp, P. Schmalbrock; *Columbus, OH/US*

**B-667** 11:24

**SENSE makes sense for diffusion tensor imaging and fibertracking at 7 T**

S. Sammet, M.O. Irfanoglu, R.M. Koch, P. Schmalbrock, M.V. Knopp; *Columbus, OH/US*

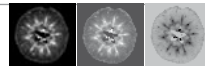
**B-668** 11:33

**First experience with fMRI at 7 T in patients with brain tumours**

B. Rumberg, C. Mönninghoff, S. Maderwald, D. Stolke, M. Forsting, M. Ladd, E. Gizewski; *Essen/DE*

**MONDAY**

**B-669** 11:42**Multi-parametric MRI in the investigation of animal models of brain gliomas: An in vivo study at 7 T**  
S. Capuani, P. Porcari, M. Lecce, E. D'Amore, F.S. Pastore, B. Maraviglia; *Rome/IT***B-670** 11:51**Evaluation of brain tumors with 7 T versus 1.5 T MRI**  
C. Moenninghoff; *Essen/DE***10:30 - 12:00****Room R1****Chest****SS 1404****Advances in CT***Moderators: P. Goodman; Durham, NC, NC/US, R. McDermott; Dublin/IE***B-671** 10:30**Pulmonary alveolar proteinosis versus exogenous lipid pneumonia: CT findings**  
H. Choi, C. Park, J. Goo, H. Lee, C. Lee, J.-G. Im; *Seoul/KR***B-672** 10:39**HRCT correlation with galactomannan levels in neutropenic immunocompromised patients**  
T.D. Suarez, S.R. Doffman, S.J. Vinnicombe, S.G. Agrawal, S. Ellis; *London/UK***B-673** 10:48**Thin-section CT findings in the ageing lung: A comparative study between >75- and <55-year-old individual controls**  
S. Copley, K. Hawtin, D. Gibson, J. Hodson, A. Wenaden, A.U. Wells, D.M. Hansell; *London/UK***B-674** 10:57**HRCT imaging of lung parenchyma in chronic heart failure (CHF) patients: Correlation with pulmonary function tests**  
E. Tavernarakis, S. Drakos, I. Nikas, L. Mouloupoulou, Z. Margari-Siafaca, C. Kostopoulos; *Athens/GR***B-675** 11:06**Pulmonary fibrosis in heavy cigarette smokers: Spectrum of HRCT findings**  
A. Oikonomou, A. Spanoudaki, A. Pataka, S. Anevlaivis, D. Bouras, P. Prassopoulos; *Alexandroupolis/GR***B-676** 11:15**To compare ultra low dose and low dose CT in detecting the presence and assessing the extent of lung abnormalities in patients with interstitial pneumonias**  
C. Beigelman Aubry, R. Khayat, M.-J. Dallaire, P. Coulon, S. Trad, P. Grenier; *Paris/FR***B-677** 11:24**Incidence of excessive tracheal collapsibility in moderate to severe COPD patients: Automatic quantification of tracheal area in cine-CT**  
M. Owsijewitsch, S. Ley, A. Mehndiratta, J. Ley-Zaporozhan, D. Simon, F.L. Giesel, C.P. Heussel, H.-U. Kauczor; *Heidelberg/DE***B-678** 11:33**Respiratory gated chest CT in pulmonary compromised patients: Correlation with lung function tests**  
P. Rogalla, N. Rogalla, B. Schmidt, B. Hamm, A. Lembcke, P. Hein; *Berlin/DE*



**B-679** 11:42

**MDCT assessment of lung volume reduction in patients undergoing bronchial stenting for treatment of pulmonary emphysema: Correlation with respiratory tests**

F. Fraioli<sup>1</sup>, L. Bertoletti, M. Mennini, S. Vetere, C. Catalano, R. Passariello; *Rome/IT*

**B-680** 11:51

**Xenon ventilation CT using a dual-energy technique of dual-source CT: Initial experience**

E. Chae<sup>1</sup>, J. Seo<sup>1</sup>, H. Goo<sup>1</sup>, N. Kim<sup>1</sup>, K.-S. Song<sup>1</sup>, S. Lee<sup>1</sup>, S.-J. Hong<sup>1</sup>, B. Krauss<sup>2</sup>; <sup>1</sup>*Seoul/KR*, <sup>2</sup>*Forchheim/DE*

**10:30 - 12:00**

**Room R2**

**Cardiac**

**SS 1403**

**MR/CT in treatment evaluation**

*Moderators: A. Jacquier; Marseille/FR, S.D. Ganadli; Lausanne/CH*

**B-681** 10:30

**Feasibility of 3D cardiac tissue engineering for embryonic stem cells therapy after myocardial infarction: Preliminary results**

M. Lepetit-Coiffe, M. Hauwel, J.-L. Daire, J.-N. Hyacinthe, M. Jaconi, J.-P. Vallee; *Geneva/CH*

**B-682** 10:39

**Cardiac MR (CMR) detection of intramyocardial haemorrhage (IMH) following primary percutaneous transluminal coronary angioplasty (PTCA) and rescue PTCA (R-PTCA)**

M. Francone, F. Calabrese, M. Mangia, P. Lucchesi, L. Agati, F. Fedele, C. Catalano, R. Passariello; *Rome/IT*

**B-683** 10:48

**Absolute quantification of myocardial blood flow from rest perfusion MRI can provide improved sensitivity for predicting myocardial viability in patients early after myocardial infarction**

M. Nagata, H. Sakuma, T. Kurita, M. Ishida, N. Ishida, Y. Mikami, H. Nakajima, M. Ito, K. Takeda; *Tsu/JP*

**B-684** 10:57

**Update on multidetector coronary CT angiography of coronary stents: In-vitro-evaluation of 27 new stent-types**

D.C. Maintz, M. Burg, H. Seifarth, A. Bunck, M. Özgün, K.-U. Juergens, R. Fischbach, W.L. Heindel; *Münster/DE*

**B-686** 11:06

**Are there differences between the four 64-multidetector computed tomography vendors for the evaluation of coronary stents? An in-vitro study**

F. Wolf<sup>1</sup>, G.M. Feuchtnr<sup>2</sup>, P. Homolka<sup>1</sup>, H. Langenberger<sup>1</sup>, A. Stadler<sup>1</sup>, T.R. Bader<sup>1</sup>, A. Dirisamer<sup>1</sup>, M. Weber<sup>1</sup>, J. Lammer<sup>1</sup>, C. Loewe<sup>1</sup>; <sup>1</sup>*Vienna/AT*, <sup>2</sup>*Innsbruck/AT*

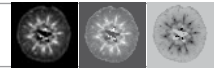
**B-687** 11:15

**Assessment of myocardial perfusion reserve in patients with X-syndrome by dypiridamole rest-stress first-pass magnetic resonance imaging (MRI): Preliminary results**

A. Esposito, F. De Cobelli, S. Ravelli, F. Arioli, G. Fragasso, M. Cera, G. Bassanelli, E. Belloni, A. Maseri, A. Del Maschio; *Milan/IT*

**MONDAY**

**B-688** 11:24**Autologous bone marrow stem cell mobilization induced by granulocyte colony-stimulating factor after STEMI undergoing late revascularization: Final results from the G-CSF-STEMI trial**A.M. Huber, A.-E. Werle-Rüdinger, B.J. Wintersperger, K. Bauner, T. Sandner, M. Engelmann, W. Franz, M.F. Reiser; *Munich/DE***B-689** 11:33**Evaluation of coronary stent patency and in-stent restenosis with dual source CT coronary angiography without heart rate control**D. Oncel, G. Oncel, A. Tastan, B. Tamci; *Izmir/TR***B-690** 11:42**Post infarction ventricular septal defects: The novel use of computed tomography and magnetic resonance imaging to guide clinical management**O.R. Tann, G. Morgan, R. Martin, M. Turner, M.C.K. Hamilton; *Bristol/UK***10:30 - 12:00****Room R3****Interventional Radiology****SS 1409****Tumor ablation/Liver regeneration***Moderators: H.A. Deutschmann; Graz/AT, I. Rozanes; Istanbul/TR***B-692** 10:30**Experimental and clinical study on the safety of ultrasound-guided percutaneous microwave ablation for hepatic tumors adjacent to gastrointestinal tract, gallbladder and diaphragm**P. Liang, G. Shao, B. Dong, H. Liang, Y. Wang, W. Shi, Y. Gao; *Beijing/CN***B-693** 10:39**Long term experience after laser ablation of 2862 colorectal carcinoma metastases in the liver in 974 patients**M.G. Mack, K. Eichler, T. Lehnert, S. Zangos, C. Müller, T.J. Vogl; *Frankfurt a. Main/DE***B-694** 10:48**Oligonodular liver metastases post laser-induced thermotherapy (LITT): Long-term results for colorectal carcinoma vs breast cancer**T.J. Vogl, A. Portugall, S. Meis, K. Eichler, T. Lehnert, M.G. Mack; *Frankfurt a. Main/DE***B-695** 10:57**The prevalence of the extrahepatic collateral artery supply for the tumor thrombi of hepatocellular carcinoma in inferior vena cava and its determined factors**I. Lee, J. Chung, H.-C. Kim, H. Jae, J. Park; *Seoul/KR***B-696** 11:06**Radiofrequency ablation of renal tumors: Mid-term follow-up in 40 patients**O. Eker, V. Perot, X. Coutouly, M. Sesay, J.M. Ferriere, P. Ballanger, N. Grenier; *Bordeaux/FR***B-697** 11:15**Initial experimental study of cryoablation on rabbit's VX2 brain tumor model under MRI guidance**C. Li; *Jinan/CN*



**B-698** 11:24

**Liver hypertrophy after portal vein embolization (PVE) before major hepatectomy: Our experience in 60 consecutive patients**

G.C. Anselmetti, A. Manca, G. Chiara, L. Cellini, D. Campanella, D. Regge; *Candiolo/IT*

**B-699** 11:33

**Role of preoperative portal vein embolization before partial or extended hepatectomy in cirrhotic liver: A compared and retrospective study**

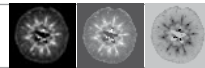
L. Carpanese, G. Pizzi, G. Vallati, G.M. Ettore, R. Santoro, M. Crecco; *Rome/IT*

**B-700** 11:42

**Human growth factor (HGF) evaluation before liver intervention: Final results of a prognostic significance for liver regeneration**

T. Lehnert, A. Gazis, K. Eichler, S. Zangos, M.G. Mack, T.J. Vogl, R. Hammerstingl;  
*Frankfurt a. Main/DE*

**10:30 - 12:00****Room A****Musculoskeletal****SS 1810****Tumors and marrow disease***Moderators: E.E. Drakonaki; Iraklion/GR, A.R. Mester; Budapest/HU***B-701** 10:30**Role of single shot echoplanar diffusion weighted MR imaging in differentiation of malignant spinal tumors from benign lesions***A.A.A. Abdel Razek<sup>1</sup>, R. Warda<sup>2</sup>, A. Elsharif<sup>2</sup>, K. Abdel Hamid<sup>2</sup>; <sup>1</sup>Mansoura/EG, <sup>2</sup>Gedda/SA***B-702** 10:39**Comparative study of whole body diffusion weighted MR imaging and bone scintigraphy in detection of bone metastases***S. Li, H.D. Xue, F. Sun, Z.Y. Jin; Beijing/CN***B-703** 10:48**Bone disease in multiple myeloma patients: 3T whole body MRI vs radiological skeletal survey. Initial clinical experience***E. Squillaci, S. Mancino, C. Ciccio, D. Bartolucci, G. Manenti, G. Simonetti; Rome/IT***B-705** 10:57**A prospective analysis of CT density measurements of bone metastases after treatment with zoledronic acid***P. Dell'Aia, C.C. Quattrocchi, S. Piciucchi, D. Santini, R. Grasso, B. Beomonte Zobel; Rome/IT***B-706** 11:06**Application study of 3T MR functional imaging in patients with musculoskeletal tumors***Z. Qi, C. Li, D. Yu, K. Zhang; Jinan City/CN***B-707** 11:15**Preliminary study of 3T 1H MR spectroscopy in bone and soft tissue tumors***Z. Qi, C. Li, Z. Li, K. Zhang, Q. Wang; Jinan City/CN***B-708** 11:24**Dynamic contrast enhanced MRI of spindle cell sarcomas: Counterintuitive relationship of perfusion to tumour necrosis***A.P. Toms<sup>1</sup>, L.M. White<sup>2</sup>, R. Kandel<sup>2</sup>, R.R. Bleakney<sup>2</sup>, M. Noseworthy<sup>3</sup>, M.E. Blackstein<sup>2</sup>, J. Wunder<sup>2</sup>, L. Shepstone<sup>1</sup>; <sup>1</sup>Norwich/UK, <sup>2</sup>Toronto, ON/CA, <sup>3</sup>Hamilton, ON/CA***B-709** 11:33**The relationship between MRI features and clinical outcome of aggressive fibromatosis***R. Arkun, S. Dogan, M. Argin, T. Akalin, D. Sabah, Y. Bolukbasi; Izmir/TR***B-710** 11:42**Morphology, metabolism, microcirculation, and strength of skeletal muscles in cancer-related cachexia***M.-A. Weber<sup>1</sup>, H. Krakowski-Roosen<sup>1</sup>, L. Schröder<sup>1</sup>, R. Kinscherf<sup>2</sup>, M. Krix<sup>1</sup>, A. Kopp-Schneider<sup>1</sup>, M. Essig<sup>1</sup>, P. Bachert<sup>1</sup>, H.-U. Kauczor<sup>1</sup>, W. Hildebrandt<sup>1</sup>; <sup>1</sup>Heidelberg/DE, <sup>2</sup>Mannheim/DE*



**Abdominal Viscera (Solid Organs)**

**SS 1801a**

**HCC, still tantalising and bewildering**

Moderators: *M.-F. Bellin; Villejuif/FR, L. Crocetti; Pisa/IT*

**B-711** 10:30

**Gadoxetic acid-enhanced MR imaging of hepatocellular carcinoma (HCC) in patients with cirrhosis correlated to histological grading: Primary assessment**

*M. Di Martino, D. Marin, C. Catalano, A. Guernisi, F. Galati, M. Baski, S. Brozetti, R. Passariello; Rome/IT*

**B-712** 10:39

**Value of Gd-BOPTA enhanced MR imaging in diagnosing hepatocellular carcinoma with correlation of pathology**

*B. Song, Y. Li, J. Xu, B. Wu, Y. Yang; Chengdu/CN*

**B-713** 10:48

**Automated RECIST and WHO criteria measurements and volumetry of solid liver tumors in multi-slice CT**

*V. Yaghmai<sup>1</sup>, S. Berggruen<sup>1</sup>, B. Atassi<sup>1</sup>, M. Rezvani<sup>1</sup>, J. Huang<sup>1</sup>, H. Soud<sup>2</sup>, P. Nikolaidis<sup>1</sup>, R. Salem<sup>1</sup>; <sup>1</sup>Chicago, IL/US, <sup>2</sup>Malvern, PA/US*

**B-714** 10:57

**Probabilistic separation of iodine: Virtually non-enhanced CT obtained with single source dual energy MDCT**

*J. Sosna<sup>1</sup>, L. Goshen<sup>2</sup>, S. Amin Spector<sup>2</sup>, R. Carmi<sup>2</sup>, E. Libson<sup>1</sup>; <sup>1</sup>Jerusalem/IL, <sup>2</sup>Haifa/IL*

**B-715** 11:06

**Quantitative color mapping of the arterial enhancement fraction of the liver for detection of hepatocellular carcinoma in cirrhotic liver**

*K. Kim<sup>1</sup>, J. Lee<sup>1</sup>, E. Klotz<sup>2</sup>, J. Lee<sup>1</sup>, S. Hong<sup>1</sup>, W. Kim<sup>1</sup>, S. Kim<sup>1</sup>; <sup>1</sup>Seoul/KR, <sup>2</sup>Forchheim/DE*

**B-716** 11:15

**Hepatocellular carcinoma in cirrhotic liver disease: Functional CT with perfusion imaging for assessment of tumor angiogenesis**

*D. Ippolito<sup>1</sup>, F. Invernizzi<sup>1</sup>, M. Pozzi<sup>1</sup>, L. Antolini<sup>1</sup>, S. Sironi<sup>1</sup>, F. Fazio<sup>2</sup>; <sup>1</sup>Monza/IT, <sup>2</sup>Milan/IT*

**B-717** 11:24

**MRI versus 64-row MDCT for diagnosis of HCC**

*R. Kloeckner, G. Otto, S. Herber, K.F. Kreitner, C. Dueber, M.B. Pitton; Mainz/DE*



**B-718** 11:33

**Comparison of enhancement with iomeprol-400 and iodixanol-320 in patients undergoing contrast-enhanced multidetector CT of the liver**

*L. Romano<sup>1</sup>, C. Catalano<sup>2</sup>, L. Grazioli<sup>3</sup>, L. Bonomo<sup>2</sup>, J.-R. Xu<sup>4</sup>, K.-M. Chen<sup>4</sup>; <sup>1</sup>Naples/IT, <sup>2</sup>Rome/IT, <sup>3</sup>Brescia/IT, <sup>4</sup>Shanghai/CN*

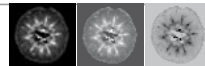
**B-719** 11:42

**The combined assessment of hepatocellular nodule vascularity at 64-row multidetector CT and contrast-enhanced US: Analysis of diagnostic performance**

*E. Quaia<sup>1</sup>, V. Alaimo<sup>2</sup>, T.V. Bartolotta<sup>2</sup>, M.A. Cova<sup>1</sup>; <sup>1</sup>Trieste/IT, <sup>2</sup>Palermo/IT*

**B-720** 11:51**Role of fusion imaging technique by a combined CT/MRI ultrasound navigation system in the diagnosis of small HCC (<20 mm) on cirrhosis**G. Vidili, F. Piscaglia, A. Bazzocchi, G. Zironi, A.G. Tewelde, M.G. Mirarchi, S. Costantini, R. Righini, R. Golfieri, L. Bolondi; *Bologna/IT***10:30 - 12:00****Room C****GI Tract****SS 1801b****Small bowel and appendix***Moderators: G.J. Antes; Kempten/DE, V. Maniatis; Athens/GR***B-721** 10:30**Improved diagnosis of Crohn's disease by peristaltic motion assessment: A comparison of standardized MRI with and without cine TrueFISP sequence**C. Waldherr<sup>1</sup>, J.M. Fröhlich<sup>2</sup>, C. Stoupis<sup>3</sup>, S.M. Ertürk<sup>4</sup>, M.A. Patak<sup>1</sup>; <sup>1</sup>Berne/CH, <sup>2</sup>Winterthur/CH, <sup>3</sup>Männedorf/CH, <sup>4</sup>Istanbul/TR**B-722** 10:39**Sliding multislice: A novel adjunct to hydro-MRI for the evaluation of patients with recurrent Crohn's disease**G. Pache, A.-O. Schaefer, M. Langer; *Freiburg/DE***B-723** 10:48**Comparison of True-FISP-MRI before and after i.v.-contrast administration in patients with inflammatory bowel disease (IBD): Is postcontrast True-FISP imaging essential?**M. Hellmann, G. Krombach, N. Krämer, M. Distelmaier, R. Günther, C. Hohl; *Aachen/DE***B-724** 10:57**Gadolinium enhancement of mesenteric lymph nodes in different Crohn disease subtypes**S. Gourtsoyanni, N. Papanikolaou, J. Grammatikakis, L. Bourikas, M. Roussomoustakaki, N. Gourtsoyannis; *Iraklion/GR***B-725** 11:06**Assessment of the Crohn disease activity using intravenous application of the blood-pool contrast agent gadofosveset during MR enterography**J. Ferda, J. Kozeluhova, B. Kreuzberg, V. Treska; *Plzen/CZ***B-726** 11:15**Contrast-enhanced wideband harmonic imaging ultrasound and contrast media "blood-pool": Quantitative measurement of inflammatory activity in Crohn's disease using parametric imaging**A. De Franco, A. Di Veronica, L. Guidi, A. Armuzzi, I. Roberto, I. De Vitis, G. Fedeli, F. Danza, E. Bock; *Rome/IT***B-727** 11:24**Magnetic resonance enteroclysis compared with conventional enteroclysis and computed tomography enteroclysis: A critically appraised topic**R. Ryan, I.S.E. Heaslip, D.E. Malone; *Dublin/IE***B-728** 11:33**MR enteroclysis in the evaluation of the small bowel neoplasms**G. Masselli, E. Casciani, E. Poletti, L. Bertini, G. Gualdi; *Rome/IT*





**B-729** 11:42

**MSCt-enteroclysis (MSCTe) in the diagnosis of bowel endometriosis**

E. [Biscaldi](#), S. Ferrero, V. Remorgida, G.A. Rollandi; *Genoa/IT*



**B-730** 11:51

**Comparison of ultrasonographic signs of appendicitis in visible appendices**

Z. [Tarján](#), A. Stefan, L. Lukács; *Budapest/HU*



**10:30 - 12:00**

**Room E1**

**Cardiac**

**SS 1803a**

**Coronary artery imaging**

*Moderators: F. Pugliese; Rotterdam/NL, H.-J. Smith; Oslo/NO*

**B-731** 10:30

**NIMIS-CAD study: Multicenter intraindividually controlled comparison study to evaluate the NPV of 16 and 64 slice MDCT imaging in patients scheduled for coronary angiography**

R. [Marano](#)<sup>1</sup>, F. De Cobelli<sup>2</sup>, C. Becker<sup>3</sup>, C. Herzog<sup>4</sup>, I. Floriani<sup>2</sup>, T. Nimiscad Study Group<sup>2</sup>, A. Del Maschio<sup>2</sup>, L. Bonomo<sup>1</sup>; <sup>1</sup>Rome/IT, <sup>2</sup>Milan/IT, <sup>3</sup>Munich/DE, <sup>4</sup>Frankfurt/DE

**B-732** 10:39

**Learning curve in dual-source CT coronary angiography in high risk patients**

T. [Adla](#), J. Neuwirth, J. Veselka, V. Suchánek, M. Polovincák, R. Duchonová, L. Martinkovicová; *Prague/CZ*

**B-733** 10:48

**Blood pool contrast agent for coronary MR angiography: Utility of first pass and steady state acquisitions**

I. Carbone, E. [Algeri](#), H. Grazhdani, D. Cannata, F. Ciolina, N. Galea, C. Catalano, R. Passariello; *Rome/IT*

**B-734** 10:57

**The relationship between the angle of the left main bifurcation and the formation and distribution of atheroma in the left main bifurcation by 64-slice spiral CT**

X.-X. [Tang](#)<sup>1</sup>, J. Yuan<sup>1</sup>, K.-M. Chen<sup>2</sup>; <sup>1</sup>Taiyuan/CN, <sup>2</sup>Shanghai/CN

**B-735** 11:06

**64-slice computed tomography coronary angiography: Diagnostic accuracy in the "real world"**

F. Cademartini<sup>1</sup>, E. [Maffei](#)<sup>2</sup>, A. Palumbo<sup>2</sup>, M. Fusaro<sup>2</sup>, F. Notarangelo<sup>2</sup>, A. Aldrovandi<sup>2</sup>; <sup>1</sup>Rotterdam/NL, <sup>2</sup>Parma/IT

**B-736** 11:15

**Detection of coronary artery stenosis with 3 Tesla coronary MR angiography**

L. [Job](#), F. Bonnet, C. Hoeffel, S. Perotin, A. Coupteau, C. Marcus; *Reims/FR*

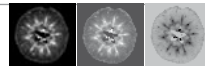
**B-737** 11:24

**Comparison of 16 and 64 multi-detector row spiral computed tomography for noninvasive detection and evaluation of coronary atherosclerotic plaques**

B. [Lu](#), W. Wu, S. Qiao, S. Jiang; *Beijing/CN*

**TUESDAY**

**B-738** 11:33**Feasibility of 64-slice cardiac CT in obese patients: A retrospective analysis of assessable arteries and segments in 567 patients**R. [Salgado](#), B. Shivalkar, P.M. Parizel, C. Vrints; *Edegem/BE***B-739** 11:42**Whole-heart coronary MRA at 3.0 Tesla: A comparison study of MRA and CTA in patients with coronary stenosis**Q. [Yang](#)<sup>1</sup>, K. Li<sup>1</sup>, D. Li<sup>2</sup>, R. Merges<sup>1</sup>, J. Chen<sup>1</sup>, J. An<sup>1</sup>; <sup>1</sup>*Beijing/CN*, <sup>2</sup>*Chicago, IL/US***B-740** 11:51**Is 64-slice computed tomography coronary angiography accurate and safe in asymptomatic, intermediate-to-high Framingham risk patients to exclude coronary artery disease? A prospective study**G. [Feuchtnner](#), D. Jodocy, D. Junker, A. Klauser, W. Dichtl, O. Pachinger, P. Soegner, D. zur Nedden, G. Friedrich; *Innsbruck/AT***10:30 - 12:00****Room F1****Genitourinary****SS 1807****Prostate imaging: Diagnosis, therapy and follow-up***Moderators: N.A. Al-Nakshabandi; Riyadh/SA, J.C. Vilanova; Girona/ES***B-741** 10:30**Comparison of preoperative prostate cancer staging performance between 3T endorectal MR imaging and real-time transrectal ultrasound**S.W.T.P. [Heijmink](#), T. Hambroek, T.W.J. Scheenen, C.A. Hulsbergen-van de Kaa, B.C. Knipscheer, J.A. Witjes, J.O. Barentsz; *Nijmegen/NL***B-742** 10:39**Value of endorectal coil T2-weighted MRI combined with 3D-CSI spectroscopy in the diagnosis of prostate cancer in patients with elevated PSA**G.M. [Villeirs](#), W. Oosterlinck, V. Fonteyne, G.O. De Meerleer; *Gent/BE***B-743** 10:48**Differentiation of normal prostate tissue, chronic prostatitis, and prostate cancer by quantitative perfusion analysis using a dynamic contrast-enhanced inversion-prepared dual-contrast gradient echo sequence**T. [Franjel](#), L. Lüdemann, B. Rudolph, H. Rehbein, A. Staack, M. Taupitz, D. Prochnow, D. Beyersdorff; *Berlin/DE***B-744** 10:57**Correlation of diffusion-weighted MR imaging (DWI) and 11Cholin PET-CT in the differentiation of benign and metastatic pelvic and inguinal lymph nodes in patients with prostate cancer: Preliminary experience**M. [Eiber](#), K. Holzapfel, C. Ganter, M. Souvatzoglou, E. Rummeny, J. Gaa; *Munich/DE***B-745** 11:06**Effect of hormonal therapy on dynamic CAD-based analysis of prostate cancer prior to iMRI-therapy**A. [Malich](#), O. Mikulik, A. Kott, S. Mikulik, D. Hentrich, W. Oehler; *Nordhausen/DE*



**B-746** 11:15

**Value of dynamic contrast-enhanced MR imaging in detecting local tumor progression after HIFU ablation of localized prostate cancer**

C. Kim, B. Park, H. Choi, H. Lee; *Seoul/KR*

**B-747** 11:24

**MR imaging in the prediction of the probability of biochemical recurrence in patients undergoing radical prostatectomy**

M.H. Fuchsjaeger<sup>1</sup>, A. Shukla-Dave<sup>1</sup>, H. Hricak<sup>1</sup>, L. Wang<sup>1</sup>, J.H. Donohue<sup>1</sup>, P.T. Scardino<sup>1</sup>, J.A. Eastham<sup>1</sup>, M.W. Kattan<sup>2</sup>; <sup>1</sup>New York, NY/US, <sup>2</sup>Cleveland, OH/US

**B-748** 11:33

**3D multiplanar TRUS with power Doppler in detecting prostatic fossa recurrences following radical prostatectomy**

V. Gazhonova, V. Solovyev, A. Zubarev; *Moscow/RU*

**B-749** 11:42

**The role of diffusion tensor imaging with 3 Telsa in the diagnosis of prostate cancer**

B. Gurses, N. Kabakci, Z. Firat, T. Alp, A. Bayram, M.A. Ulug, M.M. Cihangiroglu, I. Kovanlikaya; *Istanbul/TR*

**B-750** 11:51

**Prospective study on MR-guided galvanotherapy of prostate cancer: Initial results**

T.J. Vogl<sup>1</sup>, H.P. Mayer<sup>2</sup>, S. Zangos<sup>1</sup>, F.B. Mayer<sup>1</sup>; <sup>1</sup>Frankfurt a. Main/DE, <sup>2</sup>Regensburg/DE

---

**10:30 - 12:00**

**Room F2**

**Breast**

**SS 1802**

**MR: Role in patient management**

*Moderators: H. Dobson; Glasgow/UK, R.A. Kubik-Huch; Baden/CH*

**B-751** 10:30

**Correlation between dynamic contrast enhanced MRI (DCE-MRI) morphological and dynamic features and histopathological prognostic factors in invasive breast cancer**

V. Girardi<sup>1</sup>, G. Carbognin<sup>1</sup>, A. Russo<sup>1</sup>, M. Tonegutti<sup>2</sup>, F. Bonetti<sup>1</sup>, R. Pozzi Mucelli<sup>1</sup>; <sup>1</sup>Verona/IT, <sup>2</sup>Peschiera/IT

**B-752** 10:39

**The value of functional MRI methods in diagnosis of breast carcinoma and assessment of early response to neoadjuvant chemotherapy**

X.X.H. Wang, W.J. Peng, K. Shen, F. Sun; *Shanghai/CN*

**B-753** 10:48

**Magnetic resonance imaging (MRI) in predicting disease-free survival in patients treated with primary chemotherapy for locally advanced breast cancer**

M. Sentís Crivellé<sup>1</sup>, M. Seguí Palmer<sup>1</sup>, L.A. Fernandez Morales<sup>1</sup>, E. Dalmáu<sup>1</sup>, C. Santos<sup>1</sup>, S. Ganau Macías<sup>1</sup>, S. Fernandez<sup>1</sup>, E. Pous<sup>1</sup>, J. Font<sup>1</sup>, A. Arcusa<sup>2</sup>, E. Saigi Grai<sup>1</sup>; <sup>1</sup>Sabadell/ES, <sup>2</sup>Terrassa/ES

**B-754** 10:57

**MRI of the breast improves detection of invasive cancer, preinvasive cancer and premalignant lesions during surveillance of women with a high risk for breast cancer**

 C.C. [Riedl](#), L. Pohnhold, C. Rainer, S. Jaromi, D. Flöry, M. Fuchsjäger, T. Wagner, T.H. Helbich; *Vienna/AT*
**B-755** 11:06

**Changes from breast conserving surgery to mastectomy in breast cancer patients based on preoperative breast MRI: Reason, frequencies and results**

 S.-H. [Mun](#), E.-Y. Ko, J.-H. Shin, S.-J. Kim, B.-K. Han; *Seoul/KR*
**B-756** 11:15

**Contrast-enhanced magnetic resonance mammography: Does it affect surgical decision-making in patients with breast cancer?**

 S. [Padula](#), F. Pediconi, A. Roselli, V. Dominelli, S. Cagioli, C. Catalano, R. Passariello; *Roma/IT*
**B-757** 11:24

**The accuracy of MRI in evaluating patients for residual breast cancer after lumpectomy**

 O. [Golan](#), F. Sperber, A. Shalmon, A. Gat; *Tel Aviv/IL*
**B-758** 11:33

**Role of breast MRI in patients with unilateral nipple discharge: Preliminary study**

 L. Ballesio, S. [Savelli](#), C. Maggi, I. D'Ambrosio, L.M. Porfiri, C. De Felice, L. Manganaro; *Rome/IT*
**B-759** 11:42

**The role of real-time virtual sonography in detecting enhancing incidental lesion on contrast-enhanced MR imaging of the breast**

 S. [Nakano](#)<sup>1</sup>, K. Yorozuya<sup>1</sup>, M. Takasugi<sup>1</sup>, Y. Mouri<sup>1</sup>, T. Fukutomi<sup>1</sup>, K. Ohno<sup>1</sup>, D. Arakawa<sup>2</sup>, T. Mitake<sup>2</sup>; <sup>1</sup>*Aichi/JP*, <sup>2</sup>*Chiba/JP*
**B-760** 11:51

**Differentiation of recurrent breast cancer from post treatment changes with diffusion weighted MR imaging**

 A.A.A. [Abdel Razek](#)<sup>1</sup>, N. Abdel Razek<sup>2</sup>, A. Denewar<sup>1</sup>, N. Nada<sup>1</sup>; <sup>1</sup>*Mansoura/EG*, <sup>2</sup>*Cairo/EG*
**10:30 - 12:00**
**Room G/H**
**Head and Neck**
**SS 1808**
**Skull base and temporal bone**
*Moderators: R.B.-J. de Bondt; Maastricht/NL, S. Kösling; Halle a.d. Saale/DE*
**B-761** 10:30

**Preoperative assessment of cochlear implant patients using MSCT and MRI**

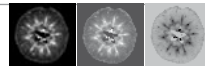
 H. Ma<sup>1</sup>, P. Han<sup>1</sup>, J. Xiao<sup>2</sup>, R. Merges<sup>2</sup>, W.-J. Kong<sup>1</sup>, G.-S. Sheng<sup>1</sup>, H. Shi<sup>1</sup>; <sup>1</sup>*Wuhan/CN*, <sup>2</sup>*Shanghai/CN*
**B-762** 10:39

**Evaluation of four MSCT systems in postoperative imaging of a cochlear implant**

 B.M. [Verbist](#), R.M.S. Joemai, W.M. Teeuwisse, J.H.M. Frijns, J. Geleijns; *Leiden/NL*
**B-763** 10:48

**CT findings of first branchial anomalies**

 K. [Lee](#), H.-J. Kim, S. Kim, P. Jeon, K. Kim, Y. Yim; *Seoul/KR*



**B-764** 10:57

**Congenital deformities of the ear**

V.K. Katsaros, N. Marangos, C. Drossos; *Athens/GR*

**B-765** 11:06

**Imaging of intralabyrinthine schwannomas: A retrospective study of 52 cases with emphasis on lesion growth**

A. Tielemans<sup>1</sup>, J.W. Casselman<sup>1</sup>, T. Somers<sup>2</sup>, J. Delanote<sup>1</sup>, J. Ghekiere<sup>1</sup>, R. Kuhweide<sup>1</sup>, B. De Foer<sup>2</sup>, E.F. Offeciers<sup>2</sup>; <sup>1</sup>*Bruges/BE*, <sup>2</sup>*Antwerp/BE*

**B-766** 11:15

**MRI of the inner ear at 1.5T and 3T**

G.A. Krombach, T. Plum, M. Westhofen, C. Hohl, R.W. Günther; *Aachen/DE*

**B-767** 11:24

**The facial nerve in the petrous bone: Improvement of visualisation using 3 T MRI**

H.P. Burmeister, F. Hause, P. Schmidt, O. Guntinas-Lichius, J. Sedlacik, H.-J. Mentzel, W.A. Kaiser; *Jena/DE*

**B-768** 11:33

**Superior semicircular canal dehiscence syndrome: CT-MPR of the superior semicircular canal improves diagnostic accuracy**

A. Iaia, C.M. Silverberg, R.T. Geracimos, B. Kung, G. Sparcia, K. Karcher, M. Teixeira; *Newark, DE/US*

**B-769** 11:42

**Traumatic ossicular chain separation: Sliding-thin-slab maximum intensity projections for diagnosis**

B. Zhao, J. He, S. Liu, T. Ma; *Jinan/CN*

**B-770** 11:51

**Detailed imaging of the jugular foramen and its content at 3Tesla MRI**

J. Linn, F. Schwarz, H. Brückmann, I. Yousry; *Munich/DE*



**10:30 - 12:00**

**Room I**

**Vascular**

**SS 1815**

**Therapy, evaluation and outcome**

*Moderators: M. Heller; Kiel/DE, P. Vilela; Almada/PT*

**B-771** 10:30

**Endovascular revascularization for limb salvage in diabetic patients**

L. Di Vito, S. Fabiano, R. Gandini, M. Stefanini, M. Messina, C. Reale, E. Pampana, G. Simonetti; *Rome/IT*

**B-772** 10:39

**Clinical validity of ECG-gated CT angiography for prediction of patient outcome after coronary artery bypass graft surgery**

P. Suranyi, B.J. Williams, S.A. Bagg, A.R. Smith, P. Huang, J.B. Selby, P. Costello, U.J. Schoepf; *Charleston, SC/US*

**B-773** 10:48

**Juxtarenal and thoracoabdominal aneurysms: Successful treatment with fenestrated and branched stent grafts**

C.D. Bicknell, N.J.W. Cheshire, P. Bourke, C.V. Riga, J.H.N. Wolfe, R.G.J. Gibbs, M.P. Jenkins, M. Hamady; *London/UK*

**B-774** 10:57

**Color-duplex ultrasonography surveillance after endovascular repair of abdominal aortic aneurysm**

 I. Bargellini, P. Torri, F. Guidocci, P. Petruzzi, R. Cioni, A. Cicorelli, C. Vignali, C. Bartolozzi; *Pisa/IT*
**B-775** 11:06

**The role of contrast-enhanced ultrasonography (CE-US) in the detection of endoleaks in patients who underwent endovascular abdominal aortic aneurysm repair (EVAR)**

 R. Iezzi, R. Basilico, V. Pasqua, M. Santoro, A.R. Cotroneo, M.L. Storto; *Chieti/IT*
**B-776** 11:15

**New frontiers of vascular imaging - dynamic MRI derived models for morphologic and functional evaluation of thoracic aorta: Clinical application in EVAR patients**

 M. Midulla<sup>1</sup>, R. Moreno<sup>1</sup>, L. Veunac<sup>1</sup>, F. Nicoud<sup>2</sup>, B. Marcheix<sup>1</sup>, V. Chabbert<sup>1</sup>, F. Joffre<sup>1</sup>, H. Rousseau<sup>1</sup>; <sup>1</sup>Toulouse/FR, <sup>2</sup>Montpellier/FR

**B-777** 11:24

**Multimodality evaluation of consecutive patients with abdominal aneurysm treated with endovascular graft: Color-Doppler-US vs low-MI CEUS as compared with 64-slice angio-CT and angio-MRI**

 V. Cantisani, P. Ricci, A. Napoli, C. Marigliano, E. Marotta, C. Catalano, F. Fanelli, U. D'Ambrosio, R. Passariello; *Rome/IT*
**B-778** 11:33

**Device-specific outcome in terms of aneurysm shrinkage and growth after endovascular abdominal aortic aneurysm repair (EVAR): A comparison between suprarenal and infrarenal fixation stent-grafts**

 R. Iezzi, D. Giancristofaro, V. Pasqua, D. Gabrielli, A.R. Cotroneo, M.L. Storto; *Chieti/IT*
**B-779** 11:42

**Detection of vascular graft infection with dual-modality FDG-PET/CT: Initial results**

 J. Votrubová, O. Belohlavek, M. Spacek, P. Sebesta; *Prague/CZ*
**B-780** 11:51

**Uterine artery pseudoaneurysms as an uncommon cause of delayed postpartum hemorrhage and their endovascular management**

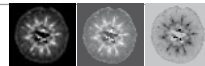
 V. Gupta, N. Khandelwal, M. Singhal, J.R. Bapuraj, A. Lal, L.K. Dhaliwal; *Chandigarh/IN*
**10:30 - 12:00**
**Room K**
**Pediatric**
**SS 1812**
**Advances in CT and MRI**
*Moderators: S. Chapman; Birmingham/UK, R.R. van Rijn; Amsterdam/NL*
**B-781** 10:30

**The corpus callosum as a paradigmatic region for motor development: A study with diffusion tensor MR imaging (DTI) and transcranial magnetic stimulation (TMS)**

 B. Ertl-Wagner, I. Koerte, R. Stahl, M. Bonfert, W. Flatz, C. Rummeny, M.F. Reiser, F. Heinen; *Munich/DE*
**B-782** 10:39

**Symmetrical CTT (central tegmental tract) hyperintensity lesion on MR imaging in children**

 S. Yoshida<sup>1</sup>, K. Hayakawa<sup>1</sup>, A. Yamamoto<sup>1</sup>, N. Aida<sup>2</sup>, S. Okano<sup>1</sup>, H. Matsushita<sup>1</sup>, T. Kanda<sup>1</sup>, Y. Yamori<sup>1</sup>, N. Yoshida<sup>1</sup>, A. Hirota<sup>1</sup>; <sup>1</sup>Kyoto/JP, <sup>2</sup>Yokohama/JP

**B-783** 10:48

**Diffusion abnormalities of the optic nerve head in pediatric brain tumor patients**

A. Vossough, T. Feygin, L.T. Bilaniuk, R.A. Zimmerman; *Philadelphia, PA/US*

**B-784** 10:57

**Cerebral perfusion CT in the evaluation of children with severe traumatic brain injury**

S. Binaghi, L. Racine-Parret, S. De Ribaupierre, F. Gudinchet; *Lausanne/CH*

**B-785** 11:06

**Estimated risk of radiation-induced thyroid cancer from pediatric head MDCT examinations: Sequential versus spiral scanning**

M. Mazonakis, A. Tzedakis, J. Damilakis, N. Gourtsoyiannis; *Iraklion/GR*

**B-786** 11:15

**How low can we go? Low dose 64 slice PET/CT protocols for paediatric patients: The importance of multidisciplinary teamwork**

L. Heiberg, C.E. de Lange, L.A. Refsum, W. Nordhøy, K. Johnsrud, H. Solheim, A.-E. Spiten, M. Sheikhaeri; *Oslo/NO*

**B-787** 11:24

**Automatic exposure control in pediatric multi-detector CT examinations: Can radiation dose be substantially reduced?**

A. Papadakis, K. Perisnakis, J. Damilakis, N. Gourtsoyiannis; *Iraklion/GR*

**B-788** 11:33

**Which is the best imaging modality to capture bone erosion in JIA?**

M.B. Damasio, M. Valle, C. Malattia, F. Magnaguagno, C. Martinoli, S. Viola, A. Ravelli, A. Martini, P. Tomà, A. Pistorio; *Genoa/IT*

**B-789** 11:42

**UK radiologists' satisfaction with training and support in suspected physical abuse: A questionnaire survey**

A.C. Offiah<sup>1</sup>, A. Pervaiz<sup>1</sup>, C. Nwachukwu<sup>1</sup>, C. Walker<sup>2</sup>, C. Landes<sup>2</sup>; <sup>1</sup>London/UK, <sup>2</sup>Liverpool/UK

**B-790** 11:51

**Value of diffusion-weighted imaging in routine MR scans using a fusion technique for visualization of malignant tumors in paediatric oncology patients**

S. Alibek, A. Cavallaro, W. Bautz, G. Staatz; *Erlangen/DE*

**10:30 - 12:00****Room L/M****Contrast Media****SS 1806a****From research to practice***Moderators: J.-M. Correas; Paris/FR, D. Reddan; Galway/IE***B-791** 10:30**Gadovist® 1.0M: Tolerance and clinical safety**

M. Forsting; Essen/DE

**B-792** 10:39**Sinerem-enhanced intravenous MR lymphography for staging pelvic cancers: Results of a European multicenter phase III trial including 271 patients**

B. Hamm<sup>1</sup>, F. Caseiro-Alves<sup>2</sup>, M.-F. Bellin<sup>3</sup>, A. Padhani<sup>4</sup>, R. Passariello<sup>5</sup>, T.H. Helbich<sup>6</sup>, C. Roy<sup>7</sup>, J.O. Barentsz<sup>8</sup>, D. Hahn<sup>9</sup>, M. Lemort<sup>10</sup>, D. Portalez<sup>11</sup>, P. Marano<sup>5</sup>, A. Chiesa<sup>12</sup>, R. Aziza<sup>13</sup>, U. Mödder<sup>14</sup>; <sup>1</sup>Berlin/DE, <sup>2</sup>Coimbra/PT, <sup>3</sup>Villejuif/FR, <sup>4</sup>Northwood/UK, <sup>5</sup>Rome/IT, <sup>6</sup>Vienna/AT, <sup>7</sup>Strasbourg/FR, <sup>8</sup>Nijmegen/NL, <sup>9</sup>Würzburg/DE, <sup>10</sup>Brussels/BE, <sup>11</sup>Saint-Jean/FR, <sup>12</sup>Brescia/IT, <sup>13</sup>Toulouse/FR, <sup>14</sup>Düsseldorf/DE

**B-793** 10:48**3-D multiphasic low dose contrast enhanced MR angiography using TWIST on a 32-channel head coil at 3 Tesla: Comparison of a conventional gadolinium chelate with a high relaxivity agent**

F.L. Giesel<sup>1</sup>, V. Runge<sup>2</sup>, S. Baumann<sup>2</sup>, B. Corell<sup>1</sup>, E.L. Lowther<sup>2</sup>, J. Gendron<sup>2</sup>, H.-U. Kauczor<sup>1</sup>, M. Essig<sup>1</sup>; <sup>1</sup>Heidelberg/DE, <sup>2</sup>Temple, TX/US

**B-794** 10:57**Comparison of the contrast media Gd-DTPA and gadofosveset for absolute quantification of myocardial perfusion using high-resolution MRI**

C.O. Ritter<sup>1</sup>, A. Wilke<sup>1</sup>, T. Wichmann<sup>2</sup>, M. Beer<sup>1</sup>, D. Hahn<sup>1</sup>, H. Köstler<sup>1</sup>; <sup>1</sup>Wuerzburg/DE, <sup>2</sup>Rimpar/DE

**B-795** 11:06**Intraindividual comparison of Gadovist®, Omniscan®, Multihance® and Vasovist® for CE-MRA of the supra-aortic arteries**

B. Buerke<sup>1</sup>, T. Alkemper<sup>1</sup>, H. Kugel<sup>1</sup>, M. Voth<sup>2</sup>, C. Bremer<sup>1</sup>, S. Evers<sup>1</sup>, W. Heindel<sup>1</sup>, B. Tombach<sup>1</sup>; <sup>1</sup>Muenster/DE, <sup>2</sup>Berlin/DE

**B-796** 11:15**Contrast-enhanced MRA of the abdominal and peripheral vessels: Is there a need for blood pool agents?**

R. Iezzi<sup>1</sup>, S. Thurnher<sup>2</sup>, G. Soulez<sup>3</sup>, G. Schneider<sup>4</sup>, N. Shen<sup>5</sup>, M.A. Kirchin<sup>6</sup>, G. Pirovano<sup>5</sup>, A. Spinazzi<sup>5</sup>; <sup>1</sup>Chieti/IT, <sup>2</sup>Vienna/AT, <sup>3</sup>Montreal, QC/CA, <sup>4</sup>Homburg a.d. Saar/DE, <sup>5</sup>Princeton, NJ/US, <sup>6</sup>Milan/IT

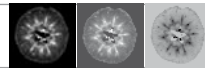
**B-797** 11:24**Influence of the contrast agent iodine concentration on the visualization of coronary arteries using automated and manual segmentation methods in dual-source CT angiography**

A. Kuettnner<sup>1</sup>, K. Anders<sup>1</sup>, S. Busch<sup>2</sup>, C. Becker<sup>2</sup>; <sup>1</sup>Erlangen/DE, <sup>2</sup>Munich/DE

**B-798** 11:33**The role of the oral contrast medium in 18F-FDG-PET studies**

S.M. Shaikh; Hyderabad/IN





**B-799** 11:42

**Comparison of 68Ga-DOTA-Tyr(3)-Octreotide PET and diagnostic CT for treatment evaluation of radionuclide therapy**

M. Gabriel, A. Oberauer, D. Kendler, D. Putzer, R. Bale, R. Madleitner, C. Uprimny, P. Kovacs, I.J. Virgolini; *Innsbruck/AT*

**B-800** 11:51

**Highly iodinated intravenous contrast agent for PET/CT: Feasible? Useful? Advisable?**

T. Heusner, H. Kuehl, P. Veit-Haibach, M. Forsting, A. Bockisch, G. Antoch; *Essen/DE*

**10:30 - 12:00**

**Room N/O**

**Neuro**

**SS 1811**

**Epilepsy and development issues**

*Moderators: A. Cianfani; Rome/IT, J.M. Garcia Santos; Murcia/ES*

**B-801** 10:30

**Incomplete inversion of the hippocampus in subjects without severe developmental anomalies: Is there a relationship to epilepsy?**

D. Bajic, E. Kumlien, P. Mattsson, S. Lundberg, C. Wang, O. Eeg-Olofsson, R. Raininko; *Uppsala/SE*

**B-802** 10:39

**Diffusion tensor imaging in lateralisation and localisation of epileptogenesis focus in temporal lobe epilepsy with and without hippocampal sclerosis**

S. Gan, W. Handoko, S. Christensen, P.M. Desmond, T.J. O'Brien; *Melbourne, Victoria/AU*

**B-803** 10:48

**Presurgical and postsurgical findings in refractory patients with anterior temporal lobe resection. Are they predictive factors of surgical outcome?**

N. Bargalló, L. Olondo, S. Capurro, S. Gonzalez, J. Rumià, M. Carreño, A. Donaire; *Barcelona/ES*

**B-804** 10:57

**Unverricht-Lundborg disease (ULD): Magnetic resonance imaging with voxel-based morphometry in nineteen patients and nineteen matched controls**

P. Koskenkorva, E. Niskanen, M. Könönen, E. Mervaala, R. Kälviäinen, R. Vanninen; *Kuopio/FI*

**B-805** 11:06

**Electrical impedance tomography (EIT): A new imaging method**

A. Romsauerova<sup>1</sup>, L. Hores<sup>2</sup>, A. McEwan<sup>1</sup>, D. Holder<sup>1</sup>; <sup>1</sup>London/UK, <sup>2</sup>Atlanta, GA/US

**B-806** 11:15

**Impact of quality management for emergency teleneuroradiology-process management for the outcome of neurology patients: Results after six years experience**

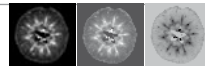
P.F.W. Soegner, F. Koppelstaetter, B. Oefner, D. zur Nedden; *Innsbruck/AT*

**B-807** 11:24

**Increased incidence of hypophosphatemia associated with serial triple-dose gadolinium administration among 75 participants in the BECOME MS trial**

L.J. Wolansky, T. Phatak, B. Peng, J. Kaplan, A.R. Jedynak, P. Baladandapani, M. Haghighi, J.H. Skurnick, S.D. Cook, D. Cadavid; *Newark, NJ/US*

**B-808** 11:33**Postmortem magnetic resonance imaging in legal cases: Where can it help?**E.H. Whitby, M. Paley, M. Cohen; *Sheffield/UK***B-810** 11:42**Diffusion tensor imaging in meningoencephalitis: Anisotropy as an indicator of meningeal inflammation and its differential diagnosis**R.H.N. Hanasoge, R.V.S.V. Vadapalli, U. Patil, U. Murgod, R. Gowda, S.V. Bommana; *Bangalore/IN***10:30 - 12:00****Room R1****Chest****SS 1804****Technical advances/Pulmonary hypertension and perfusion***Moderators: M. Bellomi; Milan/IT, C. Mueller-Mang; Vienna/AT***B-811** 10:30**Standard dose and dose-reduced mobile direct radiography versus computed radiography for bedside chest imaging: Evaluation of image quality and reader agreement**D.W. De Boog, N.J. Freling, E.E. Deurloo, H.W. Venema, D.A. Dongelmans, C.M. Schaefer-Prokop; *Amsterdam/NL***B-812** 10:39**Radiation dose during nongated MDCT angiography of the chest: Comparison between single- and dual-source CT technology**C. Santos Name, M. Rémy-Jardin, P. Dupuis, V. Deken, J.-B. Faivre, J. Rémy; *Lille/FR***B-813** 10:48**Prediction of perceptible artifacts in JPEG2000 compressed chest CT images using mathematical and perceptual quality metrics**B. Kim<sup>1</sup>, K. Lee<sup>1</sup>, K. Kim<sup>1</sup>, R. Mantiuk<sup>2</sup>, S. Hahn<sup>3</sup>, T. Kim<sup>1</sup>, Y. Kim<sup>1</sup>; <sup>1</sup>*Seongnam-si, Gyeonggi-do/KR*, <sup>2</sup>*Saarbrücken/DE*, <sup>3</sup>*Seoul/KR***B-814** 10:57**The reliability of CT signs in mild and severe pulmonary hypertension**A. Devaraj, A.U. Wells, M. Meister, T. Corte, J. Wort, D.M. Hansell; *London/UK***B-815** 11:06**The effects of diffuse pulmonary fibrosis on the accuracy of CT signs of pulmonary hypertension**A. Devaraj, A.U. Wells, M. Meister, J. Wort, T. Corte, D.M. Hansell; *London/UK***B-816** 11:15**Pulmonary hypertension: Correlation of CINE-MRI and phase-contrast MRI with six-minute-walk-test and parameters from right heart catheterization**C. Fink<sup>1</sup>, H. Leuchte<sup>2</sup>, L. Bitto<sup>2</sup>, J. Behr<sup>2</sup>, M.F. Reiser<sup>2</sup>, S.O. Schönberg<sup>1</sup>; <sup>1</sup>*Mannheim/DE*, <sup>2</sup>*Munich/DE***B-817** 11:24**Quantitatively assessed 3D dynamic perfusion MRI of the lung for disease severity evaluation in patients with collagen vascular diseases**Y. Ohno, H. Koyama, S. Matsumoto, D. Takenake, Y. Onishi, M. Nogami, K. Sugimura; *Kobe/JP*



**B-818** 11:33

**Treatment monitoring in patients with pulmonary arterial hypertension (PAH) using quantitative 3D MR pulmonary perfusion**  
S. Ley, E. Gruenig, F. Risse, N. Ehlken, D. Mereles, H.-U. Kauczor; *Heidelberg/DE*

**B-819** 11:42

**Pulmonary parenchyma perfusion imaging with SSFSE-FAIR, compared with 3D DCE MRI**  
L. Fan<sup>1</sup>, S.Y. Liu<sup>1</sup>, F. Sun<sup>2</sup>, X.S. Xiao<sup>1</sup>; <sup>1</sup>Shanghai/CN, <sup>2</sup>Beijing/CN

**B-820** 11:51

**Characterization of regional alterations in pulmonary perfusion via MDCT in nonsmokers and smokers**

S.K. Alford, E.J. van Beek, M. Hudson, H. Baumhauer, G. McLennan, E.A. Hoffman; *Iowa City, IA/US*

**10:30 - 12:00**

**Room R2**

**Cardiac**

**SS 1803b**

**Valvular and cardiac function studies**

*Moderators: N.L. Kelekis; Athens/GR, G.K. Schneider; Homburg a.d. Saar/DE*

**B-821** 10:30

**Comparison of non-invasive MRI approaches to invasive hemodynamic measurements in the assessment of valvular aortic stenosis**

M. Weininger, C.O. Ritter, B. Lengenfelder, F. Sagmeister, W. Voelker, H. Koestler, D. Hahn, M. Beer; *Wuerzburg/DE*

**B-822** 10:39

**Diagnostic performance of multislice computed tomography in infective endocarditis: Comparison with transesophageal echocardiography and intraoperative findings**

G. Feuchtnner<sup>1</sup>, P. Stolzmann<sup>2</sup>, W. Dichtl<sup>1</sup>, T. Schertler<sup>2</sup>, J. Bonatti<sup>1</sup>, H. Scheffel<sup>2</sup>, S. Müller<sup>1</sup>, A. Plass<sup>2</sup>, T. Bartel<sup>1</sup>, H. Alkadih<sup>2</sup>; <sup>1</sup>Innsbruck/AT, <sup>2</sup>Zurich/CH

**B-823** 10:48

**Preoperative evaluation of patients undergoing valvular replacement for aortic stenosis using 64-slice CT angiography**

I. Carbone, P. Sedati, H. Grazhdani, F. Ciolina, N. Galea, D. Cannata, C. Catalano, R. Passariello; *Rome/IT*

**B-824** 10:57

**Free-breathing multislice MRI for determination of cardiac functional parameters**

M.J. Beer, H. Stamm, A. Weng, C. Ritter, D. Hahn, H. Köstler; *Würzburg/DE*

**B-825** 11:06

**Accuracy of quantitative measurement of mitral valve regurgitation using 64-section multi-detector row CT: Comparison with real-time three-dimensional echocardiography**

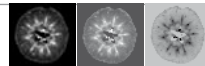
Y. Guo, Z.-G. Yang, Y. Li, Y. Wu, E.-S. Ma, X.-C. Zhang; *Chengdu/CN*

**B-826** 11:15

**Assessment of aortic stenosis after aortic valve replacement: Comparative evaluation of dual-source CT and echocardiography**

T. Saam, M. Oberhoffer, C. Rist, N. Minaifar, F. Vogt, B. Reichart, C.R. Becker, M.F. Reiser, K. Nikolaou; *Munich/DE*

**B-827** 11:24**Tricuspid annular plane systolic excursion measurement using MRI: A fast and easy tool to estimate right ventricular systolic function**A.A. [Azarine](#)<sup>1</sup>, A. Ferreira<sup>1</sup>, X. Lyon<sup>2</sup>, A. Redheuil<sup>1</sup>, P. Garrigoux<sup>1</sup>, E. Mousseaux<sup>1</sup>; <sup>1</sup>Paris/FR, <sup>2</sup>Lausanne/CH**B-828** 11:33**Computing the left atrium volume from three orthogonal dimensions measured on T1-weighted BB images is not an accurate method for measuring left atrial size**M. [Burgmans](#), I. Hof, N. Prakken, P. Loh, B. Velthuis; *Utrecht/NL***B-829** 11:42**Is it possible to predict the degree of pulmonary regurgitation after tetralogy of Fallot repair by the pulsation of the central pulmonary arteries?**L. [Uljei](#)<sup>1</sup>, N. Merchant<sup>2</sup>, E. Di Segni<sup>1</sup>, D. Chang<sup>2</sup>, O. Goitein<sup>1</sup>, N.S. Pau<sup>2</sup>, E. Konen<sup>1</sup>; <sup>1</sup>Ramat-Gan/IL, <sup>2</sup>Toronto, ON/CA**B-830** 11:51**Integration of cardiac computed tomography into pulmonary vein isolation in patients with paroxysmal atrial fibrillation**T.F. Weber<sup>1</sup>, H. Klemm<sup>2</sup>, A. Koops<sup>2</sup>, H.-D. Nagel<sup>2</sup>, G. Adam<sup>2</sup>, P.G. [Begemann](#)<sup>2</sup>; <sup>1</sup>Heidelberg/DE, <sup>2</sup>Hamburg/DE**10:30 - 12:00****Room R3****Interventional Radiology****SS 1809****Vascular interventions (2)***Moderators: P.M. Bosnjakovic; Nis/RS, I.P. Vulev; Bratislava/SK***B-831** 10:30**Carotid stent angioplasty during filter protection: Analysis of microscopical findings and clinical follow-up**P.E. [Huppert](#), D. Claus, G. Wiest; *Darmstadt/DE***B-832** 10:39**Transfemoral endovascular treatment of proximal common carotid artery lesions: A single centre experience on 153 lesions**T. [Paukovits](#), J. Haász, A. Molnar, Z. Szeberin, B. Nemes, D. Varga, K. Hüttl, V. Berczi; *Budapest/HU***B-833** 10:48**Tailored carotid stenting in 200 consecutive procedures: Is patient based endovascular treatment the method of choice for high surgical risk patients with carotid stenosis?**C. [Oláh](#), I. Lázár, S. Barta, R. Lovász, A. Valikovics; *Miskolc/HU***B-834** 10:57**Open versus closed cell design in carotid artery stenting**I.Q. [Grunwald](#), K. Karp, M. Politi, C. Krick, A. Haaß, W. Reith; *Homburg a.d. Saar/DE***B-835** 11:06**Unprotected CAS: Is it still an option?**I.Q. [Grunwald](#), K. Karp, C. Krick, P. Papanagiotou, A. Haaß, M. Müller, H. Schieber, W. Reith; *Homburg a.d. Saar/DE*



**B-836** 11:15

**Endovascular treatment of internal carotid artery stenosis: Immediate and eight years follow-up**

M. Stefanini, R. Gandini, S. Fabiano, M. Di Primio, E. Gaspari, G. Simonetti; *Rome/IT*

**B-837** 11:24

**The Cook Select™ filter: The UK and global experience so far**

C.D. Watts<sup>1</sup>, R. Uberoi<sup>1</sup>, S. Lyon<sup>2</sup>, R. Gunther<sup>3</sup>, G. Riojas<sup>4</sup>, G.M.L.G. Avendano<sup>4</sup>, M.E.B. Lipp<sup>4</sup>, G. Plant<sup>5</sup>, J. Patel<sup>6</sup>, M.A. De Gregorio<sup>7</sup>, M.J. Lee<sup>8</sup>; <sup>1</sup>*Oxford/UK*, <sup>2</sup>*Melbourne/AU*, <sup>3</sup>*Aachen/DE*, <sup>4</sup>*Mexico City/MX*, <sup>5</sup>*Basingstoke/UK*, <sup>6</sup>*Leeds/UK*, <sup>7</sup>*Zaragoza/ES*, <sup>8</sup>*Dublin/IE*

**B-838** 11:33

**Symptomatic lower and upper extremity deep venous thrombosis management: Catheter directed thrombolysis with or without pharmaco-mechanical thrombectomy**

U.C. Turba, A. Sim, M.A. Meuse, B. Arslan, J.F. Angle, U. Bozlar, A.H. Matsumoto, K.D. Hagspiel, M.D. Dake; *Charlottesville, VA/US*

**B-839** 11:42

**Outpatient treatment of arterial inflow stenoses of dysfunctional hemodialysis access fistulas by retrograde venous access puncture and catheterization**

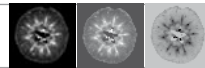
T.F. Le Maire, L.E.M. Duijm, K.J.G. Reuveur, A.V. Tielbeek; *Eindhoven/NL*

**B-840** 11:51

**Transvenous renal biopsy of kidney transplants via transfemoral approach**

A. Schmid, H.-L. Voit, C. Hugo, U. Baum, W. Bautz, M. Uder; *Erlangen/DE*





## Abdominal Viscera (Solid Organs)

### Biliary Tract

#### C-001

##### Portal biliopathy: Imaging findings

J.P. Cruz, F.D. Frota, A. Huete, F. Cruz; *Santiago/CL*

#### C-002

##### Uncommon obstructive causes of extrahepatic bile duct: Imaging findings and clinical significance

S. Kim<sup>1</sup>, H. Shin<sup>1</sup>, I. Kim<sup>1</sup>, H. Kim<sup>2</sup>, D. Lee<sup>2</sup>, Y. Ko<sup>2</sup>; <sup>1</sup>Choongnam/KR, <sup>2</sup>Seoul/KR

#### C-003

##### The MRCP features of biliary cast syndrome

A.P. Winterbottom, A.S. Krishnan, A.E. Gimson, C.J.E. Watson, D.J. Lomas; *Cambridge/UK*

#### C-004

##### Postsurgical bile leaks and bile duct strictures: From ultrasound to endoscopic retrograde cholangiopancreatography

M.D.G.A. Certo<sup>1</sup>, L. Lopes<sup>2</sup>; <sup>1</sup>Santo Tirso/PT, <sup>2</sup>Viana do Castelo/PT

#### C-005

##### Gallbladder's diseases on MDCT: Revisited

N.P. Silva, A. Almeida, M. Castro, B. Viamonte, L. Melão, J.M. Pereira; *Porto/PT*

#### C-006

##### Blood supply of intrahepatic bile duct: Histopathological findings of peribiliary plexus and its significance on hepatic imaging

S. Kobayashi, O. Matsui, T. Gabata, J. Sanada, W. Koda, Y. Nakanuma; *Kanazawa/JP*

#### C-007

##### Prediction of survival with F-18 fluorodeoxyglucose-positron emission tomography in biliary carcinoma

H. Furukawa, H. Ikuma, K. Yokoe-Asakura, K. Uesaka; *Shizuoka/JP*

#### C-008

##### Evaluation of the gross type and longitudinal extent of extrahepatic cholangiocarcinomas on contrast-enhanced MDCT

H. Seo<sup>1</sup>, J. Lee<sup>1</sup>, I. Kim<sup>2</sup>, J. Han<sup>1</sup>, S. Kim<sup>1</sup>, J. Jang<sup>1</sup>, S.-W. Kim<sup>1</sup>, B. Choi<sup>1</sup>; <sup>1</sup>Seoul/KR, <sup>2</sup>Jeju/KR

#### C-009

##### Transient hepatic attenuation difference (THAD) in biliary vessels diseases (BVD)

S. Pradella, B. Duranti, N. Centi, M. Vangelisti, G. Faralli, N. Villari, S. Colagrande; *Florence/IT*

#### C-010

##### Portal biliopathy: MR cholangiopancreatography features

E. Özkavukcu, A. Erden, I. Erden; *Ankara/TR*

#### C-011

##### Peripheral cholangiocarcinoma (PCC): Enhancement features on enhanced MR imaging with gadobenate dimeglumine (Gd-BOPTA)

L. Grazioli<sup>1</sup>, L. Romanini<sup>1</sup>, M. Bondioni<sup>1</sup>, B. Fritoli<sup>1</sup>, M. Kirchin<sup>2</sup>; <sup>1</sup>Brescia/IT, <sup>2</sup>Milan/IT

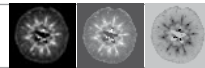
#### C-012

##### Clinical usefulness of MRCP and MR imaging in patients with hepatolithiasis: Focusing on variable complications

J. Kim, H. Eun, S. Hong, G. Kwon, D. Choi, J. Hwang; *Seoul/KR*

**C-013****Pineapple juice with gadolinium used as negative oral contrast in magnetic resonance cholangiopancreatography:****A multicentric study**J.A. [Duarte](#), A. Furtado, C.A. Marroni; *Porto Alegre/BR***C-014****The role of MR cholangiography in patients with iatrogenic bile duct injury after cholecystectomy**F. Todua, K. Lashkhi, S. Kakhadze, M. Gurgenidze, K. Gigauri, R. [Kharadze](#), G. Svanidze; *Tbilisi/GE***Abdominal Viscera (Solid Organs)****Liver****C-015****The role of imaging techniques in acute bleeding liver: A rational approach**J. [Quintero](#), J. Sampere, S. Mourelo, J. Jiménez, I. Urrea, E. Barluenga; *Badalona/ES***C-016****Magnetic resonance elastography of liver: Technique and clinical application**S.K. [Venkatesh](#)<sup>1</sup>, M. Yin<sup>2</sup>, R.L. Ehman<sup>2</sup>; <sup>1</sup>*Singapore/SG*, <sup>2</sup>*Rochester, MN/US***C-017****Third in-flow as a cause of hepatic pseudo-lesions**C. [Vallone](#)<sup>1</sup>, F. Marra<sup>1</sup>, C. Bertolani<sup>1</sup>, M. Fazi<sup>1</sup>, L. Grazioli<sup>2</sup>, N. Villari<sup>1</sup>, S. Colagrande<sup>1</sup>; <sup>1</sup>*Florence/IT*, <sup>2</sup>*Brescia/IT***C-018****Diffusion-weighted MR imaging of the liver**A.A.A. [Abdel Razek](#), M. Shady, M. Elbendary, E. Omram; *Mansoura/EG***C-019****The treated liver: A pictorial review of imaging findings following liver-directed therapy, short-term and long-term follow-up**S. Carter, C. Farinas, M. Patnana, J. [Szklaruk](#); *Houston, TX/US***C-020****Role of contrast-enhanced ultrasound in the characterization of hypervascular focal liver lesions: Spectrum of imaging findings**T.V. [Bartolotta](#), A. Taibbi, M. Galia, E. Grassedonio, A. Galluzzo, V. Alaimo, M. Midiri; *Palermo/IT***C-021****Various extrahepatic metastasis of hepatocellular carcinoma: Spectrum of imaging findings**J. [Kim](#), Y. Lee, J. Byun, S. Oh, S. Rha, S. Jung, Y. Ku; *Seoul/KR***C-022****Changes in MR-imaging features of patients with hepatocellular carcinoma following sorafenib monotherapy:****Incidence, time of occurrence and significance**M.S. [Horger](#), M. Bitzer, U. Lauer, C. Schraml, M. Lichy, C. Claussen; *Tübingen/DE***C-023****Diffusion-weighted MRI of the cirrhotic liver: Advantages and limits**J.-S. [Yu](#), J.-J. Chung, J. Kim; *Seoul/KR*





**C-024**

**Focal nodular hyperplasia or hepatic adenoma? The role of MRI using liver-specific contrast agents in this challenging differential diagnosis**

P. Paolantonio, R. Ferrari, M. Rengo, P. Lucchesi, F. Vecchiotti, A. Laghi; *Latina/IT*

**C-025**

**Diffusion-weighted MR imaging (DW-MRI) of the liver: Literature review and personal experience**

R. Girometti, A. Furlan, L. Cereser, M. Bazzocchi, C. Zuiani; *Udine/IT*

**C-026**

**Nonalcoholic fatty liver disease (NAFLD) in HIV infected patients: Prevalence, characteristics and predictors**

F. Fiocchi, G. Ligabue, N. Squillace, C. Stentarelli, G. Guaraldi, G. Orlando, R. D'Amico, P. Loria, R. Esposito, P. Torricelli; *Modena/IT*

**C-027**

**Liver hemosiderosis: Comparison of three methods for the construction of liver T2\* color parametric maps using data obtained directly from a newly designed research PACS system**

T.G. Maris<sup>1</sup>, K. Karolemeas<sup>2</sup>, E. Drakonaki<sup>1</sup>, K. Pagonidis<sup>1</sup>, N. Papanikolaou<sup>1</sup>, A. Karantanas<sup>1</sup>, N. Gourtsoyiannis<sup>1</sup>; <sup>1</sup>*Iraklion/GR*, <sup>2</sup>*Athens/GR*

**C-028**

**Detection of hepatocellular carcinoma: Comparison of diffusion-weighted sensitivity-encoding imaging and tetra-phase multi-detector row CT**

S. Takenaga<sup>1</sup>, N. Ichiba<sup>2</sup>, K. Narita<sup>3</sup>, S. Sadaoka<sup>4</sup>, D. Hayashi<sup>4</sup>, K. Fukuda<sup>4</sup>, M. Urashima<sup>4</sup>; <sup>1</sup>*Kashiwa-shi, Chiba/JP*, <sup>2</sup>*Otsu-shi, Shiga/JP*, <sup>3</sup>*Katsushika-ku, Tokyo/JP*, <sup>4</sup>*Minato-ku, Tokyo/JP*

**C-029**

**Hepatic blood flow and liver metastasis in patients with colorectal carcinoma assessed by perfusion CT**

A. Satoh, K. Shuto, G. Ohira, T. Aoyagi, K. Narushima, H. Saito, T. Ohta, H. Miyauchi, N. Yanagawa, S. Okazumi; *Chiba/JP*

**C-031**

**A liver function image by equivalent cross relaxation rate**

S. Matsushima<sup>1</sup>, H. Nishiofuku<sup>2</sup>, H. Tomozawa<sup>3</sup>, S. Era<sup>1</sup>, Y. Inaba<sup>3</sup>, Y. Kinoshita<sup>1</sup>; <sup>1</sup>*Gifu/JP*, <sup>2</sup>*Nara/JP*, <sup>3</sup>*Nagoya/JP*

**C-032**

**Multiparametric MRI (diffusion weighted imaging (DWI) and dynamic contrast enhanced-MRI (DCE)) evaluation to quantify liver fibrosis in patients with chronic hepatitis C: Preliminary results**

D. Olivé<sup>1</sup>, P.-A. Eliat<sup>1</sup>, P. Audet<sup>2</sup>, M. Mescam<sup>1</sup>, J.-S. Billiard<sup>2</sup>, J. Murphy-Lavallée<sup>2</sup>, B. N'Guyen<sup>2</sup>, M. Bilodeau<sup>2</sup>, L. Lepanto<sup>2</sup>; <sup>1</sup>*Rennes/FR*, <sup>2</sup>*Montreal, QC/CA*

**C-033**

**Diagnostic value of SPIO-mediated breath-hold black blood fluid attenuated inversion recovery (BH-BB-FLAIR) imaging in patients with hepatocellular carcinomas**

M. Matsushima, S. Naganawa, H. Ogawa, T. Komada, S. Ishigaki, H. Kawai, K. Suzuki, H. Satake, S. Ito, M. Ikeda; *Nagoya/JP*

**C-034**

**Low-dose hepatic perfusion CT using a low tube voltage technique and an adaptive noise reduction filter**

Y. Yanaga, K. Awai, T. Nakaura, M. Imuta, T. Namimoto, Y. Yamashita; *Kumamoto/JP*

**C-035** (No material submitted to EPOS™)**Multidetector CT angiography in the evaluation of potential living donors for liver transplantation: Single center experience in China**

Z. Zhuang<sup>1</sup>, J. Xu<sup>1</sup>, Y. Cheng<sup>2</sup>, L. Qian<sup>1</sup>, H. Gong<sup>1</sup>, W. Chai<sup>1</sup>, G. Li<sup>1</sup>; <sup>1</sup>Shanghai/CN, <sup>2</sup>Taiwan/CN

**C-036****Small hypoechoic nodules in cirrhotic patients with previously treated HCC: Analysis of non-enhancing nodules at contrast-enhanced-US**

L. Tarantino<sup>1</sup>, I.F.M. Sordelli<sup>2</sup>, A. Schiano<sup>1</sup>, G. Francica<sup>3</sup>; <sup>1</sup>Frattamaggiore/IT, <sup>2</sup>Naples/IT, <sup>3</sup>Casoria/IT

**C-037****Fatty metamorphosis in hepatocellular carcinoma (HCC): Comparison with MR dynamic enhancing study on HCC diagnosis**

Y.-J. Chen, T.-S. Jaw, T.-J. Hsieh, Y.-T. Kao; Kaohsiung/CN

**C-039****Predictive value of Tc-99m galactosyl human serum albumin (GSA) hepatic SPECT on the assessment of functional recovery after partial hepatectomy**

H. Wakamatsu<sup>1</sup>, S. Nagamachi<sup>1</sup>, S. Kiyohara<sup>1</sup>, S. Fujita<sup>1</sup>, K. Kamimura<sup>1</sup>, S. Futami<sup>1</sup>, R. Nishii<sup>2</sup>, S. Tamura<sup>1</sup>; <sup>1</sup>Miyazaki/JP, <sup>2</sup>Moriyama/JP

**C-040****Optimal contrast dose for depiction of hypervascular hepatocellular carcinoma at hepatic dynamic CT using a 64-detector CT scanner**

Y. Yanaga, K. Awai, T. Nakaura, T. Namimoto, Y. Yamashita; Kumamoto/JP

**C-041****Focal contrast enhancement on hepatic CT in superior vena cava obstruction syndrome: Analysis of 12 cases**

L. Tang, X.P. Zhang, Y.S. Sun, J. Li, N. Wang, K. Cao; Beijing/CN

**C-042****A new prognostic index of cirrhosis progression: CT and MR imaging findings and clinical correlation**

E. Filograna<sup>1</sup>, L. Bonomo<sup>1</sup>, V. Vilgrain<sup>2</sup>; <sup>1</sup>Rome/IT, <sup>2</sup>Clichy/FR

**C-043****Contrast-enhanced behaviour at very low MI CEUS of a large series of hepatic adenoma**

V. Cantisani<sup>1</sup>, P. Ricci<sup>1</sup>, M. D'Onofrio<sup>2</sup>, F. Calliada<sup>3</sup>, D. Sahani<sup>4</sup>, E. Pagliara<sup>1</sup>, U. D'Ambrosio<sup>1</sup>, R. Passariello<sup>1</sup>; <sup>1</sup>Rome/IT, <sup>2</sup>Verona/IT, <sup>3</sup>Pavia/IT, <sup>4</sup>Boston, MA/US

**C-044****Arterial complications of adult liver transplantation: Correlation of CT appearances with angiography and surgery**

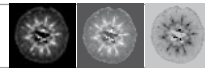
I. Martineau, S. Awad, A. Sarina, D. Castaing, R. Adam, D. Samuel, M.-F. Bellin; Villejuif/FR

**C-045****Diffusion-weighted MRI in focal hepatic lesions: The validation study**

R. Maksimovic, M. Dunjic Kratovac, G. Lilic, L. Lazic; Belgrade/RS

**C-046****Hypervascular focal liver lesions: Enhancement evaluation in the dynamic and hepatobiliary phases after Gd-E08-DTPA, comparison with MDCT**

L. Grazioli<sup>1</sup>, M. Bondioni<sup>1</sup>, B. Frittoli<sup>1</sup>, L. Romanini<sup>1</sup>, A. Filippone<sup>2</sup>; <sup>1</sup>Brescia/IT, <sup>2</sup>Chieti/IT



**C-047**

**To compare the imaging findings of different MR liver specific contrast materials (Gd-BOPTA, Gd-E0B-DTPA, Mn-DPDP, and ferumoxides) in the diagnosis of hepatic adenoma (HA) and liver adenomatosis (LA)**

L. Grazioli<sup>1</sup>, G. Morana<sup>2</sup>, G. Schneider<sup>3</sup>, M. Kirchin<sup>4</sup>, M. Bondioni<sup>1</sup>; <sup>1</sup>Brescia/IT, <sup>2</sup>Treviso/IT, <sup>3</sup>Homburg a.d. Saar/DE, <sup>4</sup>Milan/IT

**C-048**

**Usefulness of multiplanar reconstruction with multislice computed tomography to assess hepatocellular carcinoma response after transcatheter arterial chemoembolization**

T.V. Bartolotta, V. Macchiarella, V. Bova, A. Taibbi, M. Galia, F. Cannizzaro, M. Midiri; Palermo/IT

**C-049**

**Clinical usefulness of free-breathing (FB) MR techniques in abdomen**

J. Kim, H. Eun, S. Hong, G. Kwon, D. Deuk Lin Choi, J. Hwang; Seoul/KR

**C-050**

**Associations between hepatic FDG accumulation and variables**

K. Kamimura<sup>1</sup>, S. Fujita<sup>1</sup>, H. Wakamatsu<sup>1</sup>, R. Nishii<sup>1</sup>, S. Nagamachi<sup>1</sup>, Y. Umemura<sup>1</sup>, M. Ogita<sup>1</sup>, T. Fujimoto<sup>1</sup>, M. Nakajo<sup>2</sup>; <sup>1</sup>Miyazaki/JP, <sup>2</sup>Kagoshima/JP

**C-051**

**Detection of hepatocellular carcinoma with ferucarbotran-enhanced MR imaging: Efficacy of delayed fat-suppressed T1-weighted imaging**

C.-T. Chou<sup>1</sup>, R.-C. Chen<sup>2</sup>, W.-T. Chen<sup>2</sup>, J.-M. Li<sup>2</sup>, H.-K. Wu<sup>1</sup>; <sup>1</sup>Chang-Hwa/CN, <sup>2</sup>Taipei/CN

**Abdominal Viscera (Solid Organs)**

**Pancreas**

**C-052**

**Extrapancreatic lesions associated with autoimmune pancreatitis: Prevalence, distribution and image findings**

Y. Fujinaga, M. Kadoya, K. Ueda, M. Momose, S. Kawakami, S. Yamazaki, T. Hatta, H. Hamano, S. Kawa; Matsumoto/JP

**C-053**

**Imaging analysis of intrapancreatic vein under various pathological conditions of the pancreas with multi-detector CT scanning**

N. Hongo, H. Mori, R. Takaji, Y. Yamada, S. Matsumoto; Oita/JP

**C-054**

**Pancreatic adenocarcinoma: Facing the beast**

F. González, J. Izquierdo, C. Juanco, G. Blanco, M. Gutierrez, M. Lopez, M. Silvan; Santander/ES

**C-055**

**Cystic pancreatic masses: A systematic approach based on imaging findings**

F. González, A. Fernandez, C. Juanco, R. Pellon, J. Izquierdo, M. Lopez, M. Silvan; Santander/ES

**C-056**

**Primary and secondary pancreatic lymphoma: Diagnostic criteria on imaging**

C. Triantopoulou, Z. Touloumis, P. Porfyridis, I. Fagadaki, P. Maniatis, I. Sifas, J. Papailiou, C. Dervenis; Athens/GR

**C-057**

**Imaging of hypervascular pancreatic lesions: Endocrine tumor and others**

S. Arizono, H. Isoda, Y. Maetani, Y. Hirokawa, K. Shimada, K. Togashi; Kyoto/JP

**C-058****Cystic pancreatic tumors: Imaging review with pathologic correlation**

C.A. [Silva](#)<sup>1</sup>, M. Pimenta<sup>2</sup>, A. Salgueiro<sup>1</sup>; <sup>1</sup>Matosinhos/PT, <sup>2</sup>Porto/PT

**C-059****Cystic lesions of the pancreas: CEUS, MRI and MRCP features**

G.A. Zamboni, M. D'Onofrio, G. Carboognin, A. Casarin, L. Bassi, R. [Pozzi Mucelli](#); *Verona/IT*

**C-060****Intraductal papillary mucinous neoplasm of the pancreas: Assessment of the grade of dysplasia using multislice CT**

H. [Ogawa](#), S. Itoh, M. Ikeda, K. Suzuki, S. Naganawa; *Nagoya/JP*

**C-062****Predictive value of multidetector CT in determination of pancreatic cancer resectability**

S. [Mazzeo](#), C. Cappelli, V. Battaglia, D. Caramella, G. Caproni, A. Belcari, S. Pallocci, C. Bartolozzi; *Pisa/IT*

**C-063****Multidetector CT in the assessment of neuroendocrine pancreatic neoplasms nature: Comparison between CT and histological findings**

S. [Mazzeo](#), V. Battaglia, C. Cappelli, D. Caramella, G. Caproni, D. Campani, F. Mosca, C. Bartolozzi; *Pisa/IT*

**C-064****Complete pancreatic encasement of portal vein: Circumportal pancreas**

S.-Y. [Song](#)<sup>1</sup>, J.-Y. Oh<sup>1</sup>, Y. Kim<sup>2</sup>, O.-K. Cho<sup>1</sup>, B.-H. Koh<sup>1</sup>; <sup>1</sup>Seoul/KR, <sup>2</sup>Kuri/KR

**Abdominal Viscera (Solid Organs)****Miscellaneous****C-065****How diffusion and relaxation related factors influence MR signal intensity (SI): A pictorial introduction to MR diffusion weighted imaging (DWI) studies**

F. [Pasquinelli](#)<sup>1</sup>, L. Mannelli<sup>1</sup>, G. Belli<sup>1</sup>, L. Politi<sup>2</sup>, F. Vizzutti<sup>1</sup>, U. Arena<sup>1</sup>, S. Colagrande<sup>1</sup>; <sup>1</sup>Florence/IT, <sup>2</sup>Milan/IT

**C-066****Imaging of extranodal lymphoma from head to toe**

L. [Goncalves](#), S. Dias, H. Torrão, S. Kurochka, A.C. Costa, C. Leite, V. Mendes; *Braga/PT*

**C-067****State-of-the-art imaging of spleen**

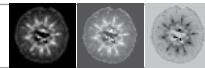
J. [Quintero](#), C. Roqué, D. Hernández, A. Olazábal, I. Guasch; *Badalona/ES*

**C-068****Virtual non-contrast (VNC) dual energy scanning with dual source CT (DSCT): Initial experience**

R. [Ma](#)<sup>1</sup>, C. Liu<sup>1</sup>, J. Chen<sup>2</sup>; <sup>1</sup>Jinan/CN, <sup>2</sup>Peking/CN

**C-069****Comprehensive approach to inflammatory pseudotumor: Various radiologic manifestations that mimic malignant tumors**

S. [Park](#)<sup>1</sup>, H. Kim<sup>2</sup>, J. Lee<sup>2</sup>, J. Kim<sup>2</sup>, K.-S. Cho<sup>2</sup>; <sup>1</sup>Ulsan/KR, <sup>2</sup>Seoul/KR



**C-070**

**The rebirth of venous imaging: MR venography using a blood pool contrast agent and time resolved imaging**

J.R. Bottomley; *Sheffield/UK*

**C-071**

**The spaces of the retroperitoneum: A pictorial review**

A. Almeida, M. Castro, J. Loureiro, B. Viamonte, J.M. Pereira; *Porto/PT*

**C-072**

**Imaging findings in alveolar hydatid disease**

M. Inal, C.K. Parsak, M. Celiktas, S. Soyupak, F. Binokay, E. Akgül, K. Bıçakçı, E. Aksungur, M. Oguz; *Adana/TR*

**C-073**

**Familial amyloidosis (Portuguese variant): Spectrum of manifestations**

J. Pires, M. França, M. Teixeira Gomes, R. Themudo, J. Reis; *Porto/PT*

**C-074**

**Understanding dissemination of diseases in the peritoneal cavity: What we should know about peritoneal anatomy**

A.G. Spanoudaki, N.A. Courcoutsakis, G.E. Daskalogiannakis, P.K. Prassopoulos; *Alexandroupolis/GR*

**C-075**

**Be mindful of melanoma**

R. Summerfield, G. Rylands, M. Goldstein, M. Metelko, N. Lane; *Stoke-on-Trent/UK*

**C-076**

**Comprehensive review of the interfascial plane of the retroperitoneum**

M. Kim, S. Lee, Y. Won, Y. Ku, K. Kim; *Seoul/KR*

**C-077**

**Marginal zone B-cell non-Hodgkin lymphoma of mucosa-associated lymphoid tissue (MALToma) type: Imaging findings**

O. Maksimovic, W. Bethge, J. Pintoffi, M. Vogel, R. Bares, C.D. Claussen, M. Horger; *Tuebingen/DE*

**C-078**

**Fat only and water only gradient echo MR imaging of the abdomen. Part I: Basic concepts and imaging findings in the liver**

E.M. Merkle, D.I. Schulz, D.T. Boll, D. Marin; *Durham, NC/US*

**C-079**

**Fat only and water only gradient echo MR imaging of the abdomen. Part II: Extrahepatic imaging findings**

E.M. Merkle, D.I. Schulz, D.T. Boll, D. Marin; *Durham, NC/US*

**C-080**

**Comparison of observer performance in a non-traumatic acute abdomen CT setting**

N.-H. Stauffer, A. Tempia, P. Rau, D. Guntern, N. Kotzampassakis, E. Melloul, C. Picht, T. Prot, S. Schmidt, C. Vallet, A. Denys; *Lausanne/CH*

**C-081**

**Should splenic injuries be reclassified with multi-detector contrast-enhanced CT?**

R. Young, H. Hiller, J.-L. Cook; *Swindon/UK*

**C-082**

**A quantitative method for splenomegaly assessment by superparamagnetic iron oxide-enhanced MRI with SHU-555A (Resovist®)**

M.L. Paolucci, S. Ciolli, L. Santoro, N. Villari, S. Colagrande; *Firenze/IT*

**C-083**

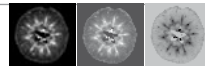
**Iron distribution in the upper abdomen, bone marrow and myocardium in beta-thalassemia major: Assessment with quantitative MR imaging**

O. Papakonstantinou, E. Alexopoulou, N. Economopoulos, K. Foufa, A. Katamis, V. Ladis, A. Gouliamos, N. Kelekis; *Athens/GR*

**C-084**

**Whole body MDCT in patients with multiple trauma: Is there still need for abdominal ultrasound follow-up studies?**

T. Meindl, M. Koerner, T. Vogl, M.F. Reiser, U. Linsenmaier; *Munich/DE*



**Breast**

**Biopsy**

**C-085**

**MRI-guided interventional procedures: Reasons for failure**

B. Viamonte, L. Melão, A. Almeida, N.P. Leite, R.G. Cunha; *Porto/PT*

**Breast**

**Digital Mammography**

**C-086**

**Effect of a computer-aided detection system on radiologists' performance in detection of lesions on mammograms obtained by using a phase contrast digital mammography system**

T. Tanaka, N. Nitta, S. Ota, K. Tsuchiya, Y. Murakami, S. Kitahara, M. Wakamiya, A. Furukawa, M. Takahashi, K. Murata; *Otsu/JP*

**C-087**

**Low-dose digital mammography technique by using image processing**

Y. Fujimura<sup>1</sup>, H. Nishiyama<sup>1</sup>, T. Masumoto<sup>1</sup>, S. Kono<sup>1</sup>, T. Furukawa<sup>1</sup>, J. Horiguchi<sup>1</sup>, K. Ito<sup>1</sup>, T. Ishida<sup>2</sup>; <sup>1</sup>*Hiroshima/JP*, <sup>2</sup>*Higashi-Hiroshima/JP*

**C-088**

**Effects of reduced dose on observer accuracy with digital mammography**

A. Roselli, F. Pediconi, S. Padula, V. Dominelli, S. Cagioli, M.L. Luciani, R. Passariello; *Rome/IT*

**C-089**

**Texture analysis of mammograms: A useful tool in differential diagnosis of breast lesions**

G.P. Giannakopoulou, S. Golemati, D. Koulocheri, A. Tsakiri, J. Stoitsis, A. Nonni, F. Zagouri, K.S. Nikita, G.C. Zografos; *Athens/GR*

**Breast**

**Magnetic Resonance**

**C-090**

**The variety of MR imaging findings on fibroadenoma of the breast: Correlation with pathologic features**

J. Tominaga, H. Hama, S. Takahashi; *Sendai/JP*

**C-091**

**MRI of the breast: The breast and so much more**

R. Bitar, P. Crystal, S. Kulkarni, T.H. Helbich; *Toronto, ON/CA*

**C-092**

**Mimickers of malignancy and pitfalls in breast MR imaging**

P. Crystal, K. Bukhanov, Y.-Y. Ong, A. Scaranelo, S. Kulkarni, T. Helbich; *Toronto, ON/CA*

**C-093**

**Unusual malignant breast lesions at breast MRI: Radiologic-histopathologic correlation**

A. Iglesias Castañón, M. Arias Gonzalez, J. Mañas Uxó, M. Herreros Villaravitz, J. León Alonso; *Vigo/ES*

**C-094**

**Can breast MRI help evaluate the tumor response to primary radiochemotherapy in patients with large breast cancers?**

**Illustration with clinical cases**

F. Thibault, A. Tardivon, A. Athanasiou, M.A. Bollet, B. Sigal-Zafrani, R. Salmon, A. Fourquet; *Paris/FR*

**C-095****Evaluation of suspicious nipple discharge by MR mammography based on BI-RADS MRI descriptors**

Y. Tokuda, K. Kuriyama, A. Nakamoto, H. Sai, K. Yutani, Y. Kunitomi, K. Haneda, M. Kawai, N. Masuda, M. Takeda; *Osaka/JP*

**C-096****Diffusion-weighted imaging in breast malignancies: Comparison of different b-value**

J. Lee, H.-Y. Choi; *Seoul/KR*

**C-097****Quantitative diffusion weighted imaging in locally advanced breast cancer**

C. Iacconi, C. Marini, M. Giannelli, A. Cilotti, D. Mazzotta, C. Bartolozzi; *Pisa/IT*

**C-098****Phase contrast mammography system: Contrast-detail comparison for mammography between phase contrast imaging and flat panel digital images**

R. Ishii<sup>1</sup>, A. Yoshida<sup>1</sup>, M. Ishii<sup>2</sup>, Y. Higashida<sup>3</sup>; <sup>1</sup>Mihara/JP, <sup>2</sup>Kurashiki/JP, <sup>3</sup>Fukuoka/JP

**C-099****Advantages of contrast enhanced MRI in the estimation of breast cancer extent before breast-preserving surgery**

E.A. Yukhno, G. Trufanov, S.V. Serebryakova, V.A. Fokin; *St. Petersburg/RU*

**C-100****Analysis of breast MR limits in the management of patients treated with neo-adjuvant chemotherapy**

A. Cilotti, C. Marini, D. Mazzotta, C. Iacconi, C. Giacconi, V. Battaglia, R. Scandiffio, C. Bartolozzi; *Pisa/IT*

**C-101****Contrast enhanced MR mammography (CE-MRM): Comparison of the blood pool agent B22956/1 and Gd-DTPA for detection and differentiation of benign and malignant breast lesions**

V. Dominelli, F. Pediconi, C. Catalano, A. Roselli, S. Cagioli, M.L. Luciani, R. Passariello; *Rome/IT*

**C-102****Evaluation of neoadjuvant chemotherapeutic response of breast cancer by MRI: Accuracy of MRI in predicting pathological complete response**

N. Gomi, Y. Yamamoto, K. Matsueda, Y. Fujiwara, H. Tanaka, A. Kohno, Y. Miyagi, T. Iwase, Y. Itoh, F. Akiyama; *Tokyo/JP*

**C-103****The role of MRI in the diagnosis of Paget's disease of the breast**

O. Golan, F. Sperber, A. Gat; *Tel Aviv/IL*

**C-104****Use of T2-weighted images in computer-aided diagnosis for breast MRI**

W. van Aalst<sup>1</sup>, T. Twellmann<sup>1</sup>, H. Buurman<sup>2</sup>, F. Gerritsen<sup>2</sup>, B.M. ter Haar Romeny<sup>1</sup>; <sup>1</sup>Eindhoven/NL, <sup>2</sup>Best/NL

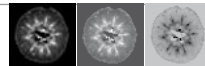
**C-105****The influence of tumor histology, tumor size, tumor grade and receptor profile on the pharmacokinetic parameters of invasive carcinomas of the breast**

R.M. Mann, H. Huisman, J. Veltman, C. Boetes; *Nijmegen/NL*

**C-106****Diffusion-weighted imaging in breast cancer: ADC value and tumor grading correlation**

P. Belli, M. Costantini, C. Ierardi, R. Lombardi, E. Bufi, L. Bonomo; *Rome/IT*





**C-107**

**ADC value changes in diffusion MRI after neoadjuvant chemotherapy in breast cancer**

P. Belli, M. Costantini, C. Ierardi, R. Lombardi, E. Bufi, L. Bonomo; *Rome/IT*

**C-108**

**Comparison of the diagnostic value of visual assessment of parametric images calculated by a computer assisted diagnosis system with region of interest (ROI) measurement in MR-mammography (MRM)**

P.A.T. Baltzer, D.M. Renz, S. Beger, C. Freiberg, J. Böttcher, M. Gajda, O. Camara, W.A. Kaiser; *Jena/DE*

**C-109**

**Diagnostic role of CAD-analysis of axillary lymph nodes on pretherapeutic dynamic breast MRI on breast cancer patients**

A. Malich, A. Kott, A. Beier, R. Gorna, J. Feger, S. Schnohr, H.-F. Holzwarth; *Nordhausen/DE*

**C-110**

**Contrast appearance of breast cancer after chemotherapy: A radiologic and histopathologic correlation in dynamic magnetic resonance mammography (MRM)**

A.B. Herzog, P.A.T. Baltzer, D.M. Renz, M. Dietzel, M. Gajda, O. Camara, W.A. Kaiser; *Jena/DE*

**C-111**

**Dynamic CE-MRI of the breast at 3.0T: A prospective comparative study between spectral fat suppression and image subtraction**

E. Eracleous<sup>1</sup>, C. Economides<sup>1</sup>, S. Kokkis<sup>1</sup>, I. Seimenis<sup>1</sup>, K. Kiale<sup>2</sup>, C. Tsompanioti<sup>2</sup>, O. Benekos<sup>2</sup>, N. Kelekis<sup>2</sup>; <sup>1</sup>Nicosia/CY, <sup>2</sup>Athens/GR

**C-112**

**Malignant and benign inflammation in MR-mammography: Can MRI distinguish inflammatory breast carcinoma from acute mastitis?**

D.M. Renz, P.A.T. Baltzer, J. Böttcher, F. Thaher, T. Vag, M. Gajda, O. Camara, W.A. Kaiser; *Jena/DE*

**C-113**

**Oedema in MR-mammography: Analysis of different localisations and their correlation with histology in invasive breast carcinomas**

D.M. Renz, P.A.T. Baltzer, M. Herold, A.B. Herzog, M. Dietzel, M. Gajda, O. Camara, W.A. Kaiser; *Jena/DE*

**C-114**

**Diagnosis of ductal carcinoma in situ using contrast-enhanced magnetic resonance mammography**

T. Vag, P.A.T. Baltzer, D.M. Renz, S.O.R. Pfeleiderer, M. Gajda, O. Camara, W.A. Kaiser; *Jena/DE*

**C-115**

**Diffusion weighted imaging for the assessment of lymph node status in patients with invasive breast carcinomas**

D.M. Renz, P.A.T. Baltzer, J. Böttcher, D. Grässel, M. Dietzel, A. Preisser, J.R. Reichenbach, W.A. Kaiser; *Jena/DE*

**C-116**

**The accuracy of diffusion weighted imaging (DWI) for the diagnosis of residual breast cancer after neoadjuvant chemotherapy**

R. Woodhams, S. Kakita, H. Hata, M. Ozaki, H. Nishimaki, S. Kan, K. Hayakawa; *Sagamihara/JP*

**C-117**

**Analyzing "texture" of lesion enhancement kinetics in dynamic contrast enhanced MRI for breast cancer diagnosis**

A. Karahaliou<sup>1</sup>, K. Vassiou<sup>2</sup>, D. Kanavou<sup>2</sup>, S. Skiadopoulos<sup>1</sup>, A. Yiakoumelos<sup>1</sup>, L. Costaridou<sup>1</sup>; <sup>1</sup>Patras/GR, <sup>2</sup>Larissa/GR

**Breast****Ultrasound****C-118****BI-RADS 3, 4 and 5 lesions on US: Five categories and their diagnostic efficacy and pitfalls in interpretation**

M. Kim, S. Chong, Y. Kim, S. Park, E. Park; *Seoul/KR*

**C-119****Value of ultrasonic breast cancer screening in women with fibrocystic disease (FCD)**

D.V. Passynkov<sup>1</sup>, I.V. Kliouchkin<sup>2</sup>, O. Pasyunkova<sup>1</sup>; <sup>1</sup>*Loshkar-Ola/RU*, <sup>2</sup>*Kazan/RU*

**C-120****Ultrasound (US) and Doppler findings in intracystic breast tumors**

O. Catalano, A. Nunziata, M. Mattace Raso, L.A. Illiano, A. Siani; *Naples/IT*

**C-121****Applicability of contrast enhanced ultrasonography (CEUS) to the differential diagnosis of solid breast lesions**

D. Stanzani, M.C. Chammas, L. Chala, M.C.V. Campos, N. Barros, G.G. Cerri; *São Paulo/BR*

**C-123****Computerized scheme for detection of masses in whole breast ultrasound images**

Y. Ikedo<sup>1</sup>, D. Fukuoka<sup>1</sup>, T. Hara<sup>1</sup>, H. Fujita<sup>1</sup>, E. Takada<sup>2</sup>, T. Endo<sup>3</sup>, T. Morita<sup>3</sup>, G. Lee<sup>1</sup>; <sup>1</sup>*Gifu/JP*, <sup>2</sup>*Tochigi/JP*, <sup>3</sup>*Nagoya/JP*

**C-124****Circumscribed solid breast masses increased in size during follow-up: Is biopsy necessarily prompted?**

Y.-M. Park, J.-S. Park, S.-J. Choi, J.-R. Juhn, S.-J. Lee, J.-H. Ryu, O.-H. Kim; *Busan/KR*

**C-125****Quantitative evaluation of contrast-enhanced ultrasound in differentiating benign and malignant breast lesions**

F. Marchisio, A. Pecchi, N. Caproni, P. D'Alimonte, R. Battista, B. Canossi, P. Torricelli; *Modena/IT*

**Breast****Miscellaneous****C-126****Focal mammographic asymmetric densities: Clinical-pathological review**

A.S.R. Preto, A. Carneiro, M. Pimenta, F. Pimentel, J. Gonçalves; *Porto/PT*

**C-127****Mammographic calcifications revisited**

A.S.R. Preto, A. Carneiro, S. Guimarães, F. Pimentel, J. Gonçalves, I. Amendoeira; *Porto/PT*

**C-128****TRAM (transverse rectus abdominus myocutaneous) flap: Breast cancer recurrence**

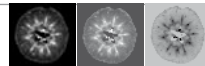
C. Carneiro, S. Alves, A. Ferrão, A. Guimarães; *Porto/PT*

**C-129****Correlation of breast lesions detected with magnetic resonance imaging with targeted ultrasound**

M. Balaro, K. Dias, M. Jasbik, V. Freitas, A. Brandão, F. Kestelman; *Rio de Janeiro/BR*

**C-130****Infection and inflammatory lesions of breast: Imaging and pathology correlations**

J. An, C. Han, J. Kang, E. Kim; *Seoul/KR*



**C-131**

**Incidental breast lesions on computed tomography**

N. Goyal<sup>1</sup>, T. Barton<sup>1</sup>, V. Rachapalli<sup>2</sup>, S. Ramamurthy<sup>2</sup>, N. Jain<sup>2</sup>, S. Rashid<sup>2</sup>, N. Evans<sup>1</sup>; <sup>1</sup>Newport/UK, <sup>2</sup>Cardiff/UK

**C-132**

**Clinical usefulness of low-dose 64-channel multidetector-row CT in prone position for breast cancer patients**

B. Seo<sup>1</sup>, K. Cho<sup>2</sup>, O. Woo<sup>2</sup>, G. Son<sup>2</sup>, Y. Kim<sup>1</sup>, S. Kim<sup>2</sup>; <sup>1</sup>Ansan City/KR, <sup>2</sup>Seoul/KR

**C-133**

**Breast cyst: Is it always benign?**

N.M. Abdel Razeq; Cairo/EG

**C-134**

**Can lowering the maximum compression force in mammography reduce pain and still provide acceptable results?**

K. Chida, Y. Komatsu, M. Sai, A. Nakagami, K. Fujisawa, E. Sato, T. Yamashita, T. Yamada, M. Zuguchi; Sendai/JP

**C-135**

**Mammography and MRI features of malignant lymphoma of the breast**

X.X.H. Wang, W.J. Peng; Shanghai/CN

**C-136**

**Diagnostic yield in tele mammography**

C. Vilà Parera, F. Gras, X. Salvador, M. López, X. Martínez, R. Salvador; Barcelona/ES

**C-137**

**Breast MRI and breast SPECT: Are they alternative or mutually complementary to each other?**

V.S. Dekan, S. Serebryakova, T. Demshina, G. Trufanov; St. Petersburg/RU

**C-138**

**Association between radiologists' experience and accuracy in interpreting screening mammograms**

M. Maristany, F. Ferrer, X. Castells, J. Royo, J. Martinez, F. Macià, A. Solano, J. Sanchez, I. Vollmer; Barcelona/ES

**Cardiac****MRI****C-139****Abnormal ventriculoarterial connections in the adult patient: From embryogenesis to the MR gantry**

B. Graca, M. Seco, P. Donato, F. Caseiro-Alves; *Coimbra/PT*

**C-140****Effectiveness of cardiovascular MRI in operative/interventional decision making in patients with mitral stenosis**

A.J. Baxi, M.M.A. Siddiqui, R.K.V. Khattari, K.L. Tourani; *Hyderabad/IN*

**C-141****Postoperative MR imaging in cyanotic congenital heart diseases: Normal findings**

C. Méndez, R. Soler, E. Rodríguez, C. Martínez, I. Raposo; *La Coruña/ES*

**C-142****Postoperative MR imaging in cyanotic congenital heart diseases: Complications**

R. Soler, C. Méndez, E. Rodríguez, C. Martínez, I. Raposo; *La Coruña/ES*

**C-143****Cardiac MRI identifies and characterizes disease of the pericardium**

A.J. Misselt, S.R. Harris, E.E. Williamson, P.A. Araoz; *Rochester, MN/US*

**C-144****Clinical experience with whole-heart coronary MRA using 3 Tesla: Comparison with 64-slice MDCT**

Q. Yang, K. Li, R. Merges, J. Chen, J. An; *Beijing/CN*

**C-145****Cardiac MRI for evaluating various causes and clinical significance of paradoxical septal motion**

D. Kim<sup>1</sup>, J. Byun<sup>1</sup>, S. Choi<sup>2</sup>; <sup>1</sup>*Gwangju/KR*, <sup>2</sup>*Bungdang/KR*

**C-146****Impact of trans-ventricular pressure on interventricular septal configuration**

F.A. Calabrese, M. Francone, M. Mangia, I. Iacucci, C. Catalano, R. Passariello; *Rome/IT*

**C-147****Emerging role of cardiac MRI in the pre-implantation assessment of patients who are candidates for cardiac resynchronization therapy**

V.G. Katsiva<sup>1</sup>, N. Kelekis<sup>2</sup>, O. Benekos<sup>2</sup>, P. Flevani<sup>2</sup>, C. Tsompanlioti<sup>2</sup>, N. Economopoulos<sup>2</sup>, D. Kremastinos<sup>2</sup>, A. Gouliamos<sup>2</sup>; <sup>1</sup>*Piraeus/GR*, <sup>2</sup>*Athens/GR*

**C-148****MR phase contrast flow measurements: Quality assurance in clinical routine**

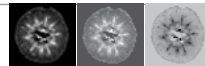
S. Pertschy, D. Hartung, R. Döker, B. Graumann, G.P. Meyer, M. Galanski, J. Lotz; *Hannover/DE*

**C-149****MRI assessment of genetic dilated cardiomyopathy in LMNA-mutations carriers**

M. Anttila<sup>1</sup>, J. Koikkalainen<sup>2</sup>, J. Lötjönen<sup>2</sup>, T. Heliö<sup>1</sup>, S. Kivistö<sup>1</sup>, K. Lauerma<sup>1</sup>; <sup>1</sup>*Helsinki/FI*, <sup>2</sup>*Tampere/FI*

**C-150****Dynamic intraventricular gradient during dobutamine stress echocardiography: Is there a myocardial structural change? Evaluation by MRI**

P. Donato, M.J. Ferreira, B. Graca, S. Monteiro, R. Martins, L.A. Providência, F. Caseiro-Alves; *Coimbra/PT*



**C-151**

**Preoperative evaluation of cardiac morphology and haemodynamic changes in patients with septal defects: Comparison of MRI and EchoCG**

E.A. Mershina, T.S. Pustovitova, V.E. Sinitsyn, S.L. Dzemeshevich; *Moscow/RU*

**C-152**

**Image quality and reconstruction timing of dual-source CT coronary angiography: Impact of the heart rate**

Y. Wang, Z. Jin, Z. Zhang, L. Kong, L. Song; *Beijing/CN*

**C-153**

**Effectiveness of cine SSFP MR technique for the estimation of infarct size after acute myocardial infarction in comparison with contrast enhanced inversion recovery technique (CE-IR)**

E. Algeri, I. Carbone, H. Grazhdani, F. Ciolina, N. Galea, M. Basood, C. Catalano, R. Passariello; *Rome/IT*

**C-154**

**Evaluation of hemodynamic effects of transjugular intrahepatic portosystemic shunt (TIPS) on cardiac function of patients with cirrhosis: Preliminary results with cardiac magnetic resonance (CMR)**

M. Francone, F. Calabrese, I. Iacucci, R. Lezoche, G. Lombardi, M. Merli, C. Catalano, R. Passariello; *Rome/IT*

**C-155**

**Atrial volumetry (AV) in patients with pulmonary arterial hypertension (PAH): Preliminary results on cardiac MR (CMR)**

F. Calabrese, M. Francone, R. Le Zoche, P. Lucchesi, C. Catalano, R. Passariello; *Rome/IT*

**C-156**

**Cardiac mass characterization using MR cine and late enhancement images**

F. Cohen, A. Jacquier, J.-Y. Gaubert, F. Thuny, P. Champsaur, J.-M. Bartoli; *Marseille/FR*

**C-157**

**Long term therapy follow-up in patients with cardiac sarcoidosis via cardiac MRI**

M. Heller, S. Zangos, T.J. Vogl; *Frankfurt a. Main/DE*

**C-158**

**Global and regional right and left ventricular function in adult patients with repaired tetralogy of Fallot: Assessment with CMR**

D. Piotrowska-Kownacka, L. Kownacki, M. Kusmierczyk, E. Kowalik, K. Mirosław, L. Krolicki; *Warsaw/PL*

**C-159**

**Late gadolinium-enhanced magnetic resonance imaging in non-compacted ventricular myocardium (NCVM) as potential expression of the disease severity**

E. Grassedonio, E. Cracolici, M. Galia, G. Lo Re, T.V. Bartolotta, M. Midiri, R. Lagalla; *Palermo/IT*

**C-160**

**Hypertrophic cardiomyopathy: Evaluation with contrast enhanced MRI and stress MR with perfusion assessment**

T.J. Pereira<sup>1</sup>, P. Donato<sup>2</sup>, M.J. Ferreira<sup>2</sup>, L.A. Providência<sup>2</sup>, F. Caseiro-Alves<sup>2</sup>; <sup>1</sup>V. N. *Gaia/PT*, <sup>2</sup>*Coimbra/PT*

**Cardiac**

**Multidetector CT**

**C-161**

**Dual source CT cardiac angiography: An A to Z guide for medical residents**

M. Diaz, C. Hernandez, B. Zudaire, M. Arraiza, G. Bastarrika, J.-I. Bilbao; *Pamplona/ES*

**C-162****Primer of cardiovascular pharmacology for radiologists**

B. Graca, R. Teixeira, A. Pereira, P. Donato, F. Caseiro-Alves; *Coimbra/PT*

**C-163****Comprehensive assessment of type A aortic dissection by ECG-gated MDCT**

J.-N. Heo<sup>1</sup>, S. Jeon<sup>2</sup>, Y. Choi<sup>2</sup>, C. Park<sup>1</sup>, Y. Kim<sup>1</sup>, D. Park<sup>1</sup>; <sup>1</sup>*Guri-si, Gyeonggi-do/KR*, <sup>2</sup>*Seoul/KR*

**C-164****Coronary calcium scoring: How to avoid pitfalls**

K. Gruszczynska<sup>1</sup>, M. Rengo<sup>1</sup>, F. Pugliese<sup>1</sup>, W.B. Meijboom<sup>1</sup>, A.C. Weustink<sup>1</sup>, A. Rossi<sup>1</sup>, M.L. Dijkshoorn<sup>1</sup>, J. Baron<sup>2</sup>, N.R. Mollet<sup>1</sup>, A. Laghi<sup>3</sup>, P.J. de Feyter<sup>1</sup>, G.P. Krestin<sup>1</sup>; <sup>1</sup>*Rotterdam/NL*, <sup>2</sup>*Katowice/PL*, <sup>3</sup>*Latina/IT*

**C-165****Several factors negatively influence stent imaging in multidetector computed tomography-coronary angiography (MDCT-CA): How to recognize and reduce this "huge" problem**

F. Alberghina<sup>1</sup>, G. Runza<sup>1</sup>, F. Pugliese<sup>2</sup>, L. Damiani<sup>1</sup>, M. Midiri<sup>1</sup>, R. Lagalla<sup>1</sup>; <sup>1</sup>*Palermo/IT*, <sup>2</sup>*Rotterdam/NL*

**C-166****Tips and tricks for interpreting and reporting a cardiac CT study: A step-by-step instruction**

S. Leschka<sup>1</sup>, H. Alkadhi<sup>1</sup>, F.T. Schmid<sup>2</sup>, P. Stolzmann<sup>1</sup>, L. Husmann<sup>1</sup>, B. Stinn<sup>2</sup>, B. Marincek<sup>1</sup>, S. Wildermuth<sup>2</sup>; <sup>1</sup>*Zurich/CH*, <sup>2</sup>*St. Gallen/CH*

**C-167****Impact of screening for coronary artery disease (CAD) using 64-slice CT in asymptomatic low to intermediate risk patients**

J. Hoe, M. Shahid; *Singapore/SG*

**C-168****Value of multi-slice CT in characterizing coronary atherosclerotic plaques: An animal study**

G. Shi, L. Yang, Q. Wang, J. Li, Q. Xu; *Beijing/CN*

**C-169****Step and shoot: Preliminary experiences with a new scan type for CT-coronary angiography**

O. Klass, S. Wuchenauer; S. Feuerlein, M. Jeltsch, M.H.K. Hoffmann; *Ulm/DE*

**C-170****Detection of cardiac allograft vasculopathy by multi-detector CT and whole-heart MR coronary angiography**

H. Machida, S. Nunoda, M. Fujimura, E. Ueno, S. Morita, K. Suzuki, K. Otsuka; *Tokyo/JP*

**C-171****Anatomical remodeling of the left atrium in paroxysmal atrial fibrillation by multislice CT in comparison with chronic atrial fibrillation and normal sinus rhythm**

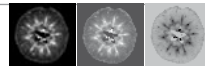
N. Funabashi<sup>1</sup>, K. Nakamura<sup>1</sup>, M. Uehara<sup>1</sup>, Y. Shiina<sup>1</sup>, T. Murayama<sup>1</sup>, H. Takaoka<sup>1</sup>, K. Suzuki<sup>2</sup>, M. Terao<sup>2</sup>, Y. Mita<sup>2</sup>, F. Maeda<sup>2</sup>, M. Ueda<sup>1</sup>, I. Komuro<sup>1</sup>; <sup>1</sup>*Chiba/JP*, <sup>2</sup>*Tateyama/JP*

**C-172****64-slice CT imaging of coronary artery lesions in patients with unstable angina**

Y. Wang, Z. Jin, L. Kong, Z. Zhang, L. Song, S. Zhang; *Beijing/CN*

**C-173****Assessment of myocardial viability in humans using contrast-enhancement MDCT: Effect of time and kinetics of iodine contrast medium in LV blood, normal and infarcted myocardium**

A. Jacquier<sup>1</sup>, N. Amabile<sup>1</sup>, F. Cohen<sup>1</sup>, J. Bartoli<sup>1</sup>, D. Revel<sup>2</sup>, P. Croisille<sup>2</sup>; <sup>1</sup>*Marseille/FR*, <sup>2</sup>*Lyon/FR*



**C-174**

**Diagnostic accuracy of 64-row gadolinium-enhanced CT coronary angiography**

P. Carrascosa<sup>1</sup>, C.M. Capuñay<sup>1</sup>, A. Deviggiano<sup>1</sup>, M. Bettinotti<sup>2</sup>, A. Goldsmit<sup>2</sup>, J. Carrascosa<sup>1</sup>, M.J. Garcia<sup>3</sup>; <sup>1</sup>Vicente López/AR, <sup>2</sup>Buenos Aires/AR, <sup>3</sup>New York, NY/US

**C-175**

**Quantitative myocardial perfusion evaluation with MDCT**

P. Carrascosa, C.M. Capuñay, J. Vallejos, E. Martín López, A. Deviggiano, J. Carrascosa; Vicente López/AR

**C-176**

**Myocardial bridging and related coronary atherosclerotic burden by 64-slice CT coronary angiography**

L. La Grutta<sup>1</sup>, G. Runza<sup>1</sup>, V. Alaimo<sup>1</sup>, L. Damiani<sup>1</sup>, F. Alberghina<sup>1</sup>, G. Lo Re<sup>1</sup>, F. Cademartini<sup>2</sup>, M. Midiri<sup>1</sup>, R. Lagalla<sup>1</sup>; <sup>1</sup>Palermo/IT, <sup>2</sup>Parma/IT

**C-177**

**Radiation induced DNA double-strand breaks in cardiac CT**

M.A. Kuefner<sup>1</sup>, J. Hamann<sup>1</sup>, M. Wiederseiner<sup>1</sup>, S.A. Schwab<sup>1</sup>, K. Anders<sup>1</sup>, S. Achenbach<sup>1</sup>, W. Bautz<sup>1</sup>, M. Lobrich<sup>2</sup>, M. Uder<sup>1</sup>; <sup>1</sup>Erlangen/DE, <sup>2</sup>Homburg a.d. Saar/DE

**C-178**

**Effect of preoxygenated breath holding on heart rate variability**

N. Karunanithy, E. Nicol, M.B. Rubens, S.P.G. Padley; London/UK

**C-179**

**Dual source CT coronary angiography improves image quality in morbid obese patients compared to 64-section CT coronary angiography**

B. Stinn<sup>1</sup>, S. Leschka<sup>2</sup>, F.T. Schmid<sup>1</sup>, M. Thurnheer<sup>1</sup>, B. Schultes<sup>1</sup>, S. Wildermuth<sup>1</sup>; <sup>1</sup>St. Gallen/CH, <sup>2</sup>Zurich/CH

**C-180**

**Assessment of coronary artery bypass grafts by 64 slice multidetector computed tomography**

I. Elia, A. Batista, A. Lainez, J. Estornell, A. Núñez, V. Hervás; Valencia/ES

**C-181**

**Metabolic syndrome and accelerated atherosclerosis. From clinical data to quantitative arterial involvement: An emerging application of whole body CT angiography**

A. Napoli, M. Anzidei, B. Cavallo Marincola, C. Zini, P.L. Di Paolo, K. Lanciotti, C. Catalano, R. Passariello; Rome/IT

**C-182**

**Clinical impact of whole body computed tomography angiography (WB-CTA) in patients with suspected coronary artery disease: Incremental value of total atherosclerosis burden assessment**

A. Napoli, M. Anzidei, B. Cavallo Marincola, C. Zini, P.L. Di Paolo, K. Lanciotti, C. Catalano, R. Passariello; Rome/IT

**C-183**

**Cardiac computed tomography in the evaluation of extensive left anterior descending coronary artery vein patch reconstruction: Preliminary findings**

M. Fusaro<sup>1</sup>, E. Calderon<sup>2</sup>, F. Santini<sup>2</sup>, E. Maffei<sup>1</sup>, A. Palumbo<sup>1</sup>, M. Romano<sup>3</sup>, S. Seitun<sup>3</sup>, F. Cademartini<sup>4</sup>; <sup>1</sup>Parma/IT, <sup>2</sup>Verona/IT, <sup>3</sup>Genoa/IT, <sup>4</sup>Rotterdam/NL

**C-184****Diagnostic accuracy of 64-slice computed tomography coronary angiography based on “Mayo Clinic” coronary calcium risk score: Per-segment and per-patient analysis**

F. Cademartiri<sup>1</sup>, A. Palumbo<sup>2</sup>, E. Maffei<sup>2</sup>, M. Fusaro<sup>2</sup>, A. Aldrovandi<sup>2</sup>, N.R. Mollet<sup>1</sup>, A.C. Weustink<sup>1</sup>, G.P. Krestin<sup>1</sup>; <sup>1</sup>Rotterdam/NL, <sup>2</sup>Parma/IT

**C-185****Detection of significant coronary artery stenosis on a per-patient but not on a per-vessel or per-segment basis in 64-slice CT angiography**

J.M. Kerl<sup>1</sup>, C. Herzog<sup>1</sup>, P. Zwerner<sup>2</sup>, S. Bisdas<sup>1</sup>, T.J. Vogl<sup>1</sup>, G. Savino<sup>2</sup>, U.J. Schoepf<sup>2</sup>; <sup>1</sup>Frankfurt a. Main/DE, <sup>2</sup>Charleston, SC/US

**C-186****Accuracy of dual-source computed tomography in the assessment of plaque morphology: Use of quantitative plaque analysis software in comparison with IVUS virtual histology**

H. Brodoefel<sup>1</sup>, C. Burgstahler<sup>2</sup>, M. Heuschmid<sup>2</sup>, I. Tsiglikas<sup>2</sup>, A. Reimann<sup>2</sup>, A. Kopp<sup>2</sup>, S. Schroeder<sup>2</sup>, C. Claussen<sup>2</sup>, M. Clouse<sup>1</sup>; <sup>1</sup>Boston, MA/US, <sup>2</sup>Tuebingen/DE

**C-187****Diagnostic accuracy of 64-slice computed tomography in quantification of coronary artery stenosis: Comparison with intravascular ultrasound**

J. Hur, B. Choi, Y. Kim, H.-J. Lee, D. Choi, K. Choe; Seoul/KR

**C-188**

(No material submitted to EPOS™)

**The role of color identification for coronary plaque imaging in interpretation of gray scale coronary MDCT**

S. Choi<sup>1</sup>, Y. Kim<sup>1</sup>, H. Seon<sup>1</sup>, Y. Choi<sup>1</sup>, N. Chang<sup>2</sup>, H. Kang<sup>1</sup>; <sup>1</sup>Kwangju/KR, <sup>2</sup>Chollanamdo/KR

**C-189****Evaluation of atrial septal aneurysms with ECG-gated multi-slice computed tomography**

E. Czekajska-Chehab, M. Tomaszewska, E. Siek, A. Tomaszewski, G. Staskiewicz, S. Uhlig, A. Drop; Lublin/PL

**C-190****Detection and assessment of intracardiac thrombi with multi-slice computed tomography (MSCT)**

E. Czekajska-Chehab, E. Siek, G.J. Staskiewicz, S. Uhlig, A. Tomaszewski, A. Wysokinski, A. Drop; Lublin/PL

**Cardiac****Miscellaneous****C-191****Coronary artery anomalies**

J. Alex<sup>1</sup>, K.T. Tan<sup>2</sup>, M. Hamilton<sup>2</sup>, P. Wilde<sup>2</sup>, G.M. McGann<sup>2</sup>; <sup>1</sup>Cheltenham/UK, <sup>2</sup>Bristol/UK

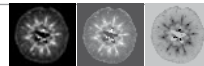
**C-192****The myocardial perfusion imaging finding of transient ischaemic dilatation: A pictorial review**

N. Kakouros, V. Raman, S. Adhya, K. Foord; Hastings/UK

**C-193****Fat in the heart: Causes and meaning**

G. Tardaguila de la Fuente, F. Tardaguila, J.A. Aguilar, R. Prada, D. Castellon, G. Fernandez; Vigo/ES





**C-194**

**Getting to the heart of the matter: An illustrative look at cardiomyopathies**

S. Harris, A. Misselt, P. Araoz, E. Williamson; *Rochester, MN/US*

**C-195**

**Imaging of fetal coronary arteries with gray and color flow Doppler sonography**

E.-K. Ji, T. Kwon, S. Kang, D. Kim; *Seoul/KR*

**C-196**

**Unusual cardiac metastases in oncologic patients: A pictorial review**

E. Salvador, A. Martinez, M.S. Gallego, E. Zabia; *Madrid/ES*

**C-197**

**Where is the wire? A review of cardiological wires and devices**

M. Metelko, R. Summerfield, M. Goldstein, D. Deva, H. Sandmann; *Stoke on Trent/UK*

**C-198**

**Atrial fibrillation: Imaging guidance of ablation therapy with CT**

C.W. Lott; *Adelaide/AU*

**C-199**

**Follow-up chest X-rays after CABGs: A waste of time and money**

S. Karthik, D.J. O'Regan; *Leeds/UK*

**C-200**

**Integrating CT in minimally invasive treatment of the coronary arteries**

D. Ruijters<sup>1</sup>, N.H. Bakker<sup>1</sup>, O. Wink<sup>1</sup>, B.M. ter Haar Romeny<sup>2</sup>, P. Suetens<sup>3</sup>; <sup>1</sup>*Best/NL*, <sup>2</sup>*Eindhoven/NL*, <sup>3</sup>*Leuven/BE*

**Chest****Lung****C-201****Radiologic staging of primary lung cancer: Questions and answers**

B. Graca, L. Semedo, M. Seco, A. Canelas, L. Teixeira, F. Caseiro-Alves; *Coimbra/PT*

**C-202****High-resolution computed tomography in adult patients with cystic fibrosis: Findings and scoring**

B. Graca, J.F. Costa, A. Canelas, F. Gamboa, L. Teixeira, F. Caseiro-Alves; *Coimbra/PT*

**C-203****Imaging appearances of adult congenital lung diseases: A pictorial review**

E.T.D. Hoey, P. Bhatnagar, K. Mankad, M. Darby, R. Robertson; *Leeds/UK*

**C-204****Cystic fibrosis: A compendium of HRCT findings**

R. Gadahadh, I.P. Gunatunga, S. Singh, M. Crane, H. Adams; *Cardiff/UK*

**C-205****Pictorial review of CT features of endobronchial lesions**

P. McParland, R. Ayer, S. Harden, I. Brown, C. Peebles; *Southampton/UK*

**C-206****Ground-glass opacification: Is it possible to achieve a specific diagnosis based on radiological and clinical features?**

C. Vázquez Olmos, M. Rodríguez Rodríguez, A. Sánchez González, J. Plasencia Martínez, C. Ordoñez González, C. Ortiz Morales; *Murcia/ES*

**C-207****Pictorial review of imaging appearances of bronchioalveolar cell carcinoma (BACC)**

P. McParland, N. Raiton, C. Peebles, I. Brown, S. Harden; *Southampton/UK*

**C-208****Chronic pulmonary embolism: A radiologic overview**

E. Ballesteros Gomiz<sup>1</sup>, E. Castañer González<sup>1</sup>, X. Gallardo Cistare<sup>1</sup>, J.M. Mata Duaso<sup>1</sup>, Y. Pallardó Calatayud<sup>2</sup>, A. Valera Abril<sup>1</sup>; <sup>1</sup>*Sabadell/ES*, <sup>2</sup>*Alzira/ES*

**C-209****High-resolution computed tomography of the chest: What every radiologist should know**

N. Bharwani, S. Grubnic; *London/UK*

**C-210****Benign or malignant? Pulmonary nodules from a lung cancer screening setting**

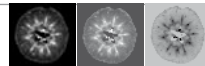
A.L.M. Leusveld, Y.R. Zhao, D.M. Xu, Y. Wang, M. Oudkerk; *Groningen/NL*

**C-211****Pulmonary nodules: Reliable growth rate estimates using volume doubling time**

A.L.M. Leusveld, Y.R. Zhao, D.M. Xu, Y. Wang, M. Oudkerk; *Groningen/NL*

**C-212****Ground glass nodules: Follow-up in non-symptomatic patients**

A. Leusveld, Y. Zhao, Y. Wang, D. Xu, M. Oudkerk; *Groningen/NL*



**C-213**

**Cavitary lung lesions: Differential diagnosis**

M.C.T. Gomes, J. Pires, R. Maia, P. Varzim, M. Ribeiro; *Oporto/PT*

**C-214**

**Thoracic lymphoma: Tackling the diagnostic dilemma**

E.J. Goldstraw, H. Verma, N. Bharwani, S. Grubnic; *London/UK*

**C-215**

**Is surgical anastomosis the only place where bronchial pathology takes place in the lung transplanted patient?**

C. García-Roch, P. Fraga, M. Pastrana, A. De Pablo, G. Mora, M. Diezhandino; *Madrid/ES*

**C-216**

**Radiologic manifestations of pulmonary nontuberculous mycobacterial infection: A pictorial review**

R. Maia, P. Santos, M. Gomes, J. Pires, M. França, J. Reis; *Oporto/PT*

**C-217**

**High resolution computed tomography findings of the lungs in febrile neutropaenic patients**

Z. Khaleel, R. Lavakumar, G. Avery, V. Arora; *Hull/UK*

**C-218**

**Non-infectious pulmonary complications of HIV infection: A pictorial review**

D.R. Vummidi, R. Siripurapu, C. Allen; *Manchester/UK*

**C-219**

**Neuroendocrine pulmonary tumors**

D. Chourmouzi, L. Papadopoulou, G. Boulogianni, A. Drevelegas; *Thessaloniki/GR*

**C-220**

**What is your diagnosis for nodular ground-glass opacity? Emphasis on CT features related to malignancy and its prognostic value**

H. Lim, C. Park, J. Goo, H. Lee, C. Lee, J.-G. Im; *Seoul/KR*

**C-221**

**Parenchymal sparing techniques in surgical treatment of central bronchogenic carcinoma: Pre-operative and post-operative assessment with MDCT**

M. Mereu, P. Santodirocco, P. D'Ambrosio, V. Di Mizio, P. Campese, M.L. Storto; *Chieti/IT*

**C-222**

**Pulmonary sarcoidosis: Typical and atypical radiological manifestations on HRCT in histologically confirmed cases**

E. Criado Paredes, M. Sánchez González, P. Arguís Giménez, F. Calaf Forn, J. Ramírez, T.M. de Caralt Robira, M.J. Perea Palazón, A. Xaubet; *Barcelona/ES*

**C-223**

**Atypical pulmonary metastases simulating benign disease: A CT pictorial review**

J. Ni Mhuircheartaigh<sup>1</sup>, B. Sabloff<sup>2</sup>, T. Mylene<sup>2</sup>, C. Roche<sup>1</sup>, J. Bruzzi<sup>1</sup>; <sup>1</sup>*Galway/IE*, <sup>2</sup>*Houston, TX/US*

**C-224**

**Pulmonary amyloidosis: The great pretender**

E. Kelliher<sup>1</sup>, C. Meehan<sup>1</sup>, A. Browne<sup>1</sup>, J. Ni Mhuircheartaigh<sup>1</sup>, P. O'Sullivan<sup>2</sup>, J. Bruzzi<sup>1</sup>; <sup>1</sup>*Galway/IE*, <sup>2</sup>*Houston, TX/US*

**C-225****Primary lung cancer complicated with pneumothorax following chemotherapy or radiation therapy: Emphasis on various CT features and correlation with pathogenesis**

J. Kim<sup>1</sup>, H. Kim<sup>2</sup>, K. Lim<sup>2</sup>, S.-H. Lee<sup>2</sup>; <sup>1</sup>Seoul/KR, <sup>2</sup>Goyang/KR

**C-226****Silicosis: Analysis of CT findings**

L. Xu, W. Peng; *Shanghai/CN*

**C-227****CT screening for asbestos-exposed former workers: Preliminary results**

K. Ashizawa, K. Nakanishi, S. Tsutsui, T. Kadota, A. Ishiyama, T. Yamaguchi, M. Uetani; *Nagasaki/JP*

**C-228****Analysis of asbestos-related lung cancer found in screening for former workers**

A. Ishiyama, K. Ashizawa, T. Hayashi, K. Nakanishi, T. Kadota, S. Tsutsui, M. Uetani; *Nagasaki/JP*

**C-229****Airway distensibility by HRCT decreases with severity of COPD**

M. Bellia, F. Cannizzaro, N. Scichilone, A. La Sala, S. Russo, V. Bellia, M. Midiri; *Palermo/IT*

**C-230****Pulmonary nodular ground-glass opacities in patients with extrapulmonary cancers**

K. Kim<sup>1</sup>, C. Park<sup>2</sup>, H. Lee<sup>2</sup>, T. Kim<sup>3</sup>, C. Lee<sup>2</sup>, H. Lee<sup>2</sup>, E.-A. Park<sup>2</sup>, J.-G. Im<sup>2</sup>; <sup>1</sup>Goyang/KR, <sup>2</sup>Seoul/KR, <sup>3</sup>Bundang/KR

**C-231****Usual interstitial pneumonia (UIP) under treatment: High resolution computed tomography (HRCT) changes observed under interferon-gamma-1b and colchicine**

K. Malagari, E. Emmanouil, D. Letsou, D. Antonopoulos, E. Alexopoulou, S. Argentos, P. Vasilidou, A. Gouliamos; *Athens/GR*

**C-232****Evaluation of small airways in healthy, COPD and asthmatic individuals using high resolution computed tomography**

K. Gao<sup>1</sup>, L. Zhang<sup>1</sup>, J. Li<sup>1</sup>, S. Dutta<sup>2</sup>; <sup>1</sup>Beijing/CN, <sup>2</sup>Waukesha, WI/US

**C-233****Pulmonary veins crossing pleural fissures: A cause for false positive findings in low-dose CT exams performed for early lung cancer detection**

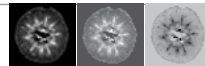
A. Villanueva, L. Díaz, A. Alonso-Burgos, C. Hernández, G. Bastarrika, B. Zudaire, J.C. Pueyo, J. Larrache, L. Garcia del Barrio, M. Arraiza, M.J. Herraiz, J. Arias, J. Broncano; *Pamplona/ES*

**Chest****Pathology****C-234****Spectrum of imaging findings in bronchioloalveolar carcinoma with pathologic correlation**

J.F. Costa, A. Canelas, A. Costa, L. Teixeira, L. Carvalho, F. Caseiro-Alves; *Coimbra/PT*

**C-235****Imaging spectrum in bronchial carcinoid tumor of the thorax: Radiologic with surgical and pathologic correlation**

J.J. Cortes Vela, J. Arenas Jiménez, J.M. Corcoles Padilla, J.M. Garcia Marco, S. Bolufer Nadal, J. De La Hoz Rosa; *Alicante/ES*



**C-236**

**Morphologic and pathophysiologic evaluation of the peripheral lung using ultra-high-resolution CT**

H. Ikura<sup>1</sup>, K. Shimizu<sup>1</sup>, M. Ikura<sup>1</sup>, T. Mochizuki<sup>2</sup>, T. Nagareda<sup>3</sup>, Y. Imai<sup>4</sup>; <sup>1</sup>Tokyo/JP, <sup>2</sup>Ehime/JP, <sup>3</sup>Hyogo/JP, <sup>4</sup>Kanagawa/JP

**C-237**

**Assessment radiologic-pathologic: Image-guided 25-gauge needle like accurate and safe lung lesions diagnosis in 785 patients**

E. Valbuena, V. Suarez, I. Torres, M. Pardo, P. Lopez Ferrer, A. Mariño Enriquez; *Madrid/ES*

**C-238**

**Clinical/pathologic correlations in 553 patients with primary centrilobular findings on HRCT of the thorax**

F. Okada, Y. Ando, S. Tanoue, S. Matsumoto, H. Mori; *Yufu/JP*

**Chest**

**PET**

**C-239**

**Unsuspected metastases demonstrated on PET-CT in patients with non-small cell lung carcinoma**

C.P. Mullan, O. McNally, T. Lynch; *Belfast/UK*

**C-240**

**Significant incidental CT findings identified on PET-CT unrelated to the primary pathology: Does the CT component of PET-CT need formal reporting?**

R. Kirke, D. Barnes, J. Raj, R. Coulden, J. Entwisle; *Leicester/UK*

**Chest**

**Technical Aspects**

**C-241**

**CT guided percutaneous needle biopsy of the lung: Technical considerations and outcome**

S.E. Mc Sweeney<sup>1</sup>, P. Hodnett<sup>1</sup>, J.-A. Shepard<sup>2</sup>, M.M. Maher<sup>1</sup>; <sup>1</sup>Cork/IE, <sup>2</sup>Boston, MA/US

**C-242**

**Lung volume quantification in multislice CT using different software tools**

B. Zudaire, M. Diaz, C. Hernandez, A. Alvarez, G. Bastarrika; *Pamplona/ES*

**C-243**

**Effect of image processing in digital chest radiograph on pulmonary nodules detection**

K. Wang, W. He, G. He; *Beijing/CN*

**C-244**

**Automated airway measurements in patients with COPD based on CT imagery**

W. Recheis, A. Foedinger, R. Eder, R. Frank, C.M. Kaehler, D. zur Nedden; *Innsbruck/AT*

**C-245**

**Validation of airway wall volume using micro-CT**

S. Gupta<sup>1</sup>, S. Siddiqui<sup>1</sup>, S.V. Hainsworth<sup>1</sup>, D. Mawby<sup>1</sup>, J. Entwisle<sup>1</sup>, S. McDonald<sup>2</sup>, P.J. Withers<sup>2</sup>, C.E. Brightling<sup>1</sup>; <sup>1</sup>Leicester/UK, <sup>2</sup>Manchester/UK

**C-246**

**CT angiography and 3D post processing in the evaluation of congenital vascular anomalies of the thorax**

A. Morra<sup>1</sup>, A. Clemente<sup>2</sup>, M. Del Borrello<sup>1</sup>, S. Berretta<sup>3</sup>, P. Greco<sup>1</sup>; <sup>1</sup>Albignasego/IT, <sup>2</sup>Ferrara/IT, <sup>3</sup>Catania/IT

**C-247****Computer-aided detection (CAD) in lung cancer screening at chest MDCT: ROC analysis of CAD vs. radiologist performance**

F. Fraioli, L. Bertoletti, M. Mennini, G. Serra, C. Catalano, R. Passariello; *Rome/IT*

**C-248****Prospective evaluation of quantitative computed tomography to predict postoperative lung function in patients with pulmonary neoplasm having a lobectomy**

F. Fraioli, L. Bertoletti, M. Mennini, G. Serra, C. Catalano, R. Passariello; *Rome/IT*

**C-249****Automatic volumetric assessment of pulmonary nodules enhancement: Correlation with axial measurements to evaluate benign and malignant nodules**

F. Fraioli, M. Mennini, S. Vetere, G. Serra, C. Catalano, R. Passariello; *Rome/IT*

**C-250****Volumetric evaluation of therapy response in patients with lung metastases: Preliminary results with a computer system and comparison with unidimensional measurements**

F. Fraioli, L. Bertoletti, M. Mennini, S. Vetere, C. Catalano, R. Passariello; *Rome/IT*

**C-251****Evaluation of the cross sectional change of pulmonary peripheral blood flow using CT perfusion**

J. Nakanishi<sup>1</sup>, K. Kodani<sup>2</sup>, Y. Shimatani<sup>2</sup>, M. Ametani<sup>3</sup>, T. Ogawa<sup>2</sup>; <sup>1</sup>Tottori-shi/J<sup>1</sup>, <sup>2</sup>Yonago-shi/J<sup>2</sup>, <sup>3</sup>Matue-shi/J<sup>3</sup>

**C-252****4-D model of peripheral pulmonary ventilation using synchrotron radiation CT**

H. Ikura<sup>1</sup>, K. Shimizu<sup>1</sup>, M. Ikura<sup>1</sup>, T. Mochizuki<sup>2</sup>, T. Nagareda<sup>3</sup>, Y. Imai<sup>1</sup>; <sup>1</sup>Tokyo/J<sup>1</sup>, <sup>2</sup>Ehime/J<sup>2</sup>, <sup>3</sup>Hyogo/J<sup>3</sup>

**C-253****Radiofrequency ablation and cryotherapy for inoperable pulmonary lung malignancy**

G.-Y. Jin, Y. Lee, Y. Choi, Y. Han; *Jeon-ju/KR*

**C-254****Is there an increased risk for pneumothorax when performing CT-guided lung punctures in patients with diffuse lung disease?**

M. Lönnemark, P. Örneholm, K. Lamberg, A. Magnusson; *Uppsala/SE*

**C-255**

(No material submitted to EPOS™)

**Quantitative assessment of airway dimension for pulmonary disease: Development of dedicated software for multi-detector CT**

S. Choi<sup>1</sup>, Y. Kim<sup>1</sup>, H. Seon<sup>1</sup>, N. Chang<sup>2</sup>, J. Kim<sup>1</sup>, J. Park<sup>1</sup>, H. Kang<sup>1</sup>; <sup>1</sup>Kwangju/KR, <sup>2</sup>Chollanamdo/KR

**C-256****Dual energy computed tomography (DECT) of the chest for differentiation of iodine and gadolinium enhanced artificial pulmonary nodules**

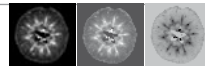
N. Knöss, H. Bolte, B. Hoffmann, M. Heller, J. Biederer; *Kiel/DE*

**C-257****Reproducibility of hemodynamic parameter quantification in lung tumors using dynamic CT**

U. Haberland<sup>1</sup>, A. Abramjuk<sup>2</sup>, E. Klotz<sup>1</sup>, N.D. Abolmaali<sup>2</sup>; <sup>1</sup>Forchheim/DE, <sup>2</sup>Dresden/DE

**C-258****Dual source CT angiography in patients with acute chest pain**

M. Arraiza, G. Bastarrika, J.C. Pueyo, B. Zudaire, A. Alonso-Burgos, A.J. Villanueva; *Pamplona/ES*



## Chest

### Vascular

#### **C-259** (No material submitted to EPOS™)

**The utility of radiographic vascular pedicle measurements in assessing the hemodynamic status of patients who recently underwent coronary artery bypass graft surgery**

V. Tatco, A. Villarosa; *Quezon City/PH*

#### **C-260**

**Pitfalls and artefacts in CT pulmonary angiography**

D.P. Deva, I. Britton, N.A. Watson; *Stoke-on-Trent/UK*

#### **C-261**

**Heart and great vessels: From chest radiograph to multislice CT**

D. Varona Porres, R. Mitjana, R. Monmany, J. Cáceres, C. Simón, M. Simonet; *Barcelona/ES*

#### **C-262**

**Partial anomalous pulmonary venous drainage: A review of CT images**

R. Summerfield, D. Deva, M. Goldstein, M. Metelko, N. Watson; *Stoke-on-Trent/UK*

#### **C-263**

**Spectrum of cardiovascular pathologies demonstrated by dual source CT angiography of the chest**

T. Heye, G. Richter, S. Ley, M. Schlieter; G. Szabo, G.W. Kauffmann, W. Hosch; *Heidelberg/DE*

#### **C-264**

**Radiological monitoring in pulmonary embolism with 64-multidetector CT**

G. Gallardo-Madueño, I. Torres, C. Fernandez-Capitán, A. Lorenzo, E. Alonso; *Madrid/ES*

#### **C-265**

**Comparison of two clinical prediction rules for suspected pulmonary embolism using multidetector computed tomography (MDCT) and CT venography**

I.R. Ozkan, C. Calisir; U.S. Yavas, F. Alatas, I.A. Cevik; *Eskisehir/TR*

#### **C-266**

**Evaluation of MDCT angiography and venography in pulmonary embolism**

J. Pamies Guilabert, P. Braun; *Valencia/ES*

#### **C-267**

**Utility of MDCT in identification of the hypertrophied bronchial artery causing hemoptysis: Correlation with bronchial angiography**

J.-Y. Rho, S.-J. Lee, M.-D. Kim, J.-Y. Jung, Y.-K. Lee; *Seongnam/KR*

#### **C-268**

**Quick and effective assessment of right ventricular dysfunction in the course of acute pulmonary embolism assessed with multislice computed tomography**

G.J. Staskiewicz, E. Czekajska-Chehab, J. Przegalinski, A. Tomaszewski, I. Wegrzyn-Szkutnik, K. Torres, A. Torres, R. Maciejewski, A. Drop; *Lublin/PL*

**Chest****Miscellaneous****C-269**

**A web-based, interactive tutorial and reference database in anatomy for chest imaging**

R. [Talanow](#)<sup>1</sup>, H.-H. Jend<sup>2</sup>; <sup>1</sup>*Cleveland, OH/US*, <sup>2</sup>*Bremen/DE*

**C-270**

**A web-based, interactive tutorial and reference database in thoracic tumor imaging**

R. [Talanow](#)<sup>1</sup>, H.-H. Jend<sup>2</sup>; <sup>1</sup>*Cleveland, OH/US*, <sup>2</sup>*Bremen/DE*

**C-271**

**Retracing the path: From MDCT to the chest X-ray**

J. [Palmer](#), J. Roldan, C. Reynés, M. Rodriguez, G. Sempere, J. Pueyo; *Palma de Mallorca/ES*

**C-272**

**A pictorial review of "signs in thoracic imaging"**

K. [Karuppasamy](#)<sup>1</sup>, J. Curtis<sup>2</sup>, M. Abhyankar-Gupta<sup>2</sup>, H. Fewins<sup>2</sup>; <sup>1</sup>*Chester/UK*, <sup>2</sup>*Liverpool/UK*

**C-273**

**Imaging findings of mediastinal masses with pathologic correlation: A pictorial review**

C. [Andreu](#), B. Lopez-Botet, M. Manzano, M. Olivera, P. Caballero; *Madrid/ES*

**C-274**

**The many faces of pleural disease**

M. [França](#)<sup>1</sup>, J. Pires<sup>1</sup>, M. Certo<sup>1</sup>, J. Calatayude<sup>2</sup>, D. Castellon<sup>2</sup>, P. Varzim<sup>1</sup>, M. Ribeiro<sup>1</sup>; <sup>1</sup>*Porto/PT*, <sup>2</sup>*Vigo/ES*

**C-275**

**Blunt chest trauma: Spectrum of findings with emphasis on MDCT**

S.K. [Lapsia](#), M. Goldstein, R. Davis, M. Bydder; *Stoke-on-Trent/UK*

**C-276**

**Congenital and developmental thoracic diseases occasionally seen in adults: Imaging features**

J. [Kim](#), E.-Y. Kang, O. Woo, H. Yong, K. Lee, Y.-W. Oh; *Seoul/KR*

**C-277**

**Multislice CT evaluation of the sternum**

T. [De la Espriella](#), A. Roque, D. Varona, J. Andreu, O. Persiva, E. Pallisa; *Barcelona/ES*

**C-278**

**Localized fibrous tumors of the pleura: Correlation of radiologic and pathologic findings**

A. [Piazza](#), M.A. Pastrana, P. Fraga, M. Reyero, C. Garcia Roch, J. de Miguel; *Madrid/ES*

**C-279**

**Management benefits and safety of computed tomography in patients undergoing extracorporeal membrane oxygenation therapy: Experience of a single centre**

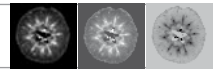
S.L. [Jepson](#), C. Harvey, J. Entwisle, G.J. Peek; *Leicester/UK*

**C-280**

**Tumours and masses of the pleura and chest wall: What the radiologist should know**

E. Kelliher<sup>1</sup>, A. Alzahrani<sup>1</sup>, T. Ramadan<sup>1</sup>, J. Ni Mhuircheartaigh<sup>1</sup>, E. Marom<sup>2</sup>, J. Bruzzi<sup>1</sup>; <sup>1</sup>*Galway/IE*, <sup>2</sup>*Houston, TX/US*





**C-281**

**Intercostal space imaging**

A. Villanueva, D. Aquerreta, A. Alonso-Burgos, J.J. Noguera, B. Zudaire, M. Arraiza, C.B. Hernandez; *Pamplona/ES*

**C-282**

**Lung ultrasound in the follow-up of patients with decompensated heart failure**

M. Busso, L. Cardinale, A. De Pascale, G. Garofalo, A. Ramanzin, G. Volpicelli, C. Fava; *Orbassano/IT*

**C-283**

**Echo contrast ultrasound in subpleural consolidations**

F.A. Bertolini<sup>1</sup>, C. Görg<sup>2</sup>, G. Mathis<sup>1</sup>; <sup>1</sup>*Rankweil/AT*, <sup>2</sup>*Marburg/DE*

**C-284**

**Endoscopic and CT findings of tracheal cysts**

A. Bray; *Rome/IT*

## Computer Applications

### C-285

#### Medico-legal issues in teleradiology

A. [Pinto](#), M. Scaglione, G. Ponticiello, G. Ruggiero, G. Russo, L. Di Nuzzo, L. Romano; *Naples/IT*

### C-287

#### How to read radiological literature: An evidence-based medicine approach dedicated for radiologists

A.N. [Chalazonitis](#)<sup>1</sup>, J. Tzovara<sup>1</sup>, G. Tsimitselis<sup>2</sup>, P. Porfyridis<sup>1</sup>, A. Fatsi<sup>1</sup>, M. Avlianos<sup>1</sup>, K. Papaioannou<sup>1</sup>, N. Ptohis<sup>1</sup>; <sup>1</sup>*Athens/GR*, <sup>2</sup>*Larissa/GR*

### C-288

#### Radiology search ([www.RadiologySearch.net](http://www.RadiologySearch.net)): A peer-reviewed and customizable radiology search engine

R. [Talanow](#); *Cleveland, OH/US*

### C-289

#### RaPSToR: An interactive, multidisciplinary, web-based content management system for teaching radiology, surgery and medicine residents

B.A. [Ahmed](#), S. Albahrani, R. McLeod, N. Jaffer; *Toronto, ON/CA*

### C-290

#### Semi-automated volumetry of the cerebrum, temporal lobe, and cerebellum-brainstem on 3D brain MR images

N. [Hayashi](#), S. Sanada, M. Suzuki, Y. Matsuura, T. Yamamoto, O. Matsui; *Kanazawa/JP*

### C-291

#### Understanding multimedia: Basic principles of interactive learning in radiology

J. [Weidemann](#), C. Schlorhauffer, G. Diekhaus, M. Galanski; *Hannover/DE*

### C-292

#### Process management in DICOM data exchange between hospitals

N. [Teodorovic](#), M. Uesbeck, A. Weilenmann, A. Rhyn, R. Naef; *Zurich/CH*

### C-293

#### Vascular post-processing, the shorter way to diagnosis: Modern concepts and new update

C.N. [De Cecco](#), M. Rengo, P. Paolantonio, R. Ferrari, F. Iafrate, A. Laghi; *Rome/IT*

### C-294

*(No material submitted to EPOS™)*

#### Guidelines for developing a successful quality assurance program for a radiology department

C.-S. [Yam](#), J. Kruskal; *Boston, MA/US*

### C-295

#### E-learning and radiology: Myths and facts

A.N. [Chalazonitis](#), D. Koumarianos, J. Tzovara, N. Ptohis, F. Laspas, G. Neofitou, M. Kelogrigoris, I. Apostolakis; *Athens/GR*

### C-296

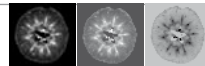
#### Viewing 4D cardiac CTA datasets with quicktime VR: An alternative to real-time dynamic volume rendering

C. [Wang](#), P. Quick, A. Persson, Ö. Smedby; *Linköping/SE*

### C-297

#### Radiology integrated training initiative: Are trainees using this new resource?

S. [Hussain](#), F. Almallah; *Birmingham/UK*



**C-298**

**Application of a computer aided diagnosis (CAD) system in MR-mammography (MRM): Do we need whole lesion time curve distribution analysis?**

P.A.T. Baltzer, D.M. Renz, S. Beger, C. Freiberg, M. Gajda, O. Camara, W.A. Kaiser; *Jena/DE*

**C-299**

**Comparison of diagnostic performance between multi-detector computed tomography and multi-planar volume rendering techniques in blunt chest trauma**

M. Le Guen, C. Beigelman, P. Grenier, O. Langeron; *Paris/FR*

**C-300**

**Automatic determination of absolute CT coordinates using a table inlay**

B.P. Selby<sup>1</sup>, G. Sakas<sup>1</sup>, S. Walter<sup>1</sup>, U. Stilla<sup>2</sup>; <sup>1</sup>*Darmstadt/DE*, <sup>2</sup>*Munich/DE*

**C-301**

**Diagnostic performance of detecting pulmonary nodules with computer-aided detection systems on multidetector-row helical CT scans: Comparison of LungVCar and Syngo LungCARE**

Y. Kawasumi, T. Yamada, K. Takase, T. Matsuhashi, S. Higano, T. Ishibashi, S. Takahashi; *Sendai/JP*

**C-302**

**Analysis of non-radiology queries for radiological data acquired more than 1 year ago**

P.M.A. van Ooijen, A. Broekema, M. Oudkerk; *Groningen/NL*

**C-303**

**Computed assisted follow-up of hepatic lesions in CT: A new software**

O. Lucidarme<sup>1</sup>, O. Ernst<sup>2</sup>; <sup>1</sup>*Paris/FR*, <sup>2</sup>*Lille/FR*

**C-304**

**Interactive virtual bronchoscopy application for transbronchial needle aspiration support**

W. Wojciechowski, M. Duplaga, M. Socha, A. Urbanik, K. Sladek; *Krakow/PL*

**C-305**

**Fast and precise rendering of virtual MR-cholangiopancreatography by a combination of thin-slice data acquisition and interactive visualization**

T. Yamagishi, T. Kawai; *Tokyo/JP*

**C-306**

**Evaluation of the optimal viewing size on soft-copy reading in digital chest radiography**

Y. Bessho<sup>1</sup>, M. Yamaguchi<sup>1</sup>, H. Fujita<sup>1</sup>, M. Azuma<sup>2</sup>; <sup>1</sup>*Habikino/JP*, <sup>2</sup>*Kashiwara/JP*

**C-307**

**Visualize coronary arteries in 3D without slabs: A fast and reliable 3D segmentation software for coronary CTA**

C. Wang, A. Persson, J. Engvall, M. Gjerde, Ö. Smedby; *Linköping/SE*

**C-308**

**Study of radiology report quality and accuracy using voice recognition software**

I.J. Barros D'Sa, C. Phillips, P. Lindley, T. Goodfellow, R. Wellings; *Coventry/UK*

**C-309**

**Development of a temporal registration system to integrate CT images and RF information from commercial RF system**

Y.H. Mah, B.J.J. Abdullah, K.H. Ng, L.K. Tan, J.H.D. Wong; *Kuala Lumpur/MY*

**C-310**

**Soft-copy reading of brain CT: Comparative performance study between high-grade and low-grade LCD in the electronic medical charts**

K. [Yoshimura](#)<sup>1</sup>, K. Shimamoto<sup>1</sup>, S. Naganawa<sup>1</sup>, K. Ichikawa<sup>2</sup>; <sup>1</sup>*Nagoya City/JP*, <sup>2</sup>*Kanazawa City/JP*

**C-311**

**Accuracy of image registration for head and neck cancer patients**

E. [Salli](#), E. Ahtola, H. Koivunoro, T. Seppälä, L. Kankaanranta, S. Savolainen; *Helsinki/FI*

**C-312**

**Decentralised upload of data from data on CD for storage into the PACS**

P.M.A. [van Ooijen](#), A. Broekema, M. Oudkerk; *Groningen/NL*

**C-313**

**Virtual pleuroscopy of the diaphragmatic pleura: Myth or reality**

A. [Khalil](#), H. Chabchoub, M.-F. Carette; *Paris/FR*

**C-314**

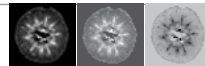
**Functional CT for quantifying tumor perfusion during tumor growth and antiangiogenic therapy in a rat model**

Z. [Kan](#), J. Huang, S. Phonkitkarun, S. Kobayashi, J. Yao, C. Charnsangavej; *Houston, TX/US*

**C-315**

**Radiology request card audit**

D. [Mondal](#), T.S. Conner, D.Y.F. Chung, N. Graham; *Milton Keynes/UK*



## Contrast Media

### C-316

#### Nephrogenic systemic fibrosis: What every radiologist must know

A. Manzella, P. Borba-Filho, F. Farias, C. Ribeiro, L. Santana, J. Kaercher, C. Zelaquett, J. Santos-Filho; *Recife/BR*

### C-317

#### Gas patterns in disease: Air, an undervalued contrast agent

I.P. Gunatunga<sup>1</sup>, S. Singh<sup>1</sup>, R. Gadahadh<sup>2</sup>, G. Davies<sup>1</sup>, E. Morris<sup>1</sup>; <sup>1</sup>*Cardiff/UK*, <sup>2</sup>*Swansea/UK*

### C-318

#### Gadobenate dimeglumine: A decade of clinical experience

M.A. Kirchin<sup>1</sup>, G. Pirovano<sup>2</sup>, N. Shen<sup>2</sup>, U. Halemane<sup>2</sup>, C. Venetianer<sup>2</sup>, J.R. Parker<sup>2</sup>, C. Schultz<sup>2</sup>, A. Spinazzi<sup>2</sup>; <sup>1</sup>*Milan/IT*, <sup>2</sup>*Princeton, NJ/US*

### C-319

#### A quantitative comparison of gadobenate dimeglumine, gadopentetate dimeglumine, gadoterate meglumine and gadodiamide in contrast enhanced MRI of the brain

B.M.M.M. Termote<sup>1</sup>, J. Vandevenne<sup>2</sup>, M.P.J. Van den Bekerom<sup>3</sup>, G. Verswijvel<sup>2</sup>, Y. Palmers<sup>2</sup>; <sup>1</sup>*Leuven/BE*, <sup>2</sup>*Genk/BE*, <sup>3</sup>*Amsterdam/NL*

### C-320

#### Extravasation complicating mechanical power injection of intravenous iodinated contrast for CT scan in 55,272 patients

S. Lau, H. Huang, S. Chan, C. Chan, T. Chan, F. Ching, T. Fung, C. Kam, W. Kan, T. Kong, K. Kwok, W. Lam, P. Poon, C. So, D. Tsang, W. Young, S. Choy, M. Tang; *Hong Kong/CN*

### C-321

#### Meta-analysis of randomized controlled trials comparing the nephrotoxicity of isoosmolar iodixanol with nonionic, low-osmolar contrast media

M. Heinrich, L. Häberle, V. Müller, W. Bautz, M. Uder; *Erlangen/DE*

### C-322

#### Assessment of the use of short injection duration of contrast material to reduce the total injection volume in 64-slice coronary CT angiography

F. Tatsugami, T. Kanamoto, G. Nakai, I. Narabayashi; *Takatsuki/JP*

### C-323

#### Iodinated contrast media increase DNA damage during CT

M.A. Kuefner<sup>1</sup>, S. Grudzenski<sup>2</sup>, N. Rief<sup>2</sup>, M. Heckmann<sup>1</sup>, S.A. Schwab<sup>1</sup>, W. Bautz<sup>1</sup>, M. Lobrich<sup>2</sup>, M. Uder<sup>1</sup>; <sup>1</sup>*Erlangen/DE*, <sup>2</sup>*Homburg a.d. Saar/DE*

### C-324

#### Superparamagnetic iron oxide-enhanced liver MRI with SHU-555A (Resovist®): New protocol infusion to improve arterial phase evaluation: A prospective study

L. Grazioli<sup>1</sup>, M. Bondioni<sup>1</sup>, L. Santoro<sup>2</sup>, G. Faralli<sup>2</sup>, L. Romanini<sup>1</sup>, S. Colagrande<sup>2</sup>; <sup>1</sup>*Brescia/IT*, <sup>2</sup>*Florence/IT*

### C-325

#### Myocardial delayed enhancement (DE): Time course of contrast-to-noise ratio (CNR) of infarcted myocardium (IM) to non-infarcted myocardium (NIM) and left ventricle cavity (LVC) after fractionated double dose (FDD) of gadobenate dimeglumine (Gd-BOPTA)

F. Secchi, G.D.E. Papini, G. Di Leo, F. Sardanelli, G.P. Cornalba; *Milan/IT*

### C-326

#### Characterisation of cisplatin adsorbed iron oxide nanoparticles for biomedical applications

M. Kettering<sup>1</sup>, H. Zorn<sup>1</sup>, S. Bremer-Streck<sup>1</sup>, H. Oehring<sup>1</sup>, M. Zeisberger<sup>1</sup>, C. Bergemann<sup>2</sup>, R. Hergt<sup>1</sup>, K.-J. Halbhuber<sup>1</sup>, W. Kaiser<sup>1</sup>, I. Hilger<sup>1</sup>; <sup>1</sup>*Jena/DE*, <sup>2</sup>*Berlin/DE*

**Genitourinary****Female****C-327****Solid components in endometriotic cysts: The role of MR imaging in detection and diagnosis**

Y. Okajima, A. Tamura, Y. Matsuo, Y. Onoda, S. Fuwa, M. Matsusako, K. Suzuki, Y. Saida; *Tokyo/JP*

**C-328****The many faces of pelvic endometriosis: Imaging findings with emphasis on unusual presentations**

S. Choudhary, N. Fasih, C. Walsh, D. Papadatos; *Ottawa, ON/CA*

**C-329****The imaging appearances of metastatic breast cancer simulating primary gynaecologic malignancy**

A.G. Rockall, N. Bharwani, P. Narayanan, S. Vinnicombe, A. Sahdev, R. Reznik; *London/UK*

**C-330****Multimodality approach to the proper diagnosis of gestational trophoblastic disease: Correlative analysis of ultrasound, MRI and pathologic specimen**

B.C. Devenney-Cakir, E. Kuligowska; *Boston, MA/US*

**C-331****Pelvic imaging after gynecological cancer treatment**

C. Campos, T.M. Cunha, A. Félix; *Lisbon/PT*

**C-332****Vulval and vaginal lesions: Imaging features with clinical and pathologic correlation**

J.-P. Akakpo, Y. Badachi, B. Lauratet, C. Genestie, F. Capron, J. Lefranc, P. Grenier; *Paris/FR*

**C-333****How to improve your technique and perform an almost painless hysterosalpingography**

A. Ghiatas, M. Gakis, A. Kateri; *Athens/GR*

**C-334****Uterine and tubal imaging: Correlation of hysterosalpingography, ultrasound and hysteroscopy findings**

M.R. Cozcolluela, L. Sanz, H. Gómez, J. Aramburu, L. Miranda, M.T. Martinez-Berganza, J.M. Mellado, H. Yagüe; *Tudela/ES*

**C-335****MR features of uterine leiomyomas with pathologic correlation**

P. Alves, T.M. Cunha, A. Félix; *Lisbon/PT*

**C-336****MR imaging for the differential diagnosis of dilated fallopian tubes**

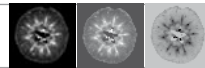
K. Tamaj, T. Koyama, N. Morisawa, K. Fujimoto, T. Ikeuchi, N. Satogami, K. Togashi; *Kyoto/JP*

**C-337****Secondary tumors in gynecologic organs: Usual, unusual imaging manifestations and pitfalls**

K. Matsuzaki, M. Takeuchi, H. Nishitani; *Tokushima/JP*

**C-338****Significance of diffusion-weighted imaging for the diagnosis of ovarian neoplasms with pathologic correlation**

S. Kakite, S. Fujii, K. Nishihara, Y. Kanasaki, M. Ishibashi, T. Ogawa; *Yonago/JP*



**C-339**

**Spectrum of findings on Mullerian duct anomalies at MRI**

P. Paolantonio, R. Ferrari, M. Rengo, P. Lucchesi, F. Vecchietti, A. Laghi; *Latina/IT*

**C-340**

**MRI pharmacokinetic modelling of treatment effects in patients with ovarian hyperstimulation syndrome**

L. Marti-Bonmati, R. Sanz; *Valencia/ES*

**C-341**

**Postpartum haemorrhage embolization with resorbable agents: Long term clinical results over fertility and menstrual function in 119 patients**

G. Gaia, P. Chabrot, R. Botchorishvili, L. Cassagnes, D. Gallot, A. Calcagno, M. Canis, G. Mage, L. Boyer; *Clermont Ferrand/FR*

**C-342**

**64-row MDCT virtual hysteroscopy**

P. Carrascosa<sup>1</sup>, M. Baronio<sup>2</sup>, C.M. Capuñay<sup>3</sup>, E. Martín López<sup>3</sup>, J. Vallejos<sup>3</sup>, C. Sueldo<sup>2</sup>, S. Papier<sup>2</sup>; <sup>1</sup>Vicente Lopez/AR, <sup>2</sup>Buenos Aires/AR, <sup>3</sup>Vicente López/AR

**C-343**

**PET-CT in recurrent ovarian cancer**

M.S. Lenhard, T.R.C. Johnson, C. Kuemper, R. Linke, N. Ditsch, A. Burges; *Munich/DE*

**C-344**

**3D transvaginal sonography in evaluation of combined endometrium and miometrium pathology before hysteroresection**

V.V. Gazhonova, A. Devyatovskaya, T. Kurganskaya, T. Smirnova; *Moscow/RU*

**C-345**

**Diffusion-weighted echo-planar 3T MRI and ADC mapping in the differential diagnosis of uterine masses: Usefulness for the detection of malignant tumors**

T. Namimoto, K. Awai, T. Nakaura, Y. Yanaga, Y. Yamashita; *Kumamoto/JP*

**C-346**

**Dynamic contrast-enhanced MR imaging of uterine cervical cancer: Tumor angiogenesis analysis and correlations with histomorphological tumor markers**

R. Domínguez-Oronoz, S. Gispert, V. Pineda, X. Merino, A. García, R. Vergés; *Barcelona/ES*

**C-347**

**Usefulness of vaginal distention with aqueous jelly to improve visibility of pelvic anatomical structures on MRI**

C. Marcotte, S. Novellas, M. Fournol, T. Caramella, P. Chevallier; *Nice/FR*

**C-348**

**Characterization of parametrium infiltration by MR imaging after preoperative radiotherapy in invasive carcinoma of the uterine cervix**

N.A. Rubtsova, S.A. Sedykh, E.G. Novikova, L.V. Demidova, O.B. Dubovetskaya; *Moscow/RU*

**C-349**

**The ovarian cystic masses: Evaluation with MRI**

N.V. Marchenko, G.E. Trufanov, A.V. Mischenko, I.A. Trofimenko; *St. Petersburg/RU*

**Genitourinary****Kidney****C-350**

**A review of percutaneous nephrolithotomy: Procedure planning, technical considerations and postprocedure evaluation**  
E. [Ward](#), A. Snow, J. O'Brien, R. Browne; *Co Dublin/IE*

**C-351**

**Evaluation of renal veins using 64-slice MDCT before laproscopic donor nephrectomy: Anatomy, variants and techniques**  
H. [Patel](#), M. Doctor, A.J. Shah, G. Tomar, M. Patel; *Ahmedabad/IN*

**C-352**

**Usefulness of contrast-enhanced ultrasonography in the evaluation of complex renal cysts**  
E. [Ballesteros Gomez](#), A. Malet Munté, J. Puig Domingo, A. Darnell Martin, A. Alguersuari Cabiscol, J.L. González Sala; *Sabadell/ES*

**C-353**

**Laparoscopic nephrectomy: A radiologist's guide**  
M.A. [Goldstein](#)<sup>1</sup>, S. Lapsia<sup>1</sup>, A. Golash<sup>1</sup>, S. Ghai<sup>2</sup>; <sup>1</sup>*Newcastle-under-Lyme/UK*, <sup>2</sup>*Toronto, ON/CA*

**C-354**

**High resolution ultrasonography in the diagnosis of the abnormalities of musculoskeletal system in patients with chronic renal failure**  
M.B. Damasio, A. [Tagliafico](#), C. Martinoli, F. Massarino, L. Derchi; *Genoa/IT*

**C-355**

**CT for planning of laparoscopic transplant donor nephrectomy: What to look for, why and how**  
N. [Bharwani](#), P. Skippage, U. Patel; *London/UK*

**C-356**

**Diffusion-weighted MR images of urothelial cancer**  
M. [Takeuchi](#), K. Matsuzaki, H. Nishitani; *Tokushima/JP*

**C-357**

**Post-operative complications evaluation after laparoscopic cryoablation of small renal masses: Role of multi-detector row computed tomography and magnetic resonance imaging**  
G. [Cardone](#), C. Iabichino, P. Mangili, A. Cestari, L. Nava, G. Guazzoni, G. Balconi; *Milan/IT*

**C-358**

**The treated kidney: A pictorial review of imaging findings following kidney-directed interventions, short-term and long-term follow-up**  
C. Farinas, S. Carter, M. Patnana, C. Sandler, J. [Szkларuk](#); *Houston, TX/US*

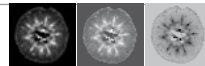
**C-359**

**Small solid renal cortical tumors: Differentiation with biphasic multi-detector row CT**  
J. [Kim](#), J. Cho, S. Kim; *Seoul/KR*

**C-360**

**Clinical and radiological analysis of 209 cases of crossed fused ectopia and horseshoe kidney**  
J. [Petersen](#), C. Schenk, P. Rehder, T. Trieb, B. Glodny; *Innsbruck/AT*





**C-361**

**Laparoscopic cryoablation (LC) of renal masses in patients affected by Von Hippel Lindau (VHL) renal cell carcinoma (RCC) syndrome and hereditary papillary (HP) RCC syndrome: Medium term outcome after 4-year magnetic resonance (MR) imaging follow-up**

G. Cardone, A. Cestari, L. Nava, P. Mangili, G. Guazzoni, G. Balconi; *Milan/IT*

**C-362** (No material submitted to EPOS™)

**Evaluation of the kidneys oxygenation in normal subjects and patients with renal transplant by BOLD MRI**

W. Xiao; *Hangzhou/CN*

**C-363**

**Evaluation of cystic renal masses with thin-section multidetector CT by using the Bosniak classification system**

J. Wang, A. Zhu; *Beijing/CN*

**C-364**

**Effects of abdominal compression and prolongation of acquisition delay on imaging quality improvement of 64-slice spiral CT urography: Initial clinical experience**

H. Sun, H.D. Xue, W. Liu, X. Wang, Z.Y. Jin; *Beijing/CN*

**C-365**

**Calculation of renal volume using respiratory-gated MRI: Intraobserver, interobserver, and interstudy reproducibility**

F. Di Terlizzi, S. Tiralongo, G. Di Leo, G.D.E. Papini, A. Morganti, F. Sardanelli, G.P. Cornalba; *Milan/IT*

**C-366**

**Laparoscopic ultrasound-guided radiofrequency ablation of renal cell carcinoma: Feasibility and outcomes**

S. Yoon, J. Cho, J. Oh, K. Nam, M. Kang, J. Lee, K. Sung; *Busan/KR*

**C-367**

**Performance of low-dose CT for detection of urolithiasis: A meta-analysis**

T. Niemann, T. Kollmann, G. Bongartz; *Basle/CH*

**C-368**

**Transplanted kidney's functional evaluation with contrast-enhanced power Doppler ultrasound and time/intensity curves**

P.V. Foti, R. Farina, F. Pennisi, C. Puglisi, M.V. Coronella, G.C. Ettore; *Catania/IT*

**C-369**

**Unenhanced multidetector CT in the diagnosis of urinary tract calculi: Factors predicting a positive yield and the incidence of significant alternate diagnoses**

H.G. Delaney, S. O Keeffe, J.F. Meaney; *Dublin/IE*

**C-370**

**Radiographic sizes versus surgical sizes of renal masses: Which is the true size of the tumor?**

B. Alicioglu, M. Kaplan, V. Yurut Caloglu, U. Usta, S. Levent; *Edirne/TR*

**C-372**

**Cortical renal volume measurements by using multi-detector row CT and its relationship with primary hypertension**

J. Vallejos, C.M. Capuñay, P. Carrascosa, J. Carrascosa; *Vicente López/AR*

**C-373**

**Multi-detector computed tomography feasibility in calculating the cortical renal volume**

J. Vallejos, C.M. Capuñay, P. Carrascosa, J. Carrascosa; *Vicente López/AR*

**C-374**

**Semi-automated region growing analysis of blood pool contrast enhanced MRI with open source software accurately predicts kidney volume as measured by a peri-operative fluid displacement technique in live renal donors**

G.C. Simpson, G. Roditi; *Glasgow/UK*

**C-375**

**CT accuracy in characterising renal tumors: The Sheffield experience and implications for optimal treatment**

R.P. Singarayan, F. Salim; *Sheffield/UK*

**C-376**

**Renal masses: Imaging at contrast-enhanced ultrasound and correlation with computed tomography**

M. Valentino<sup>1</sup>, M. Bertolotto<sup>2</sup>, C. Serra<sup>1</sup>, R. Schiavina<sup>1</sup>, P. Pavlica<sup>1</sup>, L. Barozzi<sup>1</sup>; <sup>1</sup>Bologna/IT, <sup>2</sup>Trieste/IT

**Genitourinary****Male****C-377**

**Imaging of the acute scrotum: Is there place for contrast-enhanced ultrasonography?**

H. Moschouris<sup>1</sup>, D. Kalikis<sup>1</sup>, E. Lampropoulou<sup>1</sup>, P. Goutzios<sup>2</sup>, M. Khalili<sup>1</sup>, D. Matsaidonis<sup>1</sup>; <sup>1</sup>Piraeus/GR, <sup>2</sup>Athens/GR

**C-378**

**Benign intratesticular cystic lesions: US features**

C. Pozuelo, D. Pozuelo, Y. Roca, L. Mones, M. Romero, X. Mallol; *Barcelona/ES*

**C-379**

**Peri-prostatic neurovascular bundle: Pre and post-surgical MRI assessment**

V. Panebianco, A. Sciarra, M. Osimani, D. Lisi, A. Consoli, R. Passariello; *Rome/IT*

**C-380**

**Variable imaging findings of prostate cancer: Focus on MR and PET/CT imaging**

J. Jang, J. Byun, M. Kim, Y. Lee, S. Oh, S. Rha, I. Yoo; *Seoul/KR*

**C-381**

**Sonographic appearance of tuberculous epididymitis and epididymo-orchitis**

N. Goyal<sup>1</sup>, V. Rachapalli<sup>2</sup>, S. Ramamurthy<sup>2</sup>, N. Jain<sup>2</sup>, S. Rashid<sup>2</sup>, D.L. Cochlin<sup>2</sup>, R. Clements<sup>1</sup>; <sup>1</sup>Newport/UK, <sup>2</sup>Cardiff/UK

**C-382**

**Prostate cancer (PC) evaluation: Usefulness of keyhole subtracted dynamic contrast-enhanced (CE) MR sequence**

G. Cardone, C. Iabichino, L. Nava, M. Freschi, P. Mangili, G. Guazzoni, G. Balconi; *Milan/IT*

**C-383**

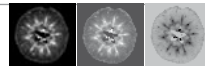
**Prostate adenocarcinoma: Evaluation of gadolinium dynamic T1-weighted MR imaging and ADC values**

K. Hayasaka<sup>1</sup>, T. Nishashi<sup>2</sup>, K. Nojiri<sup>1</sup>, K. Okamura<sup>1</sup>; <sup>1</sup>Ohbu/JP, <sup>2</sup>Nagoya/JP

**C-384**

**The usefulness of the ADC value in hormone refractory prostate cancers on diffusion-weighted MR images for predicting the effect of chemotherapy**

T. Yoshizako, M. Sumura, A. Wada, T. Hayashi, T. Katube, K. Uchida, S. Hara, N. Uchida, H. Kitagaki, M. Ikawa; *Izumo Shimane/JP*



**C-386**

**Local cancer recurrence after radical prostatectomy: Endorectal coil MR imaging at 1.5 T better accuracy level in selected patients**

V. [Panebianco](#), M. Osimani, M. Di Martino, D. Lisi, A. Consoli, R. Passariello; *Rome/IT*

**C-387**

**Prostate cancer: Pre-treatment evaluation with MRI and three-dimensional 1H-magnetic resonance spectroscopy**

S. Giusti, M. Lazzereschi, F. Francesca, A. Tognetti, C. [Bartolozzi](#); *Pisa/IT*

**C-388**

**Use of regional anesthesia during TRUS biopsy of the prostate results in decrease of patient pain and discomfort, without increasing complication rate**

D.D. Cokkinos, I. Theotokas, K. Pahos, A. Plagou, E. Skoulikaris, P.S. [Zoumpoulis](#); *Athens/GR*

**C-389**

**Endorectal magnetic resonance imaging (MRI) and magnetic resonance spectroscopy (MRS) in patients with elevated prostate specific antigen (PSA) level and prior negative biopsy**

S. [Cirillo](#), M. Petracchini, T. Gallo, P. Dellamonica, A. Manca, V. Tartaglia, D. Regge; *Candiolo/IT*

**C-390**

**Changes of testicular blood flow after vasectomy evaluated by ultrasound resistive index measurement**

R. [Faschingbauer](#), F. Aigner, E. Pallwein, G. Bartsch, F. Frauscher, L. Pallwein; *Innsbruck/AT*

**C-391**

**MRI and 1H MRS of benign disease of prostatic peripheral zone: Comparison with prostate adenocarcinoma**

L. [Zhou](#); *Shanghai/CN*

**Genitourinary**

**Miscellaneous**

**C-392**

**Amyloidosis: Review of imaging findings**

P. [Calvo](#), M. Céspedes, S. Aso, E. Fandiño, M.I. García-Hidalgo, Y. Herrero; *Toledo/ES*

**C-393**

**3 Tesla MRI of the pelvis: Challenges and solutions for clinical applications**

A. [Coupteau](#), F. Bonnet, C. Hoeffel, C. Portefaix, L. Job, C. Marcus; *Reims/FR*

**C-394**

**Cross sectional imaging appearances of extra-adrenal paragangliomas**

A. [Sahdev](#), N. Stephens, P. Narayanan, A.G. Rockall, R.H. Reznik; *London/UK*

**C-395**

**CT findings of incontinent urinary diversion (Bricker procedure) following radical cystectomy: A comprehensive pictorial review of postsurgical anatomy, common and uncommon complications**

V. [Catala](#), M. Solà, C. Quintian, J. Alberola, J. Palou, P. De la Torre; *Barcelona/ES*

**C-396**

**Pictorial review of urothelial tumours with pathological correlation**

S. Singh<sup>1</sup>, I.P. [Gunatunga](#)<sup>1</sup>, R. Gadahadh<sup>2</sup>, C. Davies<sup>1</sup>, G. Davies<sup>1</sup>; <sup>1</sup>Cardiff/UK, <sup>2</sup>Swansea/UK

**C-397**

**The MR-urethrography in the evaluation of urethral diseases**

C. [Parola](#), G. Regine, C. Pace, M. Gaffi, L. Adami; *Rome/IT*

**C-398****Fetal MRI: Incremental value in fetal imaging and impact on decision making**

J. Singh, K. Godbole, V.M. Bhide; *Pune/IN*

**C-399****The many faces of urolithiasis: A pictorial review**

A.S.R. Preto<sup>1</sup>, P. Sousa<sup>1</sup>, L. Guimarães<sup>2</sup>, J.T. Campos<sup>1</sup>, J. Gonçalves<sup>1</sup>, I. Ramos<sup>1</sup>; <sup>1</sup>Porto/PT, <sup>2</sup>Viseu/PT

**C-400****Preoperative pelvic lymph node detection: Diffusion weighted whole body imaging with background body signal suppression (DWIBS) increases the detection rate and reduces review time compared to conventional MR imaging**

W.M. Klerkx, W.B. Veldhuis, W.P.T.M. Mali, T. Takahara; *Utrecht/NL*

**C-401****Dose-reduced scan protocols according to individual body size: Cumulative unenhanced MDCT exposures in patients with flank pain from emergency**

S. Tartari, R. Rizzati, R. Righi, A. Deledda, K. Capello, G. Benea; *Lagosanto (Ferrara)/IT*

**C-402****Comparison of effective radiation doses of conventional and two-phase CT urography**

L.R. Williams, A. Smith, A. Hufton, A.J. Bradley; *Manchester/UK*

**C-403****High resolution ultrasound in the assessment of stenosis of the urethra**

G. Argento, S. Petta, G. Scavone, G. Fabbri, A. Panetta, V. David; *Rome/IT*

**C-404****Adrenocortical adenomas and pheochromocytomas: Mass and enhancement loss evaluation at 140-second delayed contrast-enhanced CT**

T. Yamamoto, H. Sugimoto; *Shimotsuke/JP*

**C-405****Characterization of adrenal lesions by using chemical shift MRI: Comparison between 3.0 T and 1.5 T scanners in quantitative evaluation**

T. Namimoto, K. Awai, T. Nakaura, Y. Yanaga, Y. Yamashita; *Kumamoto/JP*

**C-406****Multislice CT and MR imaging in the differentiation of adnexal masses**

A.C. Teiji, A. Charisiadi, C. Christakis, M. Doukas, D. Stefanou, E. Paraskevidis, C. Tsampoulas; *Ioannina/GR*

**C-407****MR imaging in differentiation of adrenal masses**

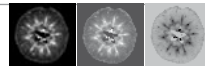
J. Zielonko, A. Babinska, M. Studniarek, R. Rzepko; *Gdansk/PL*

**C-408****CT urography in patients with gross hematuria: Risk vs. benefit correlated to age**

M. Sjöblom, P. Dahlman, L. Jangland, A. Magnusson; *Uppsala/SE*

**C-409****Whole-body CT for detection and management of renal injuries in polytraumatized patients**

I. Diez, M. Boada, M. Febrer, M. Osorio, A. Gelabert, A. Maroto, M. Teixidor, S. Juanpere; *Girona/ES*



## GI Tract

### Colon

#### C-410

##### MR colonography in inflammatory bowel disease at 3.0 T. Correlation with conventional colonoscopy

J. Bimola, S. Rodríguez, D. García, J. Panés, M. Pagés, C. de Juan, J.R. Ayuso, C. Ayuso; *Barcelona/ES*

#### C-411

##### CT colonographic characteristics of early invasive colorectal carcinomas: Correlation with colonoscopic and pathologic findings

M. Miyake<sup>1</sup>, G. Iinuma<sup>1</sup>, U. Tateishi<sup>1</sup>, T. Morimoto<sup>1</sup>, Y. Arai<sup>1</sup>, H. Taniguchi<sup>1</sup>, K. Sugimura<sup>2</sup>; <sup>1</sup>Tokyo/JP, <sup>2</sup>Kobe/JP

#### C-412

##### Isolated infarction of the cecum

R. Cytter-Kuint, D. Fisher, I. Hadas-Halpern; *Jerusalem/IL*

#### C-413

##### Cecal volvulus: Radiological findings of a frequently misdiagnosed disease

E. López-Pérez, P. Bartumeus, M.J. Martínez, L. Flors, G. Figueres, C. Leiva-Salinas; *Valencia/ES*

#### C-414

##### Appendix pathology: Far beyond acute appendicitis

B. Nieto Baltar, Y. Martínez Alvarez, N. Arevalo Galeano, L. Grana Lopez, M. Ciudad Fernandez, E. Vano Galvan, J. Gredilla Molinero, A. Casado Lopez; *Madrid/ES*

#### C-415

##### Effects of X-ray exposure on accuracy of digital cleansing in CT colonography

Y. Miyatani<sup>1</sup>, Y. Hirano<sup>2</sup>, K. Shichinohe<sup>1</sup>, M. Yamazaki<sup>3</sup>, G. Iinuma<sup>1</sup>; <sup>1</sup>Tokyo/JP, <sup>2</sup>Hokkaido/JP, <sup>3</sup>Aichi/JP

#### C-416

##### Accuracy of diffusion-weighted magnetic resonance imaging in detecting local recurrence of colorectal cancer: Initial experience

K. Shuto, T. Aoyagi, G. Ohira, K. Narushima, H. Saito, A. Saito, T. Ota, T. Kazama, S. Okazumi; *Chiba/JP*

#### C-417

##### MDCT-colonography: The value of the ratio between length and thickness of the involved segment of the colon in distinguishing neoplastic and inflammatory processes

J.M. Pienkowska, E. Szurowska, J. Wierzbowski, G. Rompa, I. Marek, M. Dubaniewicz-Wybieralska, M. Studniarek; *Gdansk/PL*

#### C-418

##### Optimizing bowel preparation for multidetector row CT colonography: Comparison of three different cleansing preparations

M.M. Slattery, E. Thornton, A. Keeling, M. Morrin; *Dublin/IE*

#### C-419

##### Can carcinoembryonic antigen be useful for preoperative computed tomography in colon cancer patients?

R. Moutinho, H. Santos, P. Caldeira, G. Afonso, D. Neto; *Faro/PT*

#### C-420

##### Evaluation of virtual colonoscopy by autodissection: Experience

I. Kiss, A. Rosztóczy, A. Palkó, T. Wittmann; *Szeged/HU*

**C-421****64-detector computed tomography in preoperative assessment of vascular anatomy of middle colic artery in left-sided colon cancer**

G. Lo Re, M. Galia, E. Grassedonio, G. Runza, T. Bartolotta, F. Coppolino, R. Lagalla; *Palermo/IT*

**C-422****Magnetic resonance imaging in the evaluation of sigmoid colonic geometric and mechanosensory properties**

J.B. Froekjaer<sup>1</sup>, D. Liao<sup>1</sup>, G. Dimcevski<sup>2</sup>, A. Bergmann<sup>1</sup>, A. Drewes<sup>1</sup>, H. Gregersen<sup>1</sup>; <sup>1</sup>*Aalborg/DK*, <sup>2</sup>*Bergen/NO*

**C-423****Should MDCT-colonography be a routine method in the post surgical follow-up of colorectal cancer in asymptomatic patients?**

J.M. Pienkowska, E. Szurowska, J. Wierzbowski, G. Rompa, I. Marek, M. Studniarek; *Gdansk/PL*

**GI Tract****Esophagus****C-424****PET CT in oesophageal cancer: Pictorial essay and review of literature**

F. Grieve, K.C. Jackson, M. Prescott, B. Rajashanker; *Manchester/UK*

**C-425****Esophageal and paraesophageal varices in cirrhosis: Imaging findings and endoscopic correlations**

I. Song, D. Choi, S. Kim, S. Lee, H. Rhim, W. Lee; *Seoul/KR*

**C-426****Caustic lesions gastrointestinal tract: Spectrum of multidetector row CT findings**

S. Merola, A. Pinto, S. Romano, L. Romano, T. Cinque; *Naples/IT*

**C-427****Diagnosis of superficial esophageal squamous cell cancer with high-barium esophagography using flat panel X-ray detector: A pilot study**

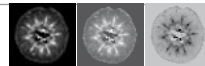
H. Saito, K. Shuto, T. Ota, A. Sato, K. Narushima, T. Aoyagi, G. Ohira, S. Okazumi; *Chiba/JP*

**C-428****Evaluation of clinical findings and staging of esophageal cancer by using diffusion-weighted imaging**

T. Aoyagi, K. Shuto, G. Ohira, K. Narushima, A. Satoh, H. Saitoh, T. Ohta, H. Shimada, H. Matsubara, T. Kazama, N. Yanagawa, S. Okazumi; *Chiba/JP*

**C-429****Diffusion MRI for prediction of response of esophageal cancer to chemoradiotherapy**

T. Aoyagi, K. Shuto, G. Ohira, K. Narushima, A. Satoh, H. Saitoh, T. Ohta, H. Shimada, H. Matsubara, T. Kazama, N. Yanagawa, S. Okazumi; *Chiba/JP*



## GI Tract

### Peritoneum

#### C-430

**Peritoneal mesotheliomas and mimickers: In-depth review of various clinicopathologic features and radiologic findings**

J. Park, K. Kim, H.-J. Kwon, M. Kim, G. Kwon, Y. Shin; *Seoul/KR*

#### C-431

**CT manifestations of peritoneal carcinomatosis: A pictorial review**

F.H. Peters, D. Boone; *London/UK*

#### C-432

**The peritoneal cavity and omentum on CT: The key to many intra-abdominal pathologies**

J. Kuriakose, S. Sinha, R. Gadahadh, C.J. Corr; *Wrexham/UK*

#### C-433

**Encapsulating peritoneal sclerosis: Spectrum of sequential computed tomographic findings**

K. Furuya<sup>1</sup>, I. Sakino<sup>2</sup>, K. Yasumori<sup>1</sup>, M. Nakamoto<sup>2</sup>, T. Yanagida<sup>2</sup>, C. Yasunaga<sup>2</sup>, T. Muranaka<sup>1</sup>; <sup>1</sup>*Fukuoka/JP*, <sup>2</sup>*Kitakyushu-City/JP*

#### C-434

**Extraparenchymal supramesocolic cystic lesions: Radiologic features**

A. Piazza, M.A. Pastrana, M.P. Reyero, P. Fraga, C. Garcia Roch, L. Arrieta; *Madrid/ES*

#### C-435

**Analysis of mesorectal fascia and mesorectum by 64-detector CT: Detectability of mesorectal fascia and influence of rectal contrast administration on mesorectal thickness**

M. Champfally, B. Scotto, P. Omoumi, D. Alison; *Tours/FR*

## GI Tract

### Rectum

#### C-436

**Radiotherapy for rectal cancer: The role of imaging**

J. Liau, A. Nikapota, R. Glynne-Jones, V. Goh; *Northwood/UK*

#### C-437

**Rectal carcinoma after therapy: MR imaging findings**

M. Arias González, A. Iglesias Castañón, J. Mañas Uxó, I. Carcacia Hermilla, M. Herreros Villaravitz; *Vigo/ES*

#### C-438

**Could MRI assess the effect of long-course chemoradiotherapy on the morphologic features of primary rectal cancer?**

I. Miucin-Vukadinovic, N. Prvulovic, M. Spirovski, B. Bokorov, A. Zvezdin; *Sremska Kamenica/RS*

#### C-439

**Characteristics of rectal gastrointestinal stromal tumors on MRI and CT**

Z. Jiang, W. Peng, Y. Shi, X. Li; *Shanghai/CN*

#### C-440

**Inter- and intra-observer variation of two- and three-dimensional anal endosonography in the evaluation of recurrent anal cancer**

A. Christensen; *Copenhagen/DK*

**GI Tract****Small Bowel****C-441**

**Spectrum of CT findings illustrating gastro-intestinal complications associated with haematopoietic stem cell transplantation**

M. Schmit; *Tübingen/DE*

**C-442**

**Primary and secondary neoplasms of the small bowel: Appearance on MRI and MDCT**

M. Anzidej, A. Napoli, P. Sedati, B. Cavallo Marincola, K. Lanciotti, C. Zini, P. Di Paolo, C. Catalano, R. Passariello; *Rome/IT*

**C-443**

**Indications, results and limitations of dedicated MDCT exam of the small bowel in the inflammatory disease: A comparison of two methodologies (enteroclysis and enterography)**

S. Romano, T. Cinque, G. Tortora, P. Lombardo, F. Maisto, L. Romano; *Naples/IT*

**C-444**

**3.0T MRI for assessment of disease activity in Crohn's disease**

J. Zhu, J. Xu; *Shanghai/CN*

**C-445**

**The role of ultrasound in Crohn's disease: A radiologic review with pathologic correlation**

L.R. Williams, D. Kasir, S.A. Sukumar; *Manchester/UK*

**C-447**

**Magnetic resonance imaging assessment of small bowel Crohn's disease activity: Literature review and personal experience**

R. Girometti, L. Cereser, G. Brondani, A. Furlan, A. Linda, C. Zuiani, M. Bazzocchi; *Udine/IT*

**C-448**

**Crohn's disease integrated imaging: MR-enterography vs CT-enterography**

P.V. Foti, R. Farina, G. Ganci, M.V. Coronella, D. D'Aniello, G. Politi, G.C. Ettorre; *Catania/IT*

**C-449**

**Mangafodipir trisodium (MnDPDP) enhanced MRI to study excluded duodenum after laparoscopic Roux-en-Y gastric bypass for morbid obesity**

E. Muraro, P. Marchisio, M. Natrella, D. Furfaro, M. Gallizioli, T. Meloni; *Aosta/IT*

**C-450**

**Semi-automated evaluation of small bowel mural attenuation at CT enterography using different temporal windows in patients affected by active Crohn disease**

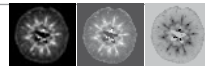
G. Lo Re, S. Vitabile, M. Galia, O. Gambino, A. Taibbi, R. Pirrone, M. Midiri; *Palermo/IT*

**C-451**

**Comparison of MDCT and MR enteroclysis with selective enterography in the detection of fistulas in Crohn's disease**

G. Tóth, L. Tóth, E. Turupoli, Á. Mester; *Budapest/HU*





## GI Tract

### Stomach

#### C-452

**Gastric cancer: Patterns of disease spread via the perigastric ligaments demonstrated by computed tomography**

S. Peungjesada, P. Bhosale, C. Charnsangavej; *Houston, TX/US*

#### C-453

**What is your differential diagnosis? Characterization of gastric submucosal tumors**

J. Kim, J. Lee, H. Park, J. Choi, S. Kim, J. Han, B. Choi; *Seoul/KR*

#### C-454

**Role of endoscopic ultrasound and MDCT for diagnosis of gastric submucosal tumors according to the revised pathologic classification of GIST**

J. Lim, M.-J. Kim, J.-H. Kim, K. Kim; *Seoul/KR*

#### C-455

**Adjustable laparoscopic gastric banding: The invaluable role of the radiologist**

A.A. Dawkins, D. Raw, S. Taneja, F. Lee; *Sheffield/UK*

#### C-456

**Detection of tumor recurrence in patients with gastric cancer: Comparison of contrast-enhanced MDCT and 18F FDG-PET/CT**

Y. Jeong, J. Kim, J. Kim, S. Shin, H. Kang; *Jeollanam-do/KR*

#### C-457

**Complications post bariatric procedures: Digital fluoroscopic evaluation**

V. Morigoni, E. Bozzi, A. Bardine, S. Giusti, M. Anselmino, P. Giusti, C. Bartolozzi; *Pisa/IT*

#### C-458

**Development of the water gastric distension method in FDG-PET cancer screening of healthy individuals**

S. Fujita, K. Kamimura, Y. Umemura, S. Nagamachi, R. Nishii, H. Wakamatsu, S. Tamura, T. Fujimoto; *Miyazaki/JP*

## GI Tract

### Miscellaneous

#### C-460

**Spontaneous abdominal haemorrhage: Imaging findings of an emergency condition**

A. Diaz de Otalora Serna, M.S. Carreras Aja, I. Arrieta Artieda, A. Dolado Llorente, A. Urresola, S. Simonetti, L.M. Larrea Bilbao; *Bilbao/ES*

#### C-461

**The appreciation of active intra-abdominal haemorrhage at CT**

T.J.C. Bryant<sup>1</sup>, S.H. Roy-Choudhury<sup>2</sup>, D. Thompson<sup>1</sup>, D.J. Breen<sup>1</sup>; <sup>1</sup>*Southampton/UK*, <sup>2</sup>*Birmingham/UK*

#### C-462

**Various cystic lesions of gastrointestinal tract: Radiologic findings with pathologic correlation**

J. Lee, C. Park, K. Kim, C. Lee, J. Choi, S. Lee, B. Shin; *Seoul/KR*

#### C-463

**Radiographic, MRI and MDCT anatomy of abdominal viscera after major gastrointestinal surgery**

M. Anzidei, A. Napoli, B. Cavallo Marincola, C. Zini, F. Francesco, P. Di Paolo, C. Catalano, R. Passariello; *Rome/IT*

**C-464****Imaging of tropical diseases**

A. Manzella, P. Borba-Filho, K. Batista, L. Santana, F. Farias, J. Santos-Filho, C. Carneiro, J. Kaercher, C. Ribeiro, C. Fontan; *Recife/BR*

**C-465****MR entero-colonography: A role beyond Crohn's disease?**

I. Aguirre<sup>1</sup>, M. Aduna<sup>2</sup>, J. Larena<sup>2</sup>, A. Merino<sup>1</sup>; <sup>1</sup>*Las Arenas (Getxo)/ES*, <sup>2</sup>*Galdakao/ES*

**C-466****Fever and pain in the left iliac fossa: Not always diverticulitis**

S. Roche, M. Escobar, M. Romera, R. Vidal, P. Veciana; *Barcelona/ES*

**C-467****MR imaging of perianal fistulas: A review and pictorial essay**

N. Ribeiro<sup>1</sup>, F. Reis Costa<sup>1</sup>, A.C. Silva<sup>2</sup>, J. Venâncio<sup>2</sup>, M.C. Tavares<sup>2</sup>, C.A. Ribeiro<sup>2</sup>; <sup>1</sup>*Viseu/PT*, <sup>2</sup>*Matosinhos/PT*

**C-468****Gastrointestinal surgical procedures: A primer for the radiologist**

S. Ramamurthy, S.H. Rashid, V. Rachapalli, N. Goyal, A. Yong; *Cardiff/UK*

**C-469****Appendicitis ruled out: Alternate causes of right lower quadrant pain in emergency department patients**

S. White; *Boston, MA/US*

**C-470****Signs of pneumoperitoneum on supine abdominal film: Every lucency in the abdomen must be interpreted**

A. Pinto, M. Scaglione, A. Sparano, C. Muzj, S. Nicotra, F. Pinto, L. Romano; *Naples/IT*

**C-471****Drug smuggling by body packing: How to avoid error in diagnosis**

A. Pinto, M. Scaglione, M. Scuderi, S. Merola, M. Pepe, C. Stavolo, L. Romano; *Naples/IT*

**C-472****Inherited gastrointestinal polyposis syndromes: Extraintestinal manifestations**

M.D.G.A. Certo<sup>1</sup>, L. Lopes<sup>2</sup>; <sup>1</sup>*Santo Tirso/PT*, <sup>2</sup>*Viana do Castelo/PT*

**C-473****CT findings of acute mesenteric ischemia: A pictorial review**

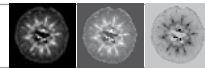
M. Pimentel-Martins, G. Gerediaga, C. Albuquerque, C. Santiago, I. Beirão; *Viseu/PT*

**C-474****Non-tumorous perianal lesions: Evaluation with various imaging modalities**

S. Rha, S. Oh, S. Jung, J. Byun, Y. Lee; *Seoul/KR*

**C-475****CT criteria for evaluation of primitive and metastatic GIST lesions before and in the early post-treatment period with imatinib**

A. Bulzacchi, I. Lionetti, M. Nardin, G. Pintacuda, D. Pastorelli, U. Basso, F. Farinati, P. Muzzio; *Padua/IT*



**C-476** (No material submitted to EPOS™)

**Fat stranding on emergency abdominal CT: Where to look at**

M. Montes Fernandez, B. Nieto Baltar, N. Arevalo Galeano, M. Ciudad Fernandez, Y. Martinez Alvarez, L. Grana Lopez, E. Vano Galvan; *Madrid/ES*

**C-477**

**Radiation exposure in patients with inflammatory bowel disease. Current status and future directions**

K. O'Regan, A. Desmond, C. Ni Churraín, S. McWilliams, S. McSweeney, F. Shanahan, M.M. Maher; *Cork/IE*

**C-478**

**Unusual hernias: An uncommon cause of acute abdomen**

B. Gutierrez, A. Franco, O. Benitez, A. Arjonilla, M. Tomás; *Madrid/ES*

**C-479**

**Acute gastrointestinal bleeding: Detection with arterial and portal venous phase imaging using MDCT**

Y. Jeong, W. Yoon, H. Kang; *Jeollanam-do/KR*

**C-480**

**Inferior mesenteric vein, normal anatomy, variations and pathological implications: Imaging with 64-row multislice computed tomography**

P. Arguís, M. Pages, S. Rodriguez, M. Sanchez, C. Ayuso; *Barcelona/ES*

**C-481**

**Gossypibomas: Spectrum of imaging findings**

A. Manzella, P. Borba-Filho, J. Kaercher, F. Farias, C. Carneiro, D. Sales, L. Santana, A. Rodrigues; *Recife/BR*

**C-482**

**Trapped on the "whirl": Diagnostic sign on emergency CT**

V.M. Suárez-Vega, M. Martí, E. Alonso, V. Pérez-Dueñas, C. Palacios; *Madrid/ES*

**C-483**

**MRI in perianal Crohn's disease**

J.P.A.F. Caldeira, I.N. Duarte; *Lisbon/PT*

**C-484**

**Gastrointestinal tract perforation: CT findings - what to look for?**

I. Arrieta Artieda, J. Mendiola Arza, M.S. Carreras Aja, M. Lazaro Serrano, A. Dolado Llorente, I. Terreros Bejo, L. Larrea Bilbao; *Barakaldo, Vizcaya/ES*

**C-485**

**Extrapulmonary manifestations of tuberculosis: A pictorial review**

N. Bharwani, K.H. Jogeessvaran, E.J. Goldstraw, S. Grubnic; *London/UK*

**C-486**

**Post-treatment CT appearances of gastrointestinal stromal tumours and the potential pitfalls in image interpretation**

M. King<sup>1</sup>, K. Tung<sup>1</sup>, C. Lee-Elliott<sup>2</sup>; <sup>1</sup>Southampton/UK, <sup>2</sup>Poole/UK

**C-487**

**Early and late-onset acute GVHD following hematopoietic cell transplantation: CT features of gastrointestinal involvement with clinical and pathological correlation**

H. Brodoefel<sup>1</sup>, M. Vogel<sup>2</sup>, W. Bethge<sup>2</sup>, C. Faul<sup>2</sup>, M. Wehrmann<sup>2</sup>, C. Claussen<sup>2</sup>, M. Horgert<sup>2</sup>; <sup>1</sup>Boston, MA/US, <sup>2</sup>Tuebingen/DE

**C-488****Can eating fish be dangerous? Evaluation of fish bone perforation of gastrointestinal tract using CT**

R. Prada, J. Calatayude, D. Castellon, J. Aguilar, G. Tardáguila, E. Santos, C. Martinez; *Vigo/ES*

**C-489****Evaluation of malignancy of gastrointestinal stromal tumor by FDG positron emission tomography comparing NCCN guideline**

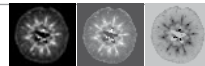
K. Narushima, S. Okazumi, K. Syuto, G. Ohira, T. Aoyagi, A. Sato, H. Saito, T. Ota; *Chiba/JP*

**C-490****The accuracy of ultrasonography in classification of groin hernias according to the criteria of the unified classification system**

A. Djuric-Stefanovic, D. Saranovic, A. Ivanovic, D. Masulovic, B. Dobriserevic; *Belgrade/RS*

**C-491****Pelvic floor dynamic imaging with magnetic resonance: Is evacuation phase mandatory?**

P.V. Foti, R. Farina, M.V. Coronella, G. Riva, D. Bellomia, G. Politi, G.C. Ettorre; *Catania/IT*



## Head and Neck

### Head and Neck Cancer

#### C-492

##### Head and neck cancer: What's new?

P. Martin, J.M. Millan, R. Hitt, F. Ballenilla, A. Delgado, S. Jimenez; *Madrid/ES*

#### C-493

*(No material submitted to EPOS™)*

##### Functional MDCT in preoperative staging of laryngeal and pharyngeal carcinomas

J. Pamies Guilabert, P. Braun, F. Gomez Muñoz, V. Ballester Leiva; *Valencia/ES*

#### C-494

##### Dural invasion by head and neck tumours: Predictive value of MRI

A.R. Borges, I. Fonseca; *Lisbon/PT*

#### C-495

##### Utility of diffusion-weighted magnetic resonance imaging in the detection of recurrent head and neck tumors

K. Michimoto, S. Fujii, T. Kan, S. Kakite, Y. Kanasaki, T. Ogawa; *Yonago/JP*

#### C-496

##### Characterization of cervical lymphadenopathy with apparent diffusion coefficient value

J. Yu<sup>1</sup>, D.-W. Park<sup>2</sup>, J. Kim<sup>1</sup>, C.-K. Hahm<sup>2</sup>, S. Kim<sup>2</sup>, Y. Kim<sup>2</sup>, C.-K. Park<sup>2</sup>, J.-N. Heo<sup>2</sup>; <sup>1</sup>*Seoul/KR*, <sup>2</sup>*Kuri/KR*

#### C-497

##### Electrical permittivity as a new imaging tool in the evaluation of sonographically suspicious lymph nodes

A. Malich<sup>1</sup>, C. Mauch<sup>1</sup>, D. Hentrich<sup>1</sup>, A. Kott<sup>1</sup>, J. Böttcher<sup>2</sup>, A. Hansch<sup>2</sup>; <sup>1</sup>*Nordhausen/DE*, <sup>2</sup>*Jena/DE*

## Head and Neck

### Maxillofacial Imaging

#### C-499

##### Paranasal sinus disease: Did you think on lymphoma?

M. Martinez Galdamez, B. Brea Alvarez, S. Cornide Santos, C. Garcia Roch, J. Hernanz Padial, L. Nombela Cano; *Madrid/ES*

#### C-500

##### Differential diagnosis of mandibular lesions in adults: Findings on plain radiographs, bone scintigraphy, CT, MRI and PET scanning

I.M. Brennan, G. Murphy, P. Beddy, P. Govender, J.F. Meaney; *Dublin/IE*

#### C-501

##### The many causes of antral bowing sign

I.A. Alorainy; *Riyadh/SA*

#### C-502

##### Nasal cavity tumours: The differential diagnosis and the role of cross-sectional imaging

F. Jabeen, R. Rahim, N. Desai; *Manchester/UK*

#### C-503

##### Ortopantomography and CT imaging of the buccal space: Normal anatomy and pathology

A. Peralta, P. Jimenez, J.A. Dieguez, R. Conde; *Jerez/ES*

**C-504****Classification and complications of mandibular fractures**

A. Hameeduddin, L. Makalanda, S. Stuart, A. Malhotra, O. Chan, R. Katz; *London/UK*

**C-505****Marginal intracranial cysts in sinonasal tumours: Diagnostic accuracy for olfactory neuroblastoma**

A.R. Borges; *Lisbon/PT*

**C-506****Quantitative mandibular bone changes in women**

E. Arana, F. Benet, L. Martí-Bonmatí; *Valencia/ES*

**Head and Neck****Temporal Bone****C-507****Temporal bone lesions: A pictorial essay**

R.S. Glikstein, L. Rosenbloom, M. Levental; *Montreal, QC/CA*

**C-508****Pocket atlas of lesser known anatomical variants in the temporal bone on CT**

S. Dekeyser, V. VandeVyver, M. Lemmerling, K. Verstraete; *Gent/BE*

**C-509****A bilingual multimedia online lecture program for multiplanar temporal bone anatomy in high resolution CT**

R. Talanow<sup>1</sup>, S. Waldeck<sup>2</sup>; <sup>1</sup>Cleveland, OH/US, <sup>2</sup>Hamburg/DE

**C-510****Klippel-Feil syndrome and associated ear anomalies: CT findings**

A. Arslanoglu, N. Yildirim; *Van/TR*

**C-511****How to find the way out of the canals and labyrinths of temporal bone: Normal anatomy of temporal bone in computed tomography and gross anatomical specimens**

G.J. Staskiewicz, E. Czekajska-Chehab, A. Trojanowska, S. Uhlig, A. Szabelska, A. Torres, K. Torres, R. Maciejewski, A. Drop; *Lublin/PL*

**C-512****Pulsatile tinnitus: A diagnostic approach**

N.S. Alam, Y. Jain, A. Anbarasu; *Birmingham/UK*

**C-513****Computed tomographic findings in the temporal bone of patients with osteogenesis imperfecta**

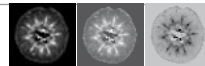
S. Mehiri, S. Bourkhis, A. Salem, F. Ben Amara, H. Rajhi, R. Hamza, N. Mnif; *Tunis/TN*

**C-514****Separate visualization of endolymphatic space, perilymphatic space and bone by a single pulse sequence: Acquisition of 3D-inversion recovery sequence utilizing real reconstruction after intratympanic Gd-DTPA administration at 3 Tesla**

S. Naganawa, H. Fukatsu, T. Nakashima, M. Kawamura; *Nagoya/JP*

**C-515****Dehiscence of the superior semicircular canal: Correlation of high-resolution CT findings with vestibular symptoms**

A. Diaz de Otalora, A.I. Ezquerro, O. Rodriguez San Vicente, B. Mateos Goñi, R. Villoria, M.A. Crovetto de la Torre, L. Larrea Bilbao; *Bilbao/ES*



## Head and Neck

### Thyroid/Parathyroid

#### C-516

**Contrast enhanced ultrasound: A useful tool for evaluation of percutaneous ablation of thyroid nodules**

L. [Tarantino](#); *Frattamaggiore/IT*

#### C-517

**Correlation between ultrasound patterns of parathyroid glands and parathormone levels in secondary hyperparathyroidism**

C. Vulpio, A. De Gaetano, F. Piludu, M. Ciliberti, N. Panocchia, S. Giungi, G. [Maresca](#); *Rome/IT*

#### C-518

**Ultrasound-guided fine needle aspiration of thyroid nodules: A how to do DVD-Rom-based audiovisual guide**

D.D. [Cokkinos](#), I. Theotokas, A. Plagou, K. Pahos, E. Skoulikaris, P.S. Zoumpoulis; *Athens/GR*

#### C-519

**Color Doppler sonography in hyperparathyroidism**

M. [Squarcia](#), L. Buñesch, R. Gilabert, F. Calaf, M. Puig; *Barcelona/ES*

#### C-520

**F-18 FDG-PET of the thyroid glands: Comparison with ultrasound findings**

S. [Kawase](#)<sup>1</sup>, K. Kato<sup>2</sup>, S. Ito<sup>1</sup>, A. Nishio<sup>2</sup>, M. Tadokoro<sup>3</sup>, N. Makino<sup>1</sup>, S. Naganawa<sup>2</sup>; <sup>1</sup>*Toyota/JP*, <sup>2</sup>*Nagoya/JP*, <sup>3</sup>*Toyoake/JP*

#### C-521

**Ultrasonographic patterns of parathyroid glands (PTG) in responders and non responders hemodialyzed patients with secondary hyperparathyroidism (SHPT)**

C. Vulpio, A. De Gaetano, A. Biscaglia, M. Bossola, G. Luciani, G. [Maresca](#); *Rome/IT*

#### C-522

**The contribution of ultrasound guided fine needle aspiration in thyroid nodules management**

A. Kokkinaki, N. Lepida, D. Kyriakoylis, M. Gravanis, A. Loubakou, A. Anagnostara, S. [Mylona](#); *Athens/GR*

## Head and Neck

### Miscellaneous

#### C-523

**Skull base foramina, a minefield for radiologists: What to look for on MR**

E. [Kelliher](#), H. Khosa, E. Delappe, C. Cronin, P. McCarthy, C. Roche; *Galway/IE*

#### C-524

**Imaging of the orbital apex and optic canal**

P.S. [Goh](#); *Singapore/SG*

#### C-525

**Compartmental anatomy of the head and neck: What every radiologist should know**

H. Verma, N. [Bharwani](#), P.L. Skippage, E. Goldstraw, S. Brown, E.J. Adam; *London/UK*

#### C-526

**Pitfalls in head and neck FDG PET CT: An update**

J.V.P. [Liew](#), F. Gollub, J. Chambers, W.L. Wong; *London/UK*

**C-527****A pictorial review of cervical nodules diagnosed by ultrasound**

M.R. Cozcolluela, L.A. Sanz, L. Miranda, M. Martinez-Berganza, H. Sarasibar, J.M. Mellado; *Tudela (Navarra)/ES*

**C-528****Looking through the orbit**

A. Garcia de Vicente<sup>1</sup>, M. Martinez Montalban<sup>1</sup>, M. Jimenez Jurado<sup>1</sup>, L. Garcia del Salto<sup>2</sup>, P. Ramos Lopez<sup>1</sup>, A. Marco Sanz<sup>2</sup>; <sup>1</sup>*Alcala de henares/ES*, <sup>2</sup>*Alcala de Henares/ES*

**C-529****The role of imaging in facial paralysis**

N. Satogami, T. Koyama, Y. Miki, K. Togashi; *Kyoto/JP*

**C-530****Neck lymph node tuberculosis: A frequently forgotten diagnosis**

B. Viamonte, J. Loureiro, N.P. Silva, M. Castro, J.C. Lobo; *Porto/PT*

**C-531****Peripheral nerve sheath tumors of head and neck: MR imaging features**

A.A.A. Abdel Razek, S. Samir, N. Nada; *Mansoura/EG*

**C-532****16-detector row CT dacryocystography**

B. Marc, F. Bonnet, C. Hoeffel, G. Mac, S. Veron-Piot, A. Ducasse, C. Marcus; *Reims/FR*

**C-533****Infectious diseases of the neck: Remark on Lemierre's syndrome**

A. Iñiguez Gomez, A. Litcheva Gueorguieva, N. Arevalo Galeano, E. Crespo Vallejo, J. Gredilla Molinero, A. Ruiz Ollero; *Madrid/ES*

**C-534****Head and neck paragangliomas: Comparison of contrast-enhanced 3D MR angiography and spin-echo MR imaging techniques**

F. Neves, L. Huwart, D. Reizine, P. Herman, E. Vicaut, J.-P. Guichard; *Paris/FR*

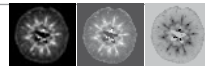
**C-535****Ultrasound in the evaluation of diseases of the submandibular and parotid gland: Oldy but goody**

S. Ntai, S. Mylona, N. Lepida, A. Loubakou, S. Patsoura, N. Batakis; *Athens/GR*

**C-536****Inflammatory salivary diseases: Pictorial essay**

J. Pires, M. Teixeira Gomes, R. Maia, P. Santos, J. Reis; *Porto/PT*





## Interventional Radiology

### Vascular

#### C-537

##### **Therapeutic embolization: First choice or last resort?**

S.S. Hedgire, P. Gupta, J. Sathenjeri Rajendra, T. Kalyanpur, V. Ilayaraja, M. Cherian, R. Dhanpalan, R. Karwal; *Coimbatore/IN*

#### C-538

##### **Non-surgical management of haemorrhagic splenic injuries**

A. Hilaro, S. Borruel, P. Martin, E. Garcia-Hidalgo, M. Chico, C. Garcia; *Madrid/ES*

#### C-539

##### **Imaging spectrum of infrarenal endovascular abdominal aortic aneurysm repairs (EVAR) complications and its management**

J.V.P. Llaw, M. Clark, R. Gibbs, M. Jenkins, N. Cheshire, M. Hamady; *London/UK*

#### C-540

##### **Technical difficulties related to endovascular stenting in hybrid repair of complex thoraco-abdominal aortic aneurysms (TAAA)**

J. Burrill, C. Riga, J. Wolfe, M. Jenkins, R. Gibbs, N. Cheshire, M. Clark, M. Hamady; *London/UK*

#### C-541

##### **Vascular and nonvascular interventions in pancreatitis**

S. Subramanian, S. Gamanagatti, D.N. Srivastava, Z. Abbas, P. Garg; *New Delhi/IN*

#### C-542

##### **Percutaneous management of aggressive vertebral haemangiomas: How, when and why?**

X. Buy, T. Moser, J.-L. Dietemann, A. Gangi; *Strasbourg/FR*

#### C-543

##### **Diagnosis and interventional radiology for renovascular disorders**

D. Uchiyama, M. Koganemaru, T. Abe, R. Iwamoto, S. Yoshida, N. Hayabuchi; *Kurume/JP*

#### C-544

##### **Initial experience with the Amplatzer® vascular plug for various hepatic pathologies**

K.I. Ringe, H. Rosenthal, M. Galanski; *Hannover/DE*

#### C-545

##### **Selective internal carotid digital subtraction angiography (DSA) for preoperative investigation of epilepsy with the Wada test**

A. Karatasidou, M. Karigiannis, E. Theodoropoulos, G. Karydas, C. Baltas; *Athens/GR*

#### C-546

##### **Postpartum hemorrhage: Influence of angiographic findings on embolic material**

Y. Fergeaudou, O. Le Dref, P. Soyer, M. Boudiaf, H. Dahan, R. Rymmer; *Paris/FR*

#### C-547

##### **An improved superselective insertion "hook back" technique of microguidewire**

M. Gibo, S. Unten, A. Yogi, S. Murayama; *Okinawa/JP*

#### C-548

##### **Therapeutic implication of pre-operative embolization in high-flow AV malformation in the head and neck region**

C. Mohan, P.S. Bhandari, B. Batra, A. Agarwal; *New Delhi/IN*

**C-549****The IVC: Diagnostic imaging and interventional therapies**

C. Shaw, D.T. Murphy, J.M. Moriarty, L.P. Lawler; *Dublin/IE*

**C-550**

*(No material submitted to EPOS™)*

**Complications after hepatic artery embolization for hepatic tumors**

J.P. Singh, N. Kandasamy, R. Harganani, A. Goode, D. Yu, N. Woodward; *London/UK*

**C-551****Role of the interventional radiologist in the management of acute lower gastrointestinal bleeding**

M. Barrufet Solé<sup>1</sup>, J. Sánchez Alipio<sup>2</sup>, J. Fadlala<sup>3</sup>, A. Mainar Turón<sup>1</sup>, J. Medrano Peña<sup>1</sup>, M. de Gregorio Ariza<sup>1</sup>; <sup>1</sup>*Zaragoza/ES*, <sup>2</sup>*Neuquén Capital/AR*, <sup>3</sup>*Rosario/AR*

**C-552****A fifteen years TIPS experience: Retrospective review of clinical involvements and technical aspects**

G. Bartoli, C. Gazzera, L. Luberto, P. Campanino, A. Doriguzzi Breatta, D. Righi, A. Ottobrelli, G. Gandini; *Turin/IT*

**C-553****IVC-SVC filters: A comprehensive review of the spectrum of complications**

J. Tisnado, M.K. Sydnor, D.J. Komorowski, D.A. Leung; *Richmond, VA/US*

**C-554****Arterial embolization for controlling traumatic pelvic hemorrhage: A rapid and effective technique and review of associated literatures**

H.-Y. Chen, Y.-F. Chen, J.-H. Chen, K.-Y. Chen, H.-J. Chiang, W.-C. Shen; *Taichung/CN*

**C-555****Use of a non-adhesive liquid embolic agent in the treatment of thoracic type II endoleaks**

M. Corona, F. Fanelli, G. Orgera, E. Boatta, A. Pucci, M. Allegritti, P. Nardis, A. Bruni, R. Passariello; *Rome/IT*

**C-556****Retrospective study of proximal vs. distal splenic artery embolization in 73 consecutive cases**

P.R. Rau, N.-H. Stauffer, A. Denys; *Lausanne/CH*

**C-557****Vascular complications of pediatric liver transplantation: Role of interventional radiology**

R. Nani, R. Agazzi; *Bergamo/IT*

**C-558****Complete tumor response after TACE: A selection criteria for liver transplantation in HCC patients exceeding Milan criteria**

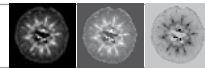
I. Bargellini, V. Vallini, P. Petruzzi, P. De Simone, R. Cioni, C. Vignali, C. Bartolozzi; *Pisa/IT*

**C-559****Interventional management of chronic pulmonary hypertension as the result of thromboembolic disease**

M. Barrufet Solé<sup>1</sup>, J. Sánchez Alipio<sup>2</sup>, R. Domene Moros<sup>1</sup>, J. Bosch<sup>1</sup>, A. Mainar Turón<sup>1</sup>, J. Medrano Peña<sup>1</sup>, M. de Gregorio Ariza<sup>1</sup>; <sup>1</sup>*Zaragoza/ES*, <sup>2</sup>*Neuquén Capital/AR*

**C-560****The Günther Tulip retrievable filter: Effectiveness and complications in temporary and permanent use**

N. Abe, R. Shuto, R. Takaji, S. Yotsumoto, Y. Sagara, N. Hongo, H. Kiyosue, H. Mori; *Yufu/JP*



**C-561**

**Accuracy of bilateral inferior petrosal sinus sampling in Cushing's syndrome**

E. Granell, C. Castaño, F. Plancarte, C. García, C. Ovejero, M. de Juan, S. Valverde; *Barcelona/ES*

**C-562**

**The possibility of the penetration injury on carotid artery and internal jugular vein during cervical transforaminal epidural injection: An analysis of 594 injections**

H.-S. Kim, D.-J. Chung, S.-H. Lee, S.-H. Lee; *Seoul/KR*

**C-563**

**Safety evaluation of gelatin microsphere (GMS) with changeable dissolution time as an embolic agent with regard to our experience of clinical use and the possible use of GMS as a drug delivery system (DDS)**

N. Nitta<sup>1</sup>, S. Ohta<sup>1</sup>, T. Tanaka<sup>1</sup>, R. Takazakura<sup>1</sup>, T. Toyama<sup>1</sup>, S. Kanasaki<sup>1</sup>, Y. Nagatani<sup>1</sup>, N. Kono<sup>1</sup>, A. Furukawa<sup>1</sup>, M. Takahashi<sup>1</sup>, K. Murata<sup>1</sup>, T. Sakamoto<sup>1</sup>, T. Sakamoto<sup>2</sup>, Y. Tabata<sup>3</sup>; <sup>1</sup>*Otsu/JP*, <sup>2</sup>*Kohka/JP*, <sup>3</sup>*Kyoto/JP*

**C-564**

**Clinicopathologic features and results of transarterial chemoembolization for nephroblastoma**

J. Li, J. Chu; *GuangZhou/CN*

**C-565**

**The efficacy and outcome of dialysis line stripping**

S.S. Yengar<sup>1</sup>, A. Abdellaoui<sup>1</sup>, J. Tee<sup>2</sup>, J. Stratton<sup>2</sup>, A. Edwards<sup>2</sup>; <sup>1</sup>*Plymouth/UK*, <sup>2</sup>*Truro/UK*

**C-566**

**The need for level 2 critical care beds in patients undergoing elective endovascular aneurysm repair (EVAR)**

A. Kheir, G. Danjoux, P. Walker, A. Parry; *Middlesbrough/UK*

**C-567**

**Endovascular stent-grafting repair after blunt thoracic aorta injury. Short to long term follow-up: Preliminary results**

I.S. Kaskarelis, A.A. Parlamenti, K. Kanakakis, V.P. Kostaras, C. Athanasiou, M. Argiriou, I. Kokotsakis; *Athens/GR*

**C-568**

**Liver radioembolisation with Y90 loaded resin microspheres: Our three year clinical experience**

A. Alonso, B. Zudaire, A. Viúdez, P. Garrastachu, B. Gil, B. Sangro, J.I. Bilbao; *Pamplona/ES*

**C-569**

**Transjugular intrahepatic portosystemic shunt (TIPS) creation after liver transplantation**

M.A. Cura, F. El Merhi, R. Suri, J. Lopera; *San Antonio, TX/US*

**C-570**

**Contrast-enhanced ultrasonography: Utility in the assessment of therapeutic response after uterine fibroid embolization**

P. Bermudez, J. Falco, J. Perendreu, J. Fortuño, J. Branera, E. Ballesteros; *Sabadell, Barcelona/ES*

**C-571**

**Hepatocellular carcinoma treated with TACE and RFA: Role of perfusion CT in determining therapeutic response**

D. Ippolito<sup>1</sup>, F. Invernizzi<sup>1</sup>, M. Pozzi<sup>1</sup>, L. Antolini<sup>1</sup>, S. Sironi<sup>1</sup>, F. Fazio<sup>2</sup>; <sup>1</sup>*Monza/IT*, <sup>2</sup>*Milan/IT*

**C-572**

**Venous complications after liver transplantation: Endovascular treatment**

A. Doros, A. Németh, E. Hartmann, Á. Deák, G. Juharosi, Z. Lénárd, I. Fehérvári, Z. Máthé, J. Fazakas, B. Nemes; *Budapest/HU*

**Interventional Radiology****Non-Vascular****C-573****Interventional radiology management of pediatric patients with biliary complications following liver transplantation**

R. Miraglia, L. Maruzzelli, S. Caruso, M. Milazzo, G. Marrone, G. Mamone, V. Carollo, A. Luca, B. Gridelli; *Palermo/IT*

**C-574****The difficult CT guided biopsy**

C.K.L. Cook<sup>1</sup>, K. Balasubramaniam<sup>2</sup>; <sup>1</sup>*Weston-super-Mare/UK*, <sup>2</sup>*Bristol/UK*

**C-575****Hepatocellular cancer response to radiofrequency tumor ablation: Contrast-enhanced ultrasound**

T.V. Bartolotta, A. Taibbi, M. Galia, G. Malizia, G. Runza, G. Lo Re, M. Midiri; *Palermo/IT*

**C-576****A review of colonic stenting: Achieving a successful outcome**

F.S. Ahmad, N. Fotiadis, A. Saini, T. Sabharwal, A. Adam; *London/UK*

**C-577****Percutaneous treatment of bone tumors and tumor-like lesions by radiofrequency thermal ablation and/or cementation**

F. Ruiz Santiago, M. Castellano García, M. Ruiz Garcia, J. Tristán Fernández, J. Martínez Montes, J. Molina Nuevo; *Granada/ES*

**C-578****Computed tomography (CT) guided biopsy in small lung nodules (0.5-1.5 cm): Method, results and complications**

S. Apostolopoulou, P. Filippousis, E. Sotiropoulou, L. Poulou, S. Velitsista, L. Thanos; *Athens/GR*

**C-579****Let us drain this collection!**

E. Crespo Vallejo, A. Litcheva Gueorguieva, E. Huelga Zapico, J. Gredilla Molinero, A. Iñiguez Gomez, N. Arevalo Galeano; *Madrid/ES*

**C-580****Potential complications of percutaneous vertebroplasty: How to prevent and manage them**

T. Moser, X. Buy, J.-L. Dietemann, A. Gangi; *Strasbourg/FR*

**C-581****Optimized CT-guided coaxial core biopsy of retroperitoneal masses**

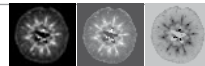
J. Stattaus, H. Kuehl, J. Kalkmann, M.R. Nowrousian, K.A. Metz, M. Forsting, S.C. Ladd; *Essen/DE*

**C-582****Artificial pneumothorax with position adjustment for computed tomography-guided percutaneous core biopsy of mediastinum lesions**

Z. Lin, Y. Li; *Fuzhou/CN*

**C-583****Femoroplasty, ilioplasty and sacroplasty under CT fluoroscopic guidance in the treatment of bone lytic metastases and multiple myeloma**

C. Pusceddu<sup>1</sup>, N. Ballicu<sup>1</sup>, G. Podda<sup>1</sup>, C. Urigo<sup>2</sup>, S. Profili<sup>2</sup>, F. Meloni<sup>2</sup>, G. Meloni<sup>2</sup>; <sup>1</sup>*Cagliari/IT*, <sup>2</sup>*Sassari/IT*



**C-584**

**Percutaneous liver biopsy: Analysis of major complications**

R.G. Lambertini, P.E. Farias, G. Ducrey, A. Gadano, J.C. Bandi, R. García Mónaco; *Buenos Aires/AR*

**C-585**

**Percutaneous radiofrequency heat ablation of malignant extra-hepatic neoplasm**

C. Pusceddu<sup>1</sup>, N. Ballicu<sup>1</sup>, F. Meloni<sup>2</sup>, G. Podda<sup>1</sup>, C. Urigo<sup>2</sup>, S. Profili<sup>2</sup>, G. Meloni<sup>2</sup>; <sup>1</sup>*Cagliari/IT*, <sup>2</sup>*Sassari/IT*

**C-586**

**Pleural complication associated with radiofrequency ablation: Histopathologic findings in rabbit lung models during follow-up period**

H. Nakada; *Miyazaki/JP*

**C-587**

**Klebsiella pneumoniae liver abscess versus non-Klebsiella pneumoniae liver abscess: Comparison of clinical features and outcome of percutaneous drainage**

H.-P. Hong, P. Kang, S. Kim, H. Park; *Seoul/KR*

**C-588**

**Evaluation of pretreatment apparent diffusion coefficients' value of hepatocellular carcinoma treated with percutaneous radiofrequency ablation**

E. Szurowska, J.M. Pienkowska, D. Zadrozny, E. Izicka-Swieszewska, W. Adamonis, M. Dubaniewicz-Wybieralska, M. Studniarek; *Gdansk/PL*

**C-589**

**The safety and efficacy of MR-guided focused ultrasound surgery in pedunculated subserosal fibroid of the uterus: Initial experience**

S.-W. Yoon; *Gyunggi-do/KR*

**C-590**

**Percutaneous femoroplasty in the cancer patient: A new therapeutic option?**

C. Pusceddu<sup>1</sup>, N. Ballicu<sup>1</sup>, G. Podda<sup>1</sup>, F. Meloni<sup>2</sup>, S. Profili<sup>2</sup>, G. Meloni<sup>2</sup>; <sup>1</sup>*Cagliari/IT*, <sup>2</sup>*Sassari/IT*

**C-591**

**XperGuide: C-arm needle guidance**

D. Ruijters<sup>1</sup>, L. Spelle<sup>2</sup>, J. Moret<sup>2</sup>, D. Babic<sup>1</sup>, R. Homan<sup>1</sup>, P. Mielekamp<sup>1</sup>, B.M. ter Haar Romeny<sup>3</sup>, P. Suetens<sup>4</sup>; <sup>1</sup>*Best/NL*, <sup>2</sup>*Paris/FR*, <sup>3</sup>*Eindhoven/NL*, <sup>4</sup>*Leuven/BE*

**C-592**

**Utility of 3D ultrasound in percutaneous nephrostomy (PCN) insertion**

L.A. Ratnam, M. Walkden, G. Munneke, S. Nayak, D. Rowlands, D. Nassiri, K. Anson, U. Patel; *London/UK*

**C-593**

**Relationship between efficacy of magnetic resonance imaging-guided focused ultrasound (MRI-FUS) treatment of uterine fibroids and MR-characteristics of the tumors**

V.Y. Lazutkina, A.V. Stepanov, Y.B. Kurashvili, K.V. Lyadov; *Moscow/RU*

**C-594**

**Postsurgery complications: Minimally invasive treatment under CT-guidance**

S. Mylona, M. Gravanis, E. Syristatidou, D. Kyriakoulis, A. Agagnostara, N. Batakis; *Athens/GR*

**C-595**

**Results of oxygen-ozone chemodiscolysis in different types of disc disease**

N. Limbucci, V. Zecca, L. Sacchetti, F. Fasano, L. Zugaro, M. Gallucci; *L'Aquila/IT*

**C-596****Post-radiofrequency ablation syndrome after percutaneous radiofrequency of abdominal tumours**

A. Ianniello, G. Carrafiello, D. Laganà, F. Fontana, P. Nicotera, C. Fugazzola; *Varese/IT*

**C-597****Safety, efficiency and cost-effectiveness in CT-guided biopsies performed on an out-patient basis**

P. Filippousis, E. Sotiropoulou, S. Apostolopoulou, A. Bouga, L. Poulou, L. Thanos; *Athens/GR*

**C-598****Post-ablation syndrome in 70 patients treated with radiofrequency ablation**

P. Filippousis, E. Sotiropoulou, S. Apostolopoulou, S. Velitsista, A. Bouga, L. Thanos; *Athens/GR*

**C-599****CT-guided tumor implantation: Animal model**

S.C.A. Herber, K. Trappe, C. Winkel, M.B. Pitton, C. Düber; *Mainz/DE*

**C-600****MR imaging for the assessment of treatment response after radiofrequency ablation of hepatocellular carcinoma: An explant correlation**

S. Rha<sup>1</sup>, H. Hussain<sup>2</sup>, B. McKenna<sup>2</sup>, W. Weadock<sup>2</sup>, H. Nghiem<sup>2</sup>; <sup>1</sup>Seoul/KR, <sup>2</sup>Ann Arbor, MI/US

**C-601****Self-expanding metallic ureteral stents to treat ureteral stenosis after kidney transplantation**

F. Diaz Romero, L. Delgado Plasencia, E. López-Tomassetti Fernández, E. Torres Monzón, I. González García, H. Vallés González, T. Pérez Albelo, P. Gutiérrez Hernández; *Santa Cruz de Tenerife/ES*

**C-602****Lumbosacral disc herniation: Spinal interventional chemonucleolysis with CT-intradiscal oxygen-ozone (O2-O3) mixture with intradiscal**

T. Angileri<sup>1</sup>, F. Verderame<sup>1</sup>, A. Taibbi<sup>2</sup>, T.V. Bartolotta<sup>2</sup>, M.A. Banco<sup>2</sup>, G. Sparacia<sup>2</sup>; <sup>1</sup>Bagheria/IT, <sup>2</sup>Palermo/IT

**C-603****Recurrent prostate cancer: A prospective study on the use of MR-guided galvano-therapy**

F. Mayer<sup>1</sup>, H. Mayer<sup>2</sup>, S. Zangos<sup>1</sup>, T.J. Vogl<sup>1</sup>; <sup>1</sup>Frankfurt a. Main/DE, <sup>2</sup>Regensburg/DE

**C-604****CT-guided fine-needle aspiration in spondylodiskitis: True usefulness of a common practice**

E. Sánchez, R. Pellón, L. Martín, J. Izquierdo, E. Marco de Lucas, G. Blanco, M. Pelaz, A. Gutiérrez, F. Quintana, E. Ruiz; *Santander/ES*

**C-605****Large HCC ablation by a new saline-enhanced expandable radiofrequency device**

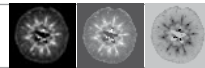
L. Tarantino<sup>1</sup>, I.F.M. Sordelli<sup>2</sup>, V. Nocera<sup>1</sup>, A. Piscopo<sup>1</sup>, C. Ripa<sup>2</sup>, D. Parmeggiani<sup>2</sup>, P. Sperlongano<sup>2</sup>; <sup>1</sup>Frattamaggiore/IT, <sup>2</sup>Naples/IT

**C-606****Percutaneous radiofrequency thermal ablation (RFA) of renal tumors: Single center experience**

A. Ianniello, G. Carrafiello, D. Laganà, C. Recaldini, P. Nicotera, C. Fugazzola; *Varese/IT*

**C-607****Management of malignant hilar bile duct obstruction with biductal stent placement in Y configuration**

H.-P. Hong, H. Lim, S. Kim; *Seoul/KR*



## Molecular Imaging

### C-608

**Usefulness of MRI on evaluating hepatic distribution of Fe304 magnetic nanoparticles in an experimental model: Preliminary steps in magnetic hyperthermic treatment of hepatic tumours**

J.J. Echevarria<sup>1</sup>, R. Maniega<sup>1</sup>, I. Garcia-Alonso<sup>2</sup>, I. Aguirre<sup>1</sup>, J. Salado<sup>2</sup>, M. Insausti<sup>2</sup>, T. Rojo<sup>2</sup>, N. Etxebarria<sup>2</sup>, G. Arana<sup>2</sup>, F. Plazaola<sup>2</sup>; <sup>1</sup>*Galdakao/ES*, <sup>2</sup>*Leioa/ES*

### C-609

**The role of fused whole body FDG-PET/MRI images for evaluation of patients with cancer**

R.C. Domingues, M. Carneiro, L.C.H. da Cruz Jr, E.G. Antunes, E.L. Gasparetto, R.C. Domingues; *Rio de Janeiro/BR*

### C-610

**Imaging angiogenesis with an endothelin-receptor affine fluorescent photoprobe**

C. Hoeltke, J. Waldeck, K. Kopka, M. Schaefers, W. Heindel, C. Bremer; *Muenster/DE*

### C-611

**Somatostatin receptor status and glucose metabolism in neuroendocrine tumours: Intra-individual comparison by Ga-68-DOTA-NOC PET/CT and F-18-FDG PET/CT**

S.W. Oh<sup>1</sup>, V. Prasad<sup>2</sup>, D.S. Lee<sup>1</sup>, R.P. Baum<sup>2</sup>; <sup>1</sup>*Seoul/KR*, <sup>2</sup>*Bad Berka/DE*

### C-612

**Assessment of treatment effects by bioluminescent imaging (BLI) and micro-CT in a mouse bone metastasis model**

E. Stepina, A. Strube, S.-M. Kaekoenen, P. Hauff; *Berlin/DE*

### C-613

**Changes in the integrin receptor availability of human adult mesenchymal stem cells after labeling with superparamagnetic iron oxide**

R. Kehlbach, R. Schäfer, E. Scheer, T. Kluba, R. Bantleon, C. Claussen, J. Wiskirchen; *Tuebingen/DE*

### C-614

**Monitoring response to peptide receptor radionuclide therapy (PRRT) in patients with metastasised neuroendocrine tumours (NET): Intraindividual comparison between Ga-68-DOTA-NOC, F-18-FDG-PET/CT, and CT alone**

S.W. Oh<sup>1</sup>, V. Prasad<sup>2</sup>, D.S. Lee<sup>1</sup>, R.P. Baum<sup>2</sup>; <sup>1</sup>*Seoul/KR*, <sup>2</sup>*Bad Berka/DE*

### C-615

**Fluorescence labelled barbiturates as novel non-peptidic MMP-2 and -9 optical imaging agents**

B. Waschkau, A. Faust, H.-J. Breyholz, J. Waldeck, K. Kopka, M. Schaefers, C. Bremer; *Muenster/DE*

**Musculoskeletal****Bone****C-616****MR imaging in bone sarcomas in children: Pre- and post-treatment imaging features**

M. [Jastrzebska](#), A. Romaniuk-Doroszevska, H. Brogoszewska, M. Bekiesinska-Figatowska; *Warsaw/PL*

**C-617****Lytic epiphyseal lesions: Is it possible to reach the correct diagnosis?**

M. [Seco](#), B. Graça, B. Gonçalves, A. Peres, F. Caseiro-Alves; *Coimbra/PT*

**C-618****Surface lesions of bone**

S. [Chaabane](#), M. Chelli Bouaziz, A. Ben Hassine, D. Kaffel, M. Ladeb; *Tunis/TN*

**C-619****The accessory navicular syndrome: Imaging features with emphasis on magnetic resonance imaging**

N. Doda, W.C.G. [Peh](#); *Singapore/SG*

**C-620**

*[No material submitted to EPOS™]*

**Osteosarcoma: Spectrum of radiological appearances**

A. [Malik](#), B. Thukral, G. Khanna, R. Prasad; *New Delhi/IN*

**C-621****Osteoblastic bone metastases: How to crack a tough nut**

T. Moser, X. Buy, J.-L. Diemann, A. [Gangi](#); *Strasbourg/FR*

**C-622****Fractures of the fifth metacarpal**

T.E. [Gudmundsen](#), L. Borgen; *Drammen/NO*

**C-623****Dynamic videofluoroscopic assessment of scaphoid non-union in decision finding for surgical therapy**

K. [Holzapfel](#), K. Werber, E.J. Rummery, C. Hannig; *Munich/DE*

**C-624****Spectrum of imaging findings in suspected multiple myeloma using dynamic contrast-enhanced and whole body MRI**

N. [Herregods](#), K. Verstraete, S. Van Snick, K. Gorleer, V. Van Hende, L. Noens, F. Offner; *Ghent/BE*

**C-625****MR elastical characterization of trabecular bone relates to bone volume ratio and is influenced by gender**

L. [Marti-Bonmati](#), A. Alberich-Bayarri, D. Moratal, R. Sanz-Requena; *Valencia/ES*

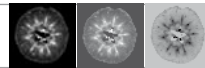
**C-626****Ewing's sarcoma: Imaging features**

B. Peersman<sup>1</sup>, F.M. [Vanhoenacker](#)<sup>1</sup>, P. Brys<sup>2</sup>, M. Stam<sup>3</sup>, K.L. Verstraete<sup>4</sup>, B. Van Herendael<sup>1</sup>, S. Heyman<sup>1</sup>, P. Van Dyck<sup>1</sup>, P.M. Parizel<sup>1</sup>, A.M. De Schepper<sup>1</sup>; <sup>1</sup>*Antwerp/BE*, <sup>2</sup>*Leuven/BE*, <sup>3</sup>*Leiden/NL*, <sup>4</sup>*Ghent/BE*

**C-627****Missed fractures in the emergency department: A structured review of the literature**

A. [Pinto](#), M. Scaglione, A. Sparano, F. Di Pietto, G. Tortora, G. Russo, L. Romano; *Naples/IT*





**C-628**

**Augmentation of cortical bone mineral density in women with polycystic ovary syndrome (PCOS): A peripheral quantitative computed tomography (pQCT) study**

A. Balanika, C. Baltas, T. Spyridopoulos, O. Papakonstantinou, D. Loggitsi, M. Mademli, E. Trakakis, A. Gouliamos; *Athens/GR*

**C-629**

**Post-surgical control after osteosynthetically treated fractures of the distal radius by means of multislice-CT**

M. Lorenzen, U. Wedegärtner, C. Weber, G. Adam, J. Lorenzen; *Hamburg/DE*

**Musculoskeletal**

**Joints**

**C-630**

**Noninfectious synovial proliferative processes: State-of-the-art MR imaging**

M.A. Santana Garcia, M.S. Garrido Carrasco, E. Alventosa Fernandez, M.C. Gonzalez Gonzalez, A. Bello Baez, M. Fernandez Del Castillo Ascanio; *Santa Cruz de Tenerife/ES*

**C-631**

**Tumours and tumour-like lesions of the intercondylar notch of the knee: A pictorial review**

A.M. Davies, M. Christie-Large, P.K.L. Li, S.L.J. James; *Birmingham/UK*

**C-632**

**Diagnostic imaging of patello-femoral incongruence**

G. Valeri, A. Quagliarini, B. Simonetti, A. Gigante, S. Ulisse, A. Giovagnoni; *Ancona/IT*

**C-633**

**A pictorial essay of MRI follow-up of the ankle in commonly used lateral ligament complex reconstructive procedures**

L. Muntaner-Gimbernat, L. Pico-Fuster, C. Reynes-Sancho, M. Camara-Baeza, A. Duran-Morell; *Palma de Mallorca/ES*

**C-634**

**Characterization of gout arthropathy by ultrasound**

C.I. Whittle, M. Cortes, G. Schiappacasse, J. Niedmann, J. MacKinnon; *Santiago/CL*

**C-635**

**Magnetic resonance imaging of knee cartilage disorders at 3.0T: Spectrum of findings**

M. Artsybasheva, S.P. Morozov, S.K. Ternovoy; *Moscow/RU*

**C-636**

**Imaging of prosthetic joint infection with focus on scintigraphy**

R. Dwarkanath, R. Jayan, C.N. Ramesh, M.L. Smith, S. Vinjamuri; *Liverpool/UK*

**C-637**

**Radiologist role in femoroacetabular impingement**

M. Martinez Montalban, A. Garcia de Vicente, J. Acosta Batlle, I. Diez Perez de las Vacas, A. Ramirez-Escobar, L. Garcia del Salto; *Madrid/ES*

**C-638**

**The frequency of middle glenohumeral ligament pathology and coexistent middle and inferior glenohumeral ligament involvement in traumatic and non-traumatic shoulder joint instability: MR arthrography findings**

M. Natsika<sup>1</sup>, I. Katsimilis<sup>1</sup>, E. Panourgias<sup>1</sup>, H. Patsopoulos<sup>1</sup>, A.H. Karantanas<sup>2</sup>; <sup>1</sup>*Athens/GR*, <sup>2</sup>*Iraklion/GR*

**C-639****Direct MR arthrography using the standard arthroscopic portals**

F. Idoate<sup>1</sup>, P. Golano<sup>2</sup>, T. Fernandez-Villa<sup>1</sup>, A. Marques<sup>1</sup>, J. Achalandabaso<sup>3</sup>, J. Bruguera<sup>1</sup>; <sup>1</sup>*Pamplona/ES*, <sup>2</sup>*Barcelona/ES*, <sup>3</sup>*San Sebastian/ES*

**C-640****Cystic lesions around the knee: MR imaging features**

M. Dias-Marra<sup>1</sup>, M. Chung<sup>1</sup>, M. Daoud-Crema<sup>1</sup>, L. Diaz<sup>1</sup>, F.W. Roemer<sup>1</sup>, S. Zaim<sup>2</sup>, A. Guermazj<sup>1</sup>; <sup>1</sup>*Boston, MA/US*, <sup>2</sup>*San Francisco, CA/US*

**C-642****Comparison of 99mTc-nanocis labelled leukocyte scintigraphy and ultrasound in diagnosis of delitescence rheumatoid arthritis of the knee joint**

V.D. Zavadovskaya, M.A. Zorkaltsev, O.Y. Kilina, N.L. Klimentenko; *Tomsk/RU*

**C-643****Haemophilic arthropathy: MR imaging features in asymptomatic patients**

O. Papakonstantinou, H. Pergantou, A. Papadopoulos, D. Loggitsi, A. Balanika, N. Economopoulos, S. Aronis, N. Kelekis, A. Gouliamos; *Athens/GR*

**C-644****Pharmacokinetic analysis of the patellar cartilage in DCE-MRI: Comparison between 1.5 and 3 Tesla**

L. Marti-Bonmati, R. Sanz; *Valencia/ES*

**C-645****Deterioration of articular cartilage associate with bone bruise after acute knee injury: Assessment with T2 mapping**

T. Okubo, A. Watanabe, H. Yamada, K. Sato, Y. Wada, T. Yamashita, K. Matsuki; *Ichihara Chiba/JP*

**C-646****MR imaging of medial meniscal root tears: Tear configuration, diagnostic accuracy, and the associated abnormalities**

J.-C. Shim, J. Kim, Y.-H. Kim, G. Lee, H. Kim, J. Suh; *Seoul/KR*

**C-647****In vitro human cartilage compression study at 3 Tesla using unique compression device**

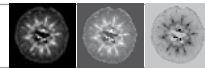
V. Juras, Z. Majdisova, M. Bittsansky, S. Trattinig; *Vienna/AT*

**C-648****Study of the anterolateral recess of the ankle with CT arthrography and MR arthrography**

E. Pessis<sup>1</sup>, A. Feydy<sup>2</sup>, R. Campagna<sup>2</sup>, J. Elis<sup>1</sup>, J. Drapé<sup>2</sup>, H. Guerini<sup>2</sup>, F. Thévenin<sup>2</sup>, A. Chevrot<sup>2</sup>; <sup>1</sup>*Saint Denis/FR*, <sup>2</sup>*Paris/FR*

**C-649****Bovine collagen meniscus implant: Long term follow-up with MRI**

M.G. Angeretti, C. Ratti, P. Bulgheroni, A. Leonardi, E. Bertolotti, E.A. Genovese, C. Fugazzola; *Varese/IT*



## Musculoskeletal

### Soft Tissue

#### C-650

##### Ulnar nerve entrapment: Dynamic ultrasound maneuvers to improve diagnosis

S. Lucarini<sup>1</sup>, C. Romagnoli<sup>2</sup>, R. Chhem<sup>2</sup>; <sup>1</sup>Firenze/IT, <sup>2</sup>London, ON/CA

#### C-651

##### Knee fat pads: What do we know about them?

L. Melao<sup>1</sup>, T. Hughes<sup>2</sup>, L. Chen<sup>2</sup>, C. Canella<sup>2</sup>, D. Resnick<sup>2</sup>; <sup>1</sup>Porto/PT, <sup>2</sup>San Diego, CA/US

#### C-652

##### Necrotizing fasciitis: Is emergent MRI useful to avoid a fatal outcome?

M. Rodríguez Alvarez, C. Saborido, J. Leon, P. Rodríguez, J. Mañas; *Vigo/ES*

#### C-653

##### Usual and unusual imaging findings of extracranial schwannomas

O. Tokuda, Y. Harada, N. Matsunaga; *Ube/JP*

#### C-654

##### Iliopsoas compartment: Normal anatomy and diverse imaging spectrum of disorders

Y. Harada, O. Tokuda, N. Matsunaga; *Ube/JP*

#### C-655

##### The value of sonographic movie-loops for dynamic assessment of functional musculoskeletal pathologies

S. Peer, G. Widmann, H. Gruber; *Innsbruck/AT*

#### C-656

##### Magnetic resonance imaging findings of leg musculature in Charcot-Marie-Tooth type 1A disease: From the beginning to the end

E. Gallardo, R. Pellón, G. Blanco, R. García-Barredo, A. García, J.A. Berciano; *Santander/ES*

#### C-657

##### Pain syndrome of the anatomical snuffbox: Differential diagnosis by high resolution ultrasound

E. Gallardo, N. Valle, J. Izquierdo, F. Peñas, R. Landeras, M.A. Fernández Echevarría; *Santander/ES*

#### C-658

##### Radiologic-pathologic correlation of musculoskeletal neurogenic tumors

M. Ruiz de Gopegui Andreu, M. Tapia Viñe, C. Martín Hervás, D. Bernabeu Taboada, F. López Barea, E. Alonso Gamarra; *Madrid/ES*

#### C-659

##### Occult groin hernias: Anatomy and techniques

S.S. Iyengar, A. Abdellaoui, M. Vouros, A. Raza, A. Davies, A. Gafoor, P. Suresh, P. Hughes; *Plymouth/UK*

#### C-660

##### Imaging of tropical pyomyositis

W.C.G. Peh<sup>1</sup>, H.E.L. Teo<sup>1</sup>, N. Pattamapaspong<sup>2</sup>; <sup>1</sup>Singapore/SG, <sup>2</sup>Chiang Mai/TH

#### C-661

##### Superficial soft-tissue masses of the extremities: Differential considerations on ultrasound

N. Kim, S. Hong, J.-Y. Choi, J. Lee, J.-A. Choi, H. Kang; *Seoul/KR*

**C-662****Classification and imaging spectrum of soft tissue vascular malformations: Guide to correct management**

R. Gupta, M. Gupta, A. Seith; *Delhi/IN*

**C-663****Role of ultrasound in the evaluation of scapholunate ligament tears: A pictorial review**

L. Pesquer<sup>1</sup>, P. Pelissier<sup>2</sup>, P. Meyer<sup>1</sup>; <sup>1</sup>Merignac/FR, <sup>2</sup>Bordeaux/FR

**C-664****Effects of strength training on metabolism of resting skeletal muscle**

M.-A. Weber<sup>1</sup>, W. Hildebrandt<sup>1</sup>, L. Schröder<sup>1</sup>, R. Kinscherf<sup>2</sup>, M. Krix<sup>1</sup>, P. Bachert<sup>1</sup>, S. Delorme<sup>1</sup>, M. Essig<sup>1</sup>, H.-U. Kauczor<sup>1</sup>, H. Krakowski-Roosen<sup>1</sup>; <sup>1</sup>Heidelberg/DE, <sup>2</sup>Mannheim/DE

**C-665****Liposarcoma or lipoma: Does cytogenetics change classic criteria?**

F. Bidault<sup>1</sup>, D. Vanel<sup>1</sup>, L.G. Shapeero<sup>2</sup>, A. Jalaguier<sup>1</sup>, A. Athanasiou<sup>3</sup>, S. Bonvalot<sup>1</sup>, P. Terrier<sup>1</sup>, F. Pedeutour<sup>1</sup>, J. Couturier<sup>1</sup>, C. Dromain<sup>1</sup>; <sup>1</sup>Villejuif/FR, <sup>2</sup>Bethesda, MD/US, <sup>3</sup>Paris/FR

**C-666****Sonographic evaluation of the rotator cuff after surgical repair of humeral diaphyseal fractures**

A. Hilarío, P. Manjon, A. Alcalá-Galiano, A. Delgado, P. Martín, R. García-Bogalo; *Madrid/ES*

**C-667****Regeneration of semitendinosus tendon harvested for ACL reconstruction: Evaluation using MRI, US and US elastography**

E.E. Drakonaki, G. Kouvidis, S. Yarmenitis, A.H. Karantanas, N. Gourtsoyiannis; *Iraklion/GR*

**C-668****How to improve performance of US in exploration of Stener's lesions: A study with anatomic correlation between US, MR and cadaveric findings**

E. Pluot, H. Guerini, C. Dumontier, A. Feydy, D. Richarme-Barthelet, J.-L. Drape; *Paris/FR*

**C-669****MR imaging of the skin at 3 Tesla: First experience on healthy volunteers**

C. Casile, S. Aubry, P. Humbert, B. Faivre, E. Delabrousse, P. Sarlieve, B. Kastler; *Besancon/FR*

**C-670****Bursitis rather than edema is associated with greater trochanteric pain syndrome: MR imaging findings with clinical correlation**

E.E. Drakonaki, A.H. Karantanas, E. Apostolaki, N. Gourtsoyiannis; *Iraklion/GR*

**C-671****Real time freehand elastography of the normal calf muscles**

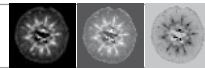
E.E. Drakonaki, S. Yarmenitis, A.H. Karantanas, N. Gourtsoyiannis; *Iraklion/GR*

**C-672****Real time freehand elastography of the normal quadriceps and patella tendons**

E.E. Drakonaki, S. Yarmenitis, A.H. Karantanas, N. Gourtsoyiannis; *Iraklion/GR*

**C-673****MR morphology of alar ligaments in asymptomatic subjects evaluated by 3 Tesla**

P. Schmidt, H.P. Burmeister, J. Boettcher, H.-J. Mentzel, W.A. Kaiser; *Jena/DE*



## Musculoskeletal

### Spine

#### C-674

##### **Chordoma: Radiologic-pathologic correlation - global view and main details**

P. Diez, R. Cano, L. Ibañez, M. Navallas, R. Navas, P. Manjon; *Madrid/ES*

#### C-675

##### **Incidental spinal osteosclerotic lesions: A pictorial review**

T. Nishiguchi, T. Nakayama, K. Mochizuki, Y. Inoue; *Osaka/JP*

#### C-676

##### **Benign bone tumors of the spine: A pictorial review**

M. Seco<sup>1</sup>, O. Vaz<sup>1</sup>, J. Brito<sup>2</sup>, B. Graça<sup>1</sup>, A. Peres<sup>1</sup>, F. Caseiro-Alves<sup>1</sup>; <sup>1</sup>*Coimbra/PT*, <sup>2</sup>*Ponta Delgada/PT*

#### C-677

##### **Destructive spondyloarthropathy in long-term haemodialysed patients: Imaging findings**

S.J. Theodorou, D.J. Theodorou, D. Resnick; *San Diego, CA/US*

#### C-678

##### **Role of imaging in the assessment and management of scoliosis**

S. Ramamurthy, V. Rachapalli, N. Goyal, S. Rashid, S. Singh, I. Gunatunga, S. Ahuja, K. Mukerjee; *Cardiff/UK*

#### C-679

##### **MR imaging features of spinal lymphoma**

L. Zhou, W. Peng, W. Yang, F. Tang; *Shanghai/CN*

#### C-680

##### **Depiction characteristics and scan method for extravasation in the sacrum in CT studies following pelvic trauma**

I. Fujimura, K. Sagara, S. Nishiike, K. Sakashita; *Izumisano/JP*

#### C-681

##### **Three-dimensional magnetic resonance imaging of the cervical spine**

T. Meindl<sup>1</sup>, S. Wirth<sup>1</sup>, S. Weckbach<sup>1</sup>, C. Born<sup>1</sup>, O. Dietrich<sup>1</sup>, M.F. Reiser<sup>1</sup>, S.O. Schönberg<sup>2</sup>; <sup>1</sup>*Munich/DE*, <sup>2</sup>*Mannheim/DE*

#### C-682

##### **Spinal CT perfusion: Possible clinical applications**

N. Valle, J. Izquierdo, E. Marco de Lucas, A. Fernández Flórez, I. Bañales, J. Crespo del Pozo, G. Blanco, M. Pelaz, A. Gutiérrez, A. González Mandly; *Santander/ES*

#### C-683

##### **Hyperextension spine fractures in ankylosing spondylitis or diffuse idiopathic skeletal hyperostosis: Spectrum of imaging findings at CT-scan and MRI**

R. Campagna, F. Thevenin, D. Richarme, A. Feydy, H. Guerini, J.-L. Drape; *Paris/FR*

**Musculoskeletal****Miscellaneous****C-684****Reduction of metal artefacts in musculoskeletal MR imaging**

J.E. Vandevenne<sup>1</sup>, K. Butts-Pauly<sup>2</sup>, P.K. Lang<sup>3</sup>, P.M. Parizel<sup>4</sup>, F. Vanhoenacker<sup>5</sup>; <sup>1</sup>Genk/BE, <sup>2</sup>Stanford, CA/US, <sup>3</sup>Boston, MA/US, <sup>4</sup>Antwerp/BE, <sup>5</sup>Duffel/BE

**C-685****Imaging findings in deep and generalized morphea (localized scleroderma)**

M.S. Horger, G. Fierlbeck, J. Fritz, M. Vogel, C. Claussen; *Tübingen/DE*

**C-686****Diffusion-weighted MR imaging in the musculoskeletal pathology: Is it useful?**

E. Balliu, I. Peláez, J. Vilanova, A. Gelabert, M. Boada, J. Puig, S. Remollo, J. Barceló, S. Pedraza; *Girona/ES*

**C-687****Neurocristopathies: Several soft tissue and musculoskeletal tumors derived from neural crest**

S. Gonzalez Ortiz, A.I. Garcia, M.S. Prevedoni, B. Paño, S. Puig; *Barcelona/ES*

**C-688****Metatarsalgia: An ultrasound atlas**

H. Guerin, G. Morvan, A. Feydy, R. Campagna, F. Thevenin, D. Richarme, A. Chevrot, J. Drapé; *Paris/FR*

**C-689**

*(No material submitted to EPOS™)*

**3.0T MRI findings of heel pain causative lesions**

L. Guimaraes<sup>1</sup>, A. Preto<sup>2</sup>, M. Pimenta<sup>2</sup>, A. Silva<sup>2</sup>, A. Vieira<sup>2</sup>; <sup>1</sup>Viseu/PT, <sup>2</sup>Porto/PT

**C-690****Hybrid angio and dynamic contrast-enhanced MR for musculoskeletal evaluation**

X. Merino-Casabiel, R. Dominguez-Oronoz, S. Gispert-Herrero, V. Pineda-Sánchez, R. Monmany-Badia, G. Garrido; *Barcelona/ES*

**C-691****Imaging of the nailbed and peronychium: MRI atlas**

T. Piedra Velasco, J. Arnáiz García, A. Canga Villegas, R. García Barredo, A. García Bolado, M. Pelaz Esteban; *Santander/ES*

**C-692****Update on radiologic evaluation of musculoskeletal infections in immunocompromised patients**

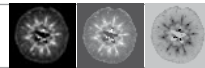
C. Vázquez Olmos, M. Martínez Fernández, A. Blanco Barrio, C. Ordoñez González, J. Plasencia Martínez, C. Ortiz Morales; *Murcia/ES*

**C-693****Musculoskeletal TB: The return of the great pretender**

N. Karunanithy; *London/UK*

**C-694****Imaging of bone and joint tuberculosis**

W.C.G. Peh<sup>1</sup>, H.E.L. Teo<sup>1</sup>, N. Pattamapasong<sup>2</sup>; <sup>1</sup>Singapore/SG, <sup>2</sup>Chiang Mai/TH



**C-695**

**Musculoskeletal non-oncological imaging with PET**

J.P. Mazzie<sup>1</sup>, S. Smith<sup>1</sup>, P. Gerard<sup>2</sup>, B. Dasgeb<sup>1</sup>, L.M. Fayad<sup>1</sup>, S. Shankman<sup>2</sup>; <sup>1</sup>Baltimore, MD/US, <sup>2</sup>Brooklyn, NY/US

**C-697**

**Unusual sites in primary extranodal involvement of non-Hodgkin lymphoma: Spectrum of imaging findings**

G. Daskalogiannakis, N.A. Courcoutsakis, A. Anastasiadis, A. Spanoudaki, K. Tsatalas, P. Prassopoulos; *Alexandroupolis/GR*

**C-698**

**Imaging spectrum of motorcycle injuries from head to toe**

S.E. Smith, J.P. Mazzie, M.D. Setton, S. Mirvis; *Baltimore, MD/US*

**C-699**

**Orthopaedic metallic implants: A pictorial review**

A. Kraus, E. Buschmann, D. Deva; *Stoke-on-Trent/UK*

**C-700**

**Minimising radiation dose in MR arthrography**

L. Manavalan; *Belfast/UK*

**C-701**

**Estimation of bone mineral density and bone strength-muscle strength relationship in elderly postmenopausal hemodialysis women using peripheral quantitative computed tomography (pQCT)**

A. Balanika, T. Spyridopoulos, C. Baltas, O. Papakonstantinou, I. Mouchtouri, A. Kelekis, G. Skarantavos, D. Vlachakos, A. Gouliamos; *Athens/GR*

**Neuro****Brain****C-702****Cerebral CT venography using 64-slice MDCT: A new door is open**

H. Patel, M. Doctor, A. Shah, G. Tomar, M. Patel; *Ahmedabad/IN*

**C-703****Sinus vein thrombosis: Review and need-to-know principles**

M. Martínez Galdamez, J. Hernanz Padial, G. Saucedo Diaz, B. Brea Alvarez, A. Vega Astudillo, P. Ruiz García; *Madrid/ES*

**C-704****Diffusion, tensor and spectroscopic MR imaging manifestations of intracranial tuberculous abscesses**

R.S.V. Vadapalli<sup>1</sup>, R. Hn<sup>2</sup>, J. Akkaraju<sup>3</sup>, G. Sreeram<sup>2</sup>, P. Pradhan<sup>2</sup>, M. Bhandari<sup>2</sup>, S. Prasanna<sup>2</sup>; <sup>1</sup>Colombo/LK, <sup>2</sup>Bangalore/IN, <sup>3</sup>Hyderabad/IN

**C-705****Cortical laminar necrosis: What, when and why**

C. Andreu, I. Hernandez, M. Manzano, B. Lopez-Botet, L. Fernandez Fresno, R. Manzanares; *Madrid/ES*

**C-706****Hyperdense hemorrhage, hematoma, and thrombus on plain CT: signs for critical pathology**

H. Odani, J. Matsumoto, S. Nakaji, Y. Minowa, Y. Nakajima; *Kawasaki/JP*

**C-707****Pericerebral fluid collections in children: Differential diagnosis using ultrasonography, computed tomography and magnetic resonance imaging**

J.E. Vazquez, N. Mayolas, I. Barber, S. Boronat, M. Roig, G. Enriquez; *Barcelona/ES*

**C-708****Brain poisoning: Accidental and intentional exposure (a review)**

A. Domingo<sup>1</sup>, M. Andreu<sup>1</sup>, J. Vives<sup>1</sup>, A. Camins<sup>2</sup>, E. Salvadó<sup>1</sup>, A. Ramos<sup>1</sup>, A. Sauri<sup>1</sup>; <sup>1</sup>Tarragona/ES, <sup>2</sup>Barcelona/ES

**C-709****Controversies of the MR based diffusion-perfusion mismatch concept for selecting acute stroke patients for thrombolytic therapy**

A. Rovira<sup>1</sup>, A. Rovira<sup>2</sup>, J. Munuera<sup>1</sup>, A. Carvajal<sup>2</sup>, G. Garrido<sup>1</sup>, A. León<sup>1</sup>, L. Frascheri<sup>1</sup>, C. Auger<sup>1</sup>; <sup>1</sup>Barcelona/ES, <sup>2</sup>Sabadell/ES

**C-710****Neurosurgical application of diffusion tensor imaging with 3D fiber tractography**

S.S. Gupta, Z.M. Patel, B.K. Misra, I. Talwar; *Mumbai/IN*

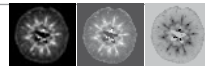
**C-711****Diffusion tensor imaging and T2 relaxometry in medial temporal lobe epilepsy on 3T MRI**

R.K. Rima Kumari, B. Guglani, R. Gupta, N. Gupta; *Delhi/IN*

**C-712****The many MR imaging faces of glioblastoma multiforme: A pictorial assay of typical and atypical features**

R.S.V. Vadapalli<sup>1</sup>, S. Perera<sup>1</sup>, F. Perera<sup>1</sup>, R. Hn<sup>2</sup>, C. Kishore<sup>2</sup>, S. Bommana<sup>2</sup>, R. Lakshmi<sup>2</sup>; <sup>1</sup>Colombo/LK, <sup>2</sup>Bangalore/IN





**C-713**

**Not so rare: Imaging findings of leptomenigeal carcinomatosis**

M. Martinez Galdamez, G. Saucedo Diaz, B. Brea Alvarez, S. Cornide Santos, C. García Roch, L. Nombela Cano; *Madrid/ES*

**C-714**

**Neuroradiological findings in epilepsy patients with hemispheric syndromes**

N. Bargalló, A. Radosevic, M. Carreño, A. Donaire, J. Setoain, M. Squarzia, S. Capurro, F. Calaf, N. Sigriz; *Barcelona/ES*

**C-715**

**Central nervous system tuberculosis: Spectrum of imaging findings at 3 Tesla MRI**

B. Guglani, R. Kumari, N. Gupta, P. Sarin; *New Delhi/IN*

**C-716**

**Imaging gallery of diseases involving the bilateral thalamus**

T.-C. Wu, Y.-K. Tsui, T.-C. Wu, T.-Y. Chen, W.-S. Tzeng; *Tainan/CN*

**C-717**

**Osmotic demyelination: A pictorial essay of MRI findings**

S.V. Bommana<sup>1</sup>, R.S.V. Vadapalli<sup>2</sup>, U.D. Patil<sup>1</sup>, B.Y.T. Arya<sup>1</sup>, R. Hanasoge<sup>1</sup>; <sup>1</sup>*Bangalore/IN*, <sup>2</sup>*Colombo/LK*

**C-718**

**MR imaging of radiation therapy- and chemotherapy-induced injury of the brain**

L. Pruzincova, V. Belan, J. Moczova, E. Boljesikova, M. Chorvat, B. Rychly, I. Makaiova, J. Steno; *Bratislava/SK*

**C-719**

**Meningeal enhancement: Causes and radiological findings**

M. Navallas, A. Martínez de Aragón, L. Ibañez, P. Dãez, R. Cano, P. Orenes; *Madrid/ES*

**C-720**

**A guide to diagnosis of acute hydrocephalus in children and importance of radiological imaging in assessment following surgical treatment**

R.C. Murphy, O. Kirmi, G. Quaghebeur; *Oxford/UK*

**C-721**

**Surface anatomy of inferior parietal lobule in high resolution three-dimensional MRI**

I. Kiriyama, H. Miki, Y. Hiratsuka, K. Kikuchi, T. Mochizuki; *Toon city/JP*

**C-722**

**Persistent trigeminal artery: Imaging by CTA and MRA with depiction of additional anatomical variations in intracerebral arterial vasculature**

A. Ghandi, H.L.J. Tanghe, D.W.J. Dippel, A. van der Lugt; *Rotterdam/NL*

**C-723**

**Neurological emergencies in HIV: A pictorial review**

R. Siripurapu, D.R. Vummidi, I.W. Turnbull; *Manchester/UK*

**C-724**

**Central nervous system involvement in systemic diseases: Spectrum of MRI findings**

A. Vendrely, F. Bonneville, D. Galanaud, J.-C. Piette, D. Dormont, J. Chiras; *Paris/FR*

**C-725****Primary central nervous system lymphoma: A great pretender**

C.H. Besada, D. Santa Cruz, J. Funes, R. García Mónaco; *Buenos Aires/AR*

**C-726****Diffusion-weighted imaging evaluation of subtle cerebral microstructural changes in intrauterine fetal hydrocephalus**

G. Erdem, O. Celik, S. Hascalik, H. Karakas, A. Alkan, A. Firat; *Malatya/TR*

**C-727****Resting-state networks in healthy young, elderly and cognitive impaired individuals**

T. Meindl, C. Born, S. Mueller, S. Teipel, A. Bokde, M.F. Reiser; *Munich/DE*

**C-728****Characterization and pre-surgical assessment of the corticospinal tract in patients with brain tumors using combined diffusion tensor tractography and fMRI**

Z. Chen, J. Xu, X. Feng, D. Geng; *Shanghai/CN*

**C-729****Amyotrophic lateral sclerosis: Correlation of fractional anisotropy values with clinical and neurophysiologic findings**

T. Gerukis, C. Hatzigeorgiou, A. Petridis, P. Sidira, V. Kimiskidis, S. Papagianopoulos, V. Kalpakidis, P. Palladas; *Thessaloniki/GR*

**C-730****The anterior pontomesencephalic-anterior medullary venous system and its bridging veins communicating to the dural sinuses: Normal anatomy and drainage routes from dural arteriovenous fistulas**

H. Kiyosue, S. Tanoue, Y. Sagara, J. Kashiwagi, Y. Hori, M. Okahara, Y. Kondo, S. Matsumoto, H. Mori; *Oita/JP*

**C-731**

(No material submitted to EPOS™)

**Fractional anisotropy of early degenerative pyramidal tract predicting outcome of motor function after ischemic stroke**

C. Yu, K. Li; *Beijing/CN*

**C-732**

(No material submitted to EPOS™)

**Hippocampal volumetry: A review**

S.V. Bommana<sup>1</sup>, R.S.V. Vadapalli<sup>2</sup>, U.D. Patil<sup>1</sup>, B.Y.T. Arya<sup>1</sup>, R. Hanasoge<sup>1</sup>; <sup>1</sup>*Bangalore/IN*, <sup>2</sup>*Colombo/LK*

**C-733****Human lymphotropic virus type I associated myelopathy/tropical spastic paraparesis: Diffusion tensor imaging evaluation of brain lesions**

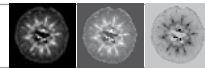
E.L. Gasparetto, L.C.H. da Cruz Jr, F. Palma, T. Doring, G. Taboada, M.T. de Freitas, R.C. Domingues, R.C. Domingues; *Rio de Janeiro/BR*

**C-734****Diagnosis of brain death: Underestimated role of MSCT angiography?**

E. Czekajska Chehab, J. Bicki, S. Uhlig, G. Staskiewicz, J. Wojczal, S. Rudzki, A. Drop; *Lublin/PL*

**C-735****Performance evaluation of radiologists with artificial neural network for differential diagnosis of intra-axial brain tumors on MR images**

K. Yamashita, T. Yoshiura, H. Arimura, Y. Yamashita, F. Mihara, T. Noguchi, A. Hiwatashi, O. Togao, Y. Higashida, H. Honda; *Fukuoka/JP*



**C-736**

**Perfusion MRI: Does it beat pathology?**

A. Hilaro, A. Ramos, P. Gonzalez, A. Perez, S. Jimenez, A. Alcalá-Galiano; *Madrid/ES*

**C-737**

**Diffusion changes in peritumoral tissue after surgery for glioblastoma: Possible prediction of radiotherapy response**

J. Qu, T. Jiang, L. Ai, S. Li, J. Dai; *Beijing/CN*

**C-738**

**Relationship between CT perfusion and brain tissue oxygen tension in head trauma patients: Preliminary results**

M.J. Picado, J. Pérez-Bárcena, A. Mas, A. Moll, J. Ibañez, J.A. Llompart, M. Brell; *Palma de Mallorca/ES*

**C-739**

**Treatment of intracranial aneurysms with Leo stent: A long-term follow-up study**

J.M. Pumar, L. Lopez-Carreira, S. Baleato, C. Ruibal, M. Blanco, F. Vazquez; *Santiago de Compostela/ES*

**C-740**

**3D diffusion weighted whole body imaging in patients with solitary brain metastases**

M.B. Dolgushin, L.M. Fadeeva, A.Y. Zaitceva, I.N. Pronin, P.V. Rodionov, V.N. Kornienko; *Moscow/RU*

**C-741**

**Proton magnetic resonance spectroscopy (MRS) in the evaluation of diffuse axonal injury**

W.B. Zheng, Y.L. Guo, H.D. Zhang; *Shantou/CN*

**C-742**

**Proton MR spectroscopy in the evaluation of axonal injury: Correlation with clinical outcome after traumatic brain injury**

W.B. Zheng, R.W. Chen, C.L. Ma; *Shantou/CN*

**C-743**

**Non-invasive assessment of brain masses using susceptibility weighted imaging**

L. Guan, S. Li, K. Xu; *Shenyang/CN*

**C-744**

**Functional connectivity analysis for paranoid schizophrenic patients in resting state and digital 2-back task**

Q. Zhang, Y. Zhang, W. Li, H. Ren; *Tianjin/CN*

**C-745**

**Working memory in mild cognitive impaired subjects in comparison with healthy young and elderly controls**

T. Meindl, C. Born, S. Hoehler, A. Bokde, S. Teipel, M.F. Reiser; *Munich/DE*

**C-746**

**MRS thalamus metabolic changes and clinical test correlation in schizophrenic patients with and without auditory hallucinations**

B. Martínez-Granados<sup>1</sup>, M.C. Martínez-Bisbal<sup>1</sup>, J. Sanjuan<sup>2</sup>, O. Brotons<sup>2</sup>, L. Martí-Bonmati<sup>2</sup>, B. Celda<sup>1</sup>; <sup>1</sup>*Burjassot (Valencia)/ES*, <sup>2</sup>*Valencia/ES*

**C-747**

**Understanding in-vitro poor cerebrospinal fluid suppression on gadolinium-enhanced FLAIR images**

L. Roccatagliata<sup>1</sup>, L. Bonzano<sup>1</sup>, F. Leviero<sup>1</sup>, G.L. Mancardi<sup>1</sup>, F. Sardanelli<sup>2</sup>, G. Cornalba<sup>2</sup>; <sup>1</sup>*Genoa/IT*, <sup>2</sup>*Milan/IT*

**C-748**

**Regional fiber degeneration in the corpus callosum monitored by fractional anisotropy correlates to FLAIR hypodensities and black holes in MS patients**

B. Bellenberg<sup>1</sup>, C. Lukas<sup>1</sup>, A. Haghikia<sup>1</sup>, M. Fischer<sup>1</sup>, J. Klein<sup>2</sup>, H.K. Hahn<sup>2</sup>, C. Beste<sup>1</sup>, M. Hausmann<sup>1</sup>, O. Köster<sup>1</sup>, S. Schimrigk<sup>1</sup>; <sup>1</sup>Bochum/DE, <sup>2</sup>Bremen/DE

**C-749**

**Regional quantification of brain cerebral blood volume maps using the Talairach proportional grid system**

J. Guzman, S. Reig, J. Olazaran, I. Cruz, E. Navarro, D. Ezpeleta, J.M. Mateos, V. Garcia, M. Desco; Madrid/ES

**C-750**

**Non local means filter enhances fMRI signal detection**

J.J. Lull, J.V. Manjón, G. Garcia-Martí, L. Martí-Bonmatí, M. Robles; Valencia/ES

**C-751**

**Artifacts during MRI of the brain at 3 Tesla: Types and remedies**

M. Spirowski<sup>1</sup>, K.M. Koprivsek<sup>1</sup>, M.A. Lucic<sup>1</sup>, V. Zlokolica<sup>2</sup>, D. Kozic<sup>1</sup>, P.M. Parizek<sup>3</sup>; <sup>1</sup>Sremska Kamenica/RS, <sup>2</sup>Novi Sad/RS, <sup>3</sup>Antwerp/BE

**C-752**

**Functional imaging with MR T1 contrast: A feasibility study with blood-pool contrast agent**

A. Majos<sup>1</sup>, P. Bogorodzki<sup>2</sup>, E. Piatkowska-Janko<sup>2</sup>, T. Wolak<sup>2</sup>, R. Kurjata<sup>2</sup>, L. Stefanczyk<sup>1</sup>; <sup>1</sup>Lodz/PL, <sup>2</sup>Warsaw/PL

**C-753**

**Fifteen years follow-up with MRI in very low birth-weight children**

C. Wang, O. Flodmark, P.-O. Gaddlin, P.-O. Gaddlin; Stockholm/SE

**C-754**

**Nociception in men and women using 3 Tesla MR spectroscopy**

P. Schmidt, A. Gussew, R. Rzanny, J.R. Reichenbach, W.A. Kaiser; Jena/DE

**C-755**

**Elevated choline/creatine ratio in central nervous system arterial infarction: Frequency, timing, extent and the effect of echo time**

M.B. Vardar, G. Akansel, N. Inan, H.T. Sarisoy, A.S. Arslan, E. Giftci, A. Demirci; Kocaeli/TR

**C-756**

**Listening to Mozart piano concert K. 491 in C-minor, part II Larghetto facilitates a visually driven complex motor task during bold fMRI in females, but not in males**

G. Akansel, B. Gulleroglu, H.T. Sarisoy, Y. Anik, A.S. Arslan, A. Demirci; Kocaeli/TR

**C-757**

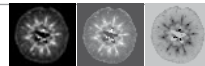
**Fusion of MRI and SPECT images as the method of planning spectroscopy in order to assess hot spots of brain tumors**

P. Grzelak, A. Majos, M. Górska-Chrzastek, J. Kusmierek, M. Olszycy, W. Gajewicz, L. Stefanczyk; Lodz/PL

**C-758**

**Volumetric measurement of human red nucleus with 3D fast spin echo T2-weighted sequence MR imaging**

E. Rahimian<sup>1</sup>, M.R. Tahsini<sup>1</sup>, A. Vossough<sup>2</sup>, B. Ohadi<sup>1</sup>; <sup>1</sup>Tehran/IR, <sup>2</sup>Boston, MA/US



**C-759**

**Prevalence of subependymal giant cell tumors in a large cohort of patients with tuberous sclerosis complex and preliminary results of a non-invasive treatment**

M.E.A.P. Adriaensen<sup>1</sup>, D.A.C. Duyndam<sup>2</sup>, B.A. Zonnenberg<sup>3</sup>, M. Prokop<sup>3</sup>; <sup>1</sup>*Amersfoort/NL*, <sup>2</sup>*Amsterdam/NL*, <sup>3</sup>*Utrecht/NL*

**C-760**

**Detection and characterization of intracranial aneurysms with volume CT digital subtraction angiography: Comparison with conventional DSA and CTA**

F. Lv<sup>1</sup>, T. Luo<sup>1</sup>, J. Liao<sup>2</sup>, Y. Shen<sup>2</sup>, K. Chen<sup>2</sup>, J. Li<sup>2</sup>; <sup>1</sup>*Chongqing/CN*, <sup>2</sup>*Beijing/CN*

**C-761**

**Autopsy imaging (Ai), a new imaging horizon in pathology by using multidetector computed tomography (MDCT)**

S. Yamamoto, K. Motoori, R. Shimofusa, T. Horikosi, T. Kazama; *Chiba/JP*

**C-762**

**Postmortem study of patients with dementia: Radiological and histological findings in the hippocampus**

T. Cabada, C. Echávarri, C. Caballero, T. Tuñón, C. Bacaicoa, I. Insausti; *Pamplona/ES*

**C-763**

**Evaluation of CT perfusion parameters in thrombolytic therapy (intravenous rt-PA injection) for acute cerebral infarction**

K. Yuba, Y. Yoshimoto, D. Yamana, H. Ohkawa, K. Wada, K. Ono, K. Suzuki; *Meguro-ku, Tokyo/JP*

**C-764**

**Correlation of PET hypo- and hypermetabolism with surgical outcome in refractory epilepsy**

R. Talanow, G. Wu; *Cleveland, OH/US*

**C-765**

**Investigation of optimal volume rendering image in brain surface with high resolution three-dimensional MRI**

I. Kiriyama, H. Miki, Y. Hiratsuka, K. Kikuchi, T. Mochizuki; *Toon city/JP*

**C-766**

**Diffusion-weighted images in the evaluation of meningiomas: Radiopathologic correlation**

T. Cabada, I. Insausti, C. Caballero, T. Tuñón, C. Bacaicoa, J. Olier; *Pamplona/ES*

**C-767**

**Evaluation of subtracted cerebral 3D-CT angiography at lower tube voltage**

T. Gomi<sup>1</sup>, M. Hasegawa<sup>1</sup>, A. Kato<sup>1</sup>, M. Nagamoto<sup>1</sup>, E. Kohda<sup>1</sup>, M. Tsunoo<sup>2</sup>, H. Terada<sup>2</sup>; <sup>1</sup>*Tokyo-Meguro/JP*, <sup>2</sup>*Chiba/JP*

**C-768**

**The effect of ethyl alcohol on the central nervous (CNS) system determined with the HMRS technique**

A. Urbanik, B. Sobiecka, J. Kozub; *Krakow/PL*

**C-769**

**The use of DYNA-CT in neuroradiology**

A. Urbanik, T. Turski, T.J. Popiela, P. Brzegowy; *Krakow/PL*

**C-770**

**The appearance of decussation of superior cerebellar peduncle in DTI**

Y. Dou<sup>1</sup>, H. Han<sup>2</sup>, S. Guo<sup>1</sup>, Y. Feng<sup>2</sup>, J. Pi<sup>3</sup>; <sup>1</sup>*Lanzhou/CN*, <sup>2</sup>*Peking/CN*, <sup>3</sup>*Changzhi/CN*

**C-771****Optimisation of hypercapnia paradigms using cued breath holding at 1.5 T and 3.0 T**

D. Bos, A. van der Lugt, M. Smits; *Rotterdam/NL*

**C-772****Multidetector-row CT angiography for evaluation of arterial dissection of the anterior cerebral artery**

I. Matsuda, I. Shirouzu, S. Amemiya, J. Kazaoka, H. Akai, M. Noda, T. Machida; *Tokyo/JP*

**C-773****Fetal ventriculomegaly: MRI investigation**

T. Stosic-Opinca, V. Peric, S. Lavrnica, M. Gavrilov, R. Milenkovic; *Belgrade/RS*

**C-774****The connection between the auditory center of bilateral temporal lobes: A BOLD fMRI and tractography study**

Z. Wang, M. Chen, H. Song, C. Zhou; *Beijing/CN*

**C-775****Long-term follow-up angiography of intracranial aneurysms treated with Cook detachable coil system**

J.M. Pumar, I. Lete, S. Baleato, M. Blanco, F. Vazquez, A. Garcia-Allut; *Santiago de Compostela/ES*

**C-776****Pattern of brain atrophy in elderly patients with depression revealed by voxel-based morphometry**

K. Egger, M. Schocke, E. Weiss, S. Auffinger, R. Esterhammer, G. Goebel, T. Walch, S. Mechtcheriakov, J. Marksteiner; *Innsbruck/AT*

**Neuro****Brain and Spine****C-777****MR imaging of the normal/diseased abducens nerve**

S. Dekeyser, M. Lemmerling, K. Verstraete; *Gent/BE*

**C-778**

*(No material submitted to EPOS™)*

**Central nervous system parasitic infections: Current trends due to immigration and world-wide travelling**

M. Navallas, A. Martínez de Aragón, R. Cano, L. Ibañez, A. Ortiz de Mendivil, E. Salto; *Madrid/ES*

**C-779****Pituitary apoplexy: A review of imaging findings**

S.H. Liyanage, L.M. Vearncombe, J. Evanson; *London/UK*

**C-780****Cavernous sinus dural arteriovenous fistula: Shunt point, venous drainage and alternative treatment options**

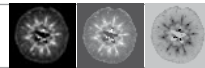
Y. Sagara, H. Kiyosue, S. Tanoue, J. Kashiwagi, Y. Hori, M. Okahara, H. Mori; *Oita/JP*

**C-781****Imaging CNS complications after bone marrow transplantation**

T. Nishiguchi, K. Mochizuki, T. Nakane, Y. Inoue; *Osaka/JP*

**C-782****Typical, atypical and misleading MR imaging manifestations of common and not so common cerebrospinal infections**

R.H.N. Hanasoge, R.V.S.V. Vadapalli, R. Anantasivan, M. Srinivas, S.V. Bommana; *Bangalore/IN*



**C-783**

**Cavernous sinus pathology: CT and MRI findings**

J. Rimoldi, A. Buzzi, A. Gaser, F. Arredondo, Y. Pardo, E. Salum; *Ciudad de Buenos Aires/AR*

**C-784**

**Precise image-guided infrequent therapeutic and diagnostic neurointerventional procedures**

A. Kraus, C.K. Jadun, P.S. Dias; *Stoke-on-Trent/UK*

**C-785**

**Antomy and pathology of the brainstem: A gaze into the stem of life**

M.A. Fernández-Gil, R. Palacios Bote, R. Querol Pascual, M. Ortega Martínez, G. Guerrero Martínez, F. Ugarriza Echevarrieta; *Badajoz/ES*

**C-786**

**MR imaging of rare congenital and acquired pathology of sellar and parasellar regions**

A.C. Athanassopoulou, I.V. Kalogeropoulos, A.N. Chalazonitis, G. Neofitou, M. Kelogrigoris, A. Kokkinaki, P. Piperopoulos, A.D. Gouliamos; *Athens/GR*

**C-787**

**Neurological imaging findings of neurocutaneous syndromes (phakomatosis) in MRI: A pictorial review**

C. Andreu, B. Lopez-Botet, M. Manzano, J. Cuesta, R. Manzanares, L. Fernandez Fresno; *Madrid/ES*

**C-788**

**Embryology, anatomy and pathology of the pituitary gland and perisellar region: MR imaging features**

S. Van Damme, W. Bauters, L. Jans, N. Herregods, K. Verstraete, E. Achten, K. Deblaere; *Gent/BE*

**C-789**

**Dural arteriovenous fistulae of the cavernous sinuses on contrast-enhanced 3D dynamic MR angiography**

H. Akiba, N. Yama, M. Tamakawa, H. Hyodoh, K. Hyodoh, M. Hareyama, T. Satoh, Y. Kawai; *Sapporo/JP*

**C-790**

**Double reading (DR) of neuroradiological MRI: Results of a 12 months period**

M. Serrallonga, E. Grivé, S. Domènech, C. Schorlemmer, H. Billing; *Barcelona/ES*

**C-791**

**Four dimensional imaging of the normal and pathological pituitary gland by using TRICKS on 3T MRI**

A. Wada, T. Hayashi, T. Katsube, N. Okada, N. Yamamoto, Y. Tsuchie, T. Yoshizako, N. Uchida, H. Kitagaki; *Izumo/JP*

**C-792**

**Dynamic relationships model of the craniospinal fluids in healthy volunteers using phase contrast magnetic resonance imaging**

N. Flórez, D. Moratal, L. Martí-Bonmatí, J. Forner, E. Arana; *Valencia/ES*

**Neuro****Spine****C-793****Extra spinal sciatica revisited: A pictorial essay of CT and MRI features**

R.S.V. [Vadapalli](#)<sup>1</sup>, R. Mulukutla<sup>2</sup>, R. Ananthasivan<sup>3</sup>, D. Singh<sup>3</sup>, E. Bari<sup>3</sup>; <sup>1</sup>Colombo/LK, <sup>2</sup>Hyderabad/IN, <sup>3</sup>Bangalore/IN

**C-794****Spine demyelinating chronic disorders: A MR DTI-fiber tracking study**

A. [Paniagua Bravo](#), J. Romero Martínez, G. Medrano Seoane, J. Ciampi Dopazo, S. Ossaba Vélez; *Madrid/ES*

**C-795****Imaging spectrum of Hirayama flexion myelopathy**

S.S. [Krishnan](#), N. Chidambaranathan; *Chennai/IN*

**C-796****Diffusion tensor imaging and MR spectroscopic findings of cervical spinal cord**

M. [Hori](#), S. Aoki, O. Abe, H. Kabasawa, K. Ohtomo, A. Yamaguchi, M. Shimada, N. Shiraga; *Tokyo/JP*

**C-797****Spondylodiscitis: Spectrum of imaging findings**

A.S.R. [Preto](#), M. Pimenta, D.M. Rocha, C. Reis, J. Gonçalves; *Porto/PT*

**C-798****Radiological study of biodegradable spinal implant in cervical arthrodesis**

M. [Gimeno](#), R. Lasierra, J. Calatayud, C. Del Rio, B. Carro, J. Pina; *Zaragoza/ES*

**C-799****Spinal DTI for dummies**

E. [Sánchez](#), E. Marco de Lucas, E. Ruiz, A. Gutiérrez, F. Quintana, I. Bañales, A. Fernández Flórez, J. Izquierdo, J. Crespo del Pozo; *Santander/ES*

**C-800****Usefulness of CSF flow-cine MRI for spinal pathology**

N. Valle, E. [Sánchez](#), E. Marco de Lucas, R. Pellón, L. Martín, V. Álvarez de Eulate, E. Ruiz, A. Gutiérrez, A. González Mandly; *Santander/ES*

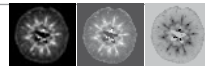
**C-801****Tuberculous spondylitis with nonsurgical treatment: MR imaging characteristics in follow-up period and correlation with drug response**

H. Gweon, D. [Kim](#), S. Suh, T.-S. Chung, D. Kim, K. Kim, Y. Cho; *Seoul/KR*

**C-802****High-resolution, three-dimensional MRA using intravascular contrast agent in detection of spinal AV malformation**

L. [Klzo](#), J. Zizka, A. Krajina, P. Ryska, V. Málek; *Hradec Kralove/CZ*





## Pediatric

### Abdominal

#### C-803

##### Assessment of hepatoblastoma: Impact of the radiology in its therapeutic approach

E. Valbuena, M. Parrón, J. Fernández-Cuadrado, I. Pastor, P. García Miguel, C. Prieto; *Madrid/ES*

#### C-804

##### Complications following pediatric liver transplantation through 64-slice computed tomography: A wise approach

G. Gallardo-Madueño, M. Parrón, I. Pastor, C. Prieto, R. Rodríguez-Lemos, M. López-Santamaría; *Madrid/ES*

#### C-805

##### Congenital intrahepatic portosystemic shunts

J.M. O'Brien, D. Rea, A. Broderick, E. Phelan; *Dublin/IE*

#### C-806

##### Imaging findings of pancreatic disorders in children

R. Sanchez<sup>1</sup>, I. Solis<sup>2</sup>, E. Stranzinger<sup>1</sup>, C. Serrano<sup>2</sup>; <sup>1</sup>*Ann Arbor, MI/US*, <sup>2</sup>*Murcia/ES*

#### C-807

##### Duodenal diseases in children: A pictorial essay

G. Pose, C. Whittle, G. Soto Giordani, A. Bataszew, G. Palominos; *Santiago/CL*

#### C-808

##### Usefulness of inner hypoechoic band of vermiform appendix as ultrasonographic criteria for the diagnosis of acute appendicitis in children

B. Kim, G. Choi, S. Kim, J. Park, K. Kim, H. Kang, K.-S. Kang; *Jeju City/KR*

#### C-809

##### Gastro-oesophageal reflux in paediatric patients: Evaluation with contrast enhanced ultrasound

P.V. Foti, R. Farina, F. Pennisi, G. Mazzone, R. Minardi, G.C. Ettore; *Catania/IT*

#### C-810

##### Pediatric abdominal Burkitt lymphoma: The spectrum of sonographic findings at presentation

M. Vakaki, G. Pitsoulakis, E. Dagiakidi, C. Koumanidou; *Athens/GR*

## Pediatric

### Lung

#### C-811

##### Unusual complications in "Mycoplasma pneumoniae" pneumonia in childhood

C.M. Rodriguez, J.L. Vazquez, M.L. Gonzalez; *Vigo/ES*

#### C-812

##### Congenital chylothorax: From fetus to adolescence

P. Martin, C. Gallego, A. Galindo, C. Medina, A. Hilario, M. Miralles; *Madrid/ES*

#### C-813

##### Pulmonary cryptococcosis with extrapulmonary involvement in immunocompetent children: Clinical and HRCT characteristics

Y. Peng, G. Sun, J. Zeng; *Beijing/CN*

**C-814****Congenital diaphragmatic hernia (CDH): Monitoring of fetal lung growth with MRI after fetal endoscopic tracheal occlusion (FETO)**

A. Kilian<sup>1</sup>, K.A. Busing<sup>1</sup>, T. Kohl<sup>2</sup>, T. Schaible<sup>1</sup>, K. Neff<sup>1</sup>; <sup>1</sup>Mannheim/DE, <sup>2</sup>Bonn/DE

**Pediatric****Musculoskeletal****C-815****Childhood osteochondroses: A review of the clinical and imaging features**

J.M. O'Brien, E. Ward, O. Buckley, E. Colhoun, M. Ryan; *Dublin/IE*

**C-816****The toddler refusing to weight bear: A revised imaging approach**

O.J. Arthurs, A.C. Gomez, P.A.K. Set; *Cambridge/UK*

**C-817****Role of MR on vascular anomalies affecting the extremities**

M. Ruiz de Gopegui Andrey, M. Parrón, C. Martín Hervás, S. Morón, T. Berrocal, J.C. López Gutiérrez; *Madrid/ES*

**Pediatric****Neuro****C-818****Intracranial meningioma of pediatrics: Manifestations in 16 patients**

H. Eo, J. Kim, S.-Y. Yoo; *Seoul/KR*

**C-819****Analysis of MRI spectrum of brain abnormalities in infants with congenital cytomegalovirus disease: Data from an institution**

E. Jurkiewicz, B. Milewska-Bobula, I. Pakula-Kosciesza; *Warsaw/PL*

**C-820****Apnoea in term newborns with temporal lobe haemorrhage**

S.R. Hoogstraate<sup>1</sup>, M.H. Lequin<sup>2</sup>, P.P. Govaert<sup>2</sup>; <sup>1</sup>Dordrecht/NL, <sup>2</sup>Rotterdam/NL

**C-821****Metabolite alterations in autistic children: A 1H MR spectroscopy study**

B. Kubas<sup>1</sup>, J. Walecki<sup>2</sup>, E. Tarasow<sup>1</sup>, W. Kulak<sup>1</sup>, K. Kaminska<sup>2</sup>, W. Sobaniec<sup>1</sup>; <sup>1</sup>Bialystok/PL, <sup>2</sup>Warsaw/PL

**C-822****Intra and inter observer variability and repeatability of fetal brain sulcation assessed on MRI**

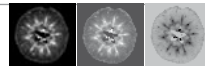
K. Brauer, A.D. Murray, T.W. Redpath, S. Olson, K.A. Duncan; *Aberdeen/UK*

**Pediatric****Urogenital****C-823****Congenital abnormalities of the kidney and lower urinary tract: From genesis to imaging findings. A pictorial review**

M.F.R. Pires, L. Lobo, J. Inácio, J. Fonseca-Santos; *Lisbon/PT*

**C-824****Value of color Doppler ultrasound for the early diagnosis and outcome of neonatal renal venous thrombosis**

A. Hilarino, C. Gallego, M. Miralles, C. Medina, P. Martín, A. Delgado; *Madrid/ES*



**C-825**

**Evaluation of pelvic ultrasonography in diagnosis and differentiation of various forms of sexual precocity in girls**

M. Bandouraki, A. Christoforidis, I. Economou, A.S. Dimitriadis, G. Katzos; *Thessaloniki/GR*

**C-826**

**Voiding cystosonography for the study of the urethra**

C. Duran, A. Valera, A. Alguersuari, E. Ballesteros, C. Martin, J. Puig; *Sabadell/ES*

**C-827**

**The role of color Doppler sonography in the detection of crossing vessels in children with pelviureteric junction obstruction**

M. Vakaki, A. Hountala, P. Zodiatis, E. Dagiakidi, C. Koumanidou; *Athens/GR*

**Pediatric**

**Vascular**

**C-828**

**Scanning method for pediatric congenital heart disease (CHD): Extremely low-dose scanning using multislice CT**

S. Nagaoka<sup>1</sup>, H. Obata<sup>1</sup>, T. Nakazawa<sup>1</sup>, S. Yasukochi<sup>1</sup>, M. Kanou<sup>2</sup>; <sup>1</sup>*Azumino, Nagano/JP*,  
<sup>2</sup>*Nagoya, Aichi/JP*

**C-829**

**Sixty four row CT angiography: A non-invasive method for the diagnosis of pediatric cardiovascular disease**

M. Ulla, F. Abramzón, J. San Román, P. Marantz, R. García Mónaco; *Buenos Aires/AR*

**C-830**

**MDCT evaluation of bidirectional carvopulmonary shunt and Blalock-Taussig shunt in pediatric patients with single ventricle: Correlation with angiography**

K. Choo, H. Lee, S. Sung, J. Ban, Y. Chang, J. Kim, J. Kim; *Pusan/KR*

**Pediatric**

**Miscellaneous**

**C-831**

**Imaging considerations of pediatric thyroid disease**

Y.-W. Chang<sup>1</sup>, H. Hong<sup>2</sup>, D. Choi<sup>1</sup>, D. Lee<sup>1</sup>; <sup>1</sup>*Seoul/KR*, <sup>2</sup>*Buchoen/KR*

**C-832** *(No material submitted to EPOS™)*

**Hydatid disease in various anatomic locations in childhood: Radiological appearances**

M.H. Atalar, H. Egilmez, P. Erdinc, M. Isleyen, S. Bulut; *Sivas/TR*

**C-833**

**Radiation-dose reduction and improved contrast enhancement at multidetector CT (MDCT) using a low tube voltage technique**

Y. Yanaga, K. Awai, Y. Nakayama, Y. Funama, T. Nakaura, T. Namimoto, Y. Yamashita; *Kumamoto/JP*

**C-834**

**Lumps in the breast of children and adolescents**

L. Ibañez, M. Gallego, P. Díez, R. Cano, E. Salvador, E. Monedero; *Madrid/ES*

**C-835**

**Infants of diabetic mothers: Imaging perspective**

I.A. Alorainy, N.B. Barlas; *Riyadh/SA*

**C-836****Sonography in the evaluation of major salivary glands in childhood: A pictorial review**

M. Vakaki, G. Pitsoulakis, E. Dagiakidi, C. Koumanidou; *Athens/GR*

**C-837****Imaging the diaphragm in children**

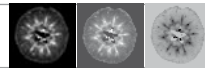
C. Géhanne, M. Cassart, F. Avni; *Brussels/BE*

**C-838****Diagnostic value of PET/CT with contrast enhancement for the staging and restaging of pediatric tumors**

M.A. Kleis<sup>1</sup>, H.E. Daldrup-Link<sup>2</sup>, K.K. Matthay<sup>2</sup>, R.E. Goldsby<sup>2</sup>, E.J. Rummeny<sup>1</sup>, T. Schuster<sup>1</sup>, R.A. Hawkins<sup>2</sup>, B.L. Franc<sup>2</sup>; <sup>1</sup>*Munich/DE*, <sup>2</sup>*San Francisco, CA/US*

**C-839****A systematic approach to dose optimization in pediatric digital X-ray imaging of the spine**

P. Brosi, R.W. Wolf; *Bern/CH*



## Physics in Radiology

### CT

#### C-840

**Low tube voltage 'SnapShot Pulse' prospective electrocardiograph (ECG)-triggered coronary 64-slice CT angiography (CTA) in children and slim patients**

J. Honiguchi, M. Kiguchi, C. Fujioka, N. Hirai, N. Matsuura, K. Ito; *Hiroshima/JP*

#### C-841

**How to optimize image quality and reduce overall patient population dose in MDCT cardiac imaging**

J. Li, W. Qi, X. Du; *Beijing/CN*

#### C-842

**Artifacts in CT: The mechanism and the methods of avoidance**

J. Kim; *Goyang-si/KR*

#### C-843

**Anatomy and physiology of multi-channel CT: What a radiologist needs to know**

N.N.N. Naguib, N. Mohammed, T.J. Vogl; *Frankfurt a. Main/DE*

#### C-844

**Achieving consistent image quality and dose reduction for MDCT coronary artery imaging with body mass index adapted tube current selection**

G. Wang, J. Gao, J. Li, N. Li; *Beijing/CN*

#### C-845

**CT-AEC image characteristics for sharp changes in X-ray absorption (step characteristics)**

I. Aizawa, Y. Muramatsu, K. Yokohama, F. Shimizu, T. Tanaka; *Chiba/JP*

#### C-846

**Image noise reduction based on wavelet transform maxima for CT image**

M. Ikeda<sup>1</sup>, R. Hitomi<sup>1</sup>, K. Imai<sup>1</sup>, M. Matsumoto<sup>1</sup>, A. Fujiwara<sup>1</sup>, S. Wada<sup>2</sup>; <sup>1</sup>Nagoya/JP, <sup>2</sup>Niigata/JP

#### C-847

**An anthropomorphic, cardiovascular flow phantom for CT contrast and imaging protocol optimization**

J.F. Kalafut<sup>1</sup>, C. Kemper<sup>1</sup>, S. Sammet<sup>2</sup>; <sup>1</sup>Indianola, PA/US, <sup>2</sup>Columbus, OH/US

## Physics in Radiology

### Dose

#### C-848

**How to use ECG mA modulation to reduce radiation dose in cardiac imaging: Consideration and experience summary**

J. Liao<sup>1</sup>, L. Liu<sup>2</sup>, Y. Shen<sup>1</sup>, J. Li<sup>1</sup>; <sup>1</sup>Beijing/CN, <sup>2</sup>Kunming/CN

#### C-849

**Evaluation on the influence of ECG mA modulated on image quality and exposure dosage of CT cardiac scan with fluctuant heart rate**

Y. Yan<sup>1</sup>, S. Yun<sup>2</sup>, X. Jianrong<sup>1</sup>; <sup>1</sup>Shanghai/CN, <sup>2</sup>Beijing/CN

#### C-850

**Organ dose evaluation of in-vivo micro-CT**

N. Buls, I. Willekens, J. de Mey; *Jette/BE*

**C-851****Audit of radiation dose during coronary MSCT angiography: A comparative study of different scanning protocols**

D. Shao, H. Ling, X. Lin, Y. Liu, K. Chen; *Shanghai/CN*

**C-852****Development of pediatric CT protocols to obtain minimal doses in PET/CT studies: A physicist's approach**

W. Nordhøy, M. Sheikhaeri, A. Larsen, O. Glomset; *Oslo/NO*

**Physics in Radiology****MR****C-853****Artefacts at high-field MRI**

G.J. Kraus, W. Drahanowsky, S. Robinson; *Vienna/AT*

**C-854****Whole-body magnetic resonance imaging: Techniques and clinical applications**

E. Onur, M. Secil, A.Y. Göktay, M. Manisali, D. Özaksoy, O. Dicle; *Izmir/TR*

**C-855****Principles of k-space sampling**

P. Paolantonio, R. Ferrari, M. Rengo, P. Lucchesi, F. Vecchietti, A. Laghi; *Latina/IT*

**C-856****Do you really know what is inside your MR scanner? Advanced anatomy of the magnet for young residents and adult radiologists**

M. Anzidei, A. Napoli, B. Cavallo Marincola, C. Zini, P. Di Paolo, C. Catalano, R. Passariello; *Rome/IT*

**C-857****Overview of current testing methods and standards for magnetic resonance safety and compatibility of medical devices**

G. Schaeffers; *Gelsenkirchen/DE*

**C-858****Spatial factors for quantifying constant flow velocity in a small tube phantom: Comparison between phase-contrast cine MR imaging and intraluminal Doppler guidewire**

H. Machida<sup>1</sup>, Y. Komori<sup>1</sup>, E. Ueno<sup>1</sup>, Y. Shen<sup>1</sup>, K. Okajima<sup>1</sup>, M. Fujimura<sup>1</sup>, M. Hirata<sup>1</sup>, S. Morita<sup>1</sup>, K. Suzuki<sup>1</sup>, S. Kojima<sup>1</sup>, M. Sato<sup>1</sup>, T. Okazaki<sup>2</sup>; <sup>1</sup>*Tokyo/JP*, <sup>2</sup>*Aichi/JP*

**C-859****2004/40/EC directive: Characterization of diagnostic room electromagnetic environment due to radiological activities**

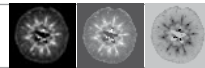
M. De Marco, S. Maggi; *Ancona/IT*

**C-860****Assessment of different image reconstruction methods for DCE-MRI**

F. Knoll, R. Stollberger, F. Ebner; *Graz/AT*

**Physics in Radiology****Miscellaneous****C-861****What is the most effective indicator for estimating the maximum radiation dose to the patient during percutaneous coronary intervention procedures?**

K. Chida, Y. Kagaya, K. Fuda, Y. Morishima, H. Saito, S. Takahashi, S. Yamada, M. Zuguchi; *Sendai/JP*



**C-862**

**The twinkling body: A pictorial guide to all possible anatomical locations of the colour Doppler twinkling artifact**

A. Nunziata, O. Catalano, P.P. Saturnino, F. Sandomenico, S. Paoletta, A. Siani; *Naples/IT*

**C-863**

**Color Doppler twinkling artifact in various conditions during abdominal ultrasonography: Pearls and pitfalls**

H. Kim, D. Yang, W. Jin; *Seoul/KR*

**C-864**

**Pulsating cardiac phantom and coronary flow phantom on the multi-modality cardiac study: Overview and history from over 10 years of experience in phantom development and phantom experiments**

Y. Shen, J. Liao, J. Li; *Beijing/CN*

**C-866**

**FP-CIT brain SPECT data: Description of a semi-quantitative analysis method**

E.M. Covelli, E. Tedeschi, P. Sullo, M. Salzillo, G. Mazzarella, G. Belfiore; *Caserta/IT*

**C-867**

**Refraction-enhanced tomosynthesis of joints by X-ray dark-field imaging**

D. Shimao<sup>1</sup>, T. Kunisada<sup>2</sup>, H. Sugiyama<sup>3</sup>, M. Ando<sup>4</sup>; <sup>1</sup>Inashiki-gun/JP, <sup>2</sup>Okayama/JP, <sup>3</sup>Tsukuba/JP, <sup>4</sup>Noda/JP

**C-868**

**Reference levels at European level for cardiac interventional procedures**

R. Padovani<sup>1</sup>, E. Vano<sup>2</sup>, K. Faulkner<sup>3</sup>, A. Trianni<sup>1</sup>, C. Bokou<sup>4</sup>, A. Dowling<sup>5</sup>, O. Dragusin<sup>6</sup>, J. Jankowski<sup>7</sup>, V. Tsapaki<sup>8</sup>, J. Vassileva<sup>9</sup>; <sup>1</sup>Udine/IT, <sup>2</sup>Madrid/ES, <sup>3</sup>Newcastle/UK, <sup>4</sup>Luxembourg/LU, <sup>5</sup>Dublin/IE, <sup>6</sup>Leuven/BE, <sup>7</sup>Lodz/PL, <sup>8</sup>Athens/GR, <sup>9</sup>Sofia/BG

**C-869**

**Half-value layer measurement using a radiochromic film for QA and QC**

T. Gotanda<sup>1</sup>, T. Katsuda<sup>2</sup>, R. Gotanda<sup>1</sup>, A. Tabuchi<sup>1</sup>, M. Eguchi<sup>1</sup>, S. Takewa<sup>1</sup>, Y. Takeda<sup>1</sup>; <sup>1</sup>Okayama-city/JP, <sup>2</sup>Himeji-city/JP

**C-870**

**Development and integration of correction methods in a vendor-independent flat-detector CT image reconstruction platform**

Y. Kyriakou, R.M. Lapp, D. Prell, M. Meyer, C. Niebler, W.A. Kalender; *Erlangen/DE*

**C-871**

**Color Doppler twinkling artifact in intrauterine fetal demise**

A. Ozkur, E. Dikensoy, S. Kervancioglu, R. Kervancioglu, S. Inaloz, M. Bayram; *Gaziantep/TR*

**C-872**

**Effect of anode-filter materials on noise equivalent quanta of a computed radiography system for mammography**

M. Buades-Forner, A. Cámara-Turbí, A. González-López, B. Tobarra-González; *El Palmar (Murcia)/ES*

**C-873**

**Needle image plates (NIP) compared to powder image plates (PIP) at same dose in routine digital radiography: A retrospective study**

W. Hey, A. Kleinholz, R. Temmen, W. Kersjes; *Ludwigsburg/DE*

**Radiographers****CT****C-874**

**Cardiac computed tomography with 64-slice technology for the detection of heart diseases: Technical aspects, applications and limitations**

A. Plotas<sup>1</sup>, A.N. Chalazonitis<sup>2</sup>, S. Lachanis<sup>2</sup>, F. Laspas<sup>2</sup>, P. Porfyridis<sup>2</sup>, G. Neofitou<sup>2</sup>, M. Kelogrigoris<sup>2</sup>, N. Ptohis<sup>2</sup>; <sup>1</sup>*Korinthos/GR*, <sup>2</sup>*Athens/GR*

**C-875**

**Clinical values of dose reduction techniques in 64-row MDCT coronary artery**

J. Gao, G. Wang, J. Li, X. Sun, N. Li, W. Zhao, R. Dai; *Beijing/CN*

**C-876**

**Scanning techniques with CT-AEC (step characteristics of CT-AEC and respiration control)**

I. Aizawa, Y. Muramatsu, K. Takahashi, Y. Maie, T. Tanaka; *Chiba/JP*

**C-877**

**Breathhold trial prior to multislice CT coronary angiography to determine optimal scanning parameters**

F. Engelken, M. Dewey; *Berlin/DE*

**C-878**

**Image quality and optimal image reconstruction interval for non-invasive coronary angiography with dual-source CT**

G. Bastarrika<sup>1</sup>, J.C. Pueyo<sup>1</sup>, M. Arraiza<sup>1</sup>, C.N. De Cecco<sup>2</sup>, B. Zudaire<sup>1</sup>, A. Villanueva<sup>1</sup>; <sup>1</sup>*Pamplona/ES*, <sup>2</sup>*Rome/IT*

**Radiographers****MR Imaging****C-879**

**Measuring metastatic liver lesions on MRI examinations: What the radiographer should know**

I. Mokali, M. Mantatzis, K. Amarantidis, D. Theodorakis, S. Voulgaridou, S. Kakoklyris, P.K. Prassopoulos; *Alexandroupolis/GR*

**C-880**

**Tips and tricks for MR arthrography: How dynamic maneuvers can improve diagnosis**

C. Martínez Guillamón, I. Camarasa Fernández, E. Rico Sandoval, C. García Llopis, E. Llopis Sanjuan; *Alzira/ES*

**C-881**

**Breast cancer staging with breast MRI**

I. Camarasa Fernández, E. Rico Sandoval, C. García Llopis, C. Martínez Guillamón, J. Paris Bueno; *Alzira/ES*

**C-882**

**MR angiography of the circle of Willis in the assessment of patients with aneurysms treated with embolization**

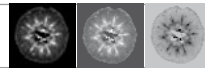
E. Rico Sandoval, C. García Llopis, I. Camarasa Fernández, C. Martínez Guillamón, A. Revert Ventura; *Alzira/ES*

**C-883**

**Lateral position imaging method in lumbar vertebrae MRI examination**

K. Kazama<sup>1</sup>, M. Kimura<sup>2</sup>, M. Tsurumaki<sup>1</sup>, M. Sekiya<sup>2</sup>, D.-Y. Tsai<sup>2</sup>; <sup>1</sup>*Tainai/JP*, <sup>2</sup>*Niigata/JP*





## Radiographers

### Miscellaneous

#### C-884

##### Evidence-based medicine meets radiology

A.N. Chalazonitis<sup>1</sup>, J. Tzovara<sup>1</sup>, G. Tsimitselis<sup>2</sup>, P. Porfyridis<sup>1</sup>, M. Avlianos<sup>1</sup>, E. Sotiropoulou<sup>1</sup>, N. Ptohis<sup>1</sup>, G. Neofitou<sup>1</sup>; <sup>1</sup>Athens/GR, <sup>2</sup>Larissa/GR

#### C-885

##### The extended role of radiographers reporting orbit radiographs for intraocular foreign body in the MRI department of a DGH

O. McDonnell, M. Vickers, A. Carson; *Craigavon/UK*

#### C-886

##### A study of adequacy of completion of radiology request forms

D. Oswal<sup>1</sup>, D. Sapherson<sup>2</sup>, A. Rehman<sup>3</sup>; <sup>1</sup>Leeds/UK, <sup>2</sup>Harrogate/UK, <sup>3</sup>Huddersfield/UK

#### C-887

##### Single-sided reading versus dual-sided reading: Comparison of image quality and radiation dose of two CR systems

H. Qi, W. Qin, S. Song, Y. Zhao; *Jinan/CN*

#### C-888

##### Optimization of anode-filter combinations and tube potentials for digital mammography with matched average glandular dose

C. Kohama<sup>1</sup>, A. Yoshida<sup>2</sup>, Y. Higashida<sup>3</sup>; <sup>1</sup>Hatsukaichi/JP, <sup>2</sup>Mihara/JP, <sup>3</sup>Fukuoka/JP

**Vascular****CT****C-889**

**64-slice CT angiography (CTA) of the thoracic aorta using 'SnapShot Pulse' prospective electrocardiograph (ECG)-triggered scan: Advantage over conventional high-pitch and 'Triple Rule Out' scans**

J. Horiguchi, C. Fujioaka, M. Kiguchi, N. Hirai, N. Matsuura, K. Ito; *Hiroshima/JP*

**C-890**

**Evaluation of arterial dissection using 64-MDCT: A review of common and uncommon imaging characteristics**

G.L. Crane, J.N. Tkacz; *Boston, MA/US*

**C-891**

**MDCT angiography in the preoperative planning of DIEP and SIEA flap breast reconstruction**

J. Pamies Guilabert, P. Braun, V. Ballester Leiva, F. Gomez Muñoz; *Valencia/ES*

**C-892**

**The spectrum of cardiovascular lesions in multitrauma patients**

G. Laguillo, A. Guiles, A. Gelabert, M. Boada, N. Cañete, M. Febrer; *Girona/ES*

**C-893**

**Multi-detector-row CT angiography in the study of inferior vena cava malformations**

L. Saba<sup>1</sup>, C. Urigo<sup>2</sup>, M. Conti<sup>2</sup>, G. Mallarini<sup>1</sup>; <sup>1</sup>*Cagliari/IT*, <sup>2</sup>*Sassari/IT*

**C-894**

**3D multi-detector CT evaluation of acute thoracic aortic syndromes: What the radiologist needs to know**

J.M. Moriarty, D.T. Murphy, L.P. Lawler; *Dublin/IE*

**C-895**

**Acute aortic pathologies: A spectrum of diseases depicted on 64-slice multi-detector row CT**

M. Bertolotto, R. Pizzolato, M. Belgrano, M. Ceschin, M. Doddi, M. Cova; *Trieste/IT*

**C-896**

**Active gastrointestinal bleeding: Spectrum of CT angiography findings and pitfalls**

S. An, W. Lee, J. Chung, J. Park; *Seoul/KR*

**C-897**

**64-row MDCT angiography of the abdominal vessels: Protocols, post-processing and clinical implications**

C.N. De Cecco, P. Paolantonio, F. Iafrate, F. Vecchietti, P. Lucchesi, A. Laghi; *Rome/IT*

**C-898**

**Cardiac arrest: Helical CT findings**

M. Scialpi<sup>1</sup>, L. Volterrani<sup>2</sup>, M.A. Mazzei<sup>2</sup>, F. Mazzei<sup>2</sup>, R. Grassi<sup>3</sup>, A. Rotondo<sup>3</sup>, L. Lupattelli<sup>1</sup>; <sup>1</sup>*Perugia/IT*, <sup>2</sup>*Siena/IT*, <sup>3</sup>*Naples/IT*

**C-899**

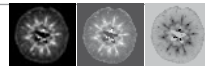
**What every radiologist should know about multi-detector row CT angiographic imaging of peripheral arterial bypass complications**

M. Santoro, R. Iezzi, D. Giancristofaro, V. Pasqua, A.R. Cotroneo, M.L. Storto; *Chieti/IT*

**C-900**

**Multi-detector row CT angiographic imaging in the follow-up of patients who underwent endovascular abdominal aortic aneurysm repair: A pictorial review**

D. Giancristofaro, R. Iezzi, M. Santoro, D. Gabrielli, A.R. Cotroneo, M.L. Storto; *Chieti/IT*



**C-901**

**The accuracy of sixty-four detector row helical CT on the diagnosis of pulmonary embolism: Prospective evaluation of 112 emergency department patients and inpatients in a patient outcome study**

C. Calisir, U.S. Yavas, I.R. Ozkan; *Eskisehir/TR*

**C-902**

**Aortic enhancement at CT angiography: A contrast injection protocol based on patient lean body weight**

Y. Yanaga, K. Awai, T. Nakaura, T. Namimoto, Y. Yamashita; *Kumamoto/JP*

**C-903**

**Initial evaluation of fast switching dual energy scanning in head CT angiography using 40mm coverage volume CT**

K. Sugisawa, Y. Okano, M. Jinzaki, S. Kuribayashi, N. Monden, Y. Imai; *Tokyo/JP*

**C-904**

**64-slice spiral carotid CT angiography using CareDose4D: Effects of current and pitch factor on image quality**

W. Liu, H.D. Xue, Z.Y. Jin; *Beijing/CN*

**C-905**

**Takayasu arteritis: Luminal and mural evaluations of carotid artery with CT angiography**

W. Liu, Z.Y. Jin, H.D. Xue, H. Sun, X. Wang; *Beijing/CN*

**C-906**

**The role of multidetector CT angiography in decision making in severe carotid stenosis**

A. Ben Ely, A. Puzhevsky, A. Bass; *Rishon Le Zion/IL*

**C-907**

**Virtual angiography of arterial disease revisited**

S.V. Bommana<sup>1</sup>, R.S.V. Vadapalli<sup>2</sup>, U.D. Patil<sup>1</sup>, B.Y.T. Arya<sup>1</sup>, R. Hanasoge<sup>1</sup>; <sup>1</sup>Bangalore/IN, <sup>2</sup>Colombo/LK

**Vascular**

**DSA**

**C-908**

**Lower limb venography: The forgotten 'gold standard'**

A. Saini, N. Fotiadis, R. Dourado, F. Ahmad, I. Ahmed, T. Sabharwal, A. Adam; *London/UK*

**C-909**

**Usefulness of 3-dimensional rotational angiography with flat detector in the management of transplanted kidney: Preliminary experience**

A. Ianniello, G. Carrafiello, D. Laganà, D. Santoro, F. Fontana, C. Fugazzola; *Varese/IT*

**Vascular**

**MR**

**C-910**

**Hemangiomas and vascular malformations: A practical approach based on MR findings**

M.E. Nazar, A. Nàpoli, D. Sarroca, C. Morales, H. Di Nunzio, C.H. Bruno; *Buenos Aires/AR*

**C-911**

**Acute aortic dissection: Typical and atypical MRI findings**

A. Buzzi, S. Ballester, C. Dominguez, R.J. de Cabo, F. Arredondo, L. Santamarina; *Buenos Aires/AR*

**C-912****High-resolution MRI of the cervical arterial wall**

C. Oppenheim, D. Naggara, E. Touzé, J.-F. Toussaint, J.-L. Mas, J.-F. Méder; *Paris/FR*

**C-913****Pre-operative assessment of potential, live renal donors: Venous variations as found on contrast-enhanced magnetic resonance angiography**

J.B. Straiton, G. Roditi; *Glasgow/UK*

**C-914****Non-enhanced MR angiography of the pelvic vessels**

T. Koyama<sup>1</sup>, T. Okada<sup>1</sup>, K. Fujimoto<sup>1</sup>, N. Satogami<sup>1</sup>, A. Nakai<sup>1</sup>, A. Ninomiya<sup>2</sup>, S. Sato<sup>2</sup>, K. Togashi<sup>1</sup>; <sup>1</sup>*Kyoto/JP*, <sup>2</sup>*Tokyo/JP*

**C-915****Assessment of dysfunctional hemodialysis access fistula and graft of the upper extremity with high resolution contrast enhanced MR angiography**

A.A.A. Abdel Razek, A. Eltantawy, E. Saad; *Mansoura/EG*

**C-916****MR angiography using 3-Tesla equipment and blood-pool contrast medium for preoperative planning of perforators flaps: Imaging findings from a work in progress**

A. Alonso-Burgos, E. Garcia-Turtor, M. Arraiza, A. Benito, J. Zubieta; *Pamplona/ES*

**C-917****3 Tesla MR angiographic assessment of the artery of Adamkiewicz in the work-up of aortic dissection**

S. Veron-Piot; *Reims/FR*

**C-918****Assessing real-time vascular wall shear stress (WSS) using MRI in vivo for possible evaluation of abdominal aortic aneurysms (AAAs) and atherosclerosis**

S. Amirbekian, R.C. Long Jr., J. Suo, N.G. Willett, W. Taylor, D.P. Giddens, J.N. Oshinski; *Atlanta, GA/US*

**C-919****MR imaging of soft tissue venous malformations**

H. Rajhi, H. Jarraya, A. Salem, S. Mehiri, N. Mnif; *Tunis/TN*

**Vascular****Multimodality****C-920****Radiological features of aortitis**

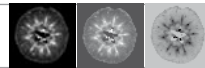
J. Alex<sup>1</sup>, K.T. Tan<sup>2</sup>, I.D. Lyburn<sup>1</sup>, M. Hamilton<sup>2</sup>, P. Wilde<sup>2</sup>, G. McGann<sup>1</sup>; <sup>1</sup>*Cheltenham/UK*, <sup>2</sup>*Bristol/UK*

**C-921****The acute aortic syndromes**

J. Alex<sup>1</sup>, K.T. Tan<sup>2</sup>, G. McGann<sup>1</sup>; <sup>1</sup>*Cheltenham/UK*, <sup>2</sup>*Bristol/UK*

**C-922****Arteriovenous fistulas**

S. Baleato, R. Garcia-Figueiras, J.C. Vilanova, C. Villalva, C. Seoane, J.M. Pumar; *Santiago de Compostela/ES*



**C-923**

**Contrast-enhanced three-dimensional MR angiography of upper limbs: From thoracic inlet to fingertips**

M.E. Nazar, A. Nápoli, P. Batezatti, C. Morales, H. Di Nunzio, C.H. Bruno; *Buenos Aires/AR*

**C-924**

**Development and congenital abnormalities of the portal venous system**

R. Shuto, H. Kiyosue, R. Takaji, S. Tanoue, S. Matsumoto, H. Mori; *Oita/JP*

**C-925**

**Imaging of systemic manifestations of vasculitis**

A. Luna<sup>1</sup>, R. Ribes<sup>2</sup>, S. Rossi<sup>3</sup>, L.C. Da Cruz<sup>4</sup>, I. Rodriguez<sup>1</sup>, E. Ramón<sup>5</sup>; <sup>1</sup>Jaén/ES, <sup>2</sup>Córdoba/ES, <sup>3</sup>Buenos Aires/AR, <sup>4</sup>Rio de Janeiro/BR, <sup>5</sup>Madrid/ES

**C-926**

**Vascular complications of tuberculosis from head to foot**

A. Seith, S. Subramanian, H. Kandpal; *New Delhi/IN*

**C-927**

**Causes of inferior vena cava thrombosis: A pictorial essay**

S.C.P.C. Dias, L.F.P. Gonçalves, H. Torrão, S. Kurochka, C. Leite, V.S. Mendes; *Braga/PT*

**C-928**

**Diagnosis of acute mesenteric ischemia with different radiological modalities: A pictorial review**

M. Reiss-Zimmermann, D. Fritzschn, T. Kahn; *Leipzig/DE*

**C-929**

**Imaging manifestations and pitfalls of cerebral venous ischemia**

A. Hasanefendioglu Bayrak<sup>1</sup>, E. Kara<sup>2</sup>, Y. Özpeynirci<sup>3</sup>, S. Albayram<sup>3</sup>, N. Kocer<sup>3</sup>, C. Isiak<sup>3</sup>; <sup>1</sup>Diyarbakir/TR, <sup>2</sup>Mersin/TR, <sup>3</sup>Istanbul/TR

**C-930**

**Hypertrophied bronchial and non-bronchial systemic arteries in hemoptysis: MDCT and DSA illustration of common variants**

M. Gupta, D.N. Srivastava, A. Seith, R. Gupta; *Delhi/IN*

**C-931**

**Pulmonary arteriovenous malformations: From diagnosis to treatment**

A. Khalil, C. Nedelcu, L. Sahel, J. Korzec, C. Marsault, M.-F. Carette; *Paris/FR*

**C-932**

**Imaging features and differential diagnosis of non-atherosclerotic arterio-occlusive lesions affecting the origins of the great vessel and the head and neck arteries**

P. Govender, I.M. Brennan, H. Delaney, C. Farrelly, J.F. Meaney; *Dublin/IE*

**C-934**

**Multidetector CT vs. color Doppler US for planning breast reconstructive surgery with deep inferior epigastric artery perforators**

A. Cina, L. Barone Adesi, M. Salgarello, L. Bonomo; *Rome/IT*

**C-935**

**64 multidetector computed tomography angiography (64MDCTA) vs. digital subtraction angiography (DSA) in the evaluation of peripheral arteries: Personal experience**

F. Pozzi-Mucelli, S. Cernic, A. Pellegrin, R. Pizzolato, M.A. Cova; *Trieste/IT*

**C-936****Hereditary hemorrhagic telangiectasia (Osler-Rendu-Weber disease): Imaging findings in abdominal involvement**

L. Curvo-Semedo, J. Brito, A. Canelas, P. Belo-Oliveira, A. Gil Agostinho, E. Pinto, V. Carvalho, F. Caseiro-Alves; *Coimbra/PT*

**C-937****Role of duplex US and contrast enhanced MR angiography in the assesment of critical carotid stenosis**

M.A. Gelabert, R. Martinez, A.M. Quiles, M. Boada, E. Rosello, S. Remollo, S. Pedraza, J. Serena; *Girona/ES*

**Vascular****US****C-938****Vascular imaging with contrast-enhanced ultrasound: Abdominal aorta and arteries of the neck and the lower extremities**

H. Moschouris<sup>1</sup>, D. Kalikis<sup>1</sup>, P. Goutzios<sup>2</sup>, D. Matsaidonis<sup>1</sup>; <sup>1</sup>*Piraeus/GR*, <sup>2</sup>*Athens/GR*

**C-939****Ultrasound of vascular anomalies of the skin: A pictorial essay**

C. Whittle, G. Pose, S. Seguel, G. Baldassare, G. Soto Giordani, F. Carreno; *Santiago/CL*

**C-940****Color Doppler ultrasound of renovascular hypertension: How to perform and handle it**

R. Basiliico, M. Romano, G. Patriarca, M. Storto; *Chieti/IT*

**C-941****Volumetric high frequency Doppler ultrasound enables the assessment of early antiangiogenic therapy effects on tumor xenografts in nude mice**

M. Palmowski, M. Jugold, J. Huppert, E.C. Woenne, W. Semmler, F. Kiessling; *Heidelberg/DE*

**C-942****Deep venous thrombosis: Is routine serial ultrasonography necessary?**

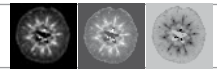
D. Mondal, R.M.S. Carter, J. Woodhouse, J. Amarnath, N. Graham; *Milton Keynes/UK*

**C-943****Contrast enhanced ultrasound (CEUS) in the assessment of carotid plaque vascularization: Correlation with the vessel density in the immunohistochemical study**

R. Gilabert, N. Bargalló, N. Solanes, J. Ramirez, A. Garcia-Criado, V. Riambau; *Barcelona/ES*

**C-944****A comparison of the value of the ultrasound tests assessing the degree of atherosclerosis in diabetic patients**

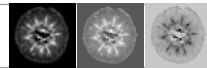
A. Rotkiewicz, P. Przelak, B. Wozniakowski, C. Wolski, L. Stefanczyk; *Lodz/PL*



**A**

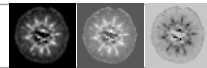
- Abbas Z.: C-541  
 Abd Elghaffar W.: B-530  
 Abd Ellah M.M.H.: B-607  
 Abdalla A.: B-528  
 Abdel Hamid K.: B-701  
 Abdel Razek A.A.A.: B-059, B-102,  
     B-103, B-262, B-387, B-389, B-422,  
     B-522, B-528, B-620, B-644, B-701,  
     B-760, C-018, C-531, C-915  
 Abdel Razek N.: B-760  
 Abdel Razek N.M.: B-164, C-133  
 Abdellaoui A.: C-565, C-659  
 Abdullah B.J.J.: C-309  
 Abe N.: C-560  
 Abe O.: C-796  
 Abe T.: C-543  
 Abegunewardene N.: B-237, B-552  
 Abhyankar-Gupta M.: C-272  
 Abolmaali N.D.: B-637, C-257  
 Abouzied M.: B-177  
 Abramyuk A.: B-637, C-257  
 Abramzón F.: C-829  
 Abro J.A.: B-111, B-116, B-119, B-443  
 Achalandabaso J.: C-639  
 Achenbach S.: A-255, B-075, B-294,  
     B-514, B-659, C-177  
 Achten E.: C-788  
 Acosta Batlle J.: C-637  
 Acosta F.L.: B-023  
 Acosta R.: B-188  
 Acunas G.: B-390  
 Adalet I.: B-390  
 Adam A.: A-097, C-576, C-908  
 Adam E.J.: C-525  
 Adam G.: B-052, B-055, B-057, B-058,  
     B-171, B-232, B-396, B-486, B-487,  
     B-830, C-629  
 Adam R.: C-044  
 Adami L.: C-397  
 Adamonis W.: C-588  
 Adams H.: B-077, C-204  
 Adams J.E.: A-155  
 Adams R.F.: B-168  
 Adamus R.: B-050  
 Adhya S.: C-192  
 Adla T.: B-732  
 Adriaensen M.E.A.P.: C-759  
 Aduna M.: C-465  
 Afonso G.: C-419  
 Agadakos E.: A-373  
 Agarwal A.: C-548  
 Agarwal N.: B-544  
 Agati L.: B-682  
 Agazzi R.: C-557  
 Agildere A.M.: B-385  
 Agrawal S.G.: B-672  
 Aguilar J.A.: C-193, C-488  
 Aguinaldo J.G.S.: B-021, B-234  
 Aguirre I.: C-465, C-608  
 Ahlers C.M.: B-271, B-507  
 Ahlström H.K.: A-437, B-626, D-53  
 Ahmad F.S.: C-576, C-908  
 Ahmed B.A.: C-289  
 Ahmed I.: C-908  
 Aho M.R.: B-327  
 Ahtola E.: C-311  
 Ahuja S.: C-678  
 Ai L.: C-737  
 Aida N.: B-782  
 Aigner F.: C-390  
 Aiken R.: B-214  
 Aime S.: A-034, A-112  
 Aizawa I.: C-845, C-876  
 Akai H.: C-772  
 Akakpo J.-P.: B-152, C-332  
 Akalin T.: B-709  
 Akansel G.: C-755, C-756  
 Akgül E.: C-072  
 Akhan D.: A-058  
 Akhlaghpoor S.: B-502, B-503  
 Akiba H.: C-789  
 Akiyama F.: C-102  
 Akkaraju J.: B-105, C-704  
 Aksungur E.: C-072  
 Alaïmo V.: B-719, C-020, C-176  
 Alam N.S.: C-512  
 Al-Assir I.: B-551  
 Alatas F.: C-265  
 Albahrani S.: C-289  
 Albanese C.V.: B-465  
 Albayram S.: C-929  
 Alberghina F.: B-114, C-165, C-176  
 Alberich-Bayarri A.: C-625  
 Alberola J.M.: C-395  
 Albert F.: D-45  
 Albert J.: B-420  
 Albrecht T.: B-128, B-184, B-190,  
     B-358, B-375  
 Al-Bulushi N.: B-177  
 Albuquerque C.: C-473  
 Alcalá-Galiano A.: B-189, C-666, C-736  
 Aldefeld D.: B-055, B-058  
 Aldrovandi A.: B-735, C-184  
 Alerci M.: B-124  
 Alex J.: C-191, C-920, C-921  
 Alexander R.: B-304  
 Alexopoulou E.: B-331, B-562, C-083,  
     C-231  
 Alfke K.: B-301  
 Alford S.K.: B-820  
 Algeri E.: B-554, B-733, C-153  
 Alguersuari A.: C-826  
 Alguersuari Cabiscol A.: C-352  
 Alibek S.: B-790  
 Alicioglu B.: C-370  
 Alison D.: C-435  
 Alizadeh H.: B-502  
 Alkadhi H.: A-051, A-115, B-450,  
     B-483, B-484, B-822, C-166  
 Alkan A.: C-726  
 Alasia M.: B-329  
 Allegritti M.: B-566, C-555  
 Allen C.: B-032, C-218  
 Allkemper T.: B-412, B-416, B-795  
 Almallah F.: C-297  
 Almarsafawy H.: B-522  
 Almeer H.: B-177  
 Almeida A.: C-005, C-071, C-085  
 Alonso A.: C-568  
 Alonso E.: C-264, C-482  
 Alonso Ferreira V.: B-292  
 Alonso Gamarra E.: C-658  
 Alonso-Burgos A.: C-233, C-258,  
     C-281, C-916  
 Alorainy I.A.: C-501, C-835  
 Alp T.: B-749  
 Alrifai A.: B-177  
 Alsugair A.: B-177  
 Altman A.: B-635  
 Altmeyer P.: B-553  
 Altun E.: B-141  
 Alvarez A.: C-242  
 Álvarez de Eulate V.: C-800  
 Alventosa Fernandez E.: C-630  
 Alves P.: C-335  
 Alves S.: C-128  
 Alvey C.: B-292  
 Alzahrani A.: C-280  
 Amabile N.: C-173





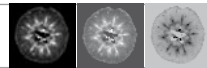
- Amaechi I.: B-159  
Amarantidis K.: C-879  
Amamath J.: C-942  
Amemiya S.: C-772  
Amendoeira I.: C-127  
Ametani M.: C-251  
Amin Spector S.: B-635, B-714  
Amirbekian S.: B-021, B-234, B-649,  
C-918  
Amirbekian V.: B-021, B-234, B-649  
An J.: B-739, C-144  
An J.K.: C-130  
An S.: B-473, C-896  
Anagnostara A.: C-522, C-594  
Anand V.: B-315  
Ananthasivan R.: C-782, C-793  
Anastasiadis A.: C-697  
Anbarasu A.: C-512  
Anders K.: B-075, B-294, B-381,  
B-659, B-797, C-177  
Andersen J.G.: B-536  
Anderson E.M.: B-243, B-365  
Anderson S.E.: A-205, B-575  
Ando M.: C-867  
Ando Y.: C-238  
Andrade J.M.: B-616  
Andree F.: B-171  
Andreini D.: B-062  
Andreu C.: C-273, C-705, C-787  
Andreu J.: C-277  
Andreu M.: C-708  
Andreula C.F.: A-093, A-366  
Anevlavis S.: B-675  
Angel E.: B-295, B-297  
Angeletti M.: B-157, B-498, B-617  
Angelini F.: B-459  
Angelopoulos G.: B-125  
Angeretti M.G.: C-649  
Angileri T.: C-602  
Angle J.F.: B-838  
Anik Y.: C-756  
Ankum W.M.: A-018  
Annertz M.: A-299  
Annoni A.: B-062  
Anselmetti G.C.C.: B-276, B-456,  
B-698  
Anselmino M.: C-457  
Anson K.: C-592  
Antal G.: B-532  
Antequera M.M.: B-430  
Antila M.: C-149  
Antoch G.: B-373, B-380, B-622, B-800  
Antolini L.: B-716, C-571  
Antonopoulos D.: B-331, C-231  
Antunes E.G.: C-609  
Antúnez C.: B-430  
Anzalone N.: A-070, B-415  
Anzidei M.: B-417, B-593, B-597,  
C-181, C-182, C-442, C-463, C-856  
Aoki S.: C-796  
Aoyagi T.: B-591, B-599, C-029, C-416,  
C-427, C-428, C-429, C-489  
Aparisi F.: A-357  
Apesteguía-Ciriza L.: A-312  
Apostolaki E.: C-670  
Apostolakis I.: C-295  
Apostolopoulou S.: C-578, C-597,  
C-598  
Aquerreta D.: C-281  
Aragão M.D.F.V.V.: B-214  
Arai K.: B-388  
Arai Y.: C-411  
Araoka O.: B-759  
Aramburu J.: C-334  
Arana E.: C-506, C-792  
Arana G.: C-608  
Araoz P.A.: B-267, C-143, C-194  
Arcidiacono P.: B-149  
Arcusa A.: B-753  
Arena U.: C-065  
Arenas Jiménez J.: C-235  
Arevalo Galeano N.: C-414, C-476,  
C-533, C-579  
Argento G.: C-403  
Argentos S.: C-231  
Argin M.: B-709  
Argiriou M.: C-567  
Arguís Giménez P.: C-222  
Arguís P.: C-480  
Argyropoulou M.I.: A-372, B-421,  
B-550  
Arias Gonzalez M.: C-093, C-437  
Arias J.: C-233  
Arimura H.: C-735  
Arioli F.: B-687  
Arizono S.: B-143, C-057  
Arjmand Shabestari A.: B-502, B-503  
Arjonilla A.: C-478  
Arkun R.: B-709  
Armuzzi A.: B-726  
Arnáiz García J.: C-691  
Arndt C.: B-052  
Arnold R.: B-521  
Arnoldi A.P.: B-578  
Aronis S.: C-643  
Arora R.: B-256  
Arora S.: B-026  
Arora V.: C-217  
Arraiza M.: C-161, C-233, C-258,  
C-281, C-878, C-916  
Arredondo F.: C-783, C-911  
Arrieta Artieda I.: C-460, C-484  
Arrieta L.: C-434  
Arsaut J.: B-025  
Arslan A.S.: C-755, C-756  
Arslan B.: B-838  
Arslanoglu A.: C-510  
Anthurs O.J.: C-816  
Artsybasheva M.: C-635  
Arya B.Y.T.: C-717, C-732, C-907  
Aschauer M.A.: A-249  
Aschoff A.J.: A-133, B-182, B-184  
Aschoff P.: B-011, B-145, B-351, B-627  
Ashizawa K.: C-227, C-228  
Aslund M.: B-043  
Aso S.: C-392  
Assanti A.P.: B-371  
Astrakas L.G.: B-421, B-550  
Åström G.K.O.: A-446  
Atalar E.: A-220  
Atalar M.H.: C-832  
Atassi B.: B-713  
Athanasίου A.: B-162, B-163, C-094,  
C-665  
Athanasiou C.: C-567  
Athanasopoulou A.C.: C-786  
Athreya S.: B-568  
Atkins M.B.: B-603  
Attenberger U.I.: B-080, B-601, B-643  
Aubard Y.: B-039  
Aubry S.: C-669  
Audet P.: C-032  
Auer D.P.: A-203  
Auffinger S.: C-776  
Auger C.: C-709  
Autier P.: B-152  
Avendano G.M.L.G.: B-837  
Avery G.: C-217  
Avlianos M.: C-287, C-884  
Avni F.E.: A-225, C-837

- Awad S.: C-044  
 Awai K.: C-034, C-040, C-345, C-405, C-833, C-902  
 Aydin E.: B-385  
 Ayer R.: C-205  
 Aytekin C.: B-565  
 Ayuso C.: C-410, C-480  
 Ayuso J.R.: C-410  
 Azarine A.A.: B-324, B-827  
 Aziza R.: B-792  
 Azuma M.: C-306
- B**  
 Babb J.: B-214  
 Babic D.: C-591  
 Babinska A.: C-407  
 Babin P.S.: B-526  
 Bacaicoa C.: C-762, C-766  
 Bachert P.: B-710, C-664  
 Back C.: B-519  
 Badachi Y.: C-332  
 Bader M.: B-489  
 Bader T.R.: B-686  
 Bae K.T.: B-263  
 Baek J.: B-150  
 Bagg S.A.: B-772  
 Bagheri M.H.: B-502, B-503  
 Baghi M.: B-051, B-060, B-180, B-386  
 Baiano M.: B-544  
 Bajic D.: B-801  
 Bakai A.-M.: B-433  
 Bakers F.: B-173  
 Bakir B.: B-390  
 Bakker N.H.: C-200  
 Baladandapani P.: B-807  
 Balanika A.: C-628, C-643, C-701  
 Balaro M.: C-129  
 Balasubramaniam K.: C-574  
 Balconi G.: C-357, C-361, C-382  
 Baldan E.: B-041, D-10  
 Baldassare G.: C-939  
 Baldi S.: B-127  
 Bale R.: B-072, B-625, B-799  
 Baleato S.: C-739, C-775, C-922  
 Balériaux D.: A-397  
 Balestrieri M.: B-544  
 Ballanger P.: B-696  
 Ballarati C.: B-413  
 Ballenilla F.: C-492  
 Ballerini G.: B-062  
 Ballelio L.: B-157, B-498, B-617, B-758  
 Ballester Leiva V.: C-493, C-891  
 Ballester S.: C-911  
 Ballesteros E.: C-570, C-826  
 Ballesteros Gomiz E.: C-208, C-352  
 Ballet S.: B-092  
 Balleyguier C.S.: A-208, A-264  
 Ballicu N.: C-583, C-585, C-590  
 Balliu E.: C-686  
 Baltas C.: C-545, C-628, C-701  
 Baltzer P.A.T.: B-491, B-493, B-496, B-500, B-614, B-619, C-108, C-110, C-112, C-113, C-114, C-115, C-298  
 Balvay D.: B-602  
 Balzano G.: B-149  
 Balzer J.O.: B-338, B-452  
 Bamberger P.: B-049  
 Ban J.E.: C-830  
 Bañales I.: C-682, C-799  
 Banco M.A.: C-602  
 Bandi J.C.: C-584  
 Bandon D.: B-199  
 Bandouraki M.: C-825  
 Bankier A.A.: A-081  
 Bantleon R.: C-613  
 Banyrs R.: B-330, B-555  
 Bapuraj J.R.: B-780  
 Barber I.: C-707  
 Barceló J.: C-686  
 Bardine A.: C-457  
 Barentsz J.O.: A-283, B-741, B-792  
 Bares R.: C-077  
 Bargalló N.: B-803, C-714, C-943  
 Bargellini I.: B-774, C-558  
 Bari E.: C-793  
 Barkhausen J.: B-240, B-258, B-322, B-411, B-418, B-420, B-553, B-558, B-581, B-622, D-72, D-75, D-76  
 Barlas N.B.: C-835  
 Barluenga E.: C-015  
 Barnes D.: C-240  
 Barneveld Binkhuysen F.H.: A-292  
 Baron J.: C-164  
 Baroncini S.: B-527  
 Barone Adesi L.: C-934  
 Baronio M.: C-342  
 Barozzi L.: B-527, C-376  
 Barrett N.K.: B-161  
 Barros D'Sa I.J.: C-308  
 Barros N.: C-121  
 Barrufet Solé M.: C-551, C-559  
 Barta S.: B-833  
 Bartel T.: B-822  
 Bartels-Kortland A.: B-047  
 Barter S.: A-313  
 Barth M.: B-663  
 Bartoli G.: C-552  
 Bartoli J.-M.: C-156, C-173  
 Bartolotta T.V.: B-719, C-020, C-048, C-159, C-421, C-575, C-602  
 Bartolozzi C.: A-300, B-245, B-585, B-774, C-062, C-063, C-097, C-100, C-387, C-457, C-558  
 Bartolucci D.: B-703  
 Barton T.: C-131  
 Bartsch G.: B-607, C-390  
 Bartumeus P.: C-413  
 Basaury M.J.: B-127  
 Basilico R.: B-775, C-940  
 Baski M.: B-016, B-355, B-711  
 Basood M.: B-554, C-153  
 Bass A.: C-906  
 Ba-Ssalamah A.: A-084, B-589, B-598  
 Bassanelli G.: B-687  
 Bassi L.: C-059  
 Basso U.: C-475  
 Bastarrika G.: C-161, C-233, C-242, C-258, C-878  
 Bastati N.: B-598  
 Batakis N.: C-535, C-594  
 Bataszew A.: C-807  
 Batezatti P.: C-923  
 Batista A.: C-180  
 Batista K.: C-464  
 Batra B.: C-548  
 Battaglia V.: C-062, C-063, C-100  
 Battista R.: C-125  
 Battisti S.: B-325  
 Batty R.: B-405  
 Bauer J.S.: B-463, B-466  
 Bauer R.: B-337  
 Bauer R.W.: B-449  
 Baum R.P.: C-611, C-614  
 Baum T.: B-463  
 Baum U.: B-381, B-840  
 Baumann C.: B-274  
 Baumann S.: B-793  
 Baumann T.: B-313, B-398  
 Baumeister R.: B-650



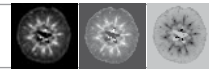
- Baumhauer H.: *B-820*  
Bauner K.U.: *B-559, B-688*  
Bauters W.: *C-788*  
Bautz W.A.: *B-053, B-075, B-294, B-381, B-659, B-790, B-840, C-177, C-321, C-323*  
Baxi A.J.: *C-140*  
Bayanati H.: *B-221*  
Bayram A.: *B-749*  
Bayram M.: *C-871*  
Bazeed M.: *B-530*  
Bazot M.: *B-155*  
Bazzocchi A.: *B-332, B-720*  
Bazzocchi M.: *B-048, B-263, B-287, B-492, B-494, B-544, C-025, C-447*  
Beauchet A.: *B-135*  
Becherer A.: *B-054*  
Becker A.: *B-440*  
Becker C.: *B-014, B-080, B-293, B-439, B-731, B-797*  
Becker C.D.: *A-236*  
Becker C.R.: *A-050, B-440, B-472, B-490, B-518, B-826, D-23*  
Becker D.: *D-26, D-45*  
Becker M.: *A-079*  
Becker W.P.: *B-663*  
Beady P.: *C-500*  
Bedenne L.: *B-335*  
Beeets-Tan R.G.H.: *B-173*  
Beek E.: *A-275*  
Beekman M.: *B-047*  
Beer A.J.: *B-624*  
Beer M.J.: *B-794, B-821, B-824*  
Begemann P.G.: *B-830*  
Beger S.: *B-619, C-108, C-298*  
Behr J.: *B-816*  
Beier A.: *C-109*  
Beigelman-Aubry C.: *A-036, A-398, B-676, C-299*  
Beijerinck D.: *B-047*  
Beirão I.: *C-473*  
Beisigal U.: *B-396*  
Bekiesinska-Figatowska M.: *C-616*  
Belan V.: *C-718*  
Belcari A.: *C-062*  
Belfiore G.: *C-866*  
Belgrano M.: *C-895*  
Bellenberg B.: *C-748*  
Belli G.: *C-065*  
Belli P.: *C-106, C-107*  
Bellia M.: *C-229*  
Bellia V.: *C-229*  
Bellin M.-F.: *B-792, C-044*  
Bello Baez A.: *C-630*  
Bellomia D.: *C-491*  
Bellon E.: *B-045*  
Belloni E.: *B-288, B-687*  
Belohlavek O.: *B-779*  
Belo-Oliveira P.: *C-936*  
Beltrami G.: *B-458*  
Ben Amara F.: *C-513*  
Ben Ely A.: *C-906*  
Ben Hassine A.: *C-618*  
Bendtsen M.: *B-572*  
Benea G.: *C-401*  
Benekos O.: *C-111, C-147*  
Benet F.: *C-506*  
Benítez D.: *C-478*  
Benito A.: *C-916*  
Benjamins E.: *B-292*  
Beomonte Zobel B.: *B-158, B-705*  
Berciano J.A.: *C-656*  
Bercoff J.: *B-163*  
Bérczi V.: *A-168, B-832*  
Beresňák A.: *B-414*  
Bergemann C.: *C-326*  
Berger F.: *A-009, A-405, B-014*  
Berggruen S.: *B-071, B-713*  
Bergmann A.: *C-422*  
Berg-Schlosser F.: *B-452*  
Bergstrøm R.: *B-505*  
Bermudez P.: *C-570*  
Bernabeu Taboada D.: *C-658*  
Bernardo S.: *B-592*  
Bernathova M.: *B-007*  
Bernatik T.: *B-357, D-45*  
Bernsen M.: *A-119*  
Berretta S.: *C-246*  
Berröcal T.: *C-817*  
Bertella E.: *B-062*  
Berthold T.: *B-540*  
Bertini L.: *B-728*  
Bertolani C.: *C-017*  
Bertoletti L.: *B-679, C-247, C-248, C-250*  
Bertolini F.A.: *C-283*  
Bertolini M.: *B-194*  
Bertolotti E.: *C-649*  
Bertolotto M.: *C-376, C-895*  
Bertotto I.: *B-615*  
Besada C.H.: *C-725*  
Besim A.: *A-404*  
Bessho Y.: *C-306*  
Beste C.: *C-748*  
Bethge W.: *C-077, C-487*  
Bettinotti M.: *C-174*  
Beyersdorff D.: *B-743*  
Bezzi M.: *B-561, B-563*  
Bezzon E.: *B-041, D-10*  
Bhandari M.: *C-704*  
Bhandari P.S.: *C-548*  
Bharwani N.: *C-209, C-214, C-329, C-355, C-485, C-525*  
Bhatnagar P.: *C-203*  
Bhatt R.: *B-603*  
Bhattacharya M.: *B-543, B-546*  
Bhide V.M.: *C-398*  
Bhosale P.: *C-452*  
Bianchi F.: *B-009*  
Biçakçı K.: *C-072*  
Bick U.: *A-131, B-043, D-34*  
Bicki J.: *C-734*  
Bicknell C.D.: *B-773*  
Bidault F.: *A-179, C-665*  
Biederer J.: *C-256*  
Bielecen D.: *B-419*  
Biery G.: *B-630*  
Bigall N.: *B-396*  
Bilaniuk L.T.: *B-403, B-783*  
Bilbao J.-I.: *A-054, C-161, C-568*  
Billiard J.-S.: *C-032*  
Billing H.: *C-790*  
Bilodeau M.: *C-032*  
Binaghi S.: *B-784*  
Binokay F.: *C-072*  
Binsler T.: *B-485*  
Bipat S.: *B-017, B-362*  
Biscaglia A.: *C-521*  
Biscaldi E.: *A-349, B-729*  
Bischof Delaloye A.: *A-214*  
Biscoito L.: *A-271*  
Bisdas S.: *B-051, B-060, B-180, B-386, C-185*  
Bisgaard C.: *B-368*  
Bitar R.: *C-091*  
Bitto L.: *B-816*  
Bittsansky M.: *C-647*  
Bitzer M.: *C-022*  
Björkman-Burtscher I.M.: *A-060, A-394*

- Blachar A.: *A-242*  
 Blackmon K.N.: *B-076*  
 Blackstein M.E.: *B-708*  
 Blanco Barrio A.: *C-692*  
 Blanco G.: *C-054, C-604, C-656, C-682*  
 Blanco M.: *C-739, C-775*  
 Blank W.: *B-357, D-45*  
 Blasberg R.G.: *B-024, B-029*  
 Blasco Andaluz J.: *A-187*  
 Bleakney R.R.: *B-708*  
 Bleiberg H.: *B-152*  
 Bley T.A.: *B-313, B-658*  
 Blickman J.G.: *A-073*  
 Bliddal H.: *B-344*  
 Blum A.: *A-028*  
 Blume J.D.: *B-218*  
 Blunt D.: *B-501*  
 Boada M.: *C-409, C-686, C-892, C-937*  
 Boatta E.: *B-564, C-555*  
 Bochmann K.: *B-068*  
 Bock E.: *B-726*  
 Bockisch A.: *B-373, B-380, B-622, B-800*  
 Boddington S.: *B-023*  
 Bodner G.: *B-007*  
 Boehm H.F.: *B-080*  
 Boehm N.: *B-630*  
 Boerger T.: *B-007*  
 Boermeester M.A.: *B-017*  
 Boesch C.: *B-575*  
 Boesen M.: *B-344*  
 Boetes C.: *A-384, A-410, C-105*  
 Boettcher J.: *C-673*  
 Bogaert J.: *A-182, A-389*  
 Bogaert S.: *B-015*  
 Bogner P.: *B-532*  
 Bogner W.: *B-429*  
 Bogoni L.: *B-315, B-476, B-478*  
 Bogorodzki P.: *C-752*  
 Böhm B.: *B-271*  
 Bohndorf K.: *A-400*  
 Boi L.: *B-125*  
 Bokde A.: *C-727, C-745*  
 Bokorov B.: *C-438*  
 Bokou C.: *B-519, C-868*  
 Boljesikova E.: *C-718*  
 Boll D.T.: *C-078, C-079*  
 Bollet M.A.: *C-094*  
 Bolondi L.: *B-720*  
 Bolte H.: *C-256*  
 Bolufer Nadal S.: *C-235*  
 Bolukbasi Y.: *B-709*  
 Bommana S.K.V.: *B-810, C-712, C-717, C-732, C-782, C-907*  
 Bonardel G.: *A-179*  
 Bonatti J.: *B-822*  
 Bondioni M.P.: *C-011, C-046, C-047, C-324*  
 Bonel H.M.: *B-391*  
 Bonetti F.: *B-751*  
 Bonfert M.: *B-781*  
 Bongartz G.: *B-292, B-415, B-419, C-367*  
 Bonini R.H.M.: *B-616*  
 Bonnemain B.: *B-350*  
 Bonnet F.: *B-736, C-393, C-532*  
 Bonnetain F.: *B-335*  
 Bonneville F.: *A-364, B-220, C-724*  
 Bonomo L.: *A-122, B-118, B-272, B-318, B-436, B-441, B-646, B-718, B-731, C-042, C-106, C-107, C-934*  
 Bonvalot S.: *C-665*  
 Bonzano L.: *C-747*  
 Boone D.: *C-431*  
 Boone J.M.: *B-170*  
 Boorsma E.: *B-314*  
 Boraschi P.: *B-585*  
 Borasi G.: *B-194*  
 Borba-Filho P.: *C-316, C-464, C-481*  
 Borglen L.: *C-622*  
 Borges A.: *A-180, C-494, C-505*  
 Borges R.S.: *B-424*  
 Born C.: *B-002, C-681, C-727, C-745*  
 Borny F.L.G.: *B-088*  
 Boronat S.: *C-707*  
 Borruel S.: *B-189, C-538*  
 Borsdorf A.: *B-638*  
 Bos D.: *C-771*  
 Bosch J.: *C-559*  
 Bosemani T.: *B-311*  
 Bosmans H.: *A-062, A-417*  
 Bossola M.: *C-521*  
 Bossuyt P.M.M.: *B-017*  
 Botchorishvili R.: *C-341*  
 Bots M.L.: *B-442*  
 Böttcher J.: *B-341, B-496, B-614, B-619, C-108, C-112, C-115, C-497*  
 Botti A.: *B-194*  
 Bottomley J.R.: *C-070*  
 Boudiaf M.: *C-546*  
 Bouga A.: *C-597, C-598*  
 Boulogianni G.: *C-219*  
 Bourekas E.: *B-664*  
 Bourikas L.: *B-724*  
 Bourke P.: *B-773*  
 Bourkhis S.: *C-513*  
 Bouros D.: *B-675*  
 Bova V.: *C-048*  
 Bowtell R.W.: *A-139*  
 Boyer L.: *C-341*  
 Boyvat F.: *B-565*  
 Bozlar U.: *B-838*  
 Bozzali M.: *B-541*  
 Bozzi E.: *B-245, C-457*  
 Brader P.: *B-024, B-029*  
 Bradley A.J.: *C-402*  
 Bradley K.: *B-365*  
 Brady M.: *A-193, B-365*  
 Brambilla C.: *B-222, B-223*  
 Brambilla P.: *B-544*  
 Brambs H.J.: *B-120*  
 Brambs H.-J.: *B-182*  
 Brancatelli G.: *A-041*  
 Brandão A.: *C-129*  
 Branera J.: *C-570*  
 Brasch R.C.: *B-028, B-612, B-648*  
 Brassel F.: *B-082, B-083*  
 Bratina A.: *B-202*  
 Brauer K.: *C-822*  
 Braun P.: *C-266, C-493, C-891*  
 Bravin A.: *B-633*  
 Bray A.: *C-284*  
 Brea Alvarez B.: *C-499, C-703, C-713*  
 Brealey S.D.: *B-251*  
 Breen D.J.: *C-461*  
 Brehmer M.: *A-360*  
 Breitenseher M.: *A-328*  
 Brell M.: *C-738*  
 Bremer C.: *A-033, A-479, B-022, B-412, B-795, C-610, C-615*  
 Bremerich J.: *A-390, A-476*  
 Bremer-Streck S.: *C-326*  
 Brennan I.M.: *C-500, C-932*  
 Brenner W.: *A-408*  
 Breuckmann F.: *B-240, B-553, B-558*  
 Breuer J.: *B-352*  
 Breyholz H.-J.: *C-615*  
 Brightling C.E.: *C-245*  
 Briley-Saebo K.C.: *B-234*  
 Brito J.: *A-141, C-676, C-936*



- Britton I.: C-260  
Britton P.B.: B-290  
Brix G.: A-454, B-624  
Brklijacic B.: B-482  
Broderick A.M.: C-805  
Brodoefel H.: C-186, C-487  
Broekema A.: C-302, C-312  
Brogoszewska H.: C-616  
Broncano J.: C-233  
Brondani G.: C-447  
Brooks D.J.: A-470  
Brosi P.: C-839  
Brotos O.: C-746  
Broutzos E.: A-048, B-562  
Brown I.: C-205, C-207  
Brown S.: C-525  
Browne A.: C-224  
Browne R.: C-350  
Brozetti S.: B-711  
Bru C.: A-234  
Brückmann H.: B-770  
Bruder H.: B-293, B-654  
Bruder O.: B-322  
Bruegel M.: B-264, B-265  
Bruel J.-M.: A-351  
Brugger P.C.: B-305, B-406, B-407, B-410  
Bruguera J.: C-639  
Bruners P.: B-379  
Bruni A.: C-555  
Brüning R.D.: A-178  
Bruno C.H.: C-910, C-923  
Bruns O.T.: B-396  
Brustia P.: B-123  
Bruzzi J.: C-223, C-224, C-280  
Bryant T.J.C.: C-461  
Brys P.: C-626  
Brzegowy P.: C-769  
Buades-Fornier M.J.: C-872  
Bucek R.A.: B-067  
Bücker A.: B-642  
Buckley O.: A-175, C-815  
Bueno Á.: B-455  
Buerke B.: B-412, B-416, B-795  
Bufi E.: C-106, C-107  
Buhk J.-H.: B-084  
Bukhanov K.: C-092  
Bulgheroni P.: C-649  
Buls N.: C-850  
Bultrini C.: B-210, B-325  
Bulut S.: C-832  
Bulzacchi A.: C-475  
Bunck A.: B-684  
Buñesch L.: C-519  
Bünger C.: B-572  
Burck I.: B-386  
Burg M.: B-684  
Burges A.: C-343  
Burgmans M.: B-828  
Burgstahler C.: C-186  
Burkhard T.: B-236  
Burling D.: B-480  
Burmeister H.P.: B-767, C-673  
Burrill J.: C-540  
Busch H.-P.: A-319  
Busch S.: B-797  
Buschmann E.: C-699  
Büsing K.A.: B-401, B-402, C-814  
Busso M.: C-282  
Bussolino Peretto C.: B-615  
Butts-Pauly K.: B-289, C-684  
Buurman H.: C-104  
Buy X.: A-377, B-278, C-542, C-580, C-621  
Buzzi A.: C-783, C-911  
Bydder M.: C-275  
Byun J.N.: C-145  
Byun J.Y.: C-021, C-380, C-474
- C**  
Cabada T.: C-762, C-766  
Caballero C.: C-762, C-766  
Caballero P.: C-273  
Caborni C.: B-149  
Cáceres J.: A-083, A-244, A-307, C-261  
Cadavid D.: B-807  
Caddeo G.: B-185  
Cademartini F.: A-049, A-181, B-445, B-446, B-447, B-735, C-176, C-183, C-184, D-12  
Cadi M.: B-361  
Cagioli S.: B-613, B-756, C-088, C-101  
Cagnon C.H.: B-295, B-297  
Cahana A.: A-188  
Cahir J.: B-257  
Cai W.: B-364, B-475, B-587  
Caiani E.G.: B-132  
Cakir H.: B-004  
Calabrese F.A.: B-323, B-682, C-146, C-154, C-155  
Calabrese M.: B-494  
Calaf F.: C-519, C-714  
Calaf Forn F.: C-222  
Calandriello L.: B-436  
Calatayud J.: C-798  
Calatayude J.: C-274, C-488  
Calcagno A.: C-341  
Caldeira J.P.A.F.: C-483  
Caldeira P.: C-419  
Calderon E.: C-183  
Calisir C.: C-265, C-901  
Callegari L.: B-460  
Calliada F.: C-043  
Callonnec F.: B-409  
Caltagirone C.: B-541  
Calvo P.: C-392  
Calzado A.: B-292, B-299  
Camara O.: B-491, B-493, B-496, B-500, B-619, C-108, C-110, C-112, C-113, C-114, C-298  
Camara-Baeza M.: C-633  
Camarasa Fernández I.: C-880, C-881, C-882  
Cámara-Turbi A.: C-872  
Camins A.: C-708  
Campagna R.: A-447, C-648, C-683, C-688  
Campanacci D.: B-458  
Campanella D.: B-363, B-698  
Campani D.: C-063  
Campanino P.P.: C-552  
Camplese P.: C-221  
Campos C.: C-331  
Campos Coy M.: B-414  
Campos J.T.: C-399  
Campos M.C.V.: C-121  
Camps-Herrero J.: A-016, A-383, B-495  
Canelas A.: C-201, C-202, C-234, C-936  
Canella C.: C-651  
Cañete N.: C-892  
Canet-Soulas E.: A-118  
Canga Villegas A.: C-691  
Canis M.: C-341  
Cannata D.: B-733, B-823  
Cannizzaro F.: C-048, C-229  
Cano Gimeno J.: B-495  
Caño Gómez A.: B-495  
Cano R.: C-674, C-719, C-778, C-834

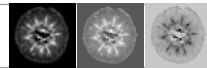
- Canossi B.: *C-125*  
 Cantisani V.: *B-777, C-043*  
 Canu T.: *B-027*  
 Cao K.: *B-595, B-596, C-041*  
 Capanna R.: *B-458*  
 Capello K.: *C-401*  
 Capener D.A.: *B-531*  
 Cappato R.: *B-231*  
 Cappelli A.: *B-332*  
 Cappelli C.: *C-062, C-063*  
 Capron F.: *C-332*  
 Caproni G.: *C-062, C-063*  
 Caproni N.: *C-125*  
 Capuani S.: *B-461, B-669*  
 Capuñay C.M.: *C-174, C-175, C-342, C-372, C-373*  
 Capurro S.: *B-803, C-714*  
 Caramella D.: *A-303, C-062, C-063*  
 Caramella T.: *C-347*  
 Carballido-Gamio J.: *B-463*  
 Carbognin G.: *B-751, C-059*  
 Carbone I.: *B-323, B-554, B-733, B-823, C-153*  
 Carbone S.F.: *B-109*  
 Carcacia Hermilla I.: *C-437*  
 Carcano M.: *B-109*  
 Cardinale L.: *C-282*  
 Cardone G.: *C-357, C-361, C-382*  
 Carette M.-F.: *C-313, C-931*  
 Carlier R.Y.: *B-427*  
 Carlos R.C.: *B-229*  
 Carmi R.: *B-714*  
 Carneiro A.: *C-126, C-127*  
 Carneiro C.: *C-128, C-464, C-481*  
 Carneiro M.: *C-609*  
 Carollo V.: *C-573*  
 Carpanese L.: *B-699*  
 Carpeggiani P.: *B-276*  
 Carpenter A.: *A-113*  
 Carpenter J.S.: *B-628*  
 Carrafiello G.: *C-596, C-606, C-909*  
 Carrara H.H.A.: *B-616*  
 Carrascosa J.: *C-174, C-175, C-372, C-373*  
 Carrascosa P.: *C-174, C-175, C-342, C-372, C-373*  
 Carreno F.: *C-939*  
 Carrero M.: *B-803, C-714*  
 Carreras Aja M.S.: *C-460, C-484*  
 Carrero A.: *B-123*  
 Carro B.: *C-798*  
 Carroll J.D.: *B-640*  
 Carson A.: *C-885*  
 Carter R.E.: *B-119*  
 Carter R.M.S.: *C-942*  
 Carter S.: *C-019, C-358*  
 Carty H.M.L.: *A-391*  
 Caruso S.: *C-573*  
 Carvajal A.: *C-709*  
 Carvalho V.: *C-936*  
 Carvalho L.: *C-234*  
 Casado Lopez A.M.: *C-414*  
 Casarin A.: *C-059*  
 Casciani E.: *B-728*  
 Caseiro-Alves F.: *A-141, A-353, A-443, B-792, C-139, C-150, C-160, C-162, C-201, C-202, C-234, C-617, C-676, C-936*  
 Casile C.: *C-669*  
 Cassagnes L.: *C-341*  
 Cassar-Pullicino V.N.: *A-145, A-257, A-357*  
 Cassart M.: *C-837*  
 Casselman J.W.: *A-452, B-765*  
 Castaing D.: *C-044*  
 Castañer González E.: *C-208*  
 Castaño C.: *C-561*  
 Castellano García M.D.M.: *C-577*  
 Castellon D.: *C-193, C-274, C-488*  
 Castells X.: *C-138*  
 Castillo J.: *A-227*  
 Castro M.: *C-005, C-071, C-530*  
 Catala V.: *C-395*  
 Catalano C.: *A-347, B-016, B-144, B-323, B-355, B-417, B-554, B-593, B-597, B-613, B-679, B-682, B-711, B-718, B-733, B-756, B-777, B-823, C-101, C-146, C-153, C-154, C-155, C-181, C-182, C-247, C-248, C-249, C-250, C-442, C-463, C-856*  
 Catalano O.: *B-359, B-587, C-120, C-862*  
 Cataldi A.: *B-249, B-250*  
 Catrin B.: *B-044*  
 Catro L.: *B-284*  
 Cavallaro A.: *B-790*  
 Cavallo Marincola B.: *B-417, B-593, B-597, C-181, C-182, C-442, C-463, C-856*  
 Celda B.: *C-746*  
 Celik O.: *C-726*  
 Celiktas M.: *C-072*  
 Cellerini M.: *B-458*  
 Cellier C.: *B-409*  
 Cellini L.: *B-615, B-698*  
 Centi N.: *C-009*  
 Cera M.: *B-687*  
 Cercueil J.-P.: *B-335*  
 Cereser L.: *C-025, C-447*  
 Cerezal L.: *B-138*  
 Cernic S.: *C-935*  
 Cerri G.G.: *C-121*  
 Certo M.: *C-274*  
 Certo M.D.G.A.: *C-004, C-472*  
 Ceschin M.: *C-895*  
 Céspedes M.: *C-392*  
 Cestari A.: *C-357, C-361*  
 Cevik I.A.: *C-265*  
 Chaabane S.: *C-618*  
 Chabbert V.: *B-776*  
 Chabchoub H.: *C-313*  
 Chabrot P.: *C-341*  
 Chae E.J.: *B-112, B-228, B-437, B-680*  
 Chagnon S.: *B-135*  
 Chai W.: *C-035*  
 Chai W.-M.: *B-425*  
 Chakeres D.W.: *B-664*  
 Chakrabarti K.: *A-416*  
 Chala L.: *C-121*  
 Chalazonitis A.N.: *C-287, C-295, C-786, C-874, C-884*  
 Chambers J.: *C-526*  
 Chammas M.C.: *C-121*  
 Champfaily M.: *C-435*  
 Champsaur P.: *C-156*  
 Chan C.: *C-320*  
 Chan O.: *C-504*  
 Chan S.: *C-320*  
 Chan T.: *C-320*  
 Chang D.: *B-829*  
 Chang J.M.: *B-285*  
 Chang N.K.: *C-188, C-255*  
 Chang R.-F.: *B-167*  
 Chang Y.H.: *C-830*  
 Chang Y.-W.: *C-831*  
 Chaopathomkul B.: *B-028, B-612*  
 Chapot R.: *A-459*  
 Charisiadi A.: *C-406*  
 Charnsangavej C.: *C-314, C-452*  
 Chartier-Huynh I.: *B-361*



- Chatzimichail K.: B-331  
Chauffert B.: B-335  
Chefdhotel C.: B-145  
Chelli Bouaziz M.: C-618  
Chen D.: B-361  
Chen H.-J.: B-104  
Chen H.-Y.: C-554  
Chen J.: B-300, B-739, C-068, C-144  
Chen J.H.: B-115  
Chen J.-H.: C-554  
Chen K.: B-366, C-760, C-851  
Chen K.-M.: B-425, B-718, B-734  
Chen K.-Y.: C-554  
Chen L.: C-651  
Chen M.: C-774  
Chen N.: B-093, B-205, B-206, B-207  
Chen R.-C.: B-146, C-051  
Chen R.W.: C-742  
Chen T.: B-146  
Chen T.-W.: B-104, B-108, B-110, B-600  
Chen T.-Y.: C-716  
Chen W.-T.: B-146, C-051  
Chen Y.-F.: C-554  
Chen Y.-J.: C-037  
Chen Z.A.: C-728  
Cheng S.: B-281  
Cheng Y.: C-035  
Cherian M.: B-247, C-537  
Cheshire N.J.W.: B-773, C-539, C-540  
Chesson R.A.: B-537  
Chetwood A.: B-404  
Chevallier P.: C-347  
Chevrot A.: C-648, C-688  
Chheang S.: B-214  
Chhem R.: C-650  
Chiang H.-J.: C-554  
Chiara G.: B-276, B-456, B-698  
Chiararamida S.A.: B-449  
Chico M.: C-538  
Chida K.: C-134, C-861  
Chidambaranathan N.: C-795  
Chiesa A.: B-792  
Ching F.: C-320  
Chiras J.: B-220, C-724  
Chiribiri A.: B-329  
Chlapoutakis K.: B-292  
Cho J.H.: C-366  
Cho J.Y.: B-604, C-359  
Cho K.R.: C-132  
Cho K.-S.: C-069  
Cho N.: B-046, B-166, B-283, B-285  
Cho O.-K.: C-064  
Cho Y.E.: C-801  
Choe K.O.: C-187  
Choi B.I.: B-147, B-353, B-582, B-594, C-008, C-453  
Choi B.-I.: B-150  
Choi B.W.: C-187  
Choi D.: B-372, B-377, B-378, C-187, C-425  
Choi D.L.: C-012, C-831  
Choi G.M.: C-808  
Choi H.: B-671  
Choi H.Y.: B-746  
Choi H.-Y.: C-096  
Choi J.-A.: C-661  
Choi J.H.H.: B-470  
Choi J.W.: B-166, C-462  
Choi J.Y.: C-453  
Choi J.-Y.: B-134, C-661  
Choi R.: B-479  
Choi S.: C-188, C-255  
Choi S.I.: C-145  
Choi S.-J.: C-124  
Choi Y.: C-188  
Choi Y.H.: C-253  
Choi Y.S.: B-444  
Choi Y.W.: C-163  
Chojnowski A.: B-257  
Chomiak J.: B-469  
Chong S.: C-118  
Choo K.S.: C-830  
Chorvat M.: C-718  
Chou C.-T.: B-146, C-051  
Chou J.-M.: B-146  
Choudhary S.: C-328  
Choudhury P.: B-432  
Choukroun G.: B-098  
Chourmouzi D.: C-219  
Choy S.: C-320  
Christakis C.: C-406  
Christe A.: B-056  
Christensen A.: C-440  
Christensen D.: B-505  
Christensen S.: B-802  
Christie-Large M.: C-631  
Christofides S.: A-369  
Christoforidis A.: C-825  
Christophe C.: A-371  
Christopher S.: B-168  
Christopoulos G.: B-255  
Chu J.: C-564  
Chung D.-J.: C-562  
Chung D.Y.F.: C-315  
Chung J.-J.: C-023  
Chung J.W.: B-334, B-695, C-896  
Chung M.: C-640  
Chung T.-S.: C-801  
Ciampi Dopazo J.J.: C-794  
Ciano R.: B-544  
Ciccio C.: B-606, B-703  
Ciccio F.: B-621  
Cicero C.: B-586  
Cicorelli A.: B-774  
Cieszanowski A.: A-159  
Ciftci E.: C-755  
Cihak C.: B-510  
Cihangiroglu M.M.: B-749  
Ciliberti M.: C-517  
Cilotti A.: C-097, C-100  
Cimmino M.A.: B-344  
Cina A.: B-646, C-934  
Cinque T.: C-426, C-443  
Ciolina F.: B-554, B-733, B-823, C-153  
Ciolli S.: C-082  
Cioni D.: A-235  
Cioni R.: B-774, C-558  
Cirillo S.: B-456, C-389  
Ciudad Fernandez M.J.: C-414, C-476  
Civitelli F.: B-465  
Clark M.: C-539, C-540  
Clarke T.: B-339  
Clarkson L.M.: B-534  
Clarus D.: B-831  
Claussen C.D.: B-011, B-128, B-145, B-212, B-235, B-239, B-351, B-448, B-557, B-627, C-022, C-077, C-186, C-487, C-613, C-685  
Clément O.: A-230, B-098  
Clemente A.: C-246  
Clements R.: C-381  
Climent V.: B-551  
Clouse M.: C-186  
Coan P.: B-633  
Coche E.E.J.G.: B-196, B-506  
Cochlin D.L.: C-381  
Codella U.: B-279  
Cody D.D.: B-295

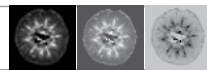
- Cohan R.H.: *B-481*  
 Cohen F.: *C-156, C-173*  
 Cohen M.: *B-808*  
 Cokkinos D.D.: *C-388, C-518*  
 Colagrande S.: *C-339, C-009, C-017, C-065, C-082, C-324*  
 Colao A.: *B-371*  
 Colhoun E.: *C-815*  
 Colin C.: *B-335*  
 Collidge T.: *B-100*  
 Collins D.: *B-040*  
 Colombo N.: *A-092*  
 Colosimo C.: *B-272*  
 Comai A.: *B-360*  
 Combs S.E.: *B-215*  
 Comitis S.: *B-161*  
 Como G.: *B-544*  
 Conde R.: *C-503*  
 Conner T.S.: *C-315*  
 Consoli A.: *C-379, C-386*  
 Conti M.: *C-893*  
 Cook C.K.L.: *C-574*  
 Cook J.-L.: *C-081*  
 Cook S.D.: *B-807*  
 Copin M.-C.: *B-107*  
 Copley S.: *B-673*  
 Copprenath E.M.: *B-383*  
 Coppolino F.: *C-421*  
 Corcione S.: *B-494*  
 Corcoles Padilla J.M.: *C-235*  
 Cordeiro Alves C.: *B-292*  
 Corell B.: *B-793*  
 Cornalba G.: *B-151, B-316, C-747*  
 Cornalba G.P.: *B-231, C-325, C-365*  
 Cornide Santos S.: *C-499, C-713*  
 Corona M.: *B-566, C-555*  
 Coronella M.V.: *C-368, C-448, C-491*  
 Corot C.: *B-021, B-026, B-092, B-420, B-649*  
 Corr C.J.: *C-432*  
 Corradini S.G.: *B-144*  
 Correias J.-M.: *A-425*  
 Correll B.J.: *B-307*  
 Corte T.: *B-814, B-815*  
 Cortés León C.: *B-605*  
 Cortes M.: *C-634*  
 Cortes Vela J.J.: *C-235*  
 Cortez A.: *B-155*  
 Coskun M.: *B-385*  
 Cossu M.C.: *B-585*  
 Costa A.: *C-234*  
 Costa A.C.: *C-066*  
 Costa J.F.: *C-202, C-234*  
 Costa M.: *B-655*  
 Costantini M.: *C-106, C-107*  
 Costantini S.: *B-720*  
 Costaridou L.: *C-117*  
 Costello P.: *B-076, B-111, B-116, B-118, B-119, B-327, B-443, B-449, B-556, B-772*  
 Cotroneo A.R.: *B-775, B-778, C-899, C-900*  
 Couillaud F.: *B-025*  
 Coulden R.: *C-240*  
 Coulomb M.: *B-222, B-223*  
 Coulon P.: *B-676*  
 Coupteau A.: *B-736, C-393*  
 Courcoutsakis N.A.: *C-074, C-697*  
 Coursey R.: *B-520*  
 Courtney H.M.: *B-019*  
 Coutouly X.: *B-696*  
 Couturier J.: *C-665*  
 Cova M.A.: *B-202, B-610, B-719, C-895, C-935*  
 Covelli E.M.: *C-866*  
 Cowan N.C.: *A-440, B-481*  
 Cowper S.E.: *A-107*  
 Cox J.: *B-311*  
 Coyle F.: *B-142*  
 Cozcolluela M.R.: *C-334, C-527*  
 Cracolici E.: *C-159*  
 Cramer M.C.: *B-055, B-058, B-171*  
 Crane G.L.: *C-890*  
 Crane M.: *C-204*  
 Crawford J.: *B-193*  
 Crecco M.: *B-699*  
 Crespi L.: *B-374*  
 Crespo del Pozo J.: *C-682, C-799*  
 Crespo Vallejo E.: *C-533, C-579*  
 Cretier S.: *B-004, B-066*  
 Criado Paredes E.: *C-222*  
 Crocetti L.: *A-086, B-245*  
 Croisille P.: *C-173*  
 Cronin C.: *C-523*  
 Cronin P.: *B-229*  
 Crovetto de la Torre M.A.: *C-515*  
 Cruz A.: *B-138*  
 Cruz F.: *C-001*  
 Cruz I.: *C-749*  
 Cruz J.P.: *C-001*  
 Crystal P.: *C-091, C-092*  
 Cucci E.: *B-154*  
 Cuenod C.A.: *B-602*  
 Cuesta J.: *C-787*  
 Cui Y.: *B-131*  
 Cunha R.G.: *C-085*  
 Cunha T.M.: *C-331, C-335*  
 Cura M.A.: *C-569*  
 Curic J.: *B-482*  
 Curtis J.: *C-272*  
 Curvo-Semedo L.: *A-141, C-936*  
 Cyran C.C.: *B-028, B-612*  
 Cytter-Kuint R.: *C-412*  
 Czekajska-Chehab E.: *C-189, C-190, C-268, C-511, C-734*  
 Czerny C.: *A-043, B-054, B-343*
- D**  
 D'Ambrosio U.: *B-777*  
 da Cruz Jr L.C.H.: *B-308, B-424, C-609, C-733*  
 Da Cruz L.C.: *C-925*  
 Dacher J.-N.: *A-464*  
 Dáez P.: *C-719*  
 Dagiakidi E.: *C-810, C-827, C-836*  
 Dahan H.: *C-546*  
 Dahlman P.: *C-408*  
 Dai J.: *B-548, C-737*  
 Dai R.: *C-875*  
 Daire J.-L.: *B-681*  
 Dake M.D.: *B-838*  
 Dal Col A.: *B-492*  
 Daldrup-Link H.E.: *A-035, B-023, B-026, C-838*  
 Dalielsson M.: *B-043*  
 D'Alimonte P.: *C-125*  
 Dallaire M.-J.: *B-676*  
 Dalmau E.: *B-753*  
 Damasio M.B.: *B-788, C-354*  
 D'Ambrosio I.: *B-498, B-617, B-758*  
 D'Ambrosio P.: *B-435, C-221*  
 D'Ambrosio U.: *C-043*  
 Damiani L.: *C-165, C-176*  
 D'Amico R.: *C-026*  
 Damilakis J.: *A-453, B-292, B-393, B-462, B-464, B-634, B-785, B-787*  
 D'Amore E.: *B-669*  
 D'Andrea M.: *B-371*  
 Daniel B.L.: *B-289*  
 D'Aniello D.: *C-448*





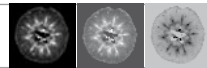
- Daniels D.L.: *B-217*  
Danjoux G.: *C-566*  
Danneskiold-Samsøe B.: *B-344*  
Danza F.M.: *B-726*  
Daoud-Crema M.: *C-640*  
Darai E.: *B-155*  
Darby M.: *C-203*  
Darge K.: *A-322*  
Darnell Martin A.: *C-352*  
Darwent G.: *B-531*  
Dasgeb B.: *C-695*  
Daskalogiannakis G.E.: *C-074, C-697*  
Dastidar P.: *B-467*  
D'Auria M.C.: *B-260*  
David V.: *C-403*  
Davies A.: *C-659*  
Davies A.M.: *A-144, C-631*  
Davies C.: *C-396*  
Davies G.: *C-317, C-396*  
Davis R.: *C-275*  
Davis W.R.: *B-032*  
Dawkins A.A.: *C-455*  
De Amicis R.: *B-210*  
de Bloeme M.: *B-540*  
de Bock G.H.: *B-074, B-226*  
de Bondt R.B.J.: *B-173*  
De Boo D.W.: *B-811*  
de Cabo R.J.: *C-911*  
de Caralt Robira T.M.: *C-222*  
De Cecco C.N.: *B-474, C-293, C-878, C-897*  
De Cobelli F.: *B-027, B-288, B-441, B-687, B-731*  
De Conti G.: *B-459*  
De Felice C.: *B-498, B-758*  
de Feyter P.J.: *B-114, C-164*  
De Filippis G.: *B-016, B-355*  
De Foer B.: *B-765*  
De Franco A.: *B-726*  
de Freitas M.E.T.: *C-733*  
De Freitas R.: *B-178*  
De Gaetano A.: *C-517, C-521*  
De Geyter C.: *B-031*  
de Gregorio Ariza M.A.: *C-551, C-559*  
De Gregorio M.A.: *A-047, B-837*  
de Greiff A.: *B-662*  
De Groot F.: *A-421*  
de Hoop B.: *B-319*  
de Jong J.: *B-399*  
de Jonge G.J.: *B-074, B-077, B-079*  
de Juan C.: *C-410*  
de Juan M.: *C-561*  
De Keyzer F.: *B-172*  
de Koning H.J.: *B-226, B-227, B-282*  
de Koning P.J.H.: *B-078*  
De la Espriella T.: *C-277*  
De La Hoz Rosa J.: *C-235*  
De la Torre P.: *C-395*  
de Lange C.E.: *B-786*  
de Lange F.: *B-639*  
de Lutio di Castelguidone E.: *B-359*  
De Marco M.: *C-859*  
De Meerleer G.O.: *B-742*  
de Mey J.: *A-013, B-488, C-850*  
de Miguel J.: *C-278*  
de Mony C.: *B-186*  
De Pablo A.: *C-215*  
De Pascale A.: *C-282*  
De Ribaupierre S.: *B-784*  
de Roos A.: *A-388, B-299*  
De Schepper A.M.: *C-626*  
De Simone P.: *C-558*  
de Souza J.P.M.: *B-308*  
De Taddeo F.: *B-569*  
de Villiers L.: *B-214*  
De Vitis I.: *B-726*  
de Vos A.M.: *B-442*  
de Vries A.H.: *B-362, B-471*  
de Weert T.T.: *B-004, B-065, B-066, B-186*  
De Wever W.: *A-286*  
De Zordo T.: *B-008, B-256, B-345*  
Deák Á.P.: *C-572*  
Deak P.: *B-513*  
Dean J.C.: *B-169*  
Deblaere K.: *C-788*  
Deffieux T.: *B-163*  
Dehesdin D.: *B-409*  
Dehm K.: *B-333*  
Deistung A.: *B-304*  
Dekan V.S.: *B-216, C-137*  
Deken V.: *B-321, B-812*  
Dekeyzer S.: *C-508, C-777*  
Dekker E.: *B-362, B-471*  
Dekker H.M.: *B-090, B-471*  
Del Borrello M.: *C-246*  
Del Frate C.: *A-382*  
Del Maschio A.: *B-027, B-149, B-288, B-441, B-569, B-687, B-731*  
Del Rio C.: *C-798*  
Del Vescovo R.: *B-158*  
Delabrousse E.: *C-669*  
Delaney H.G.: *C-932, C-369*  
Delanote J.: *B-765*  
Delappe E.: *C-523*  
Deledda A.: *C-401*  
Delgado A.: *C-492, C-824*  
Delgado A.B.: *C-666*  
Delgado Plasencia L.: *C-601*  
Delhayé D.: *B-321*  
Delikanakis N.: *A-226*  
Dell'Aia P.: *B-705*  
Dellamonica P.: *C-389*  
Delorme S.: *C-664*  
Delsanto S.: *B-363*  
Demaerel P.: *A-314*  
DeMarco J.J.: *B-295, B-297*  
DeMarco K.: *B-078*  
Demidova L.V.: *C-348*  
Demiñère C.: *B-025*  
Demirci A.: *C-755, C-756*  
Demshina T.: *C-137*  
Denewar A.: *B-760*  
Denewer A.: *B-389, B-620*  
Denys A.: *C-080, C-556*  
Deprez T.: *B-045*  
Deray G.: *B-098*  
Derchi L.E.: *A-237, C-354*  
Dervenis C.: *C-056*  
Desai N.: *C-502*  
Desai S.R.: *A-038, A-449*  
Desbiolles L.: *B-483*  
Desco M.: *C-749*  
Deshpande S.N.: *B-546*  
Desmond A.: *C-477*  
Desmond P.M.: *B-802*  
Desperramons J.: *B-135*  
Detmar K.: *B-050*  
Detreille R.: *A-028*  
Deuk Lin Choi D.L.C.: *C-049*  
Deurenberg J.: *B-047*  
Deurloo E.E.: *B-811*  
Deva D.P.: *C-197, C-260, C-262, C-699*  
Devaraj A.: *B-814, B-815*  
Devenney-Cakir B.C.: *C-330*  
Devi M.: *B-546*  
Deviggiano A.: *C-174, C-175*  
Deville C.: *B-335*  
Devyatovskaya A.: *C-344*  
Dewailly M.: *B-433*

- Dewey M.: *B-299, B-511, C-877*  
 Dhaliwal L.K.: *B-780*  
 Dhanpalan R.: *C-537*  
 Di Carlo V.: *B-149*  
 di Cesare E.: *B-325*  
 Di Fabio M.V.: *B-210, B-325*  
 Di Giacomo V.: *B-158*  
 Di Giorgio A.: *B-016*  
 Di Leo G.: *B-494, C-325, C-365*  
 di Maggio C.: *B-041, D-10*  
 Di Martino M.: *B-016, B-144, B-355, B-592, B-711, C-386*  
 Di Maurizio M.: *B-157*  
 Di Mizio V.: *B-435, C-221*  
 Di Nunzio H.: *C-910, C-923*  
 Di Nuzzo L.: *C-285*  
 Di Paolo P.L.: *B-417, B-593, B-597, C-181, C-182, C-442, C-463, C-856*  
 Di Pietto F.: *C-627*  
 Di Primio M.: *B-125, B-836*  
 Di Segni E.: *B-829*  
 Di Somma C.: *B-371*  
 Di Terlizzi F.: *C-365*  
 Di Veronica A.: *B-726*  
 Di Vito L.: *B-125, B-129, B-771*  
 Dias K.: *C-129*  
 Dias P.S.: *C-784*  
 Dias S.C.P.C.: *C-066, C-927*  
 Dias-Marra M.: *C-640*  
 Diaz de Otalora Serna A.: *C-460, C-515*  
 Díaz L.: *C-233, C-640*  
 Diaz M.L.: *C-161, C-242*  
 Diaz Romero F.: *C-601*  
 Dichtl W.: *B-740, B-822*  
 Dickson J.: *B-113*  
 Dicle O.: *C-854*  
 Diederich S.: *A-284*  
 Dieguez J.A.: *C-503*  
 Diekhaus G.: *C-291*  
 Diekmann F.: *B-043*  
 Diepolder H.: *B-472*  
 Dietemann J.-L.: *B-278, B-630, C-542, C-580, C-621*  
 Dietrich C.: *B-357*  
 Dietrich C.F.: *D-45*  
 Dietrich O.: *B-573, C-681*  
 Dietzel M.: *B-491, B-493, B-500, C-110, C-113, C-115*  
 Díez I.: *C-409*  
 Díez P.: *B-189, C-674, C-834*  
 Díez Perez de las Vacas I.: *C-637*  
 Diezhandino Gallo-Ruiz M.P.: *B-605*  
 Diezhandino M.P.: *C-215*  
 Dijkshoorn M.L.: *B-063, C-164*  
 Dikensoy E.: *C-871*  
 Dikkers R.: *B-077*  
 Dimceviski G.: *C-422*  
 Dimitriadis A.S.: *C-825*  
 Dimopoulou A.: *B-188*  
 Ding B.: *B-425*  
 Ding K.-C.: *B-146*  
 Dinges J.: *B-573*  
 Dinter D.: *B-401*  
 Dippel D.W.J.: *B-004, B-063, B-065, B-066, B-090, B-186, C-722*  
 Dirbas F.M.: *B-289*  
 Dirisamer A.: *B-686*  
 Dirix P.: *B-172*  
 Dirks K.: *D-45*  
 Distelmaier M.S.: *B-723*  
 Ditsch N.: *C-343*  
 Dixon A.K.: *A-265, B-019*  
 Djuric-Stefanovic A.: *C-490*  
 Dobriserevic B.: *C-490*  
 Dobritz M.: *B-018*  
 Doctor M.: *C-351, C-702*  
 Doda N.: *C-619*  
 Doda S.S.: *A-340, A-343*  
 Doddi M.: *C-895*  
 Doelken M.: *B-429*  
 Doerfler A.: *B-429*  
 Doering J.: *B-235, B-239, B-557*  
 Doesch C.: *B-235*  
 Doffman S.R.: *B-672*  
 Dogan S.: *B-709*  
 Döker R.: *C-148*  
 Dolado Llorente A.: *C-460, C-484*  
 Dolgushin M.B.: *C-740*  
 Doll S.: *B-504*  
 Domene Moros R.: *C-559*  
 Domènech S.: *C-790*  
 Dominelli V.: *B-613, B-756, C-088, C-101*  
 Domingo A.: *C-708*  
 Domingues F.S.: *B-308*  
 Domingues R.C.: *B-308, B-424, C-609, C-733*  
 Dominguez C.: *C-911*  
 Domínguez-Oronoz R.: *C-346, C-690*  
 Donaire A.: *B-803, C-714*  
 Donati F.: *B-585*  
 Donato P.: *C-139, C-150, C-160, C-162*  
 Dondelinger R.F.: *A-396*  
 Dondi M.: *B-432*  
 Dong B.: *B-692*  
 Dong W.: *B-037*  
 Dong Z.: *B-221*  
 Dongelmans D.A.: *B-811*  
 Donnachie N.J.: *B-006*  
 D'Onofrio M.: *B-269, B-360, C-043, C-059*  
 Donohue J.H.: *B-747*  
 Donoso L.: *A-289*  
 Dorigo A.: *B-459*  
 Doriguzzi Breatta A.: *C-552*  
 Döring J.S.: *B-448*  
 Doring T.: *B-424, C-733*  
 Dormont D.: *B-220, C-724*  
 Doros A.: *C-572*  
 Dorrius M.D.: *B-226*  
 Dorweiler B.: *B-122*  
 Dösch C.: *B-448*  
 Dou Y.: *C-770*  
 Douek P.C.: *B-415, D-06, D-49*  
 Doukas M.: *C-406*  
 Durado R.: *C-908*  
 Dousset V.: *A-196*  
 Dowling A.: *C-668*  
 Downes M.: *D-37*  
 Doyle T.C.: *B-019*  
 Draenert F.: *B-383*  
 Dragusin O.: *C-868*  
 Drahanowsky W.: *C-853*  
 Drake W.: *B-142*  
 Drakonaki E.E.: *C-027, C-667, C-670, C-671, C-672*  
 Drakos S.: *B-674*  
 Drapé J.-L.: *A-447, C-648, C-668, C-683, C-688*  
 Drees P.: *B-271, B-273*  
 Drevelegas A.: *C-219*  
 Drewes A.: *C-422*  
 Dromain C.: *A-430, C-665*  
 Drop A.: *B-174, B-176, C-189, C-190, C-268, C-511, C-734*  
 Drossos C.: *B-764*  
 Drouin-Garraud V.: *B-409*  
 Du X.: *B-296, B-618, C-841*  
 Du X.D.: *B-061, B-085, B-187*




- Duarte I.N.: C-483  
Duarte J.A.: C-013  
Dubaniewicz-Wybieralska M.: C-417, C-588  
Düber C.: B-121, B-122, B-271, B-273, B-275, B-507, B-567, C-599  
Dubovetskaya O.B.: C-348  
Ducasse A.: C-532  
Duchonová R.: B-732  
Ducrey G.: C-584  
Dudczak R.: B-054  
Dueber C.: B-552, B-717  
Duetsch S.: B-175  
Duhamel A.: B-321  
Duijm L.E.M.: B-282, B-839  
Dujardin M.I.: B-488  
Dumontier C.: C-668  
Duncan K.A.: C-822  
Dundar M.: B-476, B-478  
Dunjic Kratovac M.: C-045  
Dunn J.: B-161  
Duplaga M.: C-304  
Dupuis P.: B-812  
Duran C.: C-826  
Durando S.: B-250  
Duran-Morell A.: C-633  
Duranti B.: C-009  
Dutta S.: C-232  
Duyck P.: B-015  
Duyndam D.A.C.: C-759  
Dwamena B.A.: B-229  
Dwarkanath R.: C-636  
Dzemeshevich S.L.: C-151
- E**  
Eames J.: B-405  
Eastham J.A.: B-747  
Eberl A.: B-658  
Ebner F.: C-880  
Echávarri C.: C-762  
Echevarria J.J.: C-608  
Eckstein F.: B-463, B-466  
Economides C.: C-111  
Economopoulos N.: C-083, C-147, C-643  
Economou I.: C-825  
Eder R.: C-244  
Edwards A.: C-565  
Edyvean S.: B-515  
Eeg-Olofsson O.: B-801  
Effenberger I.: B-067  
Egger K.: C-776  
Egilmaz H.: C-832  
Eguchi M.: C-869  
Ehiklen N.: B-818  
Ehman R.L.: B-267, C-016  
Ehtuish E.F.: B-195  
Eiber M.: B-265, B-744  
Eichler K.: B-242, B-246, B-336, B-451, B-453, B-457, B-693, B-694, B-700  
Eikefjord E.: A-279  
Eisenblaetter M.: B-022  
Ekberg O.: A-468  
Eker O.: B-025, B-696  
Ekman M.: B-352, D-21  
El Halwagy S.: B-530  
El Koussy M.: B-302  
El Merhi F.: C-569  
El Sayed R.F.M.: A-127  
Elbendary M.: B-262, C-018  
Elhadedy T.: B-102, B-103  
Elia I.: C-180  
Elias, Jr J.: B-616  
Eliat P.-A.: C-032  
Elis J.B.: C-648  
Ell P.: B-113  
Elliott S.T.: D-64, D-66  
Ellis S.: B-672  
Elmas N.: A-124  
Elmongy A.: B-422  
Elmorsi A.: B-102, B-103  
Elshafeai A.: B-102, B-103  
Elsherif A.: B-701  
Eltantawy A.: C-915  
Emmanouil E.: B-331, C-231  
Endler C.: B-402  
Endo K.: B-432  
Endo T.: C-123  
Endozo R.: B-113  
Engel A.: A-242, B-266  
Engelke C.: A-123  
Engelken F.: C-877  
Engelmann M.: B-688  
Engels H.P.: B-018  
English R.E.: B-168  
Engvall J.: C-307  
Ennemoser S.: B-349  
Enrico B.: B-118  
Enriquez G.: C-707  
Entwisle J.: C-240, C-245, C-279  
Eo H.: C-818  
Epelman M.: B-403  
Era S.: C-031  
Eracleous E.: C-111  
Erbel R.: B-553, B-558  
Erbil Y.: B-390  
Erdem G.: C-726  
Erdembileg T.: B-125  
Erden A.: C-010  
Erden I.: C-010  
Erdinc P.: C-832  
Ernst A.S.: B-182  
Ernst O.: C-303  
Ertel D.: B-514  
Ertel S.: B-514  
Ertl-Wagner B.: A-392, B-218, B-781  
Ertürk S.M.: B-721  
Escobar Hoyos A.: B-495  
Escobar M.: C-466  
Eskola H.: B-467  
Esposito A.: B-027, B-687  
Esposito R.: C-026  
Esseridou A.: B-231, B-494  
Essig M.: A-006, B-215, B-307, B-710, B-793, C-664  
Esterhammer R.: B-001, C-776  
Estomell J.: C-180  
Ettorre G.C.: C-368, C-448, C-491, C-809  
Ettorre G.M.: B-699  
Etxebarria N.: C-608  
Eun H.W.: C-012, C-049  
Eustace S.J.: A-267  
Evans N.: C-131  
Evans P.: B-006  
Evanson J.: C-779  
Evers S.: B-412, B-795  
Ezpeleta D.: C-749  
Ezquerro A.I.: C-515  
Ezzat L.: B-164
- F**  
Fabbri G.: C-403  
Fabiano S.: B-771, B-836  
Faccioli N.: B-269, B-360  
Fadееva L.M.: C-740  
Fadlala J.M.: C-551  
Fagadaki I.: C-056  
Faggiano A.: B-371

- Fahy C.: *B-178*  
 Faiella E.: *B-158*  
 Faivre B.: *C-669*  
 Faivre J.-B.: *B-321, B-433, B-438, B-812*  
 Fakhrai N.: *B-598*  
 Falaschi F.: *B-585*  
 Falco J.: *C-570*  
 Falco-Fages J.: *B-570*  
 Falcone B.: *B-048*  
 Fan L.: *B-819*  
 Fandiño E.: *C-392*  
 Fanelli F.: *A-483, B-561, B-563, B-564, B-566, B-777, C-555*  
 Faralli G.: *C-009, C-324*  
 Fargeaudou Y.: *C-546*  
 Farias F.: *C-316, C-464, C-481*  
 Fariás P.E.: *C-584*  
 Farina R.: *C-368, C-448, C-491, C-809*  
 Farinas C.: *C-019, C-358*  
 Farinati F.: *C-475*  
 Farouk A.: *B-387, B-389*  
 Farrell T.: *B-404*  
 Farrelly C.: *C-932*  
 Fasano F.: *B-461, C-595*  
 Fasching A.: *B-091*  
 Faschingbauer R.: *C-390*  
 Fasih N.: *C-328*  
 Fatehi M.: *B-502, B-503*  
 Fatsi A.: *C-287*  
 Fatterpekar G.: *B-214*  
 Faul C.: *C-487*  
 Faulkner K.: *A-367, C-868*  
 Fauser C.: *B-175*  
 Faust A.: *C-615*  
 Fausto A.: *B-494*  
 Fava C.: *B-213, B-249, B-250, B-329, C-282*  
 Faverly D.R.G.: *A-057*  
 Fayad L.M.: *C-695*  
 Fayad Z.A.: *A-232, B-021, B-234, B-649*  
 Fayault A.: *D-46*  
 Fazakas J.: *C-572*  
 Fazi M.: *C-017*  
 Fazio F.: *B-716, C-571*  
 Feakins R.: *B-142*  
 Febreer M.: *C-409, C-892*  
 Fedele F.: *B-682*  
 Fedele I.: *B-288*  
 Fedele L.: *B-151*  
 Fedeli G.: *B-726*  
 Feger J.: *C-109*  
 Fehérvári I.: *C-572*  
 Felfernig M.: *B-007*  
 Felício O.: *B-653*  
 Feliu E.: *B-551, B-560*  
 Félix A.: *C-331, C-335*  
 Felix L.: *B-222, B-223*  
 Fenchel M.: *B-235, B-239, B-448, B-557*  
 Feng F.: *B-070*  
 Feng X.: *B-545, C-728*  
 Feng Y.: *C-770*  
 Fenlon H.: *A-332*  
 Feragalli B.: *B-435*  
 Ferda J.: *B-609, B-725*  
 Fernandez A.: *C-055*  
 Fernandez Del Castillo Ascanio M.: *C-630*  
 Fernández Echevarría M.A.: *C-657*  
 Fernández Flórez A.: *C-682, C-799*  
 Fernandez Fresno L.: *C-705, C-787*  
 Fernandez G.: *C-193*  
 Fernandez Morales L.A.: *B-753*  
 Fernandez S.: *B-753*  
 Fernandez-Capitán C.: *C-264*  
 Fernández-Cuadrado J.: *C-803*  
 Fernández-Gil M.A.: *C-785*  
 Fernandez-Villa T.: *C-639*  
 Ferone D.: *B-009*  
 Ferrão A.: *C-128*  
 Ferrari R.: *B-474, C-024, C-293, C-339, C-855*  
 Ferreira A.M.: *B-827*  
 Ferreira M.J.: *C-150, C-160*  
 Ferrer F.: *C-138*  
 Ferrero S.: *B-729*  
 Ferretti G.: *A-037, B-222, B-223*  
 Ferriere J.M.: *B-696*  
 Fettich J.: *B-432*  
 Feuchtner G.: *A-233, B-008, B-256, B-345, B-686, B-740, B-822*  
 Feuerlein S.: *B-120, C-169*  
 Fewins H.: *C-272*  
 Feydy A.: *A-447, C-648, C-668, C-683, C-688*  
 Feygin T.: *B-403, B-783*  
 Fierlbeck G.: *C-685*  
 Figueres G.: *C-413*  
 Filidoro L.: *B-578*  
 Filippone A.: *C-046*  
 Filippousis P.: *C-578, C-597, C-598*  
 Filograna E.: *C-042*  
 Fink C.: *B-080, B-439, B-518, B-816*  
 Fink M.: *B-163*  
 Fiocchi F.: *C-026*  
 Firat A.K.: *C-726*  
 Firat Z.: *B-749*  
 Fischbach R.: *B-684*  
 Fischer M.: *C-748*  
 Fischer T.: *A-128*  
 Fisher D.: *C-412*  
 Fishman E.K.: *D-35, D-38*  
 Flatz W.: *B-781*  
 Flauaus A.: *B-443*  
 Fleischmann D.: *A-004*  
 Flevari P.: *C-147*  
 Flodmark O.: *C-753*  
 Floemer F.: *B-408*  
 Flohr T.G.: *B-293, B-395, B-438, B-556, B-638, B-654*  
 Flor N.: *B-316*  
 Flórez N.: *C-792*  
 Floriani I.: *B-441, B-731*  
 Flors L.: *C-413*  
 Flöry D.: *B-754*  
 Fockens P.: *B-362, B-471*  
 Fodor S.: *B-255*  
 Fodinger A.: *C-244*  
 Fogliata A.: *B-124*  
 Fokin V.A.: *B-216, C-099*  
 Fong Y.: *B-024, B-029*  
 Fonseca I.: *C-494*  
 Fonseca-Santos J.: *A-321, C-823*  
 Font J.: *B-753*  
 Fontan C.: *C-464*  
 Fontana F.: *C-596, C-909*  
 Fontanilla Echeveste T.: *B-605*  
 Fonteyne V.: *B-742*  
 Foord K.: *C-192*  
 Foon D.H.: *B-538*  
 Forment Navarro M.: *B-495*  
 Formenti A.: *B-062*  
 Fornari M.: *B-132*  
 Forner J.: *C-792*  
 Forrai G.: *A-102*  
 Forsting M.: *A-171, B-373, B-380, B-661, B-662, B-663, B-668, B-791, B-800, C-581*  
 Forstner R.: *A-263*



- Fortuño J.R.: C-570  
Fossaceca R.: B-123  
Foster G.R.: B-142  
Foti P.V.: C-368, C-448, C-491, C-809  
Fotiadis N.: C-576, C-908  
Foufa K.: C-083  
Fournier L.S.: B-602  
Fournol M.: C-347  
Fourquet A.: C-094  
Fowkes M.: B-214  
Fracheboud J.: B-282  
Fraedrich G.: B-001  
Fraga P.: C-215, C-278, C-434  
Fragasso G.: B-687  
Fraile Moreno E.: B-292  
Fraïoli F.: B-679, C-247, C-248, C-249, C-250  
Frake B.: B-303  
Franc B.L.: C-838  
França M.: C-073, C-216, C-274  
Frances C.: B-098  
Francesca F.: C-387  
Franceschelli G.: B-151  
Francesco F.: C-463  
Francica G.: C-036  
Francioso A.: B-157, B-498, B-617  
Franco A.: C-478  
Francone M.: B-323, B-682, C-146, C-154, C-155  
Fraeliel T.: B-743  
Frank J.: B-451, B-457  
Frank R.: B-510, C-244  
Franz W.: B-688  
Franzius C.: B-590  
Frascheri L.: C-709  
Fraser R.: B-404  
Frauenfelder T.: B-483, B-484  
Frauscher F.: B-607, C-390, D-39  
Freeman A.H.: A-399, B-019  
Frei K.A.: B-391  
Freiberg C.: B-619, C-108, C-298  
Freitas M.: B-653  
Freitas V.: C-129  
Freling N.J.: B-811  
Frenzel T.: B-094, B-095, B-096  
Frenicks B.: B-358, B-375  
Freschi M.: C-382  
Freund M.C.: B-230, B-348  
Frey D.G.: B-111, B-515  
Frey U.: B-068  
Friebe M.: B-190  
Friedrich G.: B-740  
Friedrich K.M.: B-579, B-580  
Friedrich P.: B-182  
Friedrich-Rust M.: D-45  
Fries P.: B-642  
Friess H.: B-583  
Frija G.: B-602  
Frija J.: A-285  
Frijns J.H.M.: B-762  
Frittoli B.: C-011, C-046  
Fritz J.: C-685  
Fritzsich D.: C-928  
Froehlich J.: B-350  
Froehner S.: B-255  
Fröhlich J.M.: B-031, B-721  
Frøkjær J.B.: C-422  
Frontino G.: B-151  
Frota F.D.: C-001  
Frulio N.: B-025  
Frydrychova M.: B-469  
Frydrychowicz A.: B-658  
Fu Y.: B-028, B-612, B-648  
Fuchs H.: B-274  
Fuchsjäger M.: B-754  
Fuchsjäger M.H.: A-075, A-411, B-747  
Fuda K.: C-861  
Fuentes L.J.: B-430  
Fuerst D.: B-165  
Fuerxer F.: A-478  
Fugazzola C.: B-460, C-596, C-606, C-649, C-909  
Fujii M.: B-106  
Fujii S.: C-338, C-495  
Fujimoto K.: C-336, C-914  
Fujimoto T.: C-050, C-458  
Fujimura I.: C-680  
Fujimura M.: C-170, C-858  
Fujimura Y.: C-087  
Fujinaga Y.: C-052  
Fujioaka C.: C-840, C-889  
Fujisawa K.: C-134  
Fujita H.: C-123, C-306  
Fujita S.: C-039, C-050, C-458  
Fujiwara A.: C-846  
Fujiwara Y.: C-102  
Fukatsu H.: C-514  
Fukuda K.: C-028  
Fukuda T.: B-064, B-081  
Fukunari N.: B-388  
Fukuoka D.: C-123  
Fukutomi T.: B-759  
Funabashi N.: C-171  
Funakoshi N.: B-342  
Funama Y.: C-833  
Funes J.: C-725  
Fung G.: B-049  
Fung T.: C-320  
Furfaro D.: C-449  
Furlan A.: B-263, C-025, C-447  
Furtado A.: C-013  
Furukawa A.: C-086, C-563  
Furukawa H.: C-007  
Furukawa T.: C-087  
Furuya K.: C-433  
Fusaro M.: B-445, B-446, B-447, B-735, C-183, C-184, D-12  
Futami S.: C-039  
Fuwa S.: C-327  
Fyles A.: B-038
- ## G
- Gaa J.: A-354, B-175, B-264, B-265, B-744  
Gaballa G.: B-522, B-620  
Gabata T.: C-006  
Gabl M.: B-256  
Gabr W.: B-422  
Gabriel M.: B-799  
Gabrielli D.: B-778, C-900  
Gada V.: B-161  
Gadahadh R.: C-204, C-317, C-396, C-432  
Gadano A.: C-584  
Gaddino P.O.: C-753  
Gaemperli O.: B-450  
Gaffi M.: C-397  
Gafoor A.: C-659  
Gaia G.: C-341  
Gajda M.: B-491, B-493, B-496, B-500, B-619, C-108, C-110, C-112, C-113, C-114, C-298  
Gajewicz W.: C-757  
Gakis M.: C-333  
Galanaud D.: C-724  
Galanski M.: C-148, C-291, C-544  
Galati F.: B-711  
Galea N.: B-554, B-733, B-823, C-153  
Galia M.: C-020, C-048, C-159, C-421, C-450, C-575

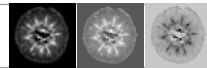
- Galid A.: *B-611*
- Galindo A.: *C-812*
- Gallardo Cistare X.: *C-208*
- Gallardo E.: *C-656, C-657*
- Gallardo-Madueño G.: *C-264, C-804*
- Gallego C.: *C-812, C-824*
- Gallego M.C.: *C-834*
- Gallego M.S.: *C-196*
- Galli S.: *B-062*
- Gallizioli M.: *C-449*
- Gallo T.M.: *B-363, C-389*
- Gallot D.: *C-341*
- Gallucci M.: *A-195, B-210, C-595*
- Galluzzo A.: *C-020*
- Gama C.: *B-655*
- Gamanagatti S.: *C-541*
- Gambino O.: *C-450*
- Gamboa F.: *C-202*
- Gan S.M.: *B-802*
- Ganau Macias S.: *B-162, B-753*
- Ganci G.: *C-448*
- Gandini G.: *C-552*
- Gandini R.: *B-125, B-129, B-771, B-836*
- Gandolfo N.M.: *B-033*
- Gangi A.: *A-136, A-375, A-377, B-278, C-542, C-580, C-621*
- Ganter C.: *B-264, B-624, B-744*
- Gao B.: *B-428*
- Gao J.: *C-844, C-875*
- Gao K.: *C-232*
- Gao Y.: *B-692*
- Gao Y.G.: *B-061, B-085, B-187*
- Garberoglio R.: *B-371*
- Garbin G.: *B-202*
- García A.: *C-346, C-656*
- García A.I.: *C-687*
- García Barredo R.: *C-691*
- García Bolado A.: *C-691*
- García C.: *C-538, C-561*
- García de Vicente A.: *C-528, C-637*
- García del Barrio L.: *C-233*
- García del Salto L.: *C-528, C-637*
- García J.: *B-640*
- García Llopis C.: *C-880, C-881, C-882*
- García M.J.: *C-174*
- García Marco J.M.: *C-235*
- García Miguel P.: *C-803*
- García Mónaco R.: *C-584, C-725, C-829*
- García O.: *C-410*
- García Roch C.: *C-278, C-434, C-499, C-713*
- García Santos J.M.: *B-430*
- García V.: *C-749*
- García-Allut A.: *C-775*
- García-Alonso I.: *C-608*
- García-Barredo R.: *C-656*
- García-Bogalo R.: *C-666*
- García-Carbonell M.: *B-560*
- García-Criado A.: *C-943*
- García-Figueiras R.: *C-922*
- García-Hidalgo E.: *B-189, C-538*
- García-Hidalgo M.I.: *C-392*
- García-Honrubia A.: *B-560*
- García-Martí G.: *C-750*
- García-Peña M.P.: *A-320*
- García-Roch C.: *C-215*
- García-Turtur E.: *C-916*
- Garg P.: *C-541*
- Garganese G.: *B-154*
- Garlaschi G.: *B-137, B-259, B-260*
- Garofalo G.: *B-249, B-250, C-282*
- Garrastachu P.: *C-568*
- Garrido Carrasco M.S.S.: *C-630*
- Garrido G.: *C-690, C-709*
- Garrigoux P.: *B-827*
- Gaser A.: *C-783*
- Gaspar T.: *A-241*
- Gasparetto E.L.: *B-308, B-424, C-609, C-733*
- Gaspari E.: *B-836*
- Gat A.: *B-757, C-103*
- Gaubert J.-Y.: *C-156*
- Gavrilov M.: *C-773*
- Gawaz M.: *B-235*
- Gayed W.H.: *B-608*
- Gazhonova V.: *B-748*
- Gazhonova V.V.: *C-344*
- Gazis A.: *B-700*
- Gazzera C.: *C-552*
- Gazzo P.: *B-033*
- Gedroyc W.M.W.: *A-098, D-51*
- Géhanne C.: *C-837*
- Geiger M.: *B-053*
- Geisbuesch S.: *B-472*
- Geisthoff U.W.: *B-642*
- Gelabert A.: *C-409, C-686, C-892*
- Gelabert M.A.: *C-937*
- Geleijns J.: *B-292, B-299, B-511, B-762*
- Gelin G.: *B-139*
- Gendron J.: *B-793*
- Genestie C.: *C-332*
- Gen D.: *C-728*
- Gennaro G.: *B-041, D-10*
- Gennisson J.-L.: *B-163*
- Genovese E.: *B-460*
- Genovese E.A.: *C-649*
- Geracimos R.T.: *B-768*
- Gerard P.: *C-695*
- Gerediaga G.: *C-473*
- Gerhards H.: *B-068*
- Germitsen F.: *C-104*
- Gerson P.: *A-423*
- Gerukis T.: *C-729*
- Geusau A.: *B-099*
- Ghai S.: *C-553*
- Ghandi A.: *C-722*
- Ghaye B.: *A-170*
- Ghekiera J.: *B-765*
- Ghiatas A.: *C-333*
- Giaconi C.: *C-100*
- Giampalma E.: *B-332*
- Giancristofaro D.: *B-778, C-899, C-900*
- Giannakopoulou G.P.: *C-089*
- Giannelli M.: *C-097*
- Gibbs R.: *C-539, C-540*
- Gibbs R.G.J.: *B-773*
- Gibo M.: *C-547*
- Gibson D.: *B-673*
- Giddens D.P.: *C-918*
- Gielen J.L.M.A.: *B-005*
- Giesel F.L.: *B-073, B-307, B-504, B-677, B-793*
- Gigante A.: *C-632*
- Gigauri K.: *C-014*
- Giglio M.: *B-656*
- Gigoni R.: *B-585*
- Gil Agostinho A.: *C-936*
- Gil B.: *C-568*
- Gil Z.: *B-024*
- Gilabert R.: *C-519, C-943*
- Gilbert F.J.: *A-311, B-034*
- Gilbert G.E.: *B-119*
- Gillams A.R.: *B-243*
- Gimeno M.J.: *C-798*
- Gimson A.E.: *C-003*
- Giovagnoni A.: *C-632*
- Girardi V.: *B-751*
- Giometti R.: *B-263, C-025, C-447*



- Gispert S.: C-346  
Gispert-Herrero S.: C-690  
Giubilei F.: B-541  
Giungi S.: C-517  
Giusti P.: C-457  
Giusti S.: C-387, C-457  
Gizewski E.R.: B-662, B-663, B-668  
Gjerde M.: C-307  
Glasberg S.: B-291  
Glaser C.: A-143, A-401, B-277,  
B-346, B-573, B-578, B-601, B-633,  
B-645, B-650  
Gleeson F.: A-379, B-365  
Glikstein R.S.: C-507  
Glockner J.F.: B-267  
Glodny B.: B-348, C-360  
Glomset O.: C-852  
Glowacki J.: A-475  
Glynn-Jones R.: C-436  
Glynos M.: A-335  
Gned D.: B-213  
Göbel G.: B-607  
Godbole K.: C-398  
Goebel G.: C-776  
Goeke B.: B-472  
Goh P.S.: C-524  
Goh T.: B-509  
Goh V.J.: B-113, C-436  
Gohli P.: B-637  
Goitein O.: B-829  
Göktay A.Y.: C-854  
Golan O.: B-757, C-103  
Golano P.: C-639  
Golash A.: C-353  
Goldberg S.N.: B-603  
Goldin J.G.: B-295, B-297  
Golding S.J.: A-061, B-292  
Goldsby R.E.: C-838  
Goldsmid A.: C-174  
Goldstein M.: C-075, C-197, C-262,  
C-275  
Goldstein M.A.: C-353  
Goldstraw E.: C-525  
Goldstraw E.J.: C-214, C-485  
Golebiowski M.: B-253  
Golemati S.: C-089  
Golfieri R.: B-332, B-720  
Göltz P.: B-622  
Gollub F.: C-526  
Gomes M.C.T.: C-213, C-216  
Gomes T.: B-651  
Gomez A.C.: C-816  
Gómez H.: C-334  
Gomez Muñoz F.: C-493, C-891  
Gómez-Ansón B.: A-414  
Gomi N.: C-102  
Gomi T.: C-767  
Gonçalves B.: C-617  
Gonçalves J.: C-126, C-127, C-399,  
C-797  
Gonçalves L.F.P.: C-066, C-927  
Gong H.: C-035  
González F.: C-054, C-055  
González García I.: C-601  
Gonzalez Gonzalez M.C.C.: C-630  
González Hernández C.: B-605  
Gonzalez M.L.: C-811  
González Mandly A.: C-682, C-800  
Gonzalez Ortiz S.: C-687  
Gonzalez P.: C-736  
Gonzalez S.: B-803  
González Sala J.L.: C-352  
González-Carrillo J.: B-551, B-560  
González-López A.: C-872  
Goo H.W.: B-680  
Goo J.M.: B-225, B-671, C-220  
Goode A.: C-550  
Goodfellow T.: C-308  
Gorenflo M.: B-521  
Görg C.: C-283  
Görnicke S.L.: B-420  
Gorleer K.: C-624  
Gorna R.: C-109  
Górska-Chrzastek M.: C-757  
Goshen L.: B-714  
Gossrau P.: B-052  
Gotanda R.: C-869  
Gotanda T.: C-869  
Goto K.: B-310  
Göttinger P.: B-589  
Gould R.S.: B-516  
Gouliamos A.: B-331, B-562, C-083,  
C-147, C-231, C-628, C-643, C-701  
Gouliamos A.D.: C-786  
Gourtsyianni S.: B-724  
Gourtsyiannis N.: A-209, A-350,  
B-192, B-462, B-464, B-561, B-563,  
B-634, B-724, B-785, B-787, C-027,  
C-667, C-670, C-671, C-672  
Goutzios P.: C-377, C-938  
Gouw C.I.B.F.: B-362  
Gouya L.: B-135  
Govaert P.P.: C-820  
Govaender P.: C-500, C-932  
Gowda R.: B-810  
Goyal N.: C-131, C-381, C-468, C-678  
Graca B.: C-139, C-150, C-162, C-201,  
C-202, C-617, C-676  
Graessner J.: B-052, B-057, B-232  
Graham N.: C-315, C-942  
Graif M.: A-240  
Grammatikakis J.: B-724  
Grana Lopez L.: C-414, C-476  
Granberg S.: B-152  
Granell E.: C-561  
Gras F.: C-136  
Graser A.: A-105, B-472, B-490, B-518  
Grass M.: B-640  
Grassedonio E.: C-020, C-159, C-421  
Grässel D.: C-115  
Grassi R.: C-898  
Grasso R.F.: B-158, B-705  
Graumann B.: C-148  
Gravanis M.: C-522, C-594  
Gravano M.: B-033  
Grazhdani H.: B-554, B-733, B-823,  
C-153  
Graziani R.: B-586, B-588  
Grazioli L.: B-352, B-413, B-718,  
C-011, C-017, C-046, C-047, C-324  
Greco Crasto S.: B-213  
Greco P.: C-246  
Gredilla Molinero J.: C-414, C-533, C-579  
Greenhalgh R.: B-480  
Gregersen H.: C-422  
Gregersen H.E.: B-508  
Greil G.F.: B-557  
Greiner A.: B-001  
Greis C.: B-357, D-45  
Grelot M.: B-519  
Grenier N.: A-169, B-025, B-696  
Grenier P.: B-152, B-361, B-676,  
C-299, C-332  
Grenier P.A.: A-148, A-212  
Greuter M.J.W.: B-392  
Gridelli B.: C-573  
Grieve F.: C-424  
Griffiths P.D.: B-328, B-405, B-531  
Grillo G.: B-259  
Grimm F.: B-239

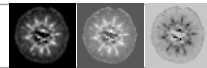
- Grimm J.: *B-029*  
 Gritzmann N.: *A-309*  
 Grivé E.: *C-790*  
 Groen H.: *B-066*  
 Groen J.M.: *B-392*  
 Groenewoud J.H.: *B-282*  
 Groves A.: *B-113*  
 Gruber H.: *C-655*  
 Gruber J.: *B-345*  
 Gruber M.: *B-636*  
 Gruber S.: *B-429*  
 Gruber T.: *B-338*  
 Grubnic S.: *C-209, C-214, C-485*  
 Grudzenski S.: *C-323*  
 Gruenig E.: *B-818*  
 Grunewald R.A.: *B-531*  
 Grunwald I.G.: *B-834, B-835*  
 Gruszczynska K.: *A-393, B-114, C-164*  
 Grützmann R.: *B-266*  
 Grzelak P.: *B-647, C-757, C-944*  
 Grzycka-Kowalczyk L.: *B-174*  
 Gschwend S.: *B-352*  
 Gstöttner W.: *A-450*  
 Gu T.: *B-211*  
 Gu Y.: *B-179*  
 Gualdi G.: *B-728*  
 Guan L.: *C-743*  
 Guaraldi G.: *C-026*  
 Guasch I.: *C-067*  
 Guazzoni G.: *C-357, C-361, C-382*  
 Gubello T.: *B-269*  
 Gudinchet F.: *B-784*  
 Gudmundsen T.E.: *C-622*  
 Guedez M.-T.: *B-138*  
 Guenther R.W.: *B-379*  
 Guerini H.: *A-447, C-648, C-668, C-683, C-688*  
 Guermazi A.: *C-640*  
 Guerrero Martínez G.: *C-785*  
 Guerrisi A.: *B-016, B-144, B-355, B-711*  
 Guglani B.: *C-711, C-715*  
 Guglielmi G.: *A-154*  
 Guichard J.-P.: *C-534*  
 Guidi L.: *B-726*  
 Guiducci F.: *B-774*  
 Guimarães A.: *C-128*  
 Guimarães L.: *C-399, C-689*  
 Guimarães S.: *C-127*  
 Guiu B.: *B-335*  
 Guiu S.: *B-335*  
 Gulati G.S.: *C-933*  
 Gulleroglu B.: *C-756*  
 Gullien R.: *B-536*  
 Gümüş B.: *B-565*  
 Gunatunga I.P.: *C-204, C-317, C-396, C-678*  
 Günsilius E.: *B-072*  
 Guntern D.: *C-080*  
 Günther R.W.: *B-020, B-130, B-570, B-723, B-766, B-837*  
 Guntinas-Lichius O.: *B-767*  
 Guo A.: *B-352*  
 Guo J.: *B-574*  
 Guo Q.Y.: *B-035, B-115*  
 Guo S.: *C-770*  
 Guo Y.-K.: *B-110, B-326, B-825*  
 Guo Y.L.: *C-741*  
 Gupta A.K.: *B-524*  
 Gupta H.: *B-013*  
 Gupta M.: *B-524, C-662, C-930*  
 Gupta N.: *C-711, C-715*  
 Gupta P.: *B-247, C-537*  
 Gupta R.: *B-524, C-662, C-711, C-930*  
 Gupta S.: *C-245*  
 Gupta S.S.: *C-710*  
 Gupta V.: *B-780*  
 Gurgendize M.: *C-014*  
 Gurses B.: *B-749*  
 Gusmini S.: *B-149, B-288*  
 Gussew A.: *C-754*  
 Gutberlet M.: *A-116*  
 Gutiérrez A.: *C-604, C-682, C-799, C-800*  
 Gutierrez B.: *C-478*  
 Gutiérrez Hernández P.: *C-601*  
 Gutierrez M.A.: *C-054*  
 Guven K.: *B-390*  
 Guzman J.: *C-749*  
 Guzzardi G.: *B-123*  
 Gweon H.M.: *C-801*
- H**  
 Haage P.: *B-020*  
 Haakull A.E.: *B-536*  
 Haab A.: *B-834, B-835*  
 Haász J.: *B-832*  
 Haberal M.: *B-565*  
 Haberal N.: *B-385*  
 Haberkorn U.: *A-405*  
 Haberland U.: *C-257*  
 Häberle L.: *C-321*  
 Habermann C.R.: *B-052, B-055, B-057, B-058, B-171*  
 Habib S.: *B-113*  
 Habs D.: *B-633*  
 Hackl M.: *B-230*  
 Hadas-Halpern I.: *C-412*  
 Hadjijev J.: *B-532*  
 Hadjigeorgiou G.: *B-426*  
 Haemmerich D.: *B-376*  
 Hagberg G.H.: *B-461*  
 Haghighi M.: *B-807*  
 Haghikia A.: *C-748*  
 Hagspiel K.D.: *B-838*  
 Hahn C.-K.: *C-496*  
 Hahn D.: *B-792, B-794, B-821, B-824*  
 Hahn H.K.: *C-748*  
 Hahn S.: *B-813*  
 Hahn S.T.: *B-444*  
 Haider M.A.: *B-038*  
 Hainsworth S.V.: *C-245*  
 Hajdu C.: *B-339*  
 Hájek M.: *A-229*  
 Hakkalamani S.: *B-006*  
 Halbhuber K.-J.: *C-326*  
 Hald J.: *B-505*  
 Halemane U.: *C-318*  
 Halligan S.: *B-477, B-480*  
 Hama H.: *C-090*  
 Hamady M.: *B-773, C-539, C-540*  
 Hamann J.: *B-294, C-177*  
 Hamano H.: *C-052*  
 Hambek M.: *B-180*  
 Hambrock T.: *B-741*  
 Hameeduddin A.: *C-504*  
 Hamilton M.C.K.: *B-690, C-191, C-920*  
 Hamm B.: *A-076, A-106, B-678, B-792*  
 Hammen T.: *B-429*  
 Hammerstingl R.: *B-242, B-246, B-700, D-74*  
 Hamza O.: *B-102, B-103*  
 Hamza R.: *C-513*  
 Han B.-K.: *B-286, B-755*  
 Han C.Y.: *C-130*  
 Han C.: *C-770*  
 Han J.K.: *B-147, B-150, B-353, B-582, B-594, C-008, C-453*  
 Han P.: *B-761*  
 Han S.J.: *B-529*





- Han Y.M.: B-244, C-253  
Hanasoge R.H.N.: B-810, C-717,  
C-732, C-782, C-907  
Handoko W.: B-802  
Haneda K.: C-095  
Hannemann P.: B-434  
Hannig C.: C-623  
Hansch A.: B-341, B-434, C-497  
Hansell D.M.: B-673, B-814, B-815  
Hansell P.: B-091  
Hansen J.: B-292  
Häntschel M.: B-627  
Hany T.F.: B-270, B-629  
Haouy D.: B-155  
Hara S.: C-384  
Hara T.: C-123  
Harada Y.: C-653, C-654  
Harden S.: C-205, C-207  
Hardy M.: B-533, B-535  
Hareyama M.: C-789  
Harganani R.: C-550  
Harman A.: B-565  
Haroche J.: B-220  
Haroun A.: B-387  
Harries-Jones H.: A-323  
Harris G.: B-587  
Harris S.R.: C-143, C-194  
Harrison L.C.V.: B-467  
Harry V.N.: B-034  
Hart J.L.: B-501  
Hartig F.: B-348, B-349  
Hartman T.E.: A-147  
Hartmann E.: C-572  
Hartmann I.: A-121  
Hartung D.: C-148  
Harvey C.: C-279  
Hasanefendioglu Bayrak A.: C-929  
Hascalik S.: C-726  
Hasegawa M.: B-200, C-767  
Hashimoto M.: B-356  
Hata H.: C-116  
Hatta T.: C-052  
Hatzidakis A.: B-561, B-563  
Hatzigeorgiou C.: C-729  
Haubner R.: A-407  
Hauff P.: B-030, C-612  
Haumer M.: B-099  
Hause F.: B-767  
Hausmann M.: C-748  
Hauwel M.: B-681  
Hawkes D.J.: A-194  
Hawkins R.A.: C-838  
Hawnaur J.M.: B-153  
Hawtin K.: B-673  
Hayabuchi N.: C-543  
Hayakawa K.: B-782, C-116  
Hayasaka K.: C-383  
Hayashi D.: C-028  
Hayashi N.: C-290  
Hayashi S.: B-200  
Hayashi T.: C-228, C-384, C-791  
Hazem M.: B-422  
He J.: B-769  
He Q.: C-243  
He W.: C-243  
Heaslip I.S.E.: B-727  
Heberlein K.: B-354  
Heckmann M.: C-323  
Hedderich J.: B-165  
Hedgire S.S.: B-247, C-537  
Heiberg L.: B-786  
Heijmink S.W.T.P.: B-741  
Heiken J.P.: B-093  
Hein P.: B-678  
Heindel W.L.: B-022, B-043, B-183,  
B-412, B-416, B-590, B-684, B-795,  
C-610  
Heine J.: B-273  
Heinen F.: B-781  
Heinrich M.: C-321  
Heinz-Peer G.: B-099  
Heiss W.-D.: B-212  
Helbich T.H.: A-162, A-480, A-484,  
B-611, B-754, B-792, C-091, C-092  
Heliö T.: C-149  
Helle M.: B-301  
Heller M.: C-157, C-256  
Heller S.: B-128  
Hellman P.: B-626  
Hellmann M.: B-723  
Hellund J.C.: A-467  
Helm E.J.: B-526  
Helmberger T.K.: A-040, B-333, B-570  
Hendrikse J.: A-091, D-48  
Hennig J.: A-002, A-140, A-202  
Henning T.D.: B-023, B-026  
Henninger B.: B-072  
Henninger V.: B-641  
Hennings J.: B-626  
Hentrich D.: B-434, B-745, C-497  
Henze M.: B-215  
Heo J.-N.: C-163, C-496  
Herber S.C.A.: B-121, B-122, B-271,  
B-273, B-275, B-567, B-717, C-599  
Herborn C.U.: D-52  
Heredia V.: B-141  
Hergt R.: C-326  
Herman B.: B-218  
Herman P.: C-534  
Hermans R.: A-080, B-172  
Hernández C.: C-233  
Hernandez C.B.: C-161, C-242, C-281  
Hernández D.: C-067  
Hernandez E.: B-138  
Hernandez I.: C-705  
Hernanz Padial J.: C-499, C-703  
Herneth A.: A-008  
Herold C.J.: A-245, A-325, B-598  
Herold M.: B-349, B-491, C-113  
Herraiz M.J.: C-233  
Herregods N.: C-624, C-788  
Herrero Y.: C-392  
Herrerros Villaravitz M.: C-093, C-437  
Herrmann K.A.: A-296, B-650  
Herrmann K.-H.: B-614  
Hertel S.: B-373  
Hervás V.: C-180  
Herzog A.B.: B-491, B-493, B-500,  
C-110, C-113  
Herzog C.: B-236, B-731, C-185  
Hes O.: B-609  
Hetzler F.H.: B-370  
Heuberger J.: B-191, B-198, B-199  
Heuschmid M.: C-186  
Heusner T.: B-622, B-800  
Heussel C.P.: B-677  
Hey W.: C-873  
Heye T.: B-583, C-263  
Heyman S.: C-626  
Heywang-Köbrunner S.H.: B-290  
Hidden-Lucet F.: B-324  
Hierholzer J.: B-274  
Hietschold V.: B-637  
Higano S.: C-301  
Higashi M.: B-064, B-081  
Higashida Y.: C-098, C-735, C-888  
Hilario A.: B-189, C-538, C-666, C-736,  
C-812, C-824  
Hildebrandt W.: B-710, C-664  
Hilger I.: C-326

- Hiller H.: *C-081*  
 Hinkmann F.M.: *B-053*  
 Hirai N.: *C-840, C-889*  
 Hirano Y.: *C-415*  
 Hirata M.: *C-858*  
 Hiratsuka Y.: *C-721, C-765*  
 Hirokawa Y.: *B-143, C-057*  
 Hirota A.: *B-782*  
 Hitomi R.: *C-846*  
 Hitt R.: *C-492*  
 Hiwatashi A.: *C-735*  
 Hn R.: *C-704, C-712*  
 Hocaoglu Y.: *B-489*  
 Hochmuth K.: *B-453*  
 Hodler J.: *B-140, B-347*  
 Hodnett P.: *C-241*  
 Hodson J.: *B-673*  
 Hoe J.: *C-167*  
 Hoeffel C.: *B-736, C-393, C-532*  
 Hoehler S.: *C-745*  
 Hoehn M.: *A-228*  
 Hoeltke C.: *C-610*  
 Hoevelborn T.: *B-235*  
 Hoey E.T.D.: *C-203*  
 Hof I.: *B-828*  
 Hoff H.: *B-266*  
 Hoffman E.A.: *B-820*  
 Hoffmann B.: *C-256*  
 Hoffmann M.H.K.: *B-120, B-182, C-169*  
 Hoffmann N.: *B-237*  
 Hoffmann R.-T.: *B-277, B-333*  
 Hofheinz N.: *B-165*  
 Hofman P.A.M.: *B-090, B-173*  
 Hoggard N.: *B-531*  
 Hohl C.: *B-020, B-130, B-723, B-766*  
 Hohl K.: *B-120*  
 Hohmann J.: *B-358*  
 Højgaard L.: *A-215*  
 Holder D.: *B-805*  
 Holzapfel K.: *B-175, B-264, B-265, B-744, C-623*  
 Holzwarth H.-F.: *C-109*  
 Homan R.: *C-591*  
 Homburg P.J.: *B-063, B-065, B-186*  
 Homolka P.: *B-636, B-686*  
 Honda C.: *B-342, B-631*  
 Honda H.: *C-735*  
 Hong H.-P.: *C-587, C-607*  
 Hong H.S.: *C-831*  
 Hong S.H.: *B-134, B-715, C-012, C-661*  
 Hong S.-J.: *B-680*  
 Hong S.S.: *C-049*  
 Hongo N.: *C-053, C-560*  
 Hoogveen R.: *B-416*  
 Hoogstraete S.R.: *C-820*  
 Horak M.: *B-469*  
 Horesh L.: *B-805*  
 Horger M.S.: *B-145, C-022, C-077, C-487, C-685*  
 Horger W.: *B-145*  
 Hori M.: *B-310, C-796*  
 Hori Y.: *B-064, B-081, C-730, C-780*  
 Horiguchi J.: *C-087, C-840, C-889*  
 Horikosi T.: *C-761*  
 Hörmann M.: *A-224*  
 Horng A.: *B-346, B-573*  
 Horstick G.: *B-237, B-552*  
 Hosch W.: *B-583, C-263*  
 Hosten N.: *A-042, B-089*  
 Hou J.W.: *B-131*  
 Hou Y.: *B-115*  
 Hountala A.: *C-827*  
 Hovius S.E.R.: *B-010*  
 Howarth N.: *A-082*  
 Hrnica H.: *A-077, A-302, B-024, B-029, B-747*  
 Hrkac-Pustahija A.: *B-482*  
 Hsieh T.-J.: *C-037*  
 Hu D.: *B-571*  
 Hu L.: *B-070*  
 Huang H.: *C-320*  
 Huang J.: *B-713, C-314*  
 Huang P.: *B-772*  
 Huang S.-Y.: *B-170*  
 Huber A.M.: *B-559, B-688*  
 Huber M.: *B-463*  
 Huda W.: *B-111, B-515, B-520*  
 Hudson M.: *B-820*  
 Huebner F.: *B-236*  
 Huelga Zapico E.: *C-579*  
 Huete A.: *C-001*  
 Huetter J.: *B-094*  
 Hufton A.: *C-402*  
 Hughes N.P.: *B-365*  
 Hughes P.: *A-305, C-659*  
 Hughes S.: *B-178*  
 Hughes T.: *B-354, C-651*  
 Hugo C.: *B-840*  
 Huisman H.: *C-105*  
 Huisman T.A.G.M.: *A-221, A-223*  
 Hulsbergen-van de Kaa C.A.: *B-741*  
 Humbert P.: *C-669*  
 Hunink M.G.M.: *A-256, B-090, B-114*  
 Hunold P.: *B-322, B-373*  
 Huppert J.: *B-030, C-941*  
 Huppert P.E.: *B-831*  
 Hur J.: *C-187*  
 Husband J.E.: *A-327*  
 Husmann L.: *B-450, C-166*  
 Hussain H.: *C-600*  
 Hussain S.: *C-297*  
 Hütter J.: *B-096*  
 Hüttl K.: *B-832*  
 Hutton B.: *B-113*  
 Huwart L.: *B-268, C-534*  
 Hwang H.-J.: *B-112*  
 Hwang J.H.: *C-012, C-049*  
 Hyacinthe J.-N.: *B-681*  
 Hyafil F.: *B-021, B-649*  
 Hyodoh H.: *C-789*  
 Hyodoh K.: *C-789*  
 Iabichino C.: *C-357, C-382*  
 Iacconi C.: *C-097, C-100*  
 Iacucci I.: *B-323, C-146, C-154*  
 Iafrate F.: *B-474, C-293, C-897*  
 Iala A.: *B-768*  
 Ianniello A.: *C-596, C-606, C-909*  
 Ibañez L.: *C-719, C-778*  
 Ibañez J.: *C-738*  
 Ibañez L.: *C-674, C-834*  
 Ibe M.: *B-434*  
 Ichiba N.: *C-028*  
 Ichikawa K.: *B-200, C-310*  
 Idée J.-M.: *B-092*  
 Idoate F.: *C-639*  
 Ierace T.: *B-374*  
 Ierardi C.: *C-106, C-107*  
 Iezzi R.: *B-415, B-646, B-775, B-778, B-796, C-899, C-900*  
 Iglesias Castañón A.: *C-093, C-437*  
 Iihara K.: *B-064*  
 Iinuma G.: *B-477, C-411, C-415*  
 Ikawa M.: *C-384*  
 Ikeda M.: *C-033, C-060, C-846*  
 Ikedo Y.: *C-123*  
 Ikeuchi T.: *C-336*  
 Ikuma H.: *C-007*  
 Ikura H.: *C-236, C-252*



- Ikura M.: C-236, C-252  
Ilangovan R.: B-480  
Ilyaraja V.: B-247, C-537  
Illiano L.A.: C-120  
Im J.-G.: B-225, B-671, C-220, C-230  
Imai K.: C-846  
Imai Y.: C-236, C-252, C-903  
Imuta M.: C-034  
Inaba Y.: C-031  
Inácio J.: C-823  
Inal M.: C-072  
Inaloz S.: C-871  
Inan N.: C-755  
Inbar Y.: A-241  
Iñiguez Gomez A.: C-533, C-579  
Inoue K.: B-233  
Inoue Y.: C-675, C-781  
Insausti I.: C-762, C-766  
Insausti M.: C-608  
Invernizzi F.: B-036, B-716, C-571  
Ipatova E.O.: B-280  
Ippolito D.: B-036, B-716, C-571  
Irfanoglu M.O.: B-667  
Isgum I.: B-078  
Ishibashi M.: C-338  
Ishibashi T.: C-301  
Ishida M.: B-683  
Ishida N.: B-233, B-683  
Ishida T.: C-087  
Ishigaki S.: C-033  
Ishii M.: C-098  
Ishii R.: C-098  
Ishiyama A.: C-227, C-228  
Ishiyama K.: B-356  
Islak C.: C-929  
Isleyen M.: C-832  
Isoda H.: B-143, C-057  
Isono S.: B-310  
Ito K.: C-087, C-840, C-889  
Ito M.: B-683  
Ito S.: C-033, C-520  
Itoh S.: C-060  
Itoh T.: B-064, B-081, B-315  
Itoh Y.: C-102  
Ivanovic A.: C-490  
Iwamoto R.: C-543  
Iwase T.: C-102  
Iyengar S.S.: C-565, C-659  
Izquierdo J.: C-054, C-055, C-604, C-657, C-682, C-799  
Izzyka-Swieszewska E.: C-588
- J**  
Jabeen F.: C-502  
Jabi F.: B-078  
Jackson K.C.: C-424  
Jacob A.L.: B-419  
Jacob U.: B-337  
Jacobi V.: B-452, B-652  
Jaconi M.: B-681  
Jacquier A.: C-156, C-173  
Jadun C.K.: C-784  
Jae H.J.: B-334, B-695  
Jaehne M.: B-052  
Jaffer N.: C-289  
Jahren A.: B-519  
Jain N.: C-131, C-381  
Jain Y.: C-512  
Jakob P.M.: B-578  
Jakobs T.F.: A-053, B-277, B-333, B-650  
Jakobsen A.: B-368  
Jakobsen J.: B-505  
Jalaguier A.: C-665  
James S.L.J.: C-631  
Jandt U.: B-640  
Jang J.H.: C-380  
Jang J.J.: B-147  
Jang J.Y.: C-008  
Jang Y.M.: B-112, B-437  
Jangland L.: C-408  
Jänisch T.: B-583  
Jankowski J.: C-868  
Jans L.: C-788  
Jansen O.: B-301  
Janus N.: B-098  
Jaromi S.: B-754  
Jarraya H.: C-919  
Jasbik M.: C-129  
Jaschke W.R.: B-001, B-072, B-230, B-348, B-349  
Jastrzebska M.: C-616  
Jaucuck C.: B-408  
Jaw T.-S.: C-037  
Jayan R.: C-636  
Je B.-K.: B-382  
Jedynak A.R.: B-807  
Jehl F.: B-630  
Jeltsch M.: B-120, B-182, C-169  
Jend H.-H.: C-269, C-270  
Jendelova P.: A-409  
Jenkins M.P.: B-773, C-539, C-540
- Jensen K.E.E.: B-344  
Jeon I.-H.: B-136  
Jeon P.: B-763  
Jeon S.C.: C-163  
Jeong Y.Y.: C-456, C-479  
Jepson S.L.: C-279  
Jerebko A.K.: B-315  
Jevtic V.: A-258  
Ji E.-K.: C-195  
Jiang L.: B-618  
Jiang S.L.: B-737  
Jiang T.: C-737  
Jiang Z.: C-439  
Jianrong X.: C-849  
Jiménez J.A.: C-015  
Jimenez Jurado M.D.: C-528  
Jimenez P.: C-503  
Jimenez S.: C-492, C-736  
Jin G.-Y.: B-244, C-253  
Jin H.: B-238  
Jin W.: B-470, C-863  
Jin Z.: B-070, C-152, C-172  
Jin Z.Y.: B-261, B-623, B-702, C-364, C-904, C-905  
Jing Z.: B-042  
Jinzaki M.: C-903  
Job L.: B-736, C-393  
Jochims M.: B-322  
Jodocy D.: B-740  
Joemai R.M.S.: B-299, B-762  
Joffre F.: B-776  
Jogeesvaran K.H.: C-485  
Johnson G.: B-214  
Johnson T.R.: A-067, B-439, B-440, B-490, B-518, C-343  
Johnsrud K.: B-786  
Johnston M.: B-221  
Jonas E.: B-352  
Jonat W.: B-165  
Jong R.A.: A-431  
Jonkergouw P.A.J.: B-639  
Jönsson L.: B-352, D-21  
Jouve J.-L.: B-335  
Juanco C.: C-054, C-055  
Juanpere S.: C-409  
Juergens K.U.: B-183, B-590, B-684  
Jugold M.: C-941  
Juharosi G.: C-572  
Juhn J.-R.: C-124  
Julián J.F.: B-284

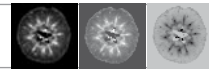
Jung J.I.: *B-444*  
 Jung J.-Y.: *C-267*  
 Jung S.E.: *C-021, C-474*  
 Junghanss T.: *B-583*  
 Junker D.: *B-008, B-345, B-740*  
 Juras V.: *C-647*  
 Jurik A.: *B-292*  
 Jurkiewicz E.: *C-819*

## K

Kabacki N.: *B-749*  
 Kabala J.E.: *A-310*  
 Kabasawa H.: *C-796*  
 Kabra S.: *B-524*  
 Kadota T.: *C-227, C-228*  
 Kadour M.J.: *B-168*  
 Kadoya M.: *C-052*  
 Kaehler C.M.: *C-244*  
 Kaekoenen S.-M.: *C-612*  
 Kaercher J.: *C-316, C-464, C-481*  
 Kaffel D.: *C-618*  
 Kagaya Y.: *C-861*  
 Kahn T.: *C-928*  
 Kaimann L.: *B-130*  
 Kainberger F.: *A-471, A-472, B-636*  
 Kaiser G.: *B-373, B-380*  
 Kaiser W.A.: *B-304, B-341, B-491, B-493, B-496, B-500, B-614, B-619, B-767, C-108, C-110, C-112, C-113, C-114, C-115, C-298, C-326, C-673, C-754*  
 Kakhadze S.: *C-014*  
 Kakita S.: *C-116*  
 Kakite S.: *C-338, C-495*  
 Kakoklyris S.: *C-879*  
 Kakouros N.: *C-192*  
 Kalafut J.F.: *B-116, B-119, C-847*  
 Kalender W.A.: *A-065, A-066, B-298, B-512, B-513, B-514, B-517, B-632, C-870, D-17*  
 Kalikis D.: *C-377, C-938*  
 Kalkmann J.: *C-581*  
 Kalogeropoulos I.V.: *C-786*  
 Kalpakidis V.: *C-729*  
 Kälviäinen R.: *B-804*  
 Kalyanpur A.: *B-509*  
 Kalyanpur T.: *B-247, C-537*  
 Kam C.: *C-320*  
 Kamimura K.: *C-039, C-050, C-458*  
 Kaminska K.: *C-821*

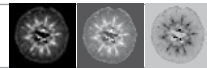
Kamman R.L.: *B-639*  
 Kan S.: *C-116*  
 Kan T.: *C-495*  
 Kan W.: *C-320*  
 Kan Z.: *C-314*  
 Kanakakis K.: *C-567*  
 Kanamoto T.: *C-322*  
 Kanasaki S.: *C-563*  
 Kanasaki Y.: *C-338, C-495*  
 Kanavou D.: *C-117*  
 Kanda T.: *B-782*  
 Kandasamy N.: *C-550*  
 Kandeel A.: *B-059*  
 Kandeel A.Y.: *B-530*  
 Kandel R.: *B-708*  
 Kandpal H.: *C-926*  
 Kaneider A.: *B-611*  
 Kang E.-Y.: *C-276*  
 Kang H.K.: *C-188, C-255, C-456, C-479*  
 Kang H.S.: *B-134, C-661*  
 Kang H.W.: *C-808*  
 Kang J.H.: *C-130*  
 Kang J.-W.: *B-112*  
 Kang K.-S.: *C-808*  
 Kang M.J.: *C-366*  
 Kang P.G.: *C-587*  
 Kang S.S.: *C-195*  
 Kankaanranta L.: *C-311*  
 Kanou M.: *C-828*  
 Kanzaki S.: *B-064, B-081*  
 Kao Y.-T.: *C-037*  
 Kaphammel O.: *B-519*  
 Kaplan J.: *B-807*  
 Kaplan M.: *C-370*  
 Kappeler L.: *B-302*  
 Kapral T.: *B-343*  
 Kapsalaki E.: *B-426*  
 Kapur R.: *A-342*  
 Kara E.: *C-929*  
 Karageorghiou C.: *B-426*  
 Karahaliou A.: *C-117*  
 Karakas H.M.: *C-726*  
 Karampekios S.: *A-365*  
 Karani J.B.: *A-336*  
 Karantanas A.H.: *A-260, B-462, B-464, C-027, C-638, C-667, C-670, C-671, C-672*  
 Karatasidou A.: *C-545*  
 Karcher K.: *B-768*  
 Karhu J.: *D-33*

Karie S.: *B-098*  
 Karigiannis M.: *C-545*  
 Karolemeas K.: *B-393, C-027*  
 Karolemeas K.P.: *B-192*  
 Karp K.: *B-834, B-835*  
 Karssemeijer N.: *B-047*  
 Karst R.: *B-232*  
 Karthik G.: *C-199*  
 Karunanithy N.: *C-178, C-693*  
 Karuppasamy K.: *C-272*  
 Karwal R.: *B-247, C-537*  
 Karydas G.: *C-545*  
 Kasemier J.H.: *B-074*  
 Kashiwagi J.: *C-730, C-780*  
 Kasir D.: *C-445*  
 Kaskarelis I.S.: *C-567*  
 Kaspar M.: *B-469*  
 Kasprian G.: *B-305*  
 Kasprian G.J.: *B-406, B-407*  
 Kastler B.: *C-669*  
 Katamis A.: *C-083*  
 Kateri A.: *C-333*  
 Kato A.: *C-767*  
 Kato K.: *C-520*  
 Katsaros V.K.: *B-764*  
 Katsimilis I.: *C-638*  
 Katsiva V.G.: *C-147*  
 Katsube T.: *C-791*  
 Katsuda T.: *C-869*  
 Kattan M.W.: *B-747*  
 Katube T.: *C-384*  
 Katz R.: *C-504*  
 Katzos G.: *C-825*  
 Kauczor H.-U.: *A-132, A-429, B-073, B-215, B-504, B-521, B-641, B-677, B-710, B-793, B-818, C-664*  
 Kauffmann G.W.: *B-583, C-263*  
 Kaufmann P.A.: *B-450*  
 Kaul M.G.: *B-396*  
 Kavcic V.: *B-423*  
 Kawa S.: *C-052*  
 Kawai H.: *C-033*  
 Kawai M.: *C-095*  
 Kawai T.: *C-305*  
 Kawai Y.: *C-789*  
 Kawakami S.: *C-052*  
 Kawamura M.: *C-514*  
 Kawasaki H.: *B-342, B-631*  
 Kawase S.: *C-520*  
 Kawasumi Y.: *C-301*



- Kayani I.: B-113  
Kazama K.: C-883  
Kazama T.: B-591, C-416, C-428,  
C-429, C-761  
Kazaoka J.: C-772  
Kearins O.: B-281  
Keeling A.: C-418  
Kehlbach R.: C-613  
Kelekis A.: B-562, C-701  
Kelekis A.D.: A-188, A-189  
Kelekis D.: B-331  
Kelekis N.: B-562, C-083, C-111,  
C-147, C-643  
Kellenberger C.J.: A-465  
Kelliher E.: C-224, C-280, C-523  
Kelly A.M.: B-229  
Kelly K.: B-024  
Kelly K.M.: B-169  
Kelognigris M.: C-295, C-786, C-874  
Kemper C.A.: B-116, B-119, C-847  
Kemper J.: B-486, B-487  
Kendler D.: B-072, B-625, B-799  
Kerl J.M.: B-119, B-327, C-185  
Kerl M.: B-386  
Kerr D.: B-365  
Kersjes W.: C-873  
Kervancioglu R.: C-871  
Kervancioglu S.: C-871  
Kessler T.M.: B-485  
Kestelman F.: C-129  
Kettenbach J.: B-340, B-570  
Kettering M.: C-326  
Khaleel Z.: C-217  
Khalil A.: C-313, C-931  
Khalil C.: A-402  
Khalili M.: C-377  
Khan F.: B-652  
Khandelwal N.: B-780  
Khanna G.: C-620  
Kharadze R.: C-014  
Khattari R.K.V.: C-140  
Khaw A.V.: B-089  
Khayat R.: B-676  
Kheddache S.: D-09  
Kheir A.: C-566  
Khoo L.: A-063  
Khosa H.: C-523  
Khouri T.: B-656  
Khushu S.: B-543, B-546  
Kiale K.: C-111  
Kiefer B.: B-145  
Kiefer D.: B-558  
Kiely D.: B-328  
Kienbaum S.: B-352, D-21  
Kiesling F.: B-030, C-941  
Kievit J.: B-511  
Kiguchi M.: C-840, C-889  
Kikuchi K.: C-721, C-765  
Kilian A.K.: C-814  
Kilian K.: B-401, B-402  
Kilina D.Y.: C-642  
Kim B.: B-813  
Kim B.H.: B-382  
Kim B.S.: C-808  
Kim C.-H.: B-136  
Kim C.K.: B-746  
Kim D.H.: C-145  
Kim D.I.: C-801  
Kim D.J.: C-801  
Kim D.Y.: C-195  
Kim E.K.: C-130  
Kim H.C.: C-863  
Kim H.-C.: B-695  
Kim H.H.: C-069  
Kim H.J.: C-002  
Kim H.-J.: B-763  
Kim H.K.: C-646  
Kim H.-R.: B-443  
Kim H.-S.: C-562  
Kim H.Y.: B-224, B-473, C-225  
Kim I.H.: C-008  
Kim I.Y.: C-002  
Kim J.: C-456  
Kim J.A.A.: B-470  
Kim J.G.: C-646, C-830  
Kim J.H.: C-012, C-021, C-023, C-049,  
C-818  
Kim J.-H.: C-454  
Kim J.I.: B-604, C-225, C-359  
Kim J.K.: C-069, C-255  
Kim J.S.: C-842  
Kim J.W.: C-276, C-456  
Kim J.Y.: C-453, C-496, C-830  
Kim K.: C-808  
Kim K.A.: C-462  
Kim K.G.: B-225, C-230  
Kim K.H.: B-763  
Kim K.J.: B-813  
Kim K.S.: C-801  
Kim K.T.: C-076  
Kim K.W.: B-715, C-430, C-454  
Kim M.: C-380  
Kim M.-D.: C-267  
Kim M.J.: C-430  
Kim M.-J.: B-529, C-454  
Kim M.K.: C-118  
Kim M.S.: C-076  
Kim N.: B-473, B-680  
Kim N.R.: B-134, C-661  
Kim O.-H.: C-124  
Kim S.: B-339, C-425, C-496  
Kim S.H.: B-147, B-150, B-353, B-473,  
B-582, B-594, B-604, C-008, C-359,  
C-453, C-808  
Kim S.J.: B-582, B-715, C-132  
Kim S.-J.: B-286, B-755  
Kim S.K.: C-587, C-607  
Kim S.M.: B-473  
Kim S.T.: B-763  
Kim S.W.: C-002  
Kim S.-W.: C-008  
Kim S.-Y.: B-167  
Kim T.J.: B-813, C-230  
Kim W.H.: B-715  
Kim Y.: C-064, C-163, C-496  
Kim Y.H.: B-367, B-473, B-813, C-188,  
C-255  
Kim Y.-H.: C-646  
Kim Y.J.: B-244, C-187  
Kim Y.N.: B-377  
Kim Y.S.: C-118, C-132  
Kim Y.-S.: B-377, B-378  
Kimiskidis V.: C-729  
Kimura M.: C-883  
Kimura N.: B-200  
King D.: B-251  
King M.: C-486  
Kinkel K.: A-288, A-484  
Kinner S.: B-418, B-420, B-581  
Kinosada Y.: C-031  
Kinscherf R.: B-710, C-664  
Kinzel S.: B-130  
Kirchin M.: C-011, C-047  
Kirchin M.A.: B-413, B-415, B-642,  
B-796, C-318  
Kiriama I.: C-721, C-765  
Kirke R.: C-240  
Kirmi O.: C-720  
Kirsch J.: B-504  
Kirsch M.: B-089

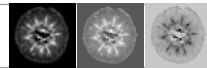
- Kishore C.: C-712  
 Kiss I.: C-420  
 Kitagaki H.: C-384, C-791  
 Kitahara S.: C-086  
 Kivistö S.: C-149  
 Kiyohara S.: C-039  
 Kiyosue H.: C-560, C-730, C-780, C-924  
 Klass O.: B-120, C-169  
 Klatka J.: B-176  
 Klauser A.: B-008, B-256, B-345,  
 B-510, B-740, D-42  
 Kleber J.-B.: B-521  
 Klein J.: C-748  
 Klein S.: B-184, B-319  
 Kleinholz A.: C-873  
 Kleis M.A.: C-838  
 Klemm H.: B-830  
 Klerkx W.M.: C-400  
 Kletter K.: A-472, B-054  
 Klimeczek P.: B-330, B-555  
 Klimentenko N.L.: C-642  
 Klingebiel R.: D-71  
 Kliouchkin I.V.: C-119  
 Kloeckner R.: B-717  
 Klotz E.: B-053, B-107, B-395, B-715,  
 C-257  
 Kluba T.: C-613  
 Klumpp B.: B-235, B-239, B-448,  
 B-557  
 Klzo L.: C-802  
 Knaup M.: B-632  
 Knauth M.: B-084  
 Knecht R.: B-180  
 Knipscheer B.C.: B-741  
 Knöfel S.: B-540  
 Knoll F.: C-860  
 Knopp M.V.: B-397, B-664, B-666,  
 B-667  
 Knöss N.: C-256  
 Ko E.-Y.: B-286, B-755  
 Ko Y.T.: C-002  
 Kobayashi S.: B-497, C-006, C-314  
 Kocer N.: C-929  
 Koch A.: B-637  
 Koch K.: B-552  
 Koch R.M.: B-667  
 Koch U.: B-273  
 Kocheida E.M.: B-427  
 Koda W.: C-006  
 Kodani K.: C-251  
 Koerner M.: C-084  
 Koerte I.: B-781  
 Koestler H.: B-821  
 Koganemaru M.: C-543  
 Kogos P.G.: B-116  
 Koh B.-H.: C-064  
 Koh D.-M.: B-040  
 Koh T.S.: B-051, B-060, B-386  
 Kohama C.: C-888  
 Kohda E.: C-767  
 Kohl T.: C-814  
 Kohno A.: C-102  
 Koikkalainen J.: C-149  
 Koivunoro H.: C-311  
 Kojima S.: C-858  
 Kokkinaki A.: C-522, C-786  
 Kokkis S.: C-111  
 Kokotsakis I.: C-567  
 Kokulinsky P.C.: B-258  
 Kölblinger C.: B-589  
 Kollia K.: B-661  
 Kolligs F.T.: B-472  
 Kollmann T.: C-367  
 Komada T.: C-033  
 Komatsu Y.: C-134  
 Komori Y.: C-858  
 Komorowski D.J.: C-553  
 Komuro I.: C-171  
 Kondo Y.: C-730  
 Konen E.: B-829  
 Kong L.: C-152, C-172  
 Kong T.: C-320  
 Kong W.-J.: B-761  
 Konitsiotis S.: B-421, B-550  
 Kono N.: C-563  
 Kono S.: C-087  
 Könönen M.: B-804  
 Kooijmann D.: B-416  
 Kooijmann H.: B-412  
 Kool D.R.: B-090  
 Koops A.: B-171, B-232, B-830  
 Kopka K.: C-610, C-615  
 Kopp A.: C-186  
 Koppelstaetter F.: B-510, B-806  
 Kopp-Schneider A.: B-710  
 Koprivsek K.M.: C-751  
 Korkusuz H.: B-246, B-652  
 Kornienko V.N.: C-740  
 Korzec J.: C-931  
 Korzenev A.V.: B-547  
 Kos S.: B-419  
 Koskenkorva P.: B-804  
 Kostaras V.P.: C-567  
 Köster O.: C-748  
 Köstler H.: B-794, B-824  
 Kostopoulos C.: B-674  
 Kothari S.S.: C-933  
 Kott A.: B-434, B-745, C-109, C-497  
 Kotter E.: B-313  
 Kotzampassakis N.: C-080  
 Koulocheri D.: C-089  
 Koumanidou C.: C-810, C-827, C-836  
 Koumarianos D.: C-295  
 Kouvidis G.: C-667  
 Kovacs P.: B-625, B-799  
 Kovanlikaya I.: B-749  
 Kowalik E.: C-158  
 Kownacki L.: C-158  
 Koyama H.: B-101, B-106, B-817  
 Koyama T.: C-336, C-529, C-914  
 Kozeluhova J.: B-725  
 Kozic D.: C-751  
 Kozub J.: C-768  
 Kraff O.: B-258, B-662, B-663  
 Kraft O.: B-432  
 Krajina A.: A-337, C-802  
 Krakowski-Roosen H.: B-710, C-664  
 Kramer H.: B-472, B-643, B-645  
 Kramer J.: A-304  
 Krämer N.A.: B-723  
 Kramer U.: B-235, B-239, B-448,  
 B-557  
 Krampf E.: B-406  
 Kranzer R.: B-298  
 Kratt T.: B-011  
 Kratzer W.: D-45  
 Kraus A.: C-699, C-784  
 Kraus G.J.: C-853  
 Krausé D.: B-335  
 Krauss B.: B-228, B-439, B-680  
 Kreitner K.F.: B-237, B-414, B-552,  
 B-717  
 Kremastinos D.: C-147  
 Kremer B.: B-173  
 Kremer S.: B-630  
 Kremser C.: B-607  
 Krestan C.R.: B-343  
 Krestin G.P.: A-253, B-114, C-164,  
 C-184, D-03  
 Kreuter A.: B-553



- Kreuzberg B.: B-609, B-725  
Krick C.: B-834, B-835  
Krieg R.: A-217, A-274  
Krimmer H.: B-255  
Kringts T.: A-338, A-457  
Krishnan A.S.: C-003  
Krishnan S.S.: C-795  
Krix M.: B-710, C-664  
Krijkuv E.: B-394  
Kroeker R.: B-411  
Krokidis M.: B-561, B-563  
Krolicki L.: C-158  
Krombach G.A.: B-020, B-130, B-723, B-766  
Kromeier J.: B-660  
Krug C.: B-023  
Krumina G.: A-022  
Krupski-Berdien G.: B-171  
Kruskal J.: C-294  
Ku Y.M.: C-021, C-076  
Kubas B.: C-821  
Kubin K.: B-340  
Kucharczyk W.: A-001  
KücüK N.: B-432  
Kuefner M.A.: B-294, C-177, C-323  
Kuehl H.: B-373, B-380, B-800, C-581  
Kuemper C.: C-343  
Kuettner A.: B-075, B-659, B-797  
Kugel H.: B-412, B-795  
Kuhl C.K.: A-163, A-339, A-432, D-62  
Kuhn M.J.: B-093  
Kuhweide R.: B-765  
Kulak W.: C-821  
Kuligowska E.: C-330  
Kulinna-Cosentini C.: B-589  
Kulkarni S.: C-091, C-092  
Kumari R.: C-715  
Kumlien E.: B-801  
Kuncheng L.: B-085, B-206, B-207  
Kundur P.R.: A-344  
Kung B.: B-768  
Kunisada T.: C-867  
Kunitomi Y.: C-095  
Kunze G.: D-45  
Kurashvili Y.B.: C-593  
Kurganskaya T.: C-344  
Kuriakose J.: C-432  
Kuribayashi S.: C-903  
Kurita T.: B-683  
Kuriyama K.: C-095  
Kurjata R.: C-752  
Kurochka S.: C-066, C-927  
Kurtaran A.: A-308  
Kusmierczyk M.: C-158  
Kuàmieriek J.: C-757  
Kutscha-Lissberg S.: B-576  
Kutschbach C.: B-304  
Küttner A.: A-231, D-11  
Kuwert T.: A-216, A-273  
Kwee T.: B-399  
Kwok K.: C-320  
Kwon G.H.: C-012, C-049  
Kwon G.Y.: C-430  
Kwon H.-J.: C-430  
Kwon J.W.: B-252  
Kwon T.H.: C-195  
Kyriakou Y.: B-298, B-513, B-632, C-870  
Kyriakoulis D.: C-594  
Kyriakoylis D.: C-522
- L**  
La Folie T.: A-438  
La Grassa M.: B-041, D-10  
La Grutta L.: C-176  
La Sala A.: C-229  
Lacelli F.: B-033, B-137, B-259  
Lachanis S.: C-874  
Lachmann R.: B-121  
Lacombe P.: B-135  
Ladd M.E.: A-137, A-204, B-240, B-258, B-418, B-661, B-662, B-663, B-668  
Ladd S.C.: A-266, B-258, B-662, B-663, C-581  
Ladeb M.F.: C-618  
Ladebeck R.: A-217, A-274  
Ladewig G.: B-030  
Ladis V.: C-083  
Laerum F.: A-466, B-505  
Lagalla R.: C-159, C-165, C-176, C-421  
Laganà D.: C-596, C-606, C-909  
Laghi A.: A-096, B-474, C-024, C-164, C-293, C-339, C-855, C-897  
Laguillo G.: C-892  
Lainez A.: C-180  
Lakare S.: B-476, B-478  
Lakosi F.: B-532  
Lakshmi R.: C-712  
Lal A.: B-780  
Lam W.: C-320  
Lambert K.: C-254  
Lambertini R.G.: C-584  
Laméris W.: B-017  
Lammer J.: A-089, B-340, B-570, B-686  
Lammertsma A.A.: A-272  
Lampmann L.: B-570  
Lampropoulou E.: C-377  
Lanca L.: B-651, B-653  
Lancelot E.: B-021, B-092, B-649  
Lanciotti K.: B-417, B-593, B-597, C-181, C-182, C-442  
Landeras R.: C-657  
Landes C.: B-789  
Lane N.: C-075  
Lanfranchini D.: B-213  
Lang P.K.: C-684  
Langenberger H.: B-686  
Langer M.: B-313, B-398, B-658, B-660, B-722  
Langeron O.: C-299  
Langner D.: B-298, B-513  
Langner S.: B-089  
Langs G.: B-579, B-580  
Laniado M.: A-130, B-266, B-637  
Lantuejoul S.: B-223  
Lapp R.M.: C-870  
Lapsia S.K.: C-275, C-353  
Larena J.A.: C-465  
Larici A.R.: B-318, B-436  
Larrache J.: C-233  
Larrea Bilbao L.: C-484, C-515  
Larrea Bilbao L.M.: C-460  
Larsen A.: C-852  
Lashkhi K.: C-014  
Lasierra R.: C-798  
Laskowicz B.: B-330  
Laspas F.: C-295, C-874  
Lau S.: C-320  
Lauenstein T.C.: B-097, B-354  
Lauer U.: C-022  
Lauerma K.: C-149  
Launay-Vacher V.: B-098  
Lauratet B.: B-152, C-332  
Lavakumar R.: C-217  
Lavandeira P.: B-655  
Lavanya T.: B-405  
Lavrnic S.: C-773  
Law E.-M.: A-023, B-203

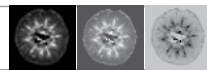
- Law M.: B-214  
 Lawler L.P.: C-549, C-894  
 Lawrence G.: B-281  
 Lázár I.: B-833  
 Lazaro Serrano M.: C-484  
 Lazic L.: C-045  
 Lazutkina V.Y.: C-593  
 Lazzereschi M.: C-387  
 Le Dosseur P.: B-409  
 Le Dref O.: C-546  
 Le Guen M.: C-299  
 Le Maire T.F.: B-282, B-839  
 Le Zoche R.: C-155  
 Leach J.: B-516  
 Lebeau A.: B-290  
 Lebrecht A.: B-290  
 Lecce M.: B-669  
 Lechel U.: B-383  
 Leconte I.: B-162  
 Lederman R.: B-049  
 Lee C.H.: B-225, B-671, C-220, C-230, C-462  
 Lee D.H.: B-147, B-334, C-002  
 Lee D.S.: C-611, C-614  
 Lee D.W.: C-831  
 Lee F.: C-455  
 Lee G.: C-123  
 Lee G.J.: C-646  
 Lee H.: B-116, B-119, B-327, B-443, B-556  
 Lee H.D.: C-830  
 Lee H.J.: B-225, B-604, B-671, C-220, C-230  
 Lee H.-J.: C-187  
 Lee H.M.: B-746  
 Lee H.Y.: C-230  
 Lee I.H.: B-252, B-454  
 Lee I.J.: B-695  
 Lee J.: B-136, C-462  
 Lee J.E.: C-096  
 Lee J.H.: B-224, C-069, C-366  
 Lee J.M.: B-147, B-150, B-353, B-582, B-594, B-715, C-008, C-453  
 Lee J.S.: B-224  
 Lee J.W.: B-134, C-661  
 Lee J.Y.: B-147, B-150, B-582, B-594, B-715  
 Lee K.H.: B-367, B-473, B-763, B-813  
 Lee K.Y.: C-276  
 Lee M.J.: B-837  
 Lee M.S.: B-529  
 Lee S.: C-425  
 Lee S.D.: B-680  
 Lee S.H.: B-224  
 Lee S.-H.: C-225, C-562  
 Lee S.J.: C-462  
 Lee S.-J.: C-124, C-267  
 Lee S.L.: C-076  
 Lee S.M.: B-367  
 Lee W.: B-334, C-425, C-896  
 Lee W.J.: B-378  
 Lee W.-J.: B-382  
 Lee Y.C.: C-253  
 Lee Y.H.: B-382  
 Lee Y.J.: C-021, C-380, C-474  
 Lee Y.-K.: C-267  
 Leeds N.: B-214  
 Lee-Elliott C.: C-486  
 Lees W.R.: B-243  
 Lefere P.: A-334, B-475  
 Lefèvre F.: A-028  
 Lefranc J.: B-152  
 Lefranc J.P.: C-332  
 Legouge A.: D-46  
 Lehnert T.: B-242, B-246, B-336, B-452, B-453, B-652, B-693, B-694, B-700  
 Leichter I.: B-049  
 Leifland K.: B-043  
 Leiner T.: A-248  
 Leite C.: C-066, C-927  
 Leite N.P.: C-085  
 Leiva-Salinas C.: C-413  
 Lell M.: A-071, B-053, B-381, D-19  
 Lembcke A.: B-678  
 Lemmerling M.M.: A-044, C-508, C-777  
 Lemort M.: B-792  
 Lénárd Z.: C-572  
 Lencioni R.: A-052, A-055, B-245, D-43  
 Lengenfelder B.: B-821  
 Lengsfeld P.: B-094, B-096  
 Lenhard M.S.: C-343  
 Lenzi D.: B-541  
 Lenzi G.L.: B-541  
 León A.: C-709  
 León Alonso J.: C-093  
 Leon J.: C-652  
 Leonardi A.: B-460, C-649  
 Lepanto L.: C-032  
 Lepetit-Coiffe M.: B-681  
 Lepida N.: C-522, C-535  
 Lequin M.H.: C-820  
 Leschka S.: A-254, B-450, B-483, B-484, C-166, C-179  
 Lete I.: C-775  
 Letsou D.: B-331, C-231  
 Lettmaier S.: B-053  
 Leuchte H.: B-816  
 Leung D.A.: C-553  
 Leusveld A.: B-226, B-227, C-212  
 Leusveld A.L.M.: B-317, C-210, C-211  
 Leuze M.: B-540  
 Levent S.: C-370  
 Levental M.: C-507  
 Levering A.: B-218  
 Levine D.: A-031  
 Levrero F.: C-747  
 Ley S.: B-073, B-521, B-641, B-677, B-818, C-263  
 Ley-Zaporozhan J.: B-073, B-521, B-641, B-677  
 Lezoche R.: C-154  
 Lhommé C.: A-264  
 Li C.: B-697, B-706, B-707  
 Li C.F.: B-131  
 Li C.-S.: B-146  
 Li D.: B-739  
 Li F.-H.: B-499  
 Li H.: B-572, B-574  
 Li J.: B-296, B-595, B-596, C-041, C-168, C-232, C-564, C-760, C-841, C-844, C-848, C-864, C-875  
 Li J.-M.: C-051  
 Li K.: B-208, B-542, B-739, C-144, C-731  
 Li K.L.: B-061, B-187  
 Li M.: B-070  
 Li N.: C-844, C-875  
 Li P.K.L.: C-631  
 Li Q.: C-035  
 Li S.: B-261, B-548, B-623, B-702, C-737, C-743  
 Li W.: C-744  
 Li X.: B-468, B-571, B-574, C-439  
 Li Y.: B-104, B-108, B-110, B-326, B-712, B-825  
 Li Y.G.: C-582  
 Li Z.: B-707  
 Li Z.-L.: B-108





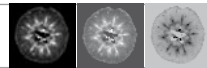
- Liang H.: B-692  
Liang P.: B-542, B-692  
Liao D.: C-422  
Liao J.: C-760, C-848, C-864  
Liasis N.: A-069  
Liaw J.: C-436  
Liaw J.V.P.: C-526, C-539  
Libson E.: B-635, B-714  
Lichy M.P.: B-011, B-145, B-351,  
B-627, C-022  
Liedenbaum M.H.: B-362, B-471  
Lifshits J.Z.: B-280  
Ligabue G.: C-026  
Lilic G.: C-045  
Lim H.J.: C-607  
Lim H.K.: B-378, C-220  
Lim J.S.: C-454  
Lim K.Y.: B-224, C-225  
Lim T.H.: B-112  
Lima M.: B-527  
Limucci N.: C-595  
Lin E.J.: B-549  
Lin X.: C-851  
Lin Z.-L.: B-110  
Lin Z.Y.: C-582  
Linda A.: B-048, B-287, C-447  
Lindebjerg J.: B-368  
Lindemayr S.: B-242  
Lindemayr S.G.: B-246  
Lindfors K.K.: B-170  
Lindley P.: C-308  
Lindner C.: B-406, B-407  
Ling H.-W.: B-425, C-851  
Link T.M.: A-156, B-463, B-466  
Linke A.: B-050  
Linke R.: C-343  
Linn J.: B-770  
Linnasmägi E.: A-374  
Linsenmaier U.: C-084  
Linzbach S.: B-236  
Lionetti I.: C-475  
Lionis C.: A-150  
Lipp M.E.B.: B-837  
Lisi D.: B-592, C-379, C-386  
Liss A.: B-188  
Liss P.: B-091  
Lissoni A.: B-036  
Litcheva Gueorguieva A.: C-533, C-579  
Liu B.: B-117, B-657  
Liu C.: B-523, C-068  
Liu H.: B-545  
Liu L.: C-848  
Liu S.: B-769  
Liu S.Y.: B-819  
Liu W.: C-364, C-904, C-905  
Liu X.: B-654  
Liu Y.: B-208, B-366, C-851  
Liyanage S.H.: C-779  
Llompert J.A.: C-738  
Llopis E.: B-138  
Llopis Sanjuan E.: C-880  
Lo Re G.: C-159, C-176, C-421, C-450,  
C-575  
Lobo J.C.: C-530  
Lobo L.: C-823  
Lobrich M.: B-294, C-177, C-323  
Locatelli M.: A-016, A-287, A-363  
Lockwood G.: B-038  
Lodemann K.-P.: B-643  
Loewe C.: B-686  
Loffroy R.: B-335  
Loggitsi D.: C-628, C-643  
Loh P.: B-828  
Lohbeck S.: B-662  
Lomas D.J.: C-003  
Lombardi G.: B-371, C-154  
Lombardi R.: C-106, C-107  
Lombardo P.: C-443  
Londero V.: B-048, B-287, B-492  
Long Jr. R.C.: C-918  
Lönnemark M.: C-254  
Loose R.W.R.: B-050  
Lopera J.: C-569  
Lopes L.: C-004, C-472  
López Barea F.: C-658  
Lopez Ferrer P.: C-237  
López Gutiérrez J.C.: C-817  
Lopez M.: C-054, C-055, C-136  
Lopez-Botet B.: C-273, C-705, C-787  
Lopez-Carreira L.: C-739  
López-Celada S.: B-560  
López-Pérez E.: C-413  
López-Santamaría M.: C-804  
López-Tomassetti Fernández E.: C-601  
Lorenzen J.: C-629  
Lorenzen M.: C-629  
Lorenzen S.: B-624  
Lorenzo A.: C-264  
Lorenzon M.: B-048  
Loria P.: C-026  
Losada M.: B-339  
Losio C.: B-027, B-288, B-569  
Lötjönen J.: C-149  
Lott C.W.: C-198  
Lottes A.: B-472  
Lotz J.C.: B-023, C-148  
Louis M.: A-028  
Loukanov T.: B-521  
Lourbakou A.: C-522, C-535  
Loureiro J.: C-071, C-530  
Louvet M.: B-427  
Lovász R.: B-833  
Løvblad K.-O.: D-20  
Lowther E.L.: B-307, B-793  
Lu B.: B-737  
Lu S.: B-542  
Lu Z.M.: B-035  
Lubbers D.D.: B-079, B-392  
Luberto L.: C-552  
Luca A.: C-573  
Lucarini S.: C-650  
Lucchesi P.: B-474, B-682, C-024,  
C-155, C-339, C-855, C-897  
Luciani G.: C-521  
Luciani M.L.: C-088, C-101  
Lucic M.A.: C-751  
Lucidarme O.: B-152, B-361, C-303  
Lüdemann L.: B-743  
Ludwig U.: B-398  
Luijten P.: B-399  
Lukács L.: B-730  
Lukas C.: C-748  
Lukken A.: A-374  
Lull J.J.: C-750  
Luna A.: C-925  
Lundberg N.: A-280  
Lundberg S.: B-801  
Lunkeit S.: B-581  
Luo B.N.: B-549  
Luo T.: C-760  
Lupattelli L.: C-898  
Lupo P.: B-231  
Luppi G.: B-566  
Lutomsky B.: B-232  
Lutz A.M.: B-350  
Luybaert R.: B-488  
Lv F.: C-760  
Lyadov K.V.: C-593  
Lyburn I.D.: C-920  
Lynch T.: C-239

Lyon S.: *B-837*Lyon X.: *B-324, B-827***M**Ma C.L.: *C-742*Ma E.-S.: *B-825*Ma H.: *B-761*Ma R.: *C-068*Ma T.: *B-769*Maas M.: *A-473*Mac G.: *C-532*Macaluso E.: *B-541*Macchiarella V.: *C-048*MacDonald S.: *A-433*Machida H.: *C-170, C-858*Machida T.: *C-772*Macià F.: *C-138*Maciejewski R.: *C-268, C-511*Mack M.G.: *B-051, B-060, B-180,  
B-241, B-386, B-451, B-452, B-453,  
B-457, B-652, B-693, B-694, B-700*MacKinnon J.: *C-634*Mademli M.: *C-628*Maderwald S.: *B-240, B-258, B-411,  
B-420, B-661, B-662, B-663, B-668*Madleitner R.: *B-625, B-799*Madureira A.J.B.S.: *A-183*Maeda F.: *C-171*Maetani Y.: *B-143, C-057*Maffei E.: *B-445, B-446, B-447, B-735,  
C-183, C-184, D-12*Maffi P.: *B-027, B-569*Mage G.: *C-341*Magerkurth O.: *B-408*Maggi C.: *B-758*Maggi F.: *B-318, B-436*Maggi S.: *C-859*Magnaguagno F.: *B-788*Magnusson A.: *A-359, B-188, C-254,  
C-408*Mah Y.H.: *C-309*Mahachie John J.M.: *B-139*Maher M.M.: *C-241, C-477*Maheshwari E.: *B-038*Mahfouz A.E.: *B-156*Mahnken A.H.: *B-379, D-16*Maia R.: *C-213, C-216, C-536*Maie Y.: *C-876*Maier B.: *B-451, B-457*Maier M.: *A-152*Maier S.: *B-468*Maieron M.: *B-544*Mainar Turón A.: *C-551, C-559*Maintz D.C.: *B-684*Maisto F.: *C-443*Majdisova Z.: *C-647*Majos A.: *C-752, C-757*Makaiova I.: *C-718*Makalanda L.: *C-504*Makino N.: *C-520*Maksimovic O.: *C-077*Maksimovic R.: *C-045*Makuc E.: *B-202*Malagari K.: *B-331, B-562, C-231*Malago R.: *B-269, D-28*Malago' R.: *B-114*Malattia C.: *B-788*Málek V.: *C-802*Malet Munté A.: *C-352*Malhotra A.: *C-504*Mali W.P.H.: *B-399*Mali W.P.T.M.: *B-289, B-442, C-400*Malich A.: *B-434, B-745, C-109, C-497*Malik A.: *C-620*Malizia G.: *C-575*Mallarini G.: *B-185, B-279, C-893*Mallol X.: *C-378*Mallouhi A.: *B-008*Malone D.E.: *B-727*Malone J.: *A-456*Malosio M.L.: *B-027*Maly Sundgren P.C.: *A-315*Mamisch T.C.: *B-576, B-577, B-579,  
B-580, D-24*Mamone G.: *C-573*Mañas J.: *C-652*Mañas Uxó J.: *C-093, C-437*Manavelan L.: *C-700*Manca A.: *B-276, B-456, B-698, C-389*Mancardi G.L.: *C-747*Mancino S.: *B-606, B-621, B-703*Mandal M.K.: *B-543*Mandapal T.: *B-105*Manenti G.: *B-606, B-621, B-703*Manfredi R.: *B-413, B-584, B-586,  
B-588*Mang T.: *A-333, B-203*Manganaro L.: *B-157, B-498, B-617,  
B-758*Mangasree R.: *B-204*Mangia M.: *B-682, C-146*Mangiafico S.: *B-458*Mangili P.: *C-357, C-361, C-382*Mangioni C.: *B-036*Maniatis P.: *C-056*Maniega R.: *C-608*Manisali M.: *C-854*Manjón J.V.: *C-750*Manjon P.: *C-666, C-674*Mankad K.: *C-203*Manke D.: *B-320*Mann R.M.: *C-105*Mannelli L.: *B-339, C-065*Mannini A.: *B-109*Mantatzis M.: *C-879*Mantiuk R.: *B-813*Mantovani W.: *B-584*Manzanares R.: *C-705, C-787*Manzano M.: *C-273, C-705, C-787*Manzella A.: *C-316, C-464, C-481*Mao L.J.: *B-549*Marangos N.: *B-764*Marano G.D.: *B-628*Marano P.: *B-792*Marano R.: *B-441, B-646, B-731*Marantz P.: *C-829*Marashi A.: *B-502*Maraviglia B.: *B-461, B-669*Marc B.: *C-532*Marchal G.: *B-045*Marcheix B.: *B-776*Marchenko N.V.: *C-349*Marchioro U.: *B-459*Marchisio F.: *C-125*Marchisio P.: *C-449*Marci V.: *B-249, B-250*Marcia S.: *B-279*Marco de Lucas E.: *C-604, C-682,  
C-799, C-800*Marco Sanz A.: *C-528*Marcotte C.: *C-347*Marcus C.: *B-736, C-393, C-532*Marek I.: *C-417, C-423*Marelli P.: *B-374*Maresca G.: *C-517, C-521*Maresca L.: *B-129*Margari- Sifacsa Z.: *B-674*Margariti P.N.: *B-421, B-550*Mariani D.: *B-460*Marie J.P.: *B-409*



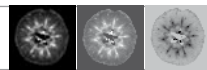
- Marie P.-Y.: A-408  
Marigliano C.: B-777  
Marin D.: B-016, B-144, B-355, B-711,  
C-078, C-079  
Marin F.: B-551, B-560  
Marinček B.: A-114, B-350, B-369,  
B-370, B-483, B-484, C-166  
Marini C.: C-097, C-100  
Marini S.: B-279  
Mariño Enriquez A.: C-237  
Maris T.G.: B-192, B-393, C-027  
Mariscal A.: B-284  
Maristany M.: C-138  
Mark P.: B-100  
Markl M.: B-309  
Marksteiner J.: C-776  
Marlovits S.: B-576, B-577  
Marocco M.C.: B-329  
Maroldi R.: A-078  
Marom E.: C-280  
Maroto A.: C-409  
Marotta E.: B-777  
Marquetting H.A.: B-077  
Marques A.: C-639  
Marques L.: B-655  
Marra F.: C-017  
Marrone G.: C-573  
Marroni C.A.: C-013  
Marsault C.: B-155, C-931  
Marshall N.: A-317  
Marshall S.: D-61  
Marshall T.: A-200  
Martánez de Aragán A.: C-719, C-778  
Martel J.: B-455  
Marthinsen P.B.: B-505  
Martí M.: C-482  
Martí-Bonmatí L.: A-294, C-340,  
C-506, C-625, C-644, C-746, C-750,  
C-792  
Martin C.: C-826  
Martin D.R.: B-097, B-354  
Martín Hervás C.: C-658, C-817  
Martin L.: C-604, C-800  
Martín López E.: C-175, C-342  
Martín P.: B-189, C-492, C-538, C-666,  
C-812, C-824  
Martin R.: B-690  
Martincich L.: B-615  
Martineau I.: C-044  
Martinenghi C.: B-149  
Martínez A.: C-196  
Martínez Alvarez Y.: C-414, C-476  
Martínez C.: C-141, C-142, C-488  
Martínez de la Cuesta A.: A-046  
Martínez Fernández M.: C-692  
Martínez Galdamez M.: C-499, C-703,  
C-713  
Martínez Guillamón C.: C-880, C-881,  
C-882  
Martínez J.: C-138  
Martínez M.J.: C-413  
Martínez Montalbán M.: C-528, C-637  
Martínez Montes J.L.: C-577  
Martínez R.: B-636, C-937  
Martínez Rubio C.: B-495  
Martínez X.: C-136  
Martínez-Berganza M.T.: C-334, C-527  
Martínez-Bisbal M.C.: C-746  
Martínez-Granados B.: C-746  
Martini A.: B-788  
Martini N.: B-492  
Martinkovicová L.: B-732  
Martinoli C.: A-448, B-009, B-137,  
B-788, C-354, D-65  
Martins R.: C-150  
Martirosian P.: B-557  
Martynov B.: B-216  
Marusic P.: B-482  
Maruzzelli L.: C-573  
Marzani S.: B-194  
Marzi I.: B-451, B-457  
Mas A.: C-738  
Mas J.-L.: C-912  
Masao Y.: B-310  
Masciocchi C.: B-325  
Masek M.: B-469  
Maseri A.: B-687  
Mashiach R.: B-152  
Masi R.: B-210  
Masoud O.: B-303  
Messarino F.: C-354  
Masselli G.: B-728  
Massmann A.: B-642  
Mastorakou I.: A-331  
Mastrangeli R.: B-606  
Masuda N.: C-095  
Masulovic D.: C-490  
Masumoto T.: C-087  
Mata Duaso J.M.: C-208  
Matejovic M.: B-609  
Mateos Goñi B.: C-515  
Mateos J.M.: C-749  
Máthé Z.: C-572  
Mather R.: B-299  
Mathers S.A.: B-537  
Mathias N.: B-568  
Mathieu E.: B-539  
Mathis G.: C-283  
Matkovich A.: B-318  
Matoba M.: B-364  
Matos C.: A-295  
Matsaidonis D.: C-377, C-938  
Matsubara H.: C-428, C-429  
Matsuda I.: C-772  
Matsueda K.: C-102  
Matsuhashi T.: C-301  
Matsui O.: C-006, C-290  
Matsuki K.: C-645  
Matsumoto A.H.: B-838  
Matsumoto J.: C-706  
Matsumoto M.: C-846  
Matsumoto S.: B-106, B-817, C-053,  
C-238, C-730, C-924  
Matsunaga N.: C-653, C-654  
Matsuo Y.: C-327  
Matsusako M.: C-327  
Matsushima M.: C-033  
Matsushima S.: C-031  
Matsushita H.: B-782  
Matsuura M.: B-466  
Matsuura N.: C-840, C-889  
Matsuura Y.: C-290  
Matsuzaki K.: C-337, C-356  
Mattace Raso M.: C-120  
Matthay K.K.: C-838  
Mattsson P.: B-801  
Matzek W.K.: B-598  
Maubon A.J.M.: B-039  
Mauch C.: C-497  
Mäurer M.: A-426, B-030  
Mayby D.: C-245  
May A.E.: B-235, B-239, B-448  
Mayer F.B.: B-750, C-603  
Mayer H.: C-603  
Mayer H.P.: B-750  
Maynar M.: B-127  
Mayo J.R.: A-455  
Mayolas N.: C-707  
Mazonakis M.: B-634, B-785  
Mazzarella G.: C-866

- Mazzarola A.: *B-656*  
 Mazzei F.: *C-898*  
 Mazzei M.A.: *B-109, C-898*  
 Mazzeo S.: *C-062, C-063*  
 Mazzie J.P.: *C-695, C-698*  
 Mazzocchi C.: *B-316*  
 Mazzone G.: *C-809*  
 Mazzotta D.: *C-097, C-100*  
 Mc Sweeney S.E.: *C-241*  
 McCain J.B.: *B-628*  
 McCall I.W.: *A-293*  
 McCarthy P.: *C-523*  
 McCollough C.H.: *B-295, B-654*  
 McDonald D.M.: *B-028*  
 McDonald S.: *C-245*  
 McDonnell O.: *C-885*  
 McEwan A.: *B-805*  
 McGann G.: *C-920, C-921*  
 McGann G.M.: *C-191*  
 McKenna B.: *C-600*  
 McKenzie G.A.: *B-537*  
 McLennan G.: *B-820*  
 McLeod R.: *C-289*  
 McNally E.G.: *A-012*  
 McNally O.: *C-239*  
 McNitt-Gray M.F.: *B-295, B-297*  
 McParland P.: *C-205, C-207*  
 McSweeney S.: *C-477*  
 McWilliams S.: *C-477*  
 Meaney J.F.M.: *A-461, C-369, C-500, C-932*  
 Mechtcheriakov S.: *C-776*  
 Meckel S.: *B-309*  
 Méder J.-F.: *C-912*  
 Medina C.: *C-812, C-824*  
 Medioni J.: *B-602*  
 Medov L.: *B-060*  
 Medrano J.: *A-047*  
 Medrano Peña J.: *C-551, C-559*  
 Medrano Seoane G.: *C-794*  
 Meehan C.: *C-224*  
 Meersschaert J.S.: *B-088*  
 Meeson S.: *B-292*  
 Megahed A.S.: *B-644*  
 Megele K.: *B-255*  
 Mehiri S.: *C-513, C-919*  
 Mehndiratta A.: *B-073, B-504, B-677*  
 Mehrabi S.: *B-584, B-586, B-588*  
 Mehrain S.: *B-343*  
 Mehrotra P.: *B-311*  
 Mehta P.: *B-247*  
 Meier R.: *B-023, B-026*  
 Meijboom W.B.: *C-164*  
 Meijer A.: *B-292*  
 Meijering E.: *B-004*  
 Meila D.: *B-082*  
 Meimarakis G.: *B-068*  
 Meindl T.: *B-383, C-084, C-681, C-727, C-745*  
 Meis S.: *B-694*  
 Meissner M.: *B-215*  
 Meister M.: *B-814, B-815*  
 Mekhloufi E.: *A-276*  
 Melão L.: *C-005, C-085, C-651*  
 Mellado J.M.: *C-334, C-527*  
 Melloul E.: *C-080*  
 Meloni F.: *C-583, C-585, C-590*  
 Meloni G.B.: *C-583, C-585, C-590*  
 Meloni T.: *C-449*  
 Memarsadeghi M.: *B-611*  
 Menchini L.: *B-318, B-436*  
 Mende K.: *B-270, B-629*  
 Mendes V.: *C-066*  
 Mendes V.S.: *C-927*  
 Méndez C.: *C-141, C-142*  
 Mendiola Arza J.: *C-484*  
 Menezes L.: *B-113*  
 Meng Q.F.: *B-549*  
 Meng X.S.: *B-131*  
 Mennini M.L.: *B-679, C-247, C-248, C-249, C-250*  
 Mentzel H.-J.: *B-341, B-767, C-673*  
 Menu Y.: *A-085, A-348, A-404*  
 Menzel H.-J.: *B-304*  
 Merchant N.: *B-829*  
 Mereddy P.K.R.: *B-006*  
 Mereles D.: *B-818*  
 Mereu M.: *C-221*  
 Merges R.: *B-300, B-739, B-761, C-144*  
 Merino A.: *C-465*  
 Merino X.: *C-346*  
 Merino-Casabiel X.: *C-690*  
 Merkle E.M.: *C-078, C-079*  
 Merlet N.: *B-049*  
 Merli M.: *C-154*  
 Merola S.: *C-426, C-471*  
 Meroni R.: *B-151*  
 Mershina E.A.: *C-151*  
 Mervaala E.: *B-804*  
 Mescam M.: *C-032*  
 Messalli G.: *B-445, B-446, B-447*  
 Messina M.: *B-771*  
 Messner H.: *B-001*  
 Mester Á.: *C-451*  
 Metelko M.: *C-075, C-197, C-262*  
 Metz C.T.: *B-197*  
 Metz K.A.: *C-581*  
 Metz S.: *B-624*  
 Meurrens P.: *B-506*  
 Meuse M.A.: *B-838*  
 Mews J.: *B-504*  
 Meyer B.C.: *B-184, B-190*  
 Meyer G.P.: *C-148*  
 Meyer M.: *C-870*  
 Meyer P.: *C-663*  
 Meyer-Wittkopf M.: *B-391*  
 Michael L.: *B-044*  
 Michaely H.: *B-518*  
 Michaely H.J.: *A-247, B-601, B-643, B-645*  
 Michell M.: *A-101*  
 Michimoto K.: *C-495*  
 Midiri M.: *C-020, C-048, C-159, C-165, C-176, C-229, C-450, C-575*  
 Midulla M.: *B-776*  
 Mielekamp P.: *C-591*  
 Mihai G.: *B-666*  
 Mihara F.: *C-735*  
 Mikami Y.: *B-233, B-683*  
 Miki H.: *C-721, C-765*  
 Miki Y.: *C-529*  
 Mikulik O.: *B-745*  
 Mikulik S.: *B-434, B-745*  
 Milazzo M.: *C-573*  
 Mildenberger P.: *A-072, B-507*  
 Milenkovic R.: *C-773*  
 Miles K.A.: *A-281*  
 Milewska-Bobula B.: *C-819*  
 Millan J.M.: *C-492*  
 Miller S.: *B-235, B-239, B-415, B-448, B-557*  
 Milone F.: *B-371*  
 Milosevic M.: *B-038*  
 Mimura T.: *B-342, B-631*  
 Minaifar N.: *B-826*  
 Minardi R.: *C-809*  
 Minowa Y.: *C-706*  
 Mir N.: *B-040*  
 Miraglia R.: *C-573*



- Miralles M.: C-812, C-824  
Miranda L.: C-334, C-527  
Mirarchi M.G.: B-720  
Mirka H.: B-609  
Miroslaw K.: C-158  
Mirvis S.: C-698  
Mischenko A.V.: C-349  
Mishra A.: B-195  
Misra B.K.: C-710  
Misselt A.: C-194  
Misselt A.J.: C-143  
Mita Y.: C-171  
Mitake T.: B-388, B-759  
Mitjana R.: C-261  
Miucin-Vukadinovic I.: C-438  
Miwa O.: B-303  
Miyagi Y.: C-102  
Miyake M.: C-411  
Miyamoto K.: B-310  
Miyatani Y.: C-415  
Miyauchi H.: C-029  
Mnif N.: C-513, C-919  
Mochizuki K.: C-675, C-781  
Mochizuki T.: C-236, C-252, C-721, C-765  
Moczova J.: C-718  
Mödder U.: B-792  
Modi S.: B-543, B-546  
Modigliani G.: B-194  
Moeninghoff C.: B-665, B-670  
Moerman W.P.: B-639  
Mohammed N.A.N.: B-241, B-336, C-843  
Mohamram A.: B-530  
Mohan C.: C-548  
Möhlenkamp S.: B-558  
Mohr A.: B-084  
Mokali I.: C-879  
Mokhtari S.: B-427  
Molina Nuevo J.D.: C-577  
Molinari F.: B-318  
Moll A.: C-738  
Mollet N.R.: A-151, B-114, B-445, B-446, B-447, C-164, C-184  
Mollet N.R.A.: B-197  
Molnar A.: B-832  
Momose M.: C-052  
Mompoin D.: B-427  
Mondal D.: C-315, C-942  
Monden N.: C-903  
Monedero E.: C-834  
Mones L.: C-378  
Monetti R.: B-466  
Monmany R.: C-261  
Monmany-Badia R.: C-690  
Mönninghoff C.: B-668  
Monsky W.: B-170  
Monteil J.: B-039  
Monteiro S.: C-150  
Montemurro F.: B-615  
Montes Fernandez M.: C-476  
Montisci R.: B-185  
Montorsi P.: B-062  
Moon W.K.: B-046, B-166, B-167, B-283, B-285  
Moonen C.T.: B-025  
Mora G.: C-215  
Morales C.: C-910, C-923  
Morana G.: C-047  
Moratal D.: C-625, C-792  
Morcaldi D.: B-260  
Morcos S.K.: A-110, D-14  
Moreno R.: B-776  
Moret J.: C-591  
Morgan G.: B-690  
Morganti A.: C-365  
Morgen N.: B-273, B-275  
Morhard D.: B-518  
Mori H.: C-053, C-238, C-560, C-730, C-780, C-924  
Moriarty J.M.: C-549, C-894  
Morice P.: A-264  
Morigoni V.: C-457  
Morimoto T.: C-411  
Morisawa N.: C-336  
Morishima Y.: C-861  
Morita S.: C-170, C-858  
Morita T.: C-123  
Morofke D.: B-365  
Morón S.: C-817  
Morozov S.P.: C-635  
Morra A.: C-246  
Morra L.: B-363  
Morreira R.: B-097  
Morrin M.: C-418  
Morris E.: C-317  
Mortensen N.M.: B-365  
Morvan G.: C-688  
Mosca F.: C-063  
Moscariello A.: B-646  
Moschouris H.: C-377, C-938  
Moser T.: B-278, C-542, C-580, C-621  
Moss J.: B-570  
Mosterd A.: B-442  
Motamed A.: B-059  
Motoori K.: C-761  
Motton M.: B-584, B-586, B-588  
Mouchtouri I.: C-701  
Mouloupoulou L.: B-674  
Mourelto S.: C-015  
Mouri Y.: B-759  
Mourou M.-Y.: A-478  
Moussa S.: A-358  
Mousseaux E.: B-324, B-827  
Moutinho R.: C-419  
Movassaghi B.: B-640  
Moyses J.: B-570  
Muacevic A.: A-100  
Mueller H.: B-379  
Mueller M.M.: B-030  
Mueller P.R.: A-376  
Mueller S.: C-727  
Mueller W.M.: B-217  
Mueller-Lisse U.G.: B-481, B-489  
Mueller-Lisse U.L.: B-383, B-489  
Mueller-Mang C.: B-054, B-203, B-305  
Muetzel E.: B-578  
Muglia V.F.: B-616  
Mühlenbruch G.: B-020  
Mukerjee K.: C-678  
Mullan C.P.: C-239  
Müller C.: B-358, B-693  
Müller D.: B-463, B-466  
Müller M.: B-835  
Muller R.: D-73  
Müller S.: B-822  
Müller V.: C-321  
Müller-Hülsbeck S.: A-481  
Mulukutla R.: B-209, C-793  
Mun S.-H.: B-286, B-755  
Munari A.: B-151  
Munneke G.J.: A-482, C-592  
Muntaner-Gimbernat L.: C-633  
Munuera J.: C-709  
Mur E.: B-348  
Murakami Y.: C-086  
Muramatsu Y.: C-845, C-876  
Murataka T.: C-433  
Muraro E.: C-449

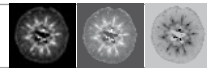
- Murata K.: *C-086, C-563*  
 Murayama S.: *C-547*  
 Murayama T.: *C-171*  
 Murgod U.: *B-810*  
 Murolo C.: *B-137*  
 Murphy D.T.: *C-549, C-894*  
 Murphy G.: *C-500*  
 Murphy R.C.: *C-720*  
 Murphy-Lavallée J.: *C-032*  
 Murray A.D.: *C-822*  
 Murray C.P.J.: *B-431*  
 Mut F.: *B-432*  
 Mutlu S.: *B-120*  
 Mützel E.: *B-633*  
 Muzj C.: *C-470*  
 Muzzio P.C.: *C-475*  
 Mylene T.: *C-223*  
 Mylona S.: *C-522, C-535, C-594*
- N**  
 N V.: *B-204*  
 Nabeya Y.: *B-599*  
 Nada N.: *B-059, B-102, B-103, B-387, B-389, B-620, B-760, C-531*  
 Naef R.: *C-292*  
 Nagamachi S.: *C-039, C-050, C-458*  
 Nagamoto M.: *C-767*  
 Naganawa S.: *C-033, C-060, C-310, C-514, C-520*  
 Nagaoka S.: *C-828*  
 Nagareda T.: *C-236, C-252*  
 Nagata M.: *B-233, B-683*  
 Nagatani Y.: *C-563*  
 Nagel D.: *B-472*  
 Nagel H.-D.: *B-830*  
 Naggara O.: *C-912*  
 Naguib N.N.N.: *B-241, B-336, B-652, C-843*  
 Nahmias C.: *B-212*  
 Naidu M.: *B-204*  
 Naito H.: *B-064, B-081*  
 Nakada H.: *C-586*  
 Nakagami A.: *C-134*  
 Nakagawa T.: *B-012*  
 Nakai A.: *C-914*  
 Nakai G.: *C-322*  
 Nakaji S.: *C-706*  
 Nakajima H.: *B-683*  
 Nakajima M.: *D-39, D-42a*  
 Nakajima Y.: *C-706*  
 Nakajo M.: *C-050*  
 Nakamoto A.: *C-095*  
 Nakamoto M.: *C-433*  
 Nakamura A.: *B-388*  
 Nakamura K.: *C-171*  
 Nakane T.: *C-781*  
 Nakanishi J.: *C-251*  
 Nakanishi K.: *C-227, C-228*  
 Nakano S.: *B-759*  
 Nakanuma Y.: *C-006*  
 Nakashima T.: *C-514*  
 Nakaura T.: *C-034, C-040, C-345, C-405, C-833, C-902*  
 Nakayama T.: *C-675*  
 Nakayama Y.: *C-833*  
 Nakazawa T.: *B-064, B-081, C-828*  
 Nam K.J.: *C-366*  
 Namimoto T.: *C-034, C-040, C-345, C-405, C-833, C-902*  
 Nani R.: *C-557*  
 Nano R.: *B-569*  
 Naoko T.: *B-303*  
 Napel S.: *B-312*  
 Napoli A.: *A-025, B-417, B-593, B-597, B-777, C-181, C-182, C-442, C-463, C-856, C-910, C-923*  
 Nappi J.: *B-364, B-475, B-479*  
 Narabayashi I.: *C-322*  
 Narayana A.: *B-214*  
 Narayanan P.: *B-142, C-329, C-394*  
 Nardin M.: *C-475*  
 Nardis G.: *B-564*  
 Nardis P.: *B-566, C-555*  
 Narita K.: *C-028*  
 Narushima K.: *B-591, B-599, C-029, C-416, C-427, C-428, C-429, C-489*  
 Nasoodi A.: *B-178*  
 Nassenstein K.: *B-240, B-322, B-553, B-558*  
 Nassini D.: *C-592*  
 Natale L.: *B-646*  
 Natrella M.: *C-449*  
 Natsika M.: *C-638*  
 Nava L.: *C-357, C-361, C-382*  
 Navab N.: *A-301*  
 Navallas M.: *C-674, C-719, C-778*  
 Navarro E.: *C-749*  
 Navas R.: *C-674*  
 Nayak S.: *C-592*  
 Nazar M.E.: *C-910, C-923*  
 Nedelcu C.: *C-931*  
 Nederkoorn P.J.: *B-090*  
 Neeman M.: *A-120, A-406*  
 Neff K.W.: *C-814*  
 Neff W.: *B-401, B-402*  
 Neitzel U.: *B-313, B-320*  
 Nelemans P.J.: *B-173*  
 Nelson R.C.: *A-250*  
 Nelting K.: *B-057*  
 Nemeo S.: *B-343*  
 Nemes B.: *B-832, C-572*  
 Németh A.: *C-572*  
 Nentwig T.: *B-184*  
 Neofitou G.: *C-295, C-786, C-874, C-884*  
 Neruda A.: *B-099*  
 Neto D.: *C-419*  
 Neuenschwander S.: *B-163*  
 Neufang A.: *B-121, B-122*  
 Neuwirth J.: *B-732*  
 Neves F.: *C-534*  
 Ng C.S.: *B-019*  
 Ng K.H.: *C-309*  
 Nghiem H.V.: *C-600*  
 N'Guyen B.: *C-032*  
 Nguyen S.: *B-556*  
 Nguyen S.A.: *B-076, B-443*  
 Ni Churrain C.: *C-477*  
 Ni H.: *B-423*  
 Ni Mhuircheartaigh J.: *C-223, C-224, C-280*  
 Nicholson A.: *A-017, A-135*  
 Nicol E.: *C-178*  
 Nicoletti R.: *B-149*  
 Nicoli F.: *B-194*  
 Nicotera P.: *C-596, C-606*  
 Nicotra S.: *C-470*  
 Nicoud F.: *B-776*  
 Niebecker R.: *B-352*  
 Niebler C.: *C-870*  
 Niederstadt T.: *B-416*  
 Niedmann J.: *C-634*  
 Niemann T.: *B-292, C-367*  
 Niendorf T.: *B-020*  
 Niessen W.J.: *A-190, B-069, B-197*  
 Nieto Baltar B.: *C-414, C-476*  
 Nihashi T.: *C-383*  
 Nikander R.: *B-467*  
 Nikapota A.: *C-436*  
 Nikas I.: *B-674*



- Nikita K.S.: C-089  
 Niklason L.: B-042, D-60  
 Nikolaidis P.: B-713  
 Nikolaou K.: A-211, B-014, B-068,  
 B-439, B-440, B-490, B-826, D-18  
 Nimiscad Study Group T.: B-441,  
 B-731  
 Ninomiya A.: C-914  
 Nir D.: B-152  
 Nishi Y.: B-200  
 Nishiguchi T.: C-675, C-781  
 Nishihara K.: C-338  
 Nishii R.: C-039, C-050, C-458  
 Nishiike S.: C-680  
 Nishimaki H.: C-116  
 Nishio A.: C-520  
 Nishiofuku H.: C-031  
 Nishitani H.: C-337, C-356  
 Nishiyama H.: C-087  
 Niskanen E.: B-804  
 Nitrosi A.: B-194  
 Nitta N.: C-086, C-563  
 Nizzo R.: B-009  
 Noble J.A.: B-168  
 Nocentini A.: B-610  
 Nocera V.: B-148, C-605  
 Noda M.: C-772  
 Noens L.: C-624  
 Nogami M.: B-101, B-106, B-817  
 Noguchi T.: C-735  
 Noguera J.J.: C-281  
 Nojiri K.: C-383  
 Nolte-Ernsting C.: B-486, B-487  
 Nolte-Ernsting C.C.A.: A-441, B-481  
 Nombela Cano L.: C-499, C-713  
 Nonni A.: C-089  
 Noo F.: B-297  
 Nordhøy W.: B-786, C-852  
 Nori J.: B-494  
 Norris D.G.: A-201, B-301  
 Norton V.: A-020  
 Noseworthy M.: B-708  
 Notarangelo F.: B-735  
 Notohamiprodjo M.: B-346, B-601,  
 B-650  
 Novellas S.: C-347  
 Novelline R.A.: A-199  
 Novikova E.G.: C-348  
 Novotny C.: B-054  
 Nowrousian M.R.: C-581  
 Ntai S.: C-535  
 Núñez A.: C-180  
 Nunoda S.: C-170  
 Nunziata A.: B-359, C-120, C-862  
 Nuyts S.: B-172  
 Nwachukwu C.: B-789
- O**  
 O Keffe S.: C-369  
 O Y.L.: B-292, B-511  
 Obata H.: C-828  
 Oberauer A.: B-799  
 Oberhoffer M.: B-826  
 Oberholzer K.: B-271, B-567  
 Oberson M.: B-124  
 O'Brien J.: C-350  
 O'Brien J.M.: C-805, C-815  
 O'Brien T.J.: B-802  
 Ocklenburg C.: B-020  
 Oda H.: B-342, B-631  
 Odani H.: C-706  
 Oefner B.: B-806  
 Oehler W.: B-745  
 Oehring H.: C-326  
 Offeciens E.F.: B-765  
 Offergeld C.: B-660  
 Offiah A.C.: B-789  
 Offner F.: C-624  
 Ogawa H.: C-033, C-060  
 Ogawa T.: C-251, C-338, C-495  
 Ogden K.M.: B-515, B-520  
 Ogino T.: B-399  
 Ogita M.: C-050  
 Ogresta F.: B-414  
 Oguz M.: C-072  
 Oh J.T.: B-529  
 Oh J.Y.: C-366  
 Oh J.-Y.: C-064  
 Oh S.N.: C-021, C-380, C-474  
 Oh S.W.: C-611, C-614  
 Oh Y.-W.: C-276  
 Ohadi B.: C-758  
 Ohara H.: B-631  
 Ohira G.: B-591, B-599, C-029, C-416,  
 C-427, C-428, C-429, C-489  
 Ohkawa H.: C-763  
 Ohlsson S.: B-193  
 Ohno K.: B-759  
 Ohno Y.: B-101, B-106, B-817  
 Ohta S.: C-563  
 Ohta T.: B-599, C-029, C-428, C-429  
 Ohtomo K.: C-796  
 Oikonomou A.: A-381, B-675  
 Okada F.: C-238  
 Okada N.: C-791  
 Okada T.: C-914  
 Okahara M.: C-730, C-780  
 Okajima K.: C-858  
 Okajima Y.: C-327  
 Okamura K.: C-383  
 Okano S.: B-782  
 Okano Y.: C-903  
 Okazaki T.: C-858  
 Okazumi S.: B-591, B-599, C-029,  
 C-416, C-427, C-428, C-429, C-489  
 Öksüz M.Ö.: B-011, B-627  
 Okubo T.: C-645  
 Oláh C.: B-833  
 Olazábal A.: C-067  
 Olazarán J.: C-749  
 Oldenburg A.: B-128, B-358  
 Olier J.: C-766  
 Olivera M.J.: C-273  
 Olivie D.: C-032  
 Ollivier L.: A-164  
 Olondo L.: B-803  
 Olsen D.A.: B-312  
 Olsen O.E.: A-420  
 Olson S.: B-013, C-822  
 Olszycki M.: B-647, C-757  
 Omoumi P.: C-435  
 Omram E.: C-018  
 Omran E.: B-262, B-528  
 Oncel D.: B-689  
 Oncel G.: B-689  
 Ong Y.-Y.: C-092  
 Onishi Y.: B-101, B-106, B-817  
 Ono K.: C-763  
 Onoda Y.: C-327  
 Onur E.: C-854  
 Oosterlinck W.: B-742  
 Oostveen L.J.: B-639  
 Oppenheim C.: C-912  
 Order B.: B-165  
 Ordoñez González C.: C-206, C-692  
 O'Regan D.J.: C-199  
 O'Regan K.: C-477  
 Orenes P.: C-719  
 Orgera G.: B-561, B-563, B-564,  
 B-566, C-555

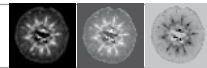
- Orlando G.: *C-026*  
 Örneholm P.: *C-254*  
 Orsi F.: *A-104, B-570*  
 Ortega G.: *B-430*  
 Ortega Martínez M.: *C-785*  
 Ortiz de Mendivil A.: *C-778*  
 Ortíz E.J.: *B-455*  
 Ortiz Morales C.M.: *C-206, C-692*  
 Orzan F.: *B-329*  
 Oshinski J.N.: *B-918*  
 Osimani M.: *B-465, B-592, C-379, C-386*  
 Osorio M.: *C-409*  
 Ossaba Vélez S.: *C-794*  
 Osterholz S.: *B-165*  
 O'Sullivan G.: *A-087*  
 O'Sullivan P.: *C-224*  
 Oswald D.: *C-886*  
 Ota S.: *C-086*  
 Ota T.: *B-591, C-416, C-427, C-489*  
 Otani K.: *B-064, B-081*  
 Otani T.: *B-384*  
 Otsuka K.: *C-170*  
 Otto G.: *B-567, B-717*  
 Ottobrelli A.: *C-552*  
 Ou P.: *B-324*  
 Oudard S.: *B-602*  
 Oudkerk M.: *B-010, B-074, B-077, B-079, B-226, B-227, B-317, B-392, B-442, C-210, C-211, C-212, C-302, C-312*  
 Ouhlous M.: *B-069*  
 Ovejero C.: *C-561*  
 Owens C.: *A-419*  
 Owsijewitsch M.: *B-073, B-504, B-677*  
 Oyen R.H.: *A-238*  
 Ozaki M.: *C-116*  
 Özaksoy D.: *C-854*  
 Özgün M.: *B-684*  
 Ozkan I.R.: *C-265, C-901*  
 Özkavukcu E.: *C-010*  
 Ozkur A.: *C-871*  
 Özpeynirci Y.: *C-929*
- P**  
 Pace C.: *C-397*  
 Pache G.: *B-313, B-398, B-658, B-722*  
 Pachinger O.: *B-740*  
 Pachmann C.: *D-45*  
 Packard N.: *B-170*  
 Padhani A.R.: *A-105, A-191, A-282, B-792*  
 Padley S.P.G.: *A-449, C-178*  
 Padovani R.: *A-368, C-868*  
 Padrón M.: *A-207*  
 Padula S.: *B-613, B-756, C-088*  
 Paganelli M.: *B-465*  
 Pagès M.: *C-410, C-480*  
 Pagliara E.: *C-043*  
 Pagonidis K.: *C-027*  
 Pahos K.: *C-388, C-518*  
 Paik D.S.: *B-312*  
 Pakula-Koscieszka I.: *C-819*  
 Palacios Bote R.: *C-785*  
 Palacios C.: *C-482*  
 Palczewski P.D.: *B-253*  
 Paley M.: *B-394, B-404, B-405, B-808*  
 Palkó A.: *A-039, C-420*  
 Palladas P.: *C-729*  
 Pallardó Calatayud Y.: *C-208*  
 Pallier K.: *B-092*  
 Pallisa E.: *C-277*  
 Pallucci S.: *C-062*  
 Pallwein E.: *C-390*  
 Pallwein L.: *B-607, C-390*  
 Palm F.: *B-091*  
 Palma F.: *C-733*  
 Palmer J.: *C-271*  
 Palmers Y.: *C-319*  
 Palmowski M.: *B-030, C-941*  
 Palominos G.: *C-807*  
 Palou J.: *C-395*  
 Palumbo A.: *B-445, B-446, B-447, B-735, C-183, C-184, D-12*  
 Pamies Guilabert J.: *C-266, C-493, C-891*  
 Pampana E.: *B-771*  
 Panagiotou I.: *B-562*  
 Panebianco V.: *B-400, B-592, C-379, C-386*  
 Panés J.: *C-410*  
 Panetta A.: *C-403*  
 Paniagua Bravo A.: *C-794*  
 Panizza P.: *B-288*  
 Paño B.: *C-687*  
 Panocchia N.: *C-517*  
 Panourgias E.: *C-638*  
 Pansini V.: *B-433, B-438*  
 Pantano P.: *B-541*  
 Paolantonio P.: *B-474, C-024, C-293, C-339, C-855, C-897*  
 Paoletta S.: *C-862*  
 Paolucci M.L.: *C-082*  
 Papadakis A.: *B-393, B-462, B-464, B-787*  
 Papadatos D.: *C-328*  
 Papadimitriou A.: *B-426*  
 Papadokostakis G.: *B-462*  
 Papadopoulos A.: *C-643*  
 Papadopoulou L.: *C-219*  
 Papagianopoulos S.: *C-729*  
 Papailiou J.: *C-056*  
 Papaioannou K.: *C-287*  
 Papakonstantinou O.: *C-083, C-628, C-643*  
 Papakonstantinou O.: *C-701*  
 Papanagioutou P.: *B-835*  
 Papanikolaou N.: *B-724, C-027*  
 Paparo F.: *B-260*  
 Papatriantafyllou J.: *B-426*  
 Papier S.: *C-342*  
 Papini G.D.E.: *B-231, C-325, C-365*  
 Papke K.: *B-082, B-083*  
 Pappas E.: *B-393*  
 Paraskevaidis E.: *C-406*  
 Pardo M.: *C-237*  
 Pardo Y.: *C-783*  
 Parente D.B.: *B-424*  
 Parianty I.: *D-68*  
 Paris Bueno J.: *C-881*  
 Parizel P.M.: *A-259, A-269, A-297, B-139, B-738, C-626, C-684, C-751*  
 Park B.K.: *B-746*  
 Park C.K.: *C-163*  
 Park C.-K.: *C-496*  
 Park C.M.: *B-225, B-671, C-220, C-230, C-462*  
 Park D.W.: *C-163*  
 Park D.-W.: *C-496*  
 Park E.-A.: *C-230*  
 Park E.S.: *C-118*  
 Park G.-W.: *B-286*  
 Park H.: *C-587*  
 Park H.S.: *B-147, B-353, B-594, C-453*  
 Park J.G.: *C-255*  
 Park J.H.: *B-334, B-695, C-896*  
 Park J.K.: *C-808*  
 Park J.-S.: *C-124*  
 Park J.S.S.: *B-470*  
 Park J.Y.: *C-430*  
 Park K.W.: *B-134*





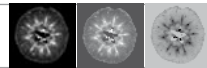
- Park S.: B-315  
Park S.B.: C-069  
Park S.H.: B-473  
Park S.J.: C-118  
Park Y.-M.: C-124  
Park Y.N.: B-529  
Parker J.R.: C-318  
Parkin D.E.: B-034  
Parlamentini A.A.: C-567  
Parmeggiani D.: C-605  
Parol N.: B-420  
Parola C.: C-397  
Parrón M.: C-803, C-804, C-817  
Parry A.: C-566  
Parsak C.K.: C-072  
Parulekar V.: B-168  
Pasariello R.: B-561  
Pasowicz M.: B-330, B-555  
Pasqua V.: B-775, B-778, C-899  
Pasquinielli F.: C-065  
Passariello R.: B-016, B-144, B-323, B-355, B-400, B-417, B-465, B-554, B-563, B-564, B-566, B-592, B-593, B-597, B-613, B-679, B-682, B-711, B-733, B-756, B-777, B-792, B-823, C-043, C-088, C-101, C-146, C-153, C-154, C-155, C-181, C-182, C-247, C-248, C-249, C-250, C-379, C-386, C-442, C-463, C-555, C-856  
Passynkov D.V.: C-119  
Pastor I.: C-803, C-804  
Pastore F.S.: B-669  
Pastorelli D.: C-475  
Pastrana Ledesma M.: B-605  
Pastrana M.A.: C-215, C-278, C-434  
Pasynkova O.: C-119  
Patak M.A.: B-721  
Pataka A.: B-675  
Patea R.L.: B-435  
Patel H.: C-351, C-702  
Patel J.: B-837  
Patel M.: C-351, C-702  
Patel R.: B-292  
Patel U.: C-355, C-592  
Patel Z.M.: C-710  
Paterson A.: A-278  
Patil U.D.: B-810, C-717, C-732, C-907  
Patkar D.P.: A-341  
Patriana M.: C-019, C-358  
Patriarca G.: C-940  
Patsios D.: B-221  
Patsopoulos H.: C-638  
Patsoura S.: C-535  
Pattacini P.: B-194  
Pattamapaspong N.: C-660, C-694  
Pattyn E.E.: B-088  
Paukovits T.M.: B-832  
Paul J.-F.: A-329, D-13  
Paul N.S.: B-829  
Paulesu E.: B-541  
Paulo G.: B-655  
Pavlica P.: A-239, B-527, C-376  
Payá E.: B-551  
Pazè F.: B-250  
Peccerelli N.: B-214  
Pecchi A.: B-494, C-125  
Peck D.: B-218  
Pedeutour F.: C-665  
Pedicelli A.: B-272  
Pedicioni F.: B-613, B-756, C-088, C-101  
Pedraza S.: C-686, C-937  
Peebles C.: C-205, C-207  
Peek G.J.: C-279  
Peer S.: C-655  
Peersman B.: B-005, C-626  
Peersman G.: B-005  
Peeters D.G.: B-088  
Pegios W.: B-031  
Peh W.C.G.: C-619, C-660, C-694  
Peitgen H.-O.: A-134, A-192  
Peláez I.: C-686  
Pelage J.-P.: A-019, A-059, B-135  
Pelaz Esteban M.: C-691  
Pelaz M.: C-604, C-682  
Peled N.: D-47  
Pelissier P.: C-663  
Pelle G.: B-400  
Pellegri A.: C-935  
Pellerin O.: A-387  
Pellon R.: C-055, C-604, C-656, C-800  
Peloschek P.: B-054  
Peñas F.: C-657  
Peng B.: B-807  
Peng W.: B-179, C-226, C-439, C-679  
Peng W.J.: B-752, C-135  
Peng Y.: B-525, C-813  
Pennisi F.: C-368, C-809  
Pepe M.: C-471  
Pepi M.: B-062  
Peralta A.: C-503  
Perandini S.: B-584, B-588  
Perea Palazón M.J.: C-222  
Perego P.: B-036  
Peregrin J.H.: A-015  
Pereira A.: B-221, C-162  
Pereira J.M.: C-005, C-071  
Pereira R.: B-651  
Pereira T.J.: C-160  
Perendreu J.: C-570  
Perera F.: C-712  
Perera S.: C-712  
Peres A.: C-617, C-676  
Perez A.: C-736  
Pérez Albelo T.: C-601  
Pérez Aranguena R.: B-605  
Pérez de Tudela A.: B-284  
Pérez Lago M.: B-270, B-629  
Pérez-Bárcena J.: C-738  
Perez-Bouza A.: B-130  
Pérez-Dueñas V.: C-482  
Pergantou H.: C-643  
Periaswamy S.: B-315  
Peric V.: C-773  
Perini L.: B-544  
Perisinakis K.: B-464, B-787  
Perona F.: B-132  
Perot V.: B-696  
Perotin S.: B-736  
Perri R.: B-541  
Perrone A.: B-157  
Perrone N.: B-033  
Perry N.M.: A-064  
Persiva O.: C-277  
Persson A.: C-296, C-307  
Persson P.: A-108, D-02  
Pertschy S.: C-148  
Pervaiz A.: B-789  
Pescarini L.: B-041, B-494, D-10  
Pesquer L.: C-663  
Pessis E.: C-648  
Peters F.H.: C-431  
Petersen J.: C-360  
Petnehazy O.: B-532  
Petracchini M.: C-389  
Petridis A.: C-729  
Petrovitch A.: B-341  
Petruzzi P.: B-774, C-558  
Petta S.: C-403  
Peungjesada S.: C-452

- Peutz-Kootstra C.: *B-173*  
 Pfannenberg C.: *B-011, B-351, B-627*  
 Pfeil A.: *B-341*  
 Pfirmann C.W.A.: *B-140, B-347*  
 Pflederer T.: *B-514*  
 Pfliederer S.O.R.: *B-496, C-114*  
 Phatak T.: *B-807*  
 Phelan E.: *C-805*  
 Phillips C.: *C-308*  
 Phillips S.: *D-08*  
 Phonkitkarun S.: *C-314*  
 Pi J.: *C-770*  
 Piano M.: *B-272*  
 Pianykh O.: *B-603*  
 Piatkowska-Janko E.: *C-752*  
 Piazza A.: *C-278, C-434*  
 Picado M.J.: *C-738*  
 Pichler B.: *B-212*  
 Picht C.: *C-080*  
 Piciucchi S.: *B-705*  
 Pickhardt P.: *B-480*  
 Pico-Fuster L.: *C-633*  
 Piedra Velasco T.: *C-691*  
 Pienkowska J.M.: *C-417, C-423, C-588*  
 Pietrzak P.: *B-647*  
 Pietsch H.: *B-094, B-096*  
 Piette J.-C.: *B-220, C-724*  
 Piludu F.: *C-517*  
 Pimenta M.: *C-058, C-126, C-689, C-797*  
 Pimentel F.: *C-126, C-127*  
 Pimentel-Martins M.: *C-473*  
 Pina J.I.: *C-798*  
 Pineda V.: *C-346*  
 Pineda-Sánchez V.: *C-690*  
 Pinker K.: *B-576, B-577*  
 Pintacuda G.: *C-475*  
 Pinto A.: *C-285, C-426, C-470, C-471, C-627*  
 Pinto E.: *C-936*  
 Pinto F.: *C-470*  
 Pintoffi J.: *C-077*  
 Piotrowska-Kownacka D.: *C-158*  
 Pipan P.: *A-422*  
 Piperopoulos P.: *C-786*  
 Pipitone V.: *B-129*  
 Pires J.: *C-073, C-213, C-216, C-274, C-536*  
 Pires M.F.R.: *C-823*  
 Pirovano G.: *B-415, B-796, C-318*  
 Pirrone R.: *C-450*  
 Piscaglia F.: *B-720*  
 Piscopo A.: *C-605*  
 Pistorio A.: *B-788*  
 Pitsoulakis G.: *C-810, C-836*  
 Pitton M.B.: *B-121, B-122, B-271, B-273, B-275, B-567, B-717, C-599*  
 Pizzi G.: *B-699*  
 Pizzolato R.: *C-895, C-935*  
 Plagou A.: *C-388, C-518*  
 Plaisier M.L.: *B-282*  
 Plancarte F.: *C-561*  
 Plancher C.: *B-162*  
 Planer D.: *B-635*  
 Plank C.M.: *B-203, B-305, B-579, B-580*  
 Plant G.: *B-837*  
 Plasencia Martínez J.M.: *C-206, C-692*  
 Plass A.: *B-822*  
 Plathow C.: *B-145*  
 Plathow D.: *B-145*  
 Platzek I.: *B-266*  
 Plazaola F.: *C-608*  
 Ploss C.: *B-457*  
 Plotas A.: *C-874*  
 Pluim J.P.W.: *B-319*  
 Plum T.: *B-130, B-766*  
 Pluot E.: *C-668*  
 Podda G.: *C-583, C-585, C-590*  
 Pohle T.: *B-590*  
 Poletti A.: *B-027*  
 Poletti P.-A.: *A-184*  
 Polettini E.: *B-728*  
 Poli A.: *B-502*  
 Politi G.: *C-448, C-491*  
 Politi L.: *C-065*  
 Politi M.: *B-834*  
 Polito R.: *B-272*  
 Polovincák M.: *B-732*  
 Pompili G.: *B-151*  
 Ponthold L.: *B-754*  
 Pontana F.: *B-438*  
 Ponticiello G.: *C-285*  
 Pontone G.: *B-062*  
 Poon P.: *C-320*  
 Popiela T.J.: *C-769*  
 Pöppel E.: *A-090*  
 Porcari P.: *B-669*  
 Porfiri L.M.: *B-758*  
 Porfyridis P.: *C-056, C-287, C-874, C-884*  
 Pörner M.: *B-082*  
 Portalez D.: *B-792*  
 Portefaix C.: *C-393*  
 Portugall A.: *B-694*  
 Pose G.: *C-807, C-939*  
 Pottel H.H.: *B-088*  
 Poulou L.: *C-578, C-597*  
 Pouquet M.: *B-039*  
 Pous E.: *B-753*  
 Powles T.: *B-608*  
 Pozdnyakov A.: *B-547*  
 Pozuelo C.: *C-378*  
 Pozuelo O.: *C-378*  
 Pozzi M.: *B-716, C-571*  
 Pozzi Mucelli R.: *B-269, B-360, B-584, B-586, B-588, B-751, C-059*  
 Pozzi-Mucelli F.: *C-935*  
 Pozzi-Mucelli R.: *A-158*  
 Pracros J.-P.: *A-276*  
 Prada R.: *C-193, C-488*  
 Pradella S.: *C-009*  
 Pradhan P.: *C-704*  
 Prakken N.: *B-828*  
 Prasad R.: *C-620*  
 Prasad V.: *C-611, C-614*  
 Prasanna S.: *C-704*  
 Praschinger A.: *A-472*  
 Prassopoulos P.K.: *B-675, C-074, C-697, C-879*  
 Prayer D.: *A-222, B-305, B-406, B-407, B-410*  
 Preda L.: *B-494*  
 Preisser A.: *C-115*  
 Prell D.: *B-632, C-870*  
 Prescott M.: *C-424*  
 Preto A.S.R.: *C-126, C-127, C-399, C-689, C-797*  
 Pretterkieber M.: *B-636*  
 Prevedoni M.S.: *C-687*  
 Prévost G.: *B-630*  
 Prewhal S.: *B-516*  
 Prieto C.: *C-803, C-804*  
 Prigent P.: *B-092*  
 Primak A.N.: *B-295, B-654*  
 Primrose B.: *B-178*  
 Principe F.: *B-269*  
 Priola A.M.: *B-249, B-250*  
 Priola S.M.: *B-249, B-250*  
 Prochnow D.: *B-743*  
 Profili S.: *C-583, C-585, C-590*



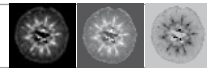
- Prokop M.: A-003, B-226, B-227,  
B-319, B-442, C-759
- Pronin I.N.: C-740
- Proscheck D.: B-453
- Prost R.W.: B-217
- Prot T.: C-080
- Providência L.A.: C-150, C-160
- Pruzincova L.: C-718
- Prvulovic N.: C-438
- Przegalinski J.: C-268
- Psychogios M.-N.: B-084
- Ptohis N.: B-562, C-287, C-295, C-874,  
C-884
- Pucci A.: C-555
- Puchner S.: B-067
- Puesken M.: B-183
- Pueyo J.: C-271
- Pueyo J.C.: C-233, C-258, C-878
- Pugliese F.: B-114, C-164, C-165
- Puglisi C.: C-368
- Pühls M.: B-489
- Puig Domingo J.: C-352
- Puig J.: C-686, C-826
- Puig M.: C-519
- Puig S.: C-687
- Pumar J.M.: C-739, C-775, C-922
- Punwani S.: B-032
- Pusceddu C.: C-583, C-585, C-590
- Pustovitova T.S.: C-151
- Putz R.: B-578
- Putzer D.: B-625, B-799
- Putzki N.: B-661
- Puzhevsky A.: C-906
- Q**
- Qi H.-T.: B-300, C-887
- Qi J.: B-306, B-423, B-468, B-571,  
B-574
- Qi W.: B-296, C-841
- Qi Z.: B-706, B-707
- Qian L.: C-035
- Qiao S.B.: B-737
- Qin W.: B-300, C-887
- Qu J.: B-548, C-737
- Quaghebeur G.: C-720
- Quagliarini A.: C-632
- Quaia E.: B-610, B-719
- Quattrocchi C.C.: B-158, B-705
- Querol Pascual R.: C-785
- Quesson B.: B-025
- Quick H.H.: A-218, B-240, B-411,  
B-418
- Quick P.: C-296
- Quiles A.M.: C-892, C-937
- Quintana F.: C-604, C-799
- Quintero J.C.: C-015, C-067
- Quintian C.: C-395
- R**
- Raatschen H.J.: B-612
- Raatschen H.-J.: B-648
- Rabellino M.: B-127
- Rabuffi P.: B-564
- Raby N.: A-173
- Rachapalli V.: C-131, C-381, C-468,  
C-678
- Racine-Parret L.: B-784
- Radosevic A.: C-714
- Radtke A.: B-581
- Radü E.-W.: A-413, B-309
- Rafaelsen S.R.: B-368
- Rago T.: D-41
- Rahim R.: C-502
- Rahimian E.: C-758
- Railton N.: C-207
- Raimondi M.T.: B-132
- Raimondi V.: B-259
- Rainer C.: B-754
- Raininko R.: B-801
- Raio L.: B-391
- Raj J.: C-240
- Raj S.B.: B-543
- Rajasekharan S.: B-113
- Rajashanker B.: C-424
- Rajhi H.: C-513, C-919
- Ralleigh G.: B-161
- Ramadan T.: C-280
- Ramalho M.: B-141
- Ramalho M.I.: B-653
- Ramamurthy S.: C-131, C-381, C-468,  
C-678
- Raman V.: C-192
- Ramanzin A.: C-282
- Ramesh C.N.: C-636
- Ramírez J.: C-222, C-943
- Ramirez-Escobar A.: C-637
- Rammohan K.: B-664, B-666
- Ramón E.: C-925
- Ramos A.: C-708, C-736
- Ramos I.: C-399
- Ramos Lopez P.: C-528
- Rampoldi A.: B-570
- Ramundo V.: B-371
- Raposo I.: C-141, C-142
- Raptopoulos V.: B-603
- Rasero M.: A-277
- Rashid S.: C-131, C-381, C-678
- Rashid S.H.: C-468
- Räth C.: B-466
- Rathmann R.: D-32
- Ratib O.: B-191, B-198, B-199
- Ratnam L.A.: C-592
- Ratti C.: C-649
- Rau P.: C-080
- Rau P.R.: C-556
- Raupach R.: B-293, B-638, B-654
- Ravagnani P.: B-062
- Ravazzolo N.: B-617
- Ravelli A.: B-788
- Ravelli S.: B-687
- Ravenel J.G.: B-111
- Ravuri P.: B-204
- Raw D.: C-455
- Raya J.G.: B-068, B-346, B-573,  
B-578, B-601
- Raza A.: C-659
- Rea D.: C-805
- Reale C.A.: B-771
- Rebuzzi M.: B-461
- Recaldini C.: C-606
- Receveur K.J.G.: B-839
- Recheis W.: C-244
- Rechicchi G.: B-036
- Redheuil A.: B-324, B-827
- Redpath T.W.: C-822
- Reekers J.A.: A-172
- Rees M.R.: A-330
- Refsum L.A.: B-786
- Regge D.: B-276, B-363, B-456, B-615,  
B-698, C-389
- Regier M.: B-486, B-487
- Regine G.: C-397
- Rehbein H.: B-743
- Rehder P.: C-360
- Rehman A.: C-886
- Reiber J.H.C.: B-078
- Reichart B.: B-826
- Reichenbach J.R.: B-304, B-614,  
C-115, C-754
- Reig S.: C-749

- Reilich P.: *B-002*  
 Reimann A.: *C-186*  
 Reimer D.: *B-093*  
 Reimold M.: *B-531*  
 Reiner B.: *B-538*  
 Reiner C.S.: *B-350, B-369*  
 Reinhardt M.: *B-030*  
 Reinhold C.: *A-032*  
 Reis C.: *C-797*  
 Reis Costa F.: *C-467*  
 Reis J.: *C-073, C-216, C-536*  
 Reischig T.: *B-609*  
 Reiser M.F.: *A-149, A-153, B-002, B-014, B-068, B-080, B-126, B-277, B-333, B-346, B-383, B-439, B-440, B-472, B-489, B-490, B-518, B-559, B-573, B-578, B-601, B-633, B-643, B-645, B-650, B-688, B-781, B-816, B-826, C-084, C-681, C-727, C-745*  
 Reisinger C.: *B-419*  
 Reiss-Zimmermann M.: *C-928*  
 Reiter M.: *B-067*  
 Reiter-Theil S.: *A-268*  
 Reith W.: *B-834, B-835*  
 Reitmeier F.: *B-052*  
 Reizine D.: *C-534*  
 Remme H.: *B-215*  
 Remollo S.: *C-686, C-937*  
 Remonda L.: *B-302, B-391*  
 Remorgida V.: *B-729*  
 Rémy J.: *A-345, B-107, B-321, B-433, B-438, B-812*  
 Rémy-Jardin M.: *A-210, A-345, B-107, B-321, B-433, B-438, B-812*  
 Ren H.: *C-744*  
 Ren Y.: *B-035*  
 Renema K.J.: *B-639*  
 Rengo M.: *B-474, C-024, C-164, C-293, C-339, C-855*  
 Rensing B.: *B-442*  
 Rentsch K.: *B-484*  
 Renz D.M.: *B-491, B-493, B-496, B-500, B-614, B-619, C-108, C-110, C-112, C-113, C-114, C-115, C-298*  
 Repa I.: *B-532*  
 Reponen J.: *A-290*  
 Rescinito G.: *B-494*  
 Resmini E.: *B-009*  
 Resnick D.: *C-651, C-677*  
 Restaino G.: *B-154*  
 Rettenbacher T.: *B-349*  
 Revel D.: *C-173*  
 Revert Ventura A.J.: *C-882*  
 Reyero M.P.: *C-278, C-434*  
 Reynés C.: *C-271*  
 Reynes-Sancho C.: *C-633*  
 Reznek R.H.: *B-142, B-608, C-329, C-394*  
 Rezvani M.: *B-071, B-713*  
 Rha S.E.: *C-021, C-380, C-474, C-600*  
 Rhim H.: *B-377, B-378, C-425*  
 Rho J.-Y.: *C-267*  
 Rhyn A.: *C-292*  
 Riambau V.: *C-943*  
 Ribeiro C.: *C-316, C-464*  
 Ribeiro C.A.: *C-467*  
 Ribeiro M.: *C-213, C-274*  
 Ribeiro N.: *C-467*  
 Ribes R.: *C-925*  
 Ricart Selma V.: *B-495*  
 Ricca P.: *B-249*  
 Ricci P.: *B-777, C-043*  
 Richarme D.: *C-683, C-688*  
 Richarme-Barthelet D.: *C-668*  
 Richter G.: *C-263*  
 Richter G.M.: *B-570*  
 Rico Sandoval E.: *C-880, C-881, C-882*  
 Riedl C.C.: *B-029, B-611, B-754*  
 Rief N.: *C-323*  
 Rieger A.: *B-203*  
 Rieger J.: *B-126*  
 Rieke V.: *B-289*  
 Ries T.: *B-057*  
 Rietsch N.: *A-217, A-274*  
 Riga C.: *C-540*  
 Riga C.V.: *B-773*  
 Righi D.: *C-552*  
 Righi R.: *C-401*  
 Righini R.: *B-720*  
 Rigo P.: *A-478*  
 Rijsdijk M.: *B-086, B-087*  
 Rima Kumari R.K.: *C-711*  
 Rimola J.: *C-410*  
 Rimoldi J.: *C-783*  
 Ringe K.I.: *C-544*  
 Ringgaard S.: *B-572*  
 Rinkel J.: *B-516*  
 Riojas G.: *B-837*  
 Ripa C.: *B-148, C-605*  
 Risse F.: *B-818*  
 Rist C.: *B-440, B-826*  
 Ritter C.O.: *B-794, B-821, B-824*  
 Ritz J.P.: *B-375*  
 Riva G.: *C-491*  
 Rizzati R.: *C-401*  
 Rizzato G.: *A-361, D-27*  
 Rizzo L.: *B-213, B-329*  
 Robert P.: *B-420*  
 Roberto I.: *B-726*  
 Roberts H.C.: *B-221*  
 Roberts V.: *B-006*  
 Robertson E.M.: *B-537*  
 Robertson R.: *C-203*  
 Robinson P.J.A.: *A-355*  
 Robinson S.: *C-853*  
 Robles M.: *C-750*  
 Roca Y.: *C-378*  
 Roccatagliata L.: *C-747*  
 Rocchetti S.: *B-149*  
 Roch D.: *A-028*  
 Rocha D.M.: *C-797*  
 Rocha M.: *B-655*  
 Roche C.: *A-395, C-223, C-523*  
 Roche S.: *C-466*  
 Rockall A.G.: *B-142, C-329, C-394*  
 Rockey D.C.: *B-479*  
 Rodionov P.V.: *C-740*  
 Roditi G.H.: *B-100, B-568, C-374, C-913*  
 Rodrigues A.: *C-481*  
 Rodríguez Alvarez M.: *C-652*  
 Rodríguez C.M.: *C-811*  
 Rodríguez E.: *C-141, C-142*  
 Rodríguez I.: *C-925*  
 Rodríguez M.: *C-271*  
 Rodríguez P.: *C-652*  
 Rodríguez Rodríguez M.L.: *C-206*  
 Rodríguez S.: *C-410, C-480*  
 Rodríguez San Vicente D.: *C-515*  
 Rodríguez-Lemos R.: *C-804*  
 Roemer F.W.: *C-640*  
 Rogalla N.: *B-678*  
 Rogalla P.: *A-094, A-142, B-678, D-69*  
 Rogut V.S.: *B-028, B-612*  
 Röhl B.: *B-271, B-275*  
 Roig M.: *C-707*  
 Rojo T.: *C-608*  
 Roldan J.: *C-271*  
 Roldán V.: *B-551*  
 Rollandi G.A.: *A-349, B-729*



- Rollo M.: B-272  
Roma R.: B-400  
Romagnoli C.: C-650  
Romanini L.: C-011, C-046, C-324  
Romanuk-Doroszewska A.: C-616  
Romano L.: B-718, C-285, C-426, C-443, C-470, C-471, C-627  
Romano M.: B-445, B-446, B-447, B-656, C-183, C-940  
Romano S.: C-426, C-443  
Romanov G.: B-216  
Romera M.J.: C-466  
Romero M.: C-378  
Romero Martínez J.: C-794  
Rompa G.: C-417, C-423  
Romsauerova A.: B-805  
Roos J.E.: B-312  
Ropers D.: B-659  
Ropers U.: B-075, B-659  
Roque A.: C-277  
Roqué C.: C-067  
Ros P.R.: A-356  
Roselli A.: B-613, B-756, C-088, C-101  
Roselli G.: B-458  
Rosello E.: C-937  
Rosenbaum-Krumme S.: B-380  
Rosenbloom L.: C-507  
Rosenthal H.: C-544  
Rosinska-Bogusiewicz K.: B-174, B-176  
Rosset A.: B-191, B-198, B-199  
Rossi A.: A-316, C-164  
Rossi M.: B-144  
Rossi S.: B-414, C-925  
Rostad E.: B-536  
Rosztóczy A.: C-420  
Roterud H.: B-505  
Roth J.: B-022  
Rotkiewicz A.: C-944  
Rotondo A.: C-898  
Roudaut P.-Y.: B-039  
Roumen R.M.H.: B-282  
Rousseau H.: B-776  
Roussomoustakaki M.: B-724  
Rovira A.: C-709  
Rovira-Cañellas A.: A-338  
Rowlands D.: C-592  
Rowley H.A.: D-05  
Roy C.: A-129, B-792  
Roy-Choudhury S.H.: C-461  
Royo J.: C-138  
Rozhkova Z.Z.: B-280  
Rozie S.: B-004, B-063, B-065, B-066, B-069, B-186  
Rubens M.B.: C-178  
Rubin G.D.: A-346, A-462, B-312  
Rubtsova N.A.: C-348  
Rudas M.: B-611  
Rudolph B.: B-743  
Rudzki S.: C-734  
Ruedel C.: B-381  
Ruehm S.G.: A-024  
Ruf K.: B-641  
Rüfenacht D.A.: A-188  
Ruggiero G.: C-285  
Ruibal C.: C-739  
Ruijters D.: C-200, C-591  
Ruiz de Gopegui Andreu M.: C-658, C-817  
Ruiz E.: C-604, C-799, C-800  
Ruiz García M.: C-577  
Ruiz García P.: C-703  
Ruiz Lopez L.: B-292  
Ruiz Ollero A.: C-533  
Ruiz Santiago F.: C-577  
Rumbert B.: B-668  
Rumboldt Z.: B-520  
Rumià J.: B-803  
Rummeny C.: B-781  
Rummeny E.J.: A-352, B-018, B-023, B-026, B-175, B-264, B-265, B-463, B-466, B-624, B-744, C-623, C-838  
Runge V.M.: B-307, B-793  
Runza G.: C-165, C-176, C-421, C-575  
Rusch E.: D-46  
Russo A.: B-751  
Russo F.: B-456  
Russo G.: C-285, C-627  
Russo S.: C-229  
Rutten A.: B-442  
Ruzsics B.: B-076, B-443, B-556  
Ryan A.G.: A-176  
Ryan M.: C-815  
Ryan R.: B-727  
Rychly B.: C-718  
Rylands G.: C-075  
Rymer R.: C-546  
Ryska P.: C-802  
Ryu J.-H.: C-124  
Ryu K.N.N.: B-470  
Ryznarova Z.: B-469  
Rzanny R.: C-754  
Rzepko R.: C-407
- ## S
- Saad E.: C-915  
Saarn T.: B-014, B-068, B-826  
Saba L.: B-185, C-893  
Sabah D.: B-709  
Sabato C.: B-460  
Sabharwal T.: C-576, C-908  
Sabloff B.: C-223  
Saborido C.: C-652  
Sacchetti L.: C-595  
Sadaoka S.: C-028  
Sadick M.: B-275  
Sagara K.: C-680  
Sagara Y.: C-560, C-730, C-780  
Sagmeister F.: B-821  
Saha B.K.: B-248  
Sahani D.V.: B-093, B-587, C-043  
Sahdev A.: B-608, C-329, C-394  
Sahel L.: C-931  
Sahni V.A.: B-480  
Sai H.: C-095  
Sai M.: C-134  
Saida Y.: C-327  
Saigi Grai E.: B-753  
Sailer J.: B-054  
Saini A.: C-576, C-908  
Saito A.: C-416  
Saito H.: B-591, B-599, C-029, C-416, C-427, C-489, C-861  
Saitoh H.: C-428, C-429  
Sakamoto T.: C-563  
Sakas G.: C-300  
Sakashita K.: C-680  
Sakaue S.: B-388  
Sakino I.: C-433  
Sakuma H.: B-233, B-683  
Sakuma I.: B-384  
Sala E.: A-030  
Salado J.: C-608  
Salah A.: B-608  
Salameh N.: B-268  
Salem A.: C-513, C-919  
Salem R.: B-071, B-713  
Salemi S.: B-585  
Sales D.: C-481  
Salgado R.: B-738

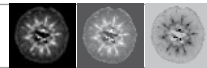
- Salganicoff M.: *B-315, B-476, B-478*  
 Salgarello M.: *C-934*  
 Salgueiro A.: *C-058*  
 Sali D.: *B-426*  
 Salim F.: *C-375*  
 Salli E.: *C-311*  
 Sallustio G.: *B-154*  
 Salman K.N.: *B-097*  
 Salmaslioglu A.: *B-390*  
 Salmeron I.: *B-292*  
 Salmon R.: *C-094*  
 Salomonowitz E.: *B-414, B-579*  
 Salto E.: *C-778*  
 Salum E.: *C-783*  
 Salvadó E.: *C-708*  
 Salvado M.: *B-299*  
 Salvador E.: *B-189, C-196, C-834*  
 Salvador R.: *B-162, C-136*  
 Salvador X.: *C-136*  
 Salvan C.-V.: *B-217*  
 Salvatori F.M.: *B-564*  
 Salvioni M.: *B-149*  
 Salzillo M.: *C-866*  
 Samir S.: *B-644, C-531*  
 Sammet S.: *B-397, B-664, B-666, B-667*  
 Sammett S.: *C-847*  
 Sampere J.: *C-015*  
 Samuel D.: *C-044*  
 San Román J.L.: *C-829*  
 Sanada J.: *C-006*  
 Sanada S.: *C-290*  
 Sánchez Alipio J.: *C-551, C-559*  
 Sánchez Cortazar J.: *B-414*  
 Sánchez E.: *C-604, C-799, C-800*  
 Sánchez González A.: *C-206*  
 Sánchez González M.: *C-222*  
 Sanchez J.: *C-138*  
 Sanchez M.: *C-480*  
 Sanchez R.: *C-806*  
 Sandler G.: *C-358*  
 Sandmann H.: *C-197*  
 Sandner T.: *B-688*  
 Sandomenico F.: *B-359, C-862*  
 Sanfilippo R.: *B-185*  
 Sangro B.: *C-568*  
 Sanjuan J.: *C-746*  
 Santa Cruz D.: *C-725*  
 Santamarina L.: *C-911*  
 Santana Garcia M.A.A.: *C-630*  
 Santana L.: *C-316, C-464, C-481*  
 Santarelli X.: *B-202*  
 Santiago C.: *C-473*  
 Santini D.: *B-705*  
 Santini F.: *B-309, C-183*  
 Santodirosso P.: *C-221*  
 Santoro D.: *C-909*  
 Santoro L.: *C-082, C-324*  
 Santoro M.: *B-775, C-899, C-900*  
 Santoro R.: *B-699*  
 Santos A.C.: *B-616*  
 Santos C.: *B-753*  
 Santos E.: *C-488*  
 Santos H.: *C-419*  
 Santos Name C.: *B-812*  
 Santos P.: *C-216, C-536*  
 Santos-Filho J.A.: *C-316, C-464*  
 Santucci E.: *B-400*  
 Sanz L.A.: *C-334, C-527*  
 Sanz R.: *C-340, C-644*  
 Sanz-Requena R.: *C-625*  
 Sapherson D.: *C-886*  
 Sapiha M.: *B-647*  
 Saranovic D.: *C-490*  
 Sarasibar H.: *C-527*  
 Sardanelli F.: *B-231, B-316, B-494, C-325, C-365, C-747*  
 Sardo D.: *B-213*  
 Sarin P.: *C-715*  
 Sarina A.: *C-044*  
 Sarisoy H.T.: *C-755, C-756*  
 Sarlieve P.: *C-669*  
 Sarmento Filho J.M.: *B-616*  
 Sarroca D.: *C-910*  
 Sassi I.: *B-288*  
 Satake H.: *C-033*  
 Satchithananda K.: *B-161*  
 Sathenjeri Rajendra J.: *B-247, C-537*  
 Satishchandra H.: *A-340*  
 Sato A.: *B-591, C-427, C-489*  
 Sato E.: *C-134*  
 Sato K.: *C-645*  
 Sato M.: *C-858*  
 Sato S.: *C-914*  
 Sato T.: *B-356*  
 Satogami N.: *C-336, C-529, C-914*  
 Satoh A.: *B-599, C-029, C-428, C-429*  
 Satoh T.: *C-789*  
 Saturnino P.P.: *C-862*  
 Saucedo Diaz G.: *C-703, C-713*  
 Sauer R.: *B-053*  
 Saueressig U.: *B-313, B-658*  
 Saupe N.: *B-003, B-140*  
 Saurí A.: *C-708*  
 Savatovsky J.: *B-220*  
 Savelli S.: *B-157, B-498, B-617, B-758*  
 Savino G.: *B-646, C-185*  
 Savolainen S.: *C-311*  
 Sbrana A.: *B-245*  
 Scaglione M.: *C-285, C-470, C-471, C-627*  
 Scambia G.: *B-154*  
 Scandiffio R.: *C-100*  
 Scaranelo A.: *C-092*  
 Scardino P.T.: *B-747*  
 Scavone G.: *C-403*  
 Schaap M.: *B-197*  
 Schaefer A.-O.: *B-722*  
 Schaefer C.: *B-472*  
 Schaefer D.: *B-640*  
 Schaefer F.K.W.: *B-165*  
 Schaefer O.: *B-398*  
 Schaefer P.J.: *B-165*  
 Schaefer-Prokop C.: *A-380, B-314, B-320, B-811*  
 Schaefers G.: *C-857*  
 Schaefers M.: *C-610, C-615*  
 Schäfer A.-O.: *D-25*  
 Schafer F.: *B-162*  
 Schäfer L.: *B-240, B-662*  
 Schäfer M.L.: *B-341*  
 Schäfer N.: *B-629*  
 Schäfer O.: *B-313*  
 Schäfer R.: *C-613*  
 Schaffelder R.: *B-402*  
 Schaible T.: *B-401, B-402, C-814*  
 Schattenberg J.: *B-567*  
 Schätzing R.: *D-31*  
 Scheel J.: *B-057*  
 Scheenen T.W.J.: *B-741*  
 Scheer E.: *C-613*  
 Scheerder M.: *B-314*  
 Scheffel H.: *A-477, B-450, B-483, B-484, B-822*  
 Scheffler K.: *B-309*  
 Scheinert D.: *A-088*  
 Schenk C.: *C-360*  
 Schenk P.: *B-302*  
 Schenkel J.: *A-469*  
 Schepis T.: *B-450*



- Scherpereel A.: B-107  
Scherrer A.: B-539  
Scherstler T.: B-483, B-484, B-822  
Scheschkowski T.: B-121  
Schiano A.: B-148, C-036  
Schiappacasse G.: C-634  
Schiavina R.: C-376  
Schick V.: B-590  
Schieber H.: B-835  
Schillaci O.: B-621  
Schillinger M.: B-067  
Schima W.: A-125, B-589  
Schimrigk S.: C-748  
Schlemmer H.: B-351  
Schlemmer H.-P.: B-145  
Schlemmer H.-P.W.: B-212  
Schlemmer M.: B-014  
Schlieter M.: C-263  
Schlorhauser C.: C-291  
Schlosser T.: B-322, B-558  
Schmalbrock P.: B-664, B-666, B-667  
Schmalfus I.: B-218  
Schmand M.: A-217, A-274  
Schmid A.: B-840  
Schmid F.T.: C-166, C-179  
Schmid T.: B-230, B-625  
Schmidt B.: B-293, B-395, B-638, B-678  
Schmidt K.-H.: B-237  
Schmidt M.: B-411  
Schmidt P.: B-767, C-673, C-754  
Schmidt S.: C-080  
Schmiedt W.: B-121, B-122  
Schmit M.: C-441  
Schmitt R.R.: B-255  
Schmitz A.C.: B-289  
Schmitz B.L.: B-184  
Schmitz-Rode T.: B-379  
Schmoeckel M.: B-559  
Schneider A.: B-018  
Schneider C.: B-567  
Schneider G.: B-415, B-796, C-047  
Schneider G.K.: B-413, B-642  
Schneider J.: B-507  
Schneider J.F.L.: B-408  
Schnohr S.: C-109  
Schober O.: B-590  
Schocke M.: C-776  
Schocke M.F.H.: B-001  
Schoenberg S.O.: B-650  
Schoeff U.J.: B-076, B-111, B-116, B-118, B-119, B-327, B-443, B-449, B-556, B-772, C-185, D-15  
Scholten E.T.: B-226, B-227  
Schönberg S.O.: B-601, B-643, B-816, C-681  
Schorlemmer C.: C-790  
Schraml C.: C-022  
Schramm N.: B-002  
Schramm W.: B-376  
Schreer I.: B-165, B-290  
Schreiber W.G.: B-237  
Schreiner A.: B-519  
Schröder L.: B-710, C-664  
Schröder T.: B-581  
Schroeder S.: C-186  
Schroth G.: B-302  
Schuchmann M.: B-567  
Schuler A.: B-357, D-45  
Schüller G.: B-589  
Schultes B.: C-179  
Schultz C.: C-318  
Schultze Koal L.J.: B-639  
Schulz D.I.: C-078, C-079  
Schulz-Wendtland R.: B-044, B-050  
Schunk K.: A-186  
Schuster T.: C-838  
Schwab S.A.: B-294, C-177, C-323  
Schwaiger M.: B-624  
Schwartz C.A.: B-020  
Schwarz F.: B-770  
Schwarz K.: B-395  
Schwenke C.: B-140  
Scialpi M.: B-109, C-898  
Sciarrà A.: C-379  
Scichilone N.: C-229  
Scipione S.: B-325  
Sconfianza L.M.: B-033, B-137, B-259, B-260  
Scotto B.: C-435  
Scuderi M.G.: C-471  
Sebening C.: B-521  
Sebesta P.: B-779  
Secchi A.: B-027, B-569  
Secchi F.: B-231, C-325  
Seccia B.: B-435  
Seçil M.: C-654  
Seco M.: C-139, C-201, C-617, C-676  
Sedati P.: B-823, C-442  
Sedlacik J.: B-304, B-767  
Sedlmair M.: B-439, B-518  
Sedykh S.A.: C-348  
Seeger A.: B-235, B-239, B-557  
Seeger A.H.: B-448  
Seguel S.: C-939  
Segui Palmer M.A.: B-753  
Sehnert W.J.: B-538  
Seifarh H.: B-684  
Seimenis I.: C-111  
Seith A.: B-524, C-662, C-926, C-930  
Seitun S.: B-445, B-446, B-447, C-183  
Seitz K.: D-45  
Seitz K.-P.: B-357  
Sekiya M.: C-883  
Selby B.P.: C-300  
Selby J.B.: B-772  
Semedo L.: C-201  
Semelka R.C.: B-141, D-07  
Semmler W.: B-030, C-941  
Sempere G.: C-271  
Semple S.I.K.: B-034  
Sennino B.: B-028, B-612  
Sennis Crivellé M.: B-753  
Seo B.K.: B-382, C-132  
Seo H.: C-008  
Seo J.B.: B-112, B-228, B-437, B-680  
Seoane C.: C-922  
Seon H.J.: C-188, C-255  
Serpälä T.: C-311  
Seradour B.: B-043  
Serafini G.: B-033, B-137  
Serebryakova S.V.: C-099, C-137  
Serena J.: C-937  
Serra C.: C-376  
Serra G.: C-247, C-248, C-249  
Serra J.F.: B-651  
Serra J.M.: B-651  
Serra L.: B-541  
Serrallonga M.: C-790  
Serrano C.: C-806  
Serra-Tosio G.: B-222, B-223  
Sesay M.: B-696  
Set P.A.K.: C-816  
Seth S.: B-685  
Setoain J.: C-714  
Setton M.D.: C-698  
Sevilla J.G.: B-430  
Seynaeve P.C.: B-088  
Shaalán M.: B-164  
Shady M.: B-262, C-018

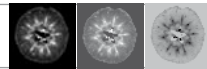
- Shah A.J.: *C-351, C-702*  
 Shah J.: *B-664, B-666*  
 Shah J.P.: *B-024*  
 Shah V.: *B-501*  
 Shahabpour-David M.: *A-013*  
 Shaham D.: *A-243*  
 Shahid M.: *C-167*  
 Shaikh S.M.: *B-133, B-160, B-798*  
 Shalek R.A.: *B-547*  
 Shalmon A.: *B-757*  
 Shames D.M.: *B-028, B-612, B-648*  
 Shamesh J.: *B-608*  
 Shamrey V.K.: *B-547*  
 Shan H.: *B-572*  
 Shanahan F.: *C-477*  
 Shankman S.: *C-695*  
 Shao D.: *C-851*  
 Shao Q.: *B-692*  
 Shapeero L.G.: *C-665*  
 Sharaf H.: *B-644*  
 Sharma P.: *B-354*  
 Sharma S.: *B-432*  
 Sharshar T.: *B-427*  
 Shastri M.: *B-113*  
 Shaw C.: *C-549*  
 Shechter G.: *B-291*  
 Sheikhaeri M.: *B-786, C-852*  
 Shen K.: *B-752*  
 Shen N.: *B-796, C-318*  
 Shen S.: *B-187*  
 Shen W.-C.: *B-167, C-554*  
 Shen Y.: *B-296, C-760, C-848, C-858, C-864*  
 Shen Y.S.: *B-061, B-085*  
 Sheng G.-S.: *B-761*  
 Shepard J.-A.: *C-241*  
 Shepstone L.: *B-708*  
 Sherif H.: *B-156*  
 Shi G.: *C-168*  
 Shi W.: *B-208, B-692*  
 Shi Y.: *C-439*  
 Shichinohe K.: *C-415*  
 Shiina Y.: *C-171*  
 Shim J.-C.: *C-646*  
 Shimada H.: *C-428, C-429*  
 Shimada K.: *B-143, C-057*  
 Shimada M.: *B-310, C-796*  
 Shimamoto K.: *C-310*  
 Shimao D.: *C-867*  
 Shimatani Y.: *C-251*  
 Shimizu F.: *C-845*  
 Shimizu K.: *C-236, C-252*  
 Shimofusa R.: *C-761*  
 Shin B.K.: *C-462*  
 Shin H.C.: *C-002*  
 Shin J.-H.: *B-286, B-755*  
 Shin S.S.: *C-456*  
 Shin Y.M.: *C-430*  
 Shinden Y.: *B-342*  
 Shiraga N.: *B-310, C-796*  
 Shirouzu I.: *C-772*  
 Shivalkar B.: *B-738*  
 Shukla-Dave A.: *B-747*  
 Shuto K.: *B-591, B-599, C-029, C-416, C-427, C-428, C-429*  
 Shuto R.: *C-560, C-924*  
 Siefert I.: *C-056*  
 Siani A.: *B-359, C-120, C-862*  
 Sibio S.: *B-016*  
 Siddiqui M.M.A.: *C-140*  
 Siddiqui S.: *C-245*  
 Sideri M.: *B-152*  
 Sidhu P.: *B-159*  
 Sidira P.: *C-729*  
 Siebenrock K.A.: *A-205*  
 Sieber M.A.: *B-094, B-096*  
 Siegel E.: *B-538*  
 Siegrist P.T.: *B-450*  
 Siek E.: *C-189, C-190*  
 Sievänen H.: *B-467*  
 Sieverding L.: *B-557*  
 Sievers B.: *B-558*  
 Sigal R.C.: *A-179*  
 Sigal-Zafrani B.: *B-163, C-094*  
 Sigriz N.: *C-714*  
 Sijens P.E.: *B-010*  
 Silva A.: *C-689*  
 Silva A.C.: *C-467*  
 Silva C.A.: *C-058*  
 Silva N.P.: *C-005, C-530*  
 Silvan M.: *C-054, C-055*  
 Silverberg C.M.: *B-768*  
 Silverman S.G.: *A-160*  
 Silvestri E.: *B-137, B-259, B-260*  
 Sim A.: *B-838*  
 Simmler R.: *B-050*  
 Simón C.: *C-261*  
 Simon D.: *B-073, B-677*  
 Simon G.H.: *B-648*  
 Simonet M.: *C-261*  
 Simonetti B.F.: *C-632*  
 Simonetti G.: *B-125, B-129, B-606, B-621, B-703, B-771, B-836*  
 Simonetti S.: *C-460*  
 Simon-Zoula S.C.: *B-485*  
 Simpson G.C.: *C-374*  
 Singaroyan R.P.: *C-375*  
 Singh A.K.: *B-479, B-587*  
 Singh D.: *C-793*  
 Singh J.: *B-509, C-398*  
 Singh J.P.: *C-550*  
 Singh S.: *C-204, C-317, C-396, C-678*  
 Singhal M.: *B-780*  
 Sinha S.: *C-432*  
 Sinitzyn V.E.: *A-117, C-151*  
 Sinkus R.: *B-268*  
 Sinnantaby R.: *B-290*  
 Siripurapu R.: *C-218, C-723*  
 Sironi S.: *B-036, B-656, B-716, C-571*  
 Sjöblom M.: *C-408*  
 Skaane P.: *B-536*  
 Skarantavos G.: *C-701*  
 Skiadopoulos S.: *C-117*  
 Skippage P.: *C-355*  
 Skippage P.L.: *C-525*  
 Skoulikaris E.: *C-388, C-518*  
 Skrok J.: *B-184, B-358*  
 Skurnick J.H.: *B-807*  
 Sladek K.: *C-304*  
 Slattery M.M.: *C-418*  
 Slotboom J.: *B-302*  
 Smedby Ö.: *C-296, C-307*  
 Smeets P.: *B-015*  
 Smet S.S.: *B-088*  
 Smirnova T.: *C-344*  
 Smith A.: *B-042, C-402*  
 Smith A.R.: *B-772*  
 Smith M.L.: *C-636*  
 Smith S.: *C-695*  
 Smith S.E.: *C-698*  
 Smits M.: *B-090, C-771*  
 Snaith B.: *A-324, B-533, B-535*  
 Snow A.: *C-350*  
 So C.: *C-320*  
 So G.J.: *B-093*  
 Sobaniec W.: *C-821*  
 Sobiecka B.: *C-768*  
 Socha M.: *C-304*  
 Soegner P.: *B-256, B-345, B-510, B-740, B-806*





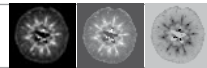
- Soffia P.: A-157  
Sohaib A.: B-040  
Sohns C.: B-084  
Soimakallio S.: B-467  
Solà M.: B-284, C-395  
Solanes N.: C-943  
Solano A.: C-138  
Solbiati L.: A-103, B-374, D-67  
Soldati C.: B-149  
Soler R.: C-141, C-142  
Solheim H.: B-786  
Soliman N.: B-387  
Solis I.: C-806  
Solitro F.: B-329  
Solopova A.E.: B-369, B-370  
Solovyev V.: B-748  
Solstad H.: A-279  
Somers T.: B-765  
Son G.S.: C-132  
Song B.: B-712  
Song H.: C-774  
Song I.: B-378, C-425  
Song J.W.: B-437  
Song J.-W.: B-228  
Song K.-S.: B-228, B-680  
Song L.: C-152, C-172  
Song S.: C-887  
Song S.-Y.: C-064  
Sont J.: B-511  
Sordelli I.F.M.: B-148, C-036, C-605  
Sørensen T.: B-368  
Sosna J.: A-243, B-635, B-714  
Sotiropoulou E.: C-578, C-597, C-598, C-884  
Soto Giordani G.: C-807, C-939  
Soud H.: B-071, B-713  
Soulez G.: B-415, B-796  
Sourbron S.: B-068, B-346, B-488, B-559  
Sousa D.: B-653  
Sousa P.: C-399  
Souvatzoglou M.: B-744  
Soyer P.: C-546  
Soyka J.D.: B-270, B-629  
Soyupak S.: C-072  
Spacek M.: B-779  
Spagnolo P.: B-656  
Spanoudaki A.G.: B-675, C-074, C-697  
Sparacia G.: C-602  
Sparano A.: C-470, C-627  
Sparcia G.: B-768  
Speck O.: A-138  
Speck U.: B-128  
Spelle L.: C-591  
Sperber F.: B-757, C-103  
Sperlongano P.: C-605  
Spiezia S.: B-371  
Spinazzi A.: B-796, C-318  
Spirovski M.: C-438, C-751  
Spiten A.-E.: B-786  
Splendiani A.: B-210  
Spreng A.: B-302  
Spyridopoulos I.: B-236  
Spyridopoulos T.: C-628, C-701  
Squarcia M.: C-519  
Squarzia M.: C-714  
Squillace N.: C-026  
Squillaci E.: B-606, B-621, B-703  
Sreenivasan N.: B-509  
Sreeram G.: C-704  
Srinivas M.: C-782  
Srivastava D.N.: C-541, C-930  
Staack A.: B-743  
Staatz G.: A-463, B-790  
Stacul F.: A-252, D-36  
Stadlbauer A.: B-429  
Stadler A.: B-340, B-686  
Stadnik T.: B-488  
Staebler A.: B-254  
Staebler M.: B-490  
Stahl R.: B-781  
Stahlke Junior H.J.: B-414  
Stainsby J.: B-003  
Stajgis M.: A-197  
Stalder A.F.: B-309  
Stam M.: C-626  
Stamm H.: B-824  
Stanzani D.: C-121  
Stanzhevsky A.A.: B-547  
Staring M.: B-319  
Starzinger M.: B-008  
Stąskiewicz G.: B-174, C-189, C-734  
Stąskiewicz G.J.: C-190, C-268, C-511  
States L.J.: B-403  
Stattaus J.: B-373, C-581  
Stauffer N.-H.: C-080, C-556  
Stavolo C.: C-471  
Stefan A.: B-730  
Stefan H.: B-429  
Stefanczyk L.: B-647, C-752, C-757, C-944  
Stefanini M.: B-129, B-771, B-836  
Stefanou D.: C-406  
Steimann S.: B-031  
Steinbrich W.: B-031  
Steinert H.C.: A-007  
Steinke M.: B-232  
Stemmler H.-J.: B-333  
Steno J.: C-718  
Stentarelli C.: C-026  
Stepanov A.V.: C-593  
Stephens N.: C-394  
Stepina E.: C-612  
Stergar H.: B-380  
Stevens D.M.: B-295  
Steyaert L.: A-412  
Steyns F.: B-552  
Stieber P.: B-472  
Stief C.G.: B-489, B-490  
Stieger S.: A-472  
Stieltjes B.: A-010, B-215  
Stierstorfer K.: B-395  
Stilla U.: C-300  
Stinn B.: C-166, C-179  
Stockx L.: A-434  
Stødkilde-Jørgensen H.: B-572  
Stoitsis J.: C-089  
Stojkovic M.: B-583  
Stoker J.: A-095, B-017, B-362, B-471  
Stolke D.: B-668  
Stollberger R.: C-860  
Stollfuss J.: B-018  
Stolzmann P.: B-450, B-483, B-484, B-822, C-166  
Størmer J.: A-291  
Storto M.L.: B-435, B-775, B-778, C-221, C-899, C-900, C-940  
Stosic-Opincal T.: C-773  
Stoupis C.: B-721  
Straiton J.B.: C-913  
Stranzinger E.: C-806  
Stratton J.: C-565  
Streck J.: B-076  
Strecker E.-P.: B-570  
Stritzker J.: B-029  
Strobel D.: B-357, D-45  
Strobel K.: B-270, B-629  
Strøm B.: A-279  
Stroszczyński C.: B-266  
Strube A.: C-612  
Strunk H.: B-357

- Strzelczyk P.: *B-253*  
Stuart S.: *C-504*  
Studer U.E.: *B-485*  
Studniarek M.: *C-407, C-417, C-423, C-588*  
Stuhr F.: *B-406, B-407*  
Stumpe S.: *B-089*  
Sturniolo G.: *B-460*  
Suarez V.: *C-237*  
Suárez-Vega V.M.: *C-482*  
Suaris T.D.: *B-672*  
Subramanian S.: *C-541, C-926*  
Suchánek V.: *B-732*  
Sueldo C.: *C-342*  
Suetens P.: *C-200, C-591*  
Sugimoto H.: *B-497, C-404*  
Sugimura K.: *B-101, B-106, B-817, C-411*  
Sugisawa K.: *C-903*  
Sugiyama H.: *C-867*  
Suh J.H.: *C-646*  
Suh K.-S.: *B-147*  
Suh S.H.: *C-801*  
Sukumar S.A.: *C-445*  
Sullivan F.J.: *D-63*  
Sullo P.: *C-866*  
Sulser T.: *B-484*  
Summerfield R.: *C-075, C-197, C-262*  
Sumura M.: *C-384*  
Sun C.: *B-523*  
Sun F.: *B-261, B-623, B-702, B-752, B-819*  
Sun G.: *C-813*  
Sun H.: *C-364, C-905*  
Sun J.: *B-545*  
Sun J.-Y.: *B-104, B-108*  
Sun X.: *C-875*  
Sun Y.S.: *B-595, B-596, C-041*  
Sun Y.X.: *B-115*  
Sundin A.E.: *B-626*  
Sung K.T.: *C-366*  
Sung S.C.: *C-830*  
Suo J.: *C-918*  
Suranyi P.: *B-116, B-118, B-119, B-327, B-556, B-772*  
Suresh P.: *C-659*  
Suri R.: *C-569*  
SűB C.: *B-395*  
Sussman M.S.: *B-003*  
Sutton E.J.: *B-023*  
Suzuki K.: *B-310, C-033, C-060, C-170, C-171, C-327, C-763, C-858*  
Suzuki M.: *C-290*  
Suzuki Y.: *B-012*  
Svab I.: *A-149*  
Svanidze G.: *C-014*  
Svensson W.E.: *B-161*  
Sychov V.A.: *B-280*  
Sydnor M.K.: *C-553*  
Syrstatidou E.: *C-594*  
Syuto K.: *C-489*  
Szabelska A.: *C-511*  
Szabo G.: *C-263*  
Szalay A.A.: *B-029*  
Szczerbo-Trojanowska M.: *A-385*  
Szeberin Z.: *B-832*  
Szeimies U.: *B-254*  
Szikora I.: *A-458*  
Szkklaruk J.: *C-019, C-358*  
Szomolanyi P.: *B-576, B-577*  
Szurowska E.: *C-417, C-423, C-588*
- T**  
Tabata Y.: *C-563*  
Taboada G.: *C-733*  
Tabuchi A.: *C-869*  
Tacelli N.: *B-107*  
Tack D.: *A-036*  
Tadokoro M.: *C-520*  
Tagliafico A.: *B-009, C-354*  
Tahsini M.R.: *C-758*  
Taibbi A.: *C-020, C-048, C-450, C-575, C-602*  
Taieb S.: *A-264*  
Takada E.: *C-123*  
Takahara T.: *B-399, C-400*  
Takahashi K.: *C-876*  
Takahashi M.: *C-086, C-563*  
Takahashi N.: *B-267*  
Takahashi S.: *B-384, B-481, C-090, C-301, C-861*  
Takaji R.: *C-053, C-560, C-924*  
Takaoka H.: *C-171*  
Takase K.: *C-301*  
Takase S.: *B-233*  
Takasugi M.: *B-759*  
Takazakura R.: *C-563*  
Takeda K.: *B-233, B-683*  
Takeda M.: *C-095*  
Takeda Y.: *C-869*  
Takenaga S.: *C-028*  
Takenaka D.: *B-101, B-106, B-817*  
Takeuchi M.: *C-337, C-356*  
Takewa S.: *C-869*  
Talanow R.: *C-269, C-270, C-288, C-509, C-764*  
Tali E.T.: *A-415*  
Talwalkar A.: *B-153*  
Talwalkar J.A.: *B-267*  
Talwar I.: *C-710*  
Tam E.: *B-480*  
Tamai K.: *C-336*  
Tamakawa M.: *C-789*  
Tamci B.: *B-689*  
Tamura A.: *C-327*  
Tamura S.: *C-039, C-458*  
Tan K.T.: *C-191, C-920, C-921*  
Tan L.: *B-509*  
Tan L.K.: *C-309*  
Tanaka H.: *C-102*  
Tanaka J.: *B-342, B-631*  
Tanaka T.: *C-086, C-563, C-845, C-876*  
Tanaka Y.: *B-200*  
Taneja S.: *C-455*  
Tang F.: *C-679*  
Tang L.: *B-595, B-596, C-041*  
Tang M.: *C-320*  
Tang X.-X.: *B-734*  
Tanghe H.L.J.: *B-065, B-090, C-722*  
Taniguchi H.: *C-411*  
Tann O.R.: *B-690*  
Tannast M.: *A-205*  
Tanoue S.: *C-238, C-730, C-780, C-924*  
Tanter M.: *B-163*  
Taori K.: *B-248*  
Taouli B.: *B-339*  
Taourel P.: *A-185*  
Tapia Viñe M.: *C-658*  
Tarantino L.: *B-148, C-036, C-516, C-605*  
Tarasow E.: *C-821*  
Tardaguila de la Fuente G.: *C-193*  
Tardaguila F.: *C-193*  
Tardáguila G.: *C-488*  
Tardivon A.: *B-163, C-094, D-40*  
Tardivon A.A.: *B-162*  
Tarján Z.: *B-730*  
Tartaglia V.: *B-363, C-389*  
Tartari S.: *C-401*  
Tastan A.: *B-689*



- Tata S.: B-097  
Tatco V.: C-259  
Tateishi U.: C-411  
Tatsch K.: B-333  
Tatsugami F.: C-322  
Taupitz M.: B-743  
Tavares M.C.: C-467  
Tavernaraki E.: B-674  
Tavri S.: B-023, B-026  
Taylor A.: B-389  
Taylor S.A.: B-477, B-480  
Taylor W.R.: C-918  
Tazaki M.: B-342  
Tedeschi E.: C-866  
Tee J.: C-565  
Teertstra H.J.: D-60  
Teeuwisse W.M.: B-762  
Teipel S.: C-727, C-745  
Teixeira Gomes M.: C-073, C-536  
Teixeira L.: C-201, C-202, C-234  
Teixera R.: C-162  
Teixido M.: B-768  
Teixidor M.: C-409  
Temmen R.: C-873  
Tempia A.: C-080  
Teo H.E.L.: C-660, C-694  
Teodorovic N.: C-292  
Tepe G.: B-128  
ter Beek L.: B-268  
ter Haar G.R.: A-378  
ter Haar Romeny B.M.: C-104, C-200, C-591  
Terada H.: B-310, C-767  
Terao M.: C-171  
Termote B.M.M.M.: C-319  
Ternovoy S.K.: C-635  
Terreros Bejo I.: C-484  
Terrier P.: C-665  
Tewelde A.G.: B-720  
Thaher F.: C-112  
Thalhammer A.: B-451  
Thanos L.: C-578, C-597, C-598  
Themudo R.: C-073  
Theocharopoulos N.: B-292  
Theodorakis D.: C-879  
Theodoropoulos E.: C-545  
Theodorou D.J.: C-677  
Theodorou S.J.: C-677  
Theotokas I.: C-388, C-518  
Thévenin F.: C-648, C-683, C-688  
Theysohn J.M.: B-258, B-662, B-663  
Thiam R.: B-602  
Thibault F.: C-094  
Thilo C.: B-076, B-118, B-443, B-449  
Thng C.H.: B-386  
Thoeny H.C.: B-056, B-485  
Thomaides T.: B-426  
Thomas M.: B-044  
Thomassin-Naggara I.: B-155  
Thompson D.: C-461  
Thomsen H.S.: A-109, A-442, D-04  
Thomson P.: B-100  
Thornton E.: C-418  
Thrall J.H.: A-246, A-326  
Thukral B.: C-620  
Thuny F.: C-156  
Thurnheer M.: C-179  
Thurnher M.M.: A-166, A-298, B-203  
Thurnher S.: B-413, B-415, B-796  
Tielbeek A.V.: B-839  
Tieleman A.: B-765  
Timsit J.-F.: B-222, B-223  
Tins B.: A-145  
Tiralongo S.: B-231, C-365  
Tisnado J.: C-553  
Tkacz J.N.: C-890  
Tobarra-González B.: C-872  
Tocino I.: A-208  
Todt M.: B-552  
Todua F.: C-014  
Togao O.: C-735  
Togashi K.: B-143, C-057, C-336, C-529, C-914  
Tognetti A.: C-387  
Tognolini A.: B-603  
Tokuda O.: C-653, C-654  
Tokuda Y.: C-095  
Tomà P.: B-788  
Tomar G.: C-351, C-702  
Tomás M.: C-478  
Tomaszewska M.: C-189  
Tomaszewski A.: C-189, C-190, C-268  
Tombach B.: B-412, B-416, B-795  
Tominaga J.: C-090  
Tomlinson G.: B-003  
Tomozawa H.: C-031  
Toms A.: A-029  
Toms A.P.: B-257, B-708  
Tomura N.: B-384  
Tonegutti M.: B-751  
Torelli L.: B-610  
Torge M.: B-436  
Toriyama A.: B-012  
Torp-Pedersen S.: B-344, D-29  
Torrão H.: C-066, C-927  
Torreggiani W.: A-174  
Torregrosa Andres A.: B-495  
Torres A.: C-268, C-511  
Torres del Río S.: B-430  
Torres I.: C-237, C-264  
Torres K.: C-268, C-511  
Torres Monzón E.: C-601  
Torres-Tabanera M.: A-312  
Torri P.: B-774  
Torriceilli P.: C-026, C-125  
Tortajada M.: B-636  
Tortora G.: C-443, C-627  
Tot T.: A-056  
Tóth G.: C-451  
Tóth L.: C-451  
Touloumis Z.: C-056  
Tourani K.L.: C-140  
Toussaint J.-F.: C-912  
Touzé E.: C-912  
Townsend D.W.: B-212  
Toyama T.: C-563  
Trad C.S.: B-616  
Trad S.: B-676  
Trakakis E.: C-628  
Tranquart F.: D-46  
Trappe K.: C-599  
Trattinig S.: B-429, B-576, B-577, B-579, B-580, C-647  
Treier M.: B-313  
Treitl M.: A-153, B-126  
Trenkner S.W.: A-177  
Treska V.: B-725  
Tresoldi S.: B-445, B-446, B-447  
Treyer V.: B-270, B-540  
Trianni A.: C-868  
Triantopoulou C.: A-126, C-056  
Trieb T.: C-360  
Trinquant L.: B-602  
Tripathi R.P.: B-546  
Tristán Fernández J.M.: C-577  
Trofimenko I.A.: C-349  
Trojanowska A.: B-174, B-176, C-511  
Trojanowski P.: B-174, B-176  
Tromsdorf U.I.: B-396  
Trufanov G.: B-216, C-099, C-137

- Trufanov G.E.: *C-349*  
 Trumm C.G.: *A-027, B-277, B-333*  
 Tsai D.-Y.: *C-883*  
 Tsakiri A.: *C-089*  
 Tsampoulas C.: *C-406*  
 Tsang D.: *C-320*  
 Tsapaki V.: *C-868*  
 Tsatalas K.: *C-697*  
 Tschirch F.: *B-350*  
 Tschugunow A.: *B-183*  
 Tsetis D.K.: *A-026*  
 Tsiflikas I.: *C-186*  
 Tsili A.C.: *C-406*  
 Tsimitselis G.: *C-287, C-884*  
 Tsompanlioti C.: *C-111, C-147*  
 Tsouli S.: *B-421, B-550*  
 Tsuchie Y.: *C-791*  
 Tsuchiya K.: *C-086*  
 Tsui Y.-K.: *C-716*  
 Tsunoo M.: *C-767*  
 Tsurumaki M.: *C-883*  
 Tsurusaki M.: *B-141*  
 Tsutsui S.: *C-227, C-228*  
 Tunaci M.: *B-390*  
 Tung K.: *C-486*  
 Tuñón T.: *C-762, C-766*  
 Turba U.C.: *B-838*  
 Turnbull I.W.: *C-723*  
 Turner M.: *B-690*  
 Turner R.: *A-111*  
 Turski T.: *C-769*  
 Turupoli E.: *C-451*  
 Tüttenberg J.: *B-215*  
 Tutuian R.: *B-369*  
 Twellmann T.: *C-104*  
 Twijnstra A.: *B-090*  
 Tyutin L.: *B-547*  
 Tzarouhi L.C.: *B-421, B-550*  
 Tzedakis A.: *B-785*  
 Tzeng W.-S.: *C-716*  
 Tzovara J.: *C-287, C-295, C-884*
- U**  
 Uberoi R.: *A-460, B-837*  
 Ucar A.: *B-390*  
 Uchida K.: *C-384*  
 Uchida N.: *C-384, C-791*  
 Uchiyama D.: *C-543*  
 Uder M.: *B-294, B-840, C-177, C-321, C-323*
- Udupa J.: *B-218*  
 Ueda K.: *C-052*  
 Ueda M.: *C-171*  
 Uehara M.: *C-171*  
 Ueno E.: *C-170, C-858*  
 Uesaka K.: *C-007*  
 Uesbeck M.: *C-292*  
 Uetani M.: *C-227, C-228*  
 Uffmann M.: *B-314*  
 Ugarriza Echevarrieta F.: *C-785*  
 Uhlig S.: *C-189, C-190, C-511, C-734*  
 Ujita M.: *B-315*  
 Ukmar M.: *B-202*  
 Ulriel L.: *B-829*  
 Ulisse S.: *C-632*  
 Ulla M.: *C-829*  
 Ullrich K.: *B-266*  
 Ulmer H.: *B-349*  
 Ulmer J.L.: *B-217*  
 Ulrich A.: *B-434*  
 Ulug M.A.: *B-749*  
 Umehara I.: *B-012*  
 Umemura Y.: *C-050, C-458*  
 Unezawa T.: *B-342*  
 Uno T.: *B-012*  
 Unsinn K.M.: *B-348*  
 Unten S.: *C-547*  
 Uotani K.: *B-064, B-081*  
 Uprimny C.: *B-072, B-625, B-799*  
 Urashima M.: *C-028*  
 Urbanik A.: *A-021, C-304, C-768, C-769*  
 Urigo C.: *C-583, C-585, C-893*  
 Urna I.: *C-015*  
 Urresola A.: *C-460*  
 Usta U.: *C-370*
- V**  
 Vadapalli R.M.S.V.: *B-105, B-204, B-209, C-704, C-712, C-717, C-732, C-793, C-907*  
 Vadapalli R.M.V.S.V.: *B-810, C-782*  
 Vag T.: *C-112, C-114*  
 Vaga S.: *B-132*  
 Vajdi C.: *B-161*  
 Vakaki M.: *C-810, C-827, C-836*  
 Valbuena E.: *C-237, C-803*  
 Valdeig S.: *B-375*  
 Valenta I.: *B-450*  
 Valentin-Gamazo C.: *B-581*
- Valentino M.: *B-527, C-376*  
 Valera Abril A.: *C-208, C-826*  
 Valeri G.: *B-494, C-632*  
 Valikovics A.: *B-833*  
 Vallati G.: *B-699*  
 Valle M.: *B-788*  
 Valle N.: *C-657, C-682, C-800*  
 Vallée C.A.: *B-427*  
 Vallee J.-P.: *B-681*  
 Vallejos J.: *C-175, C-342, C-372, C-373*  
 Vallés González H.: *C-601*  
 Vallet C.: *C-080*  
 Vallini V.: *C-558*  
 Vallone C.: *C-017*  
 Valverde S.: *C-561*  
 van Aalst W.: *C-104*  
 van Beek E.J.R.: *B-093, B-328, B-820*  
 van Beek M.: *B-282*  
 Van Beers B.: *B-268*  
 van Buchem M.A.: *A-091, A-270*  
 Van Damme S.: *C-788*  
 van de Zaag-Loonen H.: *B-317*  
 van Delden O.M.: *A-386*  
 Van den Bekerom M.P.J.: *C-319*  
 van den Berg J.C.: *A-435*  
 van den Bosch M.A.A.J.: *B-289*  
 van den Hauwe L.: *A-259*  
 van der Geest R.J.: *B-078*  
 van der Kroft L.: *D-70*  
 van der Lugt A.: *B-004, B-063, B-065, B-066, B-069, B-186, C-722, C-771*  
 van der Molen A.J.: *A-005, A-439, B-481*  
 Van der Niepen P.: *B-488*  
 van der Vleuten P.A.: *B-074, B-079, B-392*  
 van der Zaag H.: *B-442*  
 van der Zaag-Loonen H.J.: *B-079, B-227*  
 Van Dyck P.: *B-005, C-626*  
 van Engelshoven J.M.A.: *B-173*  
 van Ginneken B.: *A-427*  
 Van Goethem J.W.M.: *A-259*  
 Van Hende V.: *C-624*  
 Van Herendael B.: *C-266*  
 van Klaveren R.J.: *B-226, B-317*  
 van Klavern R.J.: *B-227*  
 Van Laer P.: *B-015*  
 van Langen H.: *B-639*  
 van Leeuwen M.: *B-399*  
 Van Ongeval C.: *B-045*  
 van Ooijen P.M.A.: *B-010, B-074, B-077, B-079, B-317, C-302, C-312*



- Van Pelt N.: B-114  
van Randen A.: B-017  
van Rijn A.F.: B-362, B-471  
van Rijssel D.A.: B-090  
Van Snick S.: C-624  
Van Steen A.: B-045  
van 't Klooster R.: B-078  
van Walsum T.: B-069, B-197  
Vande Berg B.: A-206  
Vandecaveye V.: B-172  
Vander Poorten V.: B-172  
Vanderdonckt P.M.: B-088  
Vandevenne J.E.: B-139, C-319, C-684  
VandeVyver V.: C-508  
Vandulek C.: B-532  
Vanel D.: C-665  
Vangelisti M.: C-009  
Vanhoenacker F.M.H.M.: A-261, B-005,  
B-139, C-626, C-684  
Vanninen R.: B-804  
Vaño E.: A-318, C-868  
Vano Galvan E.: C-414, C-476  
Vardar M.B.: C-755  
Varga D.: B-832  
Varlet P.M.: B-575  
Varona Porras D.: C-261, C-277  
Varzim P.: C-213, C-274  
Vasilevska V.J.N.: B-254  
Vasilio P.: C-231  
Vasselli F.: B-323  
Vassileva J.: C-868  
Vassiou K.: C-117  
Vaz O.: C-676  
Vazquez F.: C-739, C-775  
Vazquez J.E.: C-707  
Vazquez J.L.: C-811  
Vázquez Olmos C.: C-206, C-692  
Vearncombe L.M.: C-779  
Vecchietti F.: C-024, C-339, C-855,  
C-897  
Veciana P.: C-466  
Vega Astudillo A.: C-703  
Veillon F.: A-451  
Veit R.: B-383  
Veit-Haibach P.: B-270, B-540, B-629,  
B-800  
Velazquez M.: B-191  
Veldhuis W.B.: C-400  
Velitsista S.: C-578, C-598  
Velthuis B.: B-828  
Veltman J.: A-384, C-105  
Veltri A.: B-213  
Vembar M.: B-196  
Venâncio J.: C-467  
Vendrely A.: B-220, C-724  
Venema H.W.: B-811  
Venetianer C.: C-318  
Venkatesh S.K.: B-267, C-016  
Venturini M.: B-149, B-569  
Verardi N.: B-288  
Verbeelen D.: B-488  
Verbeken E.: B-172  
Verbist B.M.: B-762  
Vercruyssen J.: B-015  
Verderame F.: C-602  
Vergadis V.: B-331  
Verganelakis D.A.: B-426  
Vergari V.: B-400  
Vergé M.: A-478  
Vergés R.: C-346  
Verma H.: C-214, C-525  
Vermathen P.: B-485  
Veron-Piot S.: C-532, C-917  
Verschakelen J.A.: A-146, B-226, B-227  
Verstraete K.: A-474, C-508, C-624,  
C-626, C-777, C-788  
Verswijvel G.: C-319  
Veselka J.: B-732  
Vetere S.: B-679, C-249, C-250  
Veunac L.: B-776  
Veyrac C.: A-370  
Viamonte B.: C-005, C-071, C-085, C-530  
Vianello E.: B-048, B-287  
Vicaut E.: B-268, C-534  
Vickers M.: C-885  
Vidal J.B.: B-430  
Vidal R.: C-466  
Vidarsson L.: B-526  
Viddeleer A.R.: B-010  
Vidili G.: B-720  
Vieira A.: C-689  
Vignali C.: B-774, C-558  
Vikgren J.: D-09  
Vilà Parera C.: C-136  
Vilanova J.C.: C-686, C-922  
Vilar J.: A-307  
Vilgrain V.: C-042  
Villalva C.: C-922  
Villanueva A.: C-233, C-281, C-878  
Villanueva A.J.: C-258  
Villari N.: C-009, C-017, C-082  
Villarosa A.: C-259  
Villoria G.M.: B-742  
Villiers R.: C-515  
Vincenti M.: B-109  
Vinjamuri S.: C-636  
Vinnicombe S.: C-329  
Vinnicombe S.J.: B-672  
Viola S.: B-788  
Virgolini I.: B-072  
Virgolini I.J.: B-625, B-799  
Visser R.: B-047  
Vitabile S.: B-397, C-450  
Vitti P.: D-41  
Viúdez A.: C-568  
Vives J.P.: C-708  
Vizcaya S.: B-284  
Vizza D.: B-323  
Vizzutti F.: C-065  
Vlachakos D.: C-701  
Vlahos I.: A-068  
Vlassenbroek A.: B-196  
Voelker W.: B-821  
Vogel M.: C-077, C-487, C-685  
Vogel W.: B-627  
Vogl R.: A-074  
Vogl T.: C-084  
Vogl T.J.: B-022, B-051, B-060, B-180,  
B-236, B-241, B-242, B-246, B-336,  
B-337, B-338, B-386, B-443, B-449,  
B-451, B-452, B-453, B-457, B-652,  
B-693, B-694, B-700, B-750, C-157,  
C-185, C-603, C-843  
Vogt F.: B-622, B-826  
Vogt F.M.: B-411, B-414, B-418  
Vogt-Schaden M.: B-215  
Voigtländer T.: B-414  
Voit H.-L.: B-840  
Vollmar S.V.: B-512, B-517  
Vollmer I.: C-138  
Voloudaki A.: B-462  
Volpicelli G.: C-282  
Volterrani L.: B-109, C-898  
von Berg J.: B-320  
von Herbay A.: B-357, D-45  
von Krogh Lid C.: A-279  
von Tengg-Kobligk H.: B-504, B-641  
Vorlat P.: A-013  
Vorwerk D.: A-045, B-570  
Vos P.E.: B-090

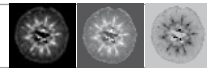
Vosseler M.: B-237  
 Vossough A.: B-403, B-783, C-758  
 Voth M.: B-795  
 Votrubová J.: B-779  
 Voulgaridou S.: C-879  
 Vouros M.: C-659  
 Vrints C.: B-738  
 Vucic E.: B-021, B-234, B-649  
 Vukelic-Markovic M.: B-482  
 Vullierme M.-P.: A-444  
 Vulpio C.: C-517, C-521  
 Vummidi D.R.: C-218, C-723  
 Vychytil A.: B-099

## W

Wacker F.K.: A-219  
 Wada A.: C-384, C-791  
 Wada K.: C-763  
 Wada S.: C-846  
 Wada Y.: B-342, B-631, C-645  
 Wagenblast J.: B-051, B-386  
 Wagner A.: B-472  
 Wagner H.-J.: A-014  
 Wagner T.: B-754  
 Wakamatsu H.: C-039, C-050, C-458  
 Wakamiya M.: C-086  
 Walch T.: C-776  
 Walcher F.: B-451  
 Waldeck J.: C-610, C-615  
 Waldeck S.: C-509  
 Waldherr C.: B-056, B-721  
 Waldt S.: B-264  
 Walecki J.: C-821  
 Walkden M.: C-592  
 Walker C.: B-789  
 Walker M.: B-196  
 Walker P.: C-566  
 Wall A.: B-022  
 Wallis L.I.: B-531  
 Wallis M.G.: A-418, B-043, B-162,  
 B-281  
 Walsh C.: C-328  
 Walter J.: B-094  
 Walter M.C.: B-002  
 Walter S.: C-300  
 Wang C.: B-801, C-296, C-307, C-753  
 Wang G.: C-844, C-875  
 Wang J.: B-303, C-363  
 Wang K.: C-243  
 Wang L.: B-747

Wang N.: B-595, B-596, C-041  
 Wang Q.: B-707, C-168  
 Wang X.: C-364, C-905  
 Wang X.-M.: B-523  
 Wang X.X.H.: B-752, C-135  
 Wang Y.: B-226, B-227, B-317, B-692,  
 C-152, C-172, C-210, C-211, C-212  
 Wang Z.: C-774  
 Wanke I.: B-661  
 Wan-Shi Z.: B-037  
 Ward E.: C-350, C-815  
 Warda R.: B-701  
 Waschkau B.: C-615  
 Watanabe A.: B-575, C-645  
 Watanabe N.: B-432  
 Watanabe Y.: B-064, B-081  
 Watarai J.: B-356, B-384  
 Watschinger B.: B-099  
 Watson C.J.E.: C-003  
 Watson N.A.: C-260, C-262  
 Watts C.D.: B-837  
 Weadock W.: C-600  
 Weber C.: C-629  
 Weber D.L.: B-578  
 Weber J.: B-578  
 Weber M.: B-054, B-099, B-314,  
 B-407, B-611, B-686  
 Weber M.-A.: B-215, B-710, C-664  
 Weber T.F.: B-055, B-058, B-830  
 Wechsel M.: B-075  
 Weckbach S.: B-002, B-346, B-518,  
 C-681  
 Wedegärtner U.: C-629  
 Ween B.: A-279  
 Wegrzyn-Szkutnik I.: C-268  
 Wehner M.: B-130  
 Wehrmann M.: C-487  
 Wei J.H.: B-131  
 Wei W.: B-019  
 Weidemann J.: C-291  
 Weilenmann A.: C-292  
 Weinger M.: B-821  
 Weishaupt D.: A-198, A-403, B-350,  
 B-369, B-370, D-01  
 Weismann C.F.: A-362  
 Weiss E.: C-776  
 Weiss F.: B-055, B-058  
 Weller H.: B-396  
 Wellings R.: C-308  
 Wells A.U.: B-673, B-814, B-815

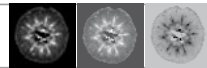
Wels T.: B-140  
 Welsch G.H.: B-576, B-577, B-579,  
 B-580  
 Wenaden A.: B-673  
 Wendland M.F.: B-028, B-612  
 Weng A.: B-824  
 Wenkel E.: B-044  
 Wentzel J.: B-066  
 Werber K.: C-623  
 Werf A.: B-068  
 Werlen S.F.: D-24  
 Werle-Rüdingen A.-E.: B-688  
 Werncke T.: B-190  
 Werner B.: B-044  
 Werner J.: B-583  
 Weskott H.-P.: D-30  
 Wessling J.: B-183  
 Westhofen M.: B-766  
 Weston M.: A-262  
 Westphalen K.: B-274  
 Wetzel S.G.: B-309  
 Weustink A.C.: C-164, C-184  
 Whitby E.H.: B-394, B-404, B-405,  
 B-808  
 White C.S.: A-213  
 White L.M.: B-003, B-708  
 White S.: C-469  
 Whittle C.I.: C-634, C-807, C-939  
 Wichmann T.: B-794  
 Widmann G.: C-655  
 Wiczorek A.P.: A-424  
 Wieder H.: B-018  
 Wiederseiner M.: C-177  
 Wielopolski P.A.: B-069  
 Wiener E.: B-347  
 Wierzbowski J.: C-417, C-423  
 Wiest G.: B-831  
 Wiest R.: B-302, B-391  
 Wild J.: B-394  
 Wild J.M.: B-328  
 Wilde P.: C-191, C-920  
 Wildermuth S.: C-166, C-179  
 Wilke A.: B-794  
 Wilkinson I.D.: B-531  
 Will U.: D-45  
 Willekens I.: C-850  
 Willems S.: B-232  
 Willems T.P.: B-077  
 Willett N.G.: C-918  
 Willi J.P.: B-191



- Williams B.J.: B-722  
Williams L.R.: C-402, C-445  
Williamson E.: C-194  
Williamson E.E.: C-143  
Willinek W.A.: B-414, D-22  
Wilms G.: A-165  
Wink O.: C-200  
Winkel C.: C-599  
Winterbottom A.P.: C-003  
Wintersperger B.J.: A-436, B-645, B-688  
Wirth S.: B-126, C-681  
Wiskirchen J.: C-613  
Withers P.J.: C-245  
Witjes J.A.: B-741  
Witoszynskij S.: B-304  
Wittmann T.: C-420  
Woenne E.C.: C-941  
Woentler K.: B-264  
Wojciechowski W.: C-304  
Wojczal J.: C-734  
Wolak T.: C-752  
Wolansky L.J.: B-807  
Wolf C.: B-230  
Wolf F.: B-686  
Wolf K.-J.: B-128, B-184, B-190,  
B-358, B-375, B-648  
Wolf M.: B-315, B-476, B-478  
Wolf R.W.: C-839  
Wolfe J.H.N.: B-773, C-540  
Wolski C.: C-944  
Won Y.D.: C-076  
Wong J.H.D.: C-309  
Wong R.J.: B-024  
Wong W.L.: C-526  
Woo O.H.: C-132, C-276  
Wood B.J.: A-099, A-161  
Woodhams R.: C-116  
Woodhouse J.: C-942  
Woodhouse N.: B-328  
Woodward N.: C-550  
Working Group of the ESUR C.T.U.: B-481  
Wormanns D.: A-428  
Wort J.: B-814, B-815  
Wörtler K.: A-306  
Wozniakowski B.: B-647, C-944  
Wright C.: B-043  
Wu B.: B-179, B-712  
Wu D.: B-181  
Wu G.: C-764  
Wu H.-K.: C-051  
Wu L.-B.: B-523  
Wu T.-C.: C-716  
Wu W.H.: B-737  
Wu Y.: B-326, B-825  
Wuchenauer S.: C-169  
Wucherer M.: B-050  
Wunder J.: B-708  
Wunder K.: B-507  
Wysokinski A.: C-190  
Wytttenbach R.: B-124
- K**  
Xaubert A.: C-222  
Xia L.: B-468, B-571  
Xia S.: B-306  
Xiang-Sheng L.: B-037  
Xiao J.: B-761  
Xiao W.: C-362  
Xiao X.S.: B-819  
Xu D.: B-226, B-227, C-212  
Xu D.M.: B-317, C-210, C-211  
Xu J.: B-712, C-035, C-728  
Xu J.R.: C-444  
Xu J.-R.: B-718  
Xu K.: C-743  
Xu L.: C-226  
Xu Q.: C-168  
Xu X.: B-366  
Xu Y.: B-364  
Xue H.D.: B-261, B-623, B-702, C-364,  
C-904, C-905
- Y**  
Yaghmai N.: B-295, B-297  
Yaghmai V.: B-071, B-713  
Yagüe H.: C-334  
Yam C.-S.: C-294  
Yama N.: C-789  
Yamada H.: C-645  
Yamada M.: B-012  
Yamada N.: B-064, B-081  
Yamada S.: C-861  
Yamada T.: C-134, C-301  
Yamada Y.: C-053  
Yamagishi T.: C-305  
Yamaguchi A.: B-310, C-796  
Yamaguchi M.: C-306  
Yamaguchi T.: C-227  
Yamamoto A.: B-782  
Yamamoto N.: C-791  
Yamamoto S.: C-761  
Yamamoto T.: C-290, C-404  
Yamamoto Y.: C-102  
Yamana D.: C-763  
Yamashita K.: C-735  
Yamashita T.: C-134, C-645  
Yamashita Y.: C-034, C-040, C-345,  
C-405, C-735, C-833, C-902  
Yamazaki M.: C-415  
Yamazaki S.: C-052  
Yamori Y.: B-782  
Yan Y.: C-849  
Yanaga Y.: C-034, C-040, C-345, C-405,  
C-833, C-902  
Yanagawa N.: B-599, C-029, C-428,  
C-429  
Yanagida T.: C-433  
Yang D.M.: C-863  
Yang K.: B-170  
Yang L.: C-168  
Yang P.: B-208  
Yang Q.: B-739, C-144  
Yang W.: C-679  
Yang Y.: B-208, B-542, B-712  
Yang Y.Y.: B-187  
Yang Z.G.: B-108  
Yang Z.-G.: B-104, B-110, B-326,  
B-600, B-825  
Yao J.: B-108, B-600, C-314  
Yarmentis S.D.: A-209, C-667, C-671,  
C-672, D-44  
Yasuda K.: B-384  
Yasukochi S.: C-828  
Yasumori K.: C-433  
Yasunaga C.: C-433  
Yavas U.S.: C-265, C-901  
Yazdanifard K.: B-503  
Yeh B.: B-516  
Yeom J.-S.: B-134  
Yeom S.K.: B-382  
Yerli H.: B-385  
Yi N.-J.: B-147  
Yiakoumelos A.: C-117  
Yildirim N.: C-510  
Yim Y.J.: B-763  
Yin M.: B-267, C-016  
Yogi A.: C-547  
Yokoe-Asakura K.: C-007  
Yokohama K.: C-845  
Yokota A.: B-012

- Yong A.: C-468  
 Yong H.S.: C-276  
 Yoo I.R.: C-380  
 Yoo S.-Y.: C-818  
 Yoon C.S.: B-529  
 Yoon H.J.: B-444  
 Yoon S.K.: B-444, C-366  
 Yoon S.-W.: C-589  
 Yoon W.: C-479  
 Yoon Y.C.: B-252, B-454  
 Yorozuya K.: B-759  
 Yoshida A.: C-098, C-888  
 Yoshida H.: B-364, B-475, B-479, B-587  
 Yoshida K.: B-012  
 Yoshida N.: B-782  
 Yoshida S.: B-782, C-543  
 Yoshimoto Y.: C-763  
 Yoshimura K.: C-310  
 Yoshiura T.: C-735  
 Yoshizako T.: C-384, C-791  
 Yotsumoto S.: C-560  
 You H.: B-070  
 Young R.: C-081  
 Young W.: C-320  
 Yousry I.: B-770  
 Yousry T.A.: A-167  
 Yu C.: C-731  
 Yu D.: B-706, C-550  
 Yu J.-Q.: B-110  
 Yu J.-S.: C-023  
 Yu J.Y.: C-496  
 Yu S.: B-315  
 Yuan J.: B-734  
 Yuba K.: C-763  
 Yue Y.: B-115  
 Yuhno E.A.: C-099  
 Yun S.: C-849  
 Yun-Long S.: B-037  
 Yurut Caloglu V.: C-370  
 Yutani K.: C-095
- Z**  
 Zabia E.: C-196  
 Zacharopoulou F.: B-393, B-634  
 Zacherl J.: B-598  
 Zadrozny D.: C-588  
 Zagouri F.: C-089  
 Zaid S.: B-374  
 Zaim S.: C-640
- Zaitceva A.Y.: C-740  
 Zalata K.: B-262, B-528  
 Zalis M.E.: B-475, B-479  
 Zaman N.: B-161  
 Zamboni G.A.: B-269, C-059  
 Zanasi A.: B-569  
 Zander T.: B-127  
 Zanetti M.: A-011, B-140, B-347  
 Zangos S.: B-246, B-337, B-338, B-453, B-693, B-700, B-750, C-157, C-603, D-49  
 Zanon E.: B-494  
 Zavadovskaya V.D.: C-642  
 Zbaeren P.: B-056  
 Zecca V.: C-595  
 Zech C.J.: A-445, B-352, D-21  
 Zeisberger M.: C-326  
 Zelaquett C.: C-316  
 Zelger B.: B-230  
 Zeller T.: B-128  
 Zeng J.: B-525, C-813  
 Zeng M.-S.: B-238  
 Zenge M.O.: B-418  
 Zeotti D.M.: B-616  
 Zerbi A.: B-149  
 Zerolo I.: B-127  
 Zhang H.: B-208, B-425  
 Zhang H.D.: C-741  
 Zhang J.: B-477, B-480  
 Zhang K.: B-706, B-707  
 Zhang L.: C-232  
 Zhang Q.: C-744  
 Zhang S.: C-172  
 Zhang T.-M.: B-326  
 Zhang X.: B-548  
 Zhang X.-C.: B-326, B-825  
 Zhang X.P.: B-595, B-596, C-041  
 Zhang Y.: C-744  
 Zhang Z.: C-152, C-172  
 Zhao B.: B-769  
 Zhao W.: C-875  
 Zhao Y.: B-226, B-227, C-212, C-887  
 Zhao Y.R.: B-317, C-210, C-211  
 Zheng W.B.: C-741, C-742  
 Zhi X.: B-208  
 Zhong J.: B-423  
 Zhong N.: B-542  
 Zhou C.: B-618, C-774  
 Zhou L.: C-391, C-679  
 Zhou Z.: B-572
- Zhu A.: C-363  
 Zhu J.: C-444  
 Zhu Y.: B-070  
 Zhuang Z.: C-035  
 Zielonko J.: C-407  
 Zijlstra F.: B-442  
 Zimmerman R.A.: B-403, B-783  
 Zini C.: B-417, B-593, B-597, C-181, C-182, C-442, C-463, C-856  
 Zins M.: A-251  
 Zironi G.: B-720  
 Zizka J.: C-802  
 Zlokolica V.: C-751  
 Zo J.I.: B-224  
 Zodiatis P.: C-827  
 Zografos G.C.: C-089  
 Zonnenberg B.A.: C-759  
 Zorkaltsev M.A.: C-642  
 Zorn H.: C-326  
 Zou L.: B-572  
 Zou X.: B-572  
 Zoumpoulis P.S.: C-388, C-518  
 Zubarev A.: B-748  
 Zubieta J.L.: C-916  
 Zudaire B.: C-161, C-233, C-242, C-258, C-281, C-568, C-878  
 Zugaro L.: C-595  
 Zuguchi M.: C-134, C-861  
 Zuieni C.: B-048, B-263, B-287, B-492, B-494, C-025, C-447  
 Zuliani R.: B-544  
 Zunterer H.: B-510  
 zur Nedden D.: B-510, B-740, B-806, C-244  
 Zvezdin A.: C-438  
 Zwerner P.: B-556, C-185



**A**

Abd El Bagi M.: *SS 310*  
Adam A.: *EM 1, EM 2, EM 3, EM 4, NH 5*  
Adam E.J.: *SS 207*  
Adam G.B.: *CC 917*  
Åhlström Riklund K.: *MC 919*  
Al-Nakshabandi N.: *SS 1807*  
Andreu J.: *E<sup>3</sup> 1720*  
Antes G.J.: *SS 1801b*  
Arkun R.: *SS 210*  
Arredondo F.: *SS 601a*  
Aspelin P.: *SS 307*  
Aubé C.: *RC 901*  
Azavedo E.: *CC 1218*

**B**

Balassy C.: *SS 712*  
Bali M.A.: *SS 1401b*  
Baramia M.: *SS 210*  
Bargellini I.: *SS 715*  
Barkhausen J.: *SY 20*  
Bartolozzi C.: *SF 13, SY 14*  
Basak M.: *RC 1207*  
Basekim C.C.: *RC 1709*  
Basile A.: *RC 1609*  
Bastarrika G.: *SS 304*  
Baur-Melnyk A.: *RC 1610*  
Bekiesinska-Figatowska M.: *MC 125*  
Bellin M.-F.: *SS 1801a*  
Bellomi M.: *SS 1804*  
Bellon E.: *RC 105*  
Bérczi V.: *SS 609b*  
Berger F.: *SF 16b*  
Bianek-Bodzak A.: *SS 307*  
Bilbao J.-I.: *E<sup>3</sup> 620, FC Self Assessment Test*  
Bilecen D.: *SS 609a*  
Biscaldi E.: *SS 201b*  
Bischof Delaloye A.: *SF 9b*  
Bittoun J.: *RC 913*  
Bloem J.L.: *SS 1010*  
Bockisch A.: *RC 1213*  
Bohndorf K.: *E<sup>3</sup> 1220*  
Boijesen M.: *SS 204*  
Bojanovic A.L.J.: *RC 415*  
Borges A.: *SS 208*  
Bosnjakovic P.M.: *SS 1809*  
Boyer L.: *SS 315*  
Breatnach E.: *E<sup>3</sup> 520b*  
Brown G.: *CC 1316*

Bru C.: *SY 12*  
Bucek R.A.: *SS 215*  
Bücker A.: *SS 703*  
Burkart W.: *RC 1513*

**C**

Cakirer S.: *RC 1512*  
Carrió I.: *SS 206b*  
Carty H.M.L.: *PC 16*  
Castañer E.: *RC 1504*  
Castelijns J.A.: *E<sup>3</sup> 420b*  
Catalano O.: *RC 1606*  
Chapman S.: *SS 1812*  
Chateil J.-F.: *RC 1217*  
Chatziioannou A.: *RC 409*  
Chevrot A.: *RC 1710*  
Choi B.I.: *SS 701a*  
Chong V.: *SS 708*  
Christofides S.: *EF 2*  
Cianfoni A.: *SS 1811*  
Cinillo M.: *SS 1411*  
Claudon M.: *SS 1407*  
Correas J.-M.: *SS 1806a*  
Cova M.A.: *SS 1410*  
Crocetti L.: *SS 1801a*  
Cuénod C.A.: *SS 1406b*  
Curvo-Semedo L.: *SS 701a*  
Czermak B.V.: *SS 309*

**D**

Dalla Palma L.: *SS 1014*  
Damilakis J.: *SF 17b*  
Davies A.M.: *RC 1314*  
de Baère T.: *SS 709a*  
de Bondt R.B.-J.: *SS 1808*  
De Cobelli F.: *SS 1415*  
de Haan M.W.: *SS 215*  
de Roos A.: *SY 4, SY 15, SY 19*  
De Vries L.: *SY 13*  
Del Guerra A.: *SS 713*  
Deutschmann H.A.: *SS 1409*  
Di Cesare E.: *SS 303*  
Dietrich O.: *SS 713*  
Dimopoulou A.: *SS 609a*  
Dixon A.K.: *SF 12*  
Dobson H.: *SS 1802*  
Dondelinger R.F.: *SF 16a*  
Donoghue V.: *SS 712*  
Donoso L.: *PC 12*  
Drakonaki E.E.: *SS 1810*

**E**

Efremidis S.C.: *E<sup>3</sup> 720*  
Eggesbø H.B.: *SS 308*  
El Khoury C.: *CC 418*  
Escobar M.: *E<sup>3</sup> 1620*  
Essig M.: *NH 1*  
Exarhos D.N.: *CC 417*

**F**

Fabiano S.: *SS 1009*  
Faletti C.: *RC 110*  
Fausto A.: *CC 518*  
Fellner F.A.: *SY 7*  
Ferda J.: *SS 315*  
Fernandez-Bayó J.: *SS 305*  
Fishman E.K.: *SY 10*  
Flodmark O.: *CC 516*  
Flöry D.: *CC 1518*  
Forgács B.: *SS 610*  
Fotter R.: *RC 1612*  
Fournier L.S.: *CC 1718*  
Furancher F.: *SY 11*  
Furmanek M.I.: *RC 1115*  
Fütterer J.J.: *SS 1007*

**G**

Gambaccini M.: *RC 1213*  
Gangi A.: *SF 15b*  
Garcia Santos J.M.: *SS 1811*  
Gardarsdottir M.: *SS 603*  
Garvey C.: *RC 914*  
Gasparotti R.: *RC 1211*  
Girometti R.: *SS 207*  
Goldsher D.: *CC 916*  
Goodman P.: *SS 1404*  
Góraj B.: *SS 1011*  
Graif M.: *EM 3*  
Grammenou-Pomoni M.-S.: *RC 1715*  
Graser A.: *Face-Off Session*  
Grenier D.: *MC 425*  
Grenier N.: *MC 119*  
Grenier P.A.: *RC 1604*  
Grimm J.: *SS 206a*  
Günther R.W.: *SS 1415*

**H**

Haberkorn U.: *SF 16b*  
 Hadjidekov G.: *SS 203*  
 Hamm B.: *SF 5a, SY 6, SY 19*  
 Hanna S.A.A.Z.: *SS 1007*  
 Hausegger K.A.: *RC 1309*  
 Heinz-Peer G.: *E<sup>3</sup> 820*  
 Helbich T.H.: *E<sup>3</sup> 1820*  
 Heller M.: *SS 1815*  
 Herold C.J.: *PC 13*  
 Hiorns M.: *RC 1212*  
 Hoogewoud H.-M.: *SS 1009*  
 Huber S.: *RC 1514*  
 Huisman T.A.G.M.: *SF 9c*  
 Huppert P.E.: *SS 1401a*  
 Husband J.E.: *RC 807*

**I**

Imai Y.: *SS 201b*  
 Imhof H.: *RC 910*  
 Isherwood I.: *RC 1614*

**J**

Jackson J.E.: *RC 1509*  
 Jacquier A.: *SS 1403*  
 Jäger H.R.: *RC 1611*  
 Jevtic V.: *SS 1410*  
 Jökel M.: *RC 1614*  
 Jong R.A.: *SS 1002*

**K**

Kachelrieß M.: *CC 117*  
 Kainberger F.: *SF 17d*  
 Kaiser W.A.: *RC 1206*  
 Kalender W.A.: *SF 4*  
 Karssemeijer N.: *CC 1618*  
 Kaskarelis I.S.: *E<sup>3</sup> 420a*  
 Katz L.: *SY 3*  
 Kelekis N.L.: *SS 1803b*  
 Kettenbach J.: *E<sup>3</sup> 120a*  
 Khoo L.: *SS 202*  
 Kiessling F.: *SS 206b*  
 Kinkel K.: *E<sup>3</sup> 1820*  
 Klauser A.: *SS 1010*  
 Köcher M.: *SS 309*  
 Kornaat P.R.: *TF 1*  
 Kösling S.: *SS 1808*  
 Krestin G.P.: *EF 2, SA 12*  
 Kreuzberg B.: *RC 108*  
 Krumina G.: *RC 810*

Kubik-Huch R.A.: *SS 1802*  
 Kuhelj D.: *SS 709a*  
 Kulasekaran N.: *EM 4*

**L**

Laerum F.: *SF 17c*  
 Laghi A.: *E<sup>3</sup> 920b*  
 Laméris J.S.: *SS 301a*  
 Laniado M.: *EM 1*  
 Larsson E.-M.B.: *SS 1411*  
 Lavayssiere R.L.: *SS 202*  
 Leclerc X.: *SS 611*  
 Lecouvet F.: *RC 1210*  
 Leidecker C.: *RC 1613*  
 Lencioni R.: *E<sup>3</sup> 520a, SA 4*  
 Lisbona A.: *RC 1313*  
 Llopis E.: *RC 1310*  
 Loeckx D.: *SS 205*  
 Loewe C.: *CC 1716*  
 Lomas D.J.: *RC 101*  
 Lönn L.: *SS 1414*  
 Loose R.W.R.: *SS 305*  
 Lubicz B.: *SS 211*  
 Lubienski A.: *SS 301a*  
 Lucic M.A.: *SS 611*

**M**

Mack M.G.: *RC 1308*  
 Maksimovic R.: *RC 1703*  
 Malagari K.: *RC 404*  
 Malahias G.: *RC 907*  
 Maly Sundgren P.C.: *SS 311b*  
 Manfredi R.: *RC 507*  
 Maniatis V.: *SS 1801b*  
 Marchal G.: *CC 1217*  
 Marinček B.: *SF 5b, SY 1*  
 Maris T.G.: *SS 1413*  
 Marotti M.: *RC 801*  
 Marshall G.A.: *RC 1214*  
 Marshall N.: *SS 613*  
 Marten K.: *SS 604*  
 Masciocchi C.: *SS 610*  
 Maskell G.: *SS 701b*  
 Matson M.: *SS 709b*  
 McDermott R.: *SS 1404*  
 Meaney J.F.M.: *CC 1216*  
 Meindl T.: *SS 1407*  
 Menu Y.: *SA 15*  
 Merhemc Z.: *RC 1311*  
 Mester A.R.: *SS 1810*

Metafratzi Z.M.: *SS 1003*  
 Michaely H.J.: *J11Q*  
 Morcos S.K.: *SS 206a*  
 Morgan R.: *E<sup>3</sup> 220*  
 Morozov S.P.: *SS 711*  
 Mostbeck G.H.: *E<sup>3</sup> 1320*  
 Mueller-Mang C.: *SS 1804*  
 Müller M.A.: *SS 601a*  
 Müller-Schimpfle M.: *SS 1402*

**N**

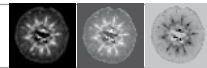
Nakajima M.: *SY 11*  
 Nakstad P.H.: *RC 811*  
 Natale L.: *RC 803*  
 Nemes B.: *SS 209*  
 Neri E.: *SS 1001b*  
 Neuwirth J.: *RC 104*  
 Nicholson A.: *SF 1*  
 Nicklin J.: *RC 1314*  
 Niessen W.J.: *SF 8b*  
 Norris D.G.: *NH 9*  
 Nyhsen C.: *TF 1*

**O**

Oikonomou A.: *SS 204*  
 Otto R.C.: *E<sup>3</sup> 120b*  
 Oudkerk M.: *RC 1303*

**P**

Pallardó Y.: *CC 817*  
 Papanicolaou N.: *SS 1401b*  
 Parizel P.M.: *E<sup>3</sup> 1420*  
 Parkar A.P.: *SS 704*  
 Pärtan C.: *SS 1005*  
 Passariello R.: *SS 205*  
 Patay Z.: *SS 711*  
 Paterson A.: *SS 1012*  
 Pattynama P.M.T.: *RC 815*  
 Pediconi F.: *RC 802*  
 Pedraza S.: *RC 111*  
 Peh W.C.G.: *SS 710*  
 Pellicanò G.: *RC 1711*  
 Peloschek P.: *SS 710*  
 Petrow P.: *SS 602*  
 Pfammatter T.: *E<sup>3</sup> 320*  
 Pierot L.: *RC 809*  
 Piñero P.: *SS 308*  
 Piotrowska-Kownacka D.: *SS 1003*  
 Pirich C.: *MC 519*  
 Popiela T.J.: *SS 609b*



Prassopoulos P.K.: *RC 401*  
Prokesch R.W.: *RC 1701*  
Pugliese F.: *SS 1803a*  
Puig Domingo J.: *CC 517*

**Q**

Ganadli S.D.: *SS 1403*

**R**

Raissaki M.: *RC 1513*  
Ratib O.: *RC 1313*  
Reddan D.: *SS 1806a*  
Reimer P.: *SS 709b*  
Reiser M.F.: *EM 1, EM 2, EM 3, EM 4,*  
*IL, HL 1, HL 2, HL 3*  
Rémy-Jardin M.: *SF 9a*  
Riccabona M.: *RC 1507*  
Riedl C.C.: *SS 1406b*  
Ringertz H.: *RC 1514*  
Rizzatto G.: *SS 302, SY 8*  
Robinson S.: *RC 408*  
Roche C.: *RC 1214*  
Rozanes I.: *SS 1409*  
Ruehm S.G.: *SS 715*  
Rummeny E.J.: *SF 15a*  
Ruscalleda J.: *RC 1511*

**S**

Salvador R.: *RC 402*  
Saraiva C.: *SS 303*  
Sardanelli F.: *SS 603*  
Sasiadek M.: *SS 311a*  
Schlegel W.: *EF 1*  
Schmidt S.: *SS 701b*  
Schneider G.K.: *SS 1803b*  
Schönberg S.O.: *SY 5*  
Schuknecht B.F.: *RC 1708*  
Schulz-Wendtland R.: *RC 1602*  
Semelka R.C.: *SY 2*  
Sentís M.: *SS 602*  
Siemianowicz A.: *SS 310*  
Silberman B.: *SS 1012*  
Sinitsyn V.E.: *CC 1616*  
Skilakaki M.G.: *SS 604*  
Smith A.: *SY 16*  
Smith H.-J.: *SS 1803a*  
Soffia P.: *RC 501*  
Soimakallio S.: *SS 209*  
Somers S.: *SS 1001b*  
Spüntrup E.: *RC 903*

Stern E.J.: *SS 704*  
Storto M.L.: *RC 1204*  
Strickland N.H.: *RC 405*  
Sunaert S.: *SS 1011*  
Svab I.: *EM 2*

**T**

Takis F.: *SS 1401a*  
Tali E.T.: *CC 1317*  
Tassiopoulos I.-H.: *SS 1014*  
Tay K.H.: *CC 1517*  
Taylor S.A.: *RC 1301*  
Thanassoulas K.: *RC 914*  
Thomsen C.: *RC 913*  
Thomsen H.S.: *SY 2*  
Tomà P.: *RC 1312*  
Torreggiani W.: *SF 8a*  
Tosetti M.: *EF 1*  
Trojanowska A.: *RC 808, SS 708*  
Turóczy G.: *SS 1005*

**U**

Urbanik A.: *SS 311a*

**V**

van der Molen A.J.: *SF 17a*  
van der Putten W.J.M.: *SS 1413*  
van Rijn R.R.: *SS 1812*  
Vandecaveye V.: *SS 208*  
Varian C.: *SY 9*  
Vassiou K.: *SS 1402*  
Veltman J.: *SS 1002*  
Verdun F.R.: *SS 1013*  
Verschakelen J.A.: *E<sup>3</sup> 1020*  
Viehweg P.: *RC 1302*  
Vilanova J.C.: *SS 1807*  
Vilar J.: *RC 504*  
Vilela P.: *SS 1815*  
Vliegenthart R.: *SS 703*  
Vock P.: *SS 613*  
Votrubová J.: *SS 304*  
Vulev I.P.: *SS 1809*

**W**

Walchenbach J.: *SY 18*  
Walecki J.: *SS 211*  
Wallis M.G.: *E<sup>3</sup> 920a*  
Watkinson A.: *IIQ*  
Weishaupt D.: *CC 116*  
Weum S.: *SS 302*

White C.S.: *SS 203*  
Willis S.: *SS 1414*  
Wilson D.J.: *E<sup>3</sup> 1520*  
Wirth S.: *RC 1613*

**Y**

Yousry T.A.: *SS 311b*

**Z**

Zanetti M.: *CC 816*  
Zdesar U.: *SS 1013*  
Zonderland H.M.: *RC 1502*













# ECR 2009

**European Congress of Radiology**

March 6-10, Vienna / Austria

*the summit of science*



The annual meeting of



[myESR.org](http://myESR.org)



[myESR.org](http://myESR.org)