

A 3D Stereo System to Assist Surgical Treatment of Prostate Cancer

Dongbin Chen, Erik Mayer, Justin Vale, Ann Anstee, Lin Mei, Ara Darzi, Guang-Zhong Yang, and Philip Edwards

Dept. of Biosurgery and Surgical Technology, Imperial College, London, UK
dchen1,l.mei,a.darzi,eddie.edwards@imperial.ac.uk *

Abstract. This paper presents our work to establish the feasibility and utility of a system for guiding robotic removal of the prostate (radical prostatectomy). The guidance is based on preoperative imaging aligned to the patient on the operating table and presented to the surgeon as graphics overlaid on the stereo laparoscopic view through the da Vinci robot. The results of preoperative and intraoperative data collection and processing are presented, along with stereo calibration and visualisation on the surgical scenes. We have gathered data on 8 patients for retrospective evaluation. We have identified the relevant anatomy that should be modelled: the prostate itself, urethra, surrounding nerve bundle, seminal vesicles and the pelvic bone for registration. Stereo visualisation provides good depth perception, which we will present at the workshop. At present registration is by direct alignment to the endoscope view, but we plan to incorporate transrectal ultrasound to compensate for soft tissue motion. There will be full clinical evaluation on 20 patients in the next phase of this project. From the outset we have considered the path to clinical implementation and guidelines are presented that could be followed by any researchers aiming to provide augmented reality surgical guidance.

1 Introduction

1.1 Clinical Need

Prostate cancer is increasing in an aging population and is now the most common form of cancer among men in the UK. Robot-assisted prostatectomy is becoming an accepted form of surgical treatment [1]. There are significant rates of complication, however, from both robotic and open radical prostatectomy. These include impotence, incontinence and recurrence of disease due to incomplete resection. We propose that complication rates can be reduced for robotic procedures using augmented reality (AR) guidance. Overlay of correctly aligned

* We would like to thank Cancer Research UK for funding this project (C24520/A8087). We are also grateful to many other members of the Department of Computing and the Department of Biosurgery and Surgical Technology at Imperial College as well as the radiology and theatre staff at St. Mary's Hospital, London.

3D anatomy and pathology derived from preoperative imaging should help the surgeon to achieve full extraction of the diseased tissue while preserving as much as possible of the surrounding neurovascular bundle, leading to better outcomes for the patient.

1.2 Previous Work

Image guidance is now an accepted tool in neurosurgery, ENT, maxillofacial surgery and orthopaedics [2, 3]. Visualisation usually shows the location of a pointer or tool in orthogonal cuts through the preoperative dataset, but AR solutions showing virtual structures overlaid on an optical or camera view of the patient have also been proposed [4–6].

Within the abdomen image guidance has been proposed to aid liver surgery [7, 8], but though AR laparoscopy has been suggested [9], only a single clinical demonstration of AR guidance for adrenalectomy has so far been reported [10].

There are a number of technical hurdles that must be overcome to achieve AR guidance. The optics of the stereoendoscope must be calibrated. The preoperative scan must be registered to the physical position of the patient relative to the endoscope coordinate system. If there is tissue deformation, this registration is non-rigid. Finally, the aligned model must be presented to the surgeon in real time using visualisation that enables correct 3D perception of structures.

In this work we aim to follow a clear path that should lead to a clinically useful system. This follows a three stage approach — retrospective evaluation, intraoperative evaluation and initial clinical use. In all phases the involvement of clinicians is key and the gradual introduction of equipment into the operating room will ease the acceptance the system. We are currently approaching the end of the first phase of this project, where preoperative imaging and intraoperative stereo video data are gathered and evaluated. We present the hardware configuration of the system and describe 3D model construction from preoperative data, stereo optical calibration and our implementation of AR visualisation. Results are given for calibration as well as evaluation on a phantom and 8 patients.

2 Methods

2.1 Hardware Configuration and System Integration

Hardware configuration of the system is shown in Figure 1. The da Vinci robot has a master and slave configuration. The stereoendoscope video images are captured using a multi-input framegrabber (the Active Silicon LFG4) with input from the camera controller on the da Vinci stack. The system software runs on a 64-bit linux workstation (HP XW9400) with dual graphics output (2 x NVidia Quadro FX1400). The graphics and video are merged by two video mixers (Edirol LV4) using the chroma-key function. We decided to use video mixers rather than merging the graphics on the workstation since this ensures there is no lag introduced and means that the normal surgical view is not dependent on

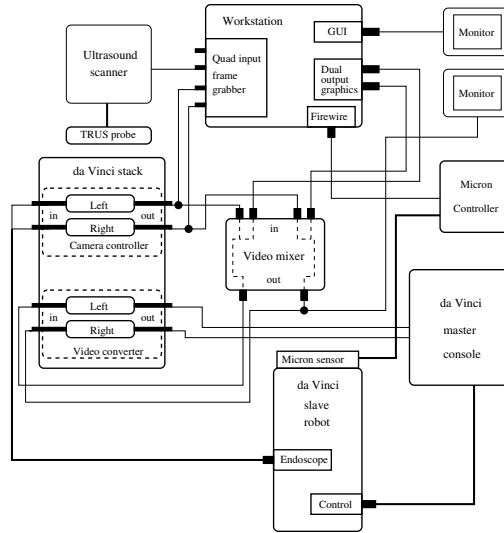


Fig. 1. The system configuration. The guidance is provided from a workstation which takes as input the stereo video from the da Vinci robot along with tracking and registration data from the MicronTrackerTM and ultrasound scanner and produces aligned graphics. AR is provided using two video mixers to avoid lag in display of the real data

the function of the workstation. An optical tracker can be incorporated (the MicronTracker2 from Claron Technologies). Though not yet incorporated, we aim to include an ultrasound scanner for tracking of soft tissue motion during surgery.

The proposed system provides 3D visualisation of graphics overlaid on the surgical scene through the robot’s stereoendoscope. We will display preoperative image information showing the location of anatomical and pathological structures accurately aligned to the patient. The 3D nature of the overlaid virtual features will enable the surgeon to view structures such as the vas deferens, seminal vesicles and the neurovascular bundle beneath the operative surface, effectively providing “X-ray eyes”.

2.2 Preoperative Imaging Model

As the first step in deciding on an imaging model, we identified the relevant anatomy in consultation with clinicians. For guidance of surgery several features are of interest. These include the prostate itself, the urethra, rectum, seminal vesicles and the surrounding nerve bundle. Most of these can be seen on MRI, though the nerves can be difficult to identify. In addition to the local anatomy we need to extract the bone of the pelvis for registration. This would ideally come from a CT scan registered to MRI, but we would like to build our model from MRI alone. This can be problematic, since bone does not enhance with

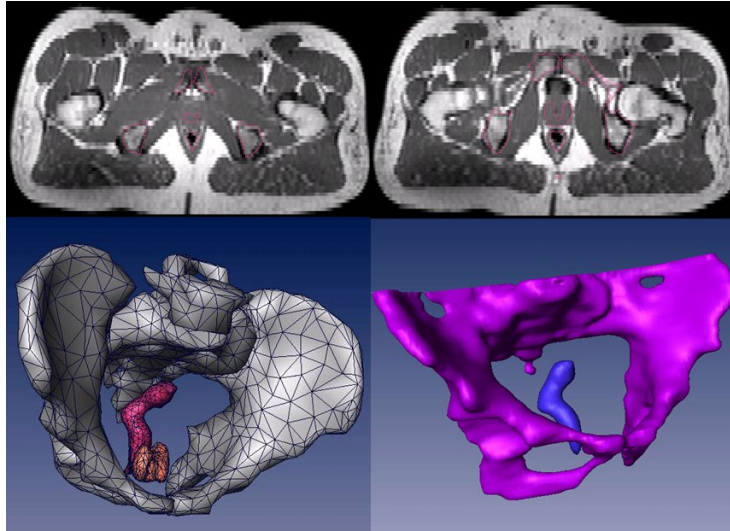


Fig. 2. Atlas segmentation. Overlaid on the patient MRI (top) we see the segmentation resulting from registration of the Atlas to the patient. A 3D rendering of the warped atlas (bottom left) and corresponding manual segmentation (bottom right) are shown.

MRI. We are examining whether registration to a template CT scan can provide bone segmentation from MRI.

For our initial group of patients, manual segmentation has been performed to create a 3D model. This is a laborious task. The advantage of expert manual segmentation is the high accuracy of results. We are working on automated atlas segmentation guided by a statistical shape model of the lower abdomen. To this end we are building a database of scans to ensure sufficiency of the training set and are developing techniques to establish that the shape model has stabilised. Comparing the results with expert segmentation, we achieve errors of the order of 2 voxels.

We have used atlas segmentation to obtain 3D models from 12 patients respectively. Figure 2 shows a 3D model of prostate, pelvis and rectum segmented from a patient’s scan data. Comparing the warped atlas to the manually segmented patient model, we can see that there are some small differences. We are examining whether a final correction of the registration can be applied to improve the results further.

2.3 Stereo Camera Calibration

Stereo camera calibration is vital component for accurate overlay on the 3D surgical scene. We use Bouguet’s Matlab camera calibration toolbox [11] to calibrate the stereo camera system. We first determine intrinsic calibration parameters to each endoscope. These parameters include internal parameters of the pinhole

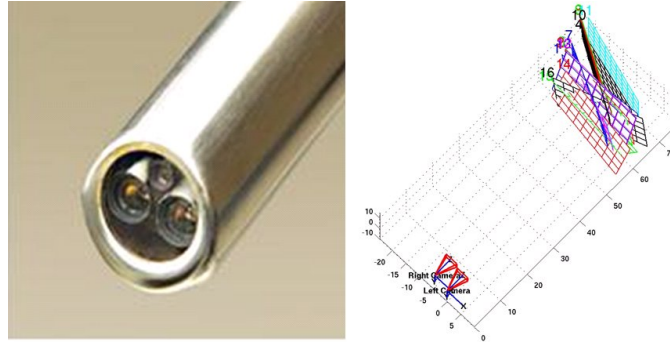


Fig. 3. The da Vinci stereo endoscope and an example of the resulting calibration from the Matlab toolbox

model plus parameters describing lens distortion. The position and orientation of one camera is established with respect to the other in the stereo phase of the calibration. Figure 3 gives the reconstruction of locations between the stereo camera and images captured for the calibration.

2.4 System for Augmented Reality Guidance and Retrospective Overlay

As well as providing a system for live overlay in the operating room, we have developed software for retrospective augmented reality. We can also control the position and orientation of the 3D models overlaid on recorded intraoperative video. The software interface displays a 3D surgical scene with overlay as a pair of stereo images, which can be viewed using a simple set of prism glasses. This retrospective overlay system enables experimentation with different rendering paradigms and allows us to examine which visualisations provide useful guidance and accurate depth perception. This can be done without taking up time in the operating theatre.

For live overlay, the workstation simply displays graphics on a blue background. The video mixers then merge this with the live endoscopic video using the blue color as the background colour for chroma-keying. Registration is currently achieved by manual alignment with the visible pelvic arch, but we are working on automated alignment to the stereo video and refinement using transrectal ultrasound.

3 Results

Figure 4 shows overlay on a prostate phantom. The overlay shows pelvis, prostate, urethra and seminal vesicles. Figure 5 shows an example of augmented reality on a real intraoperative patient view. We have collected such data on 8 patients and will present these at the workshop.

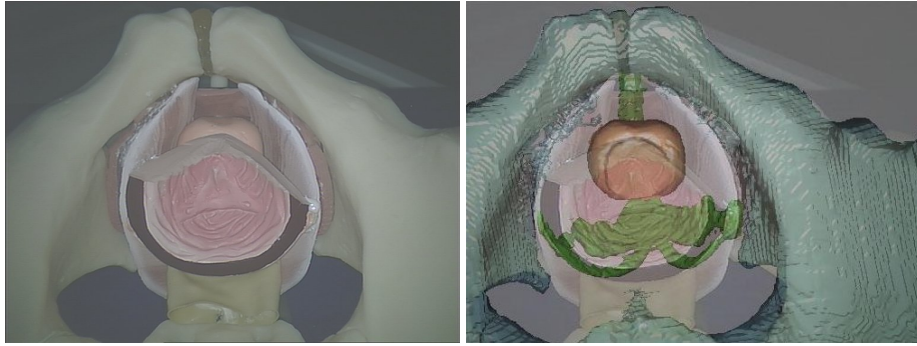


Fig. 4. Overlay on the anatomical phantom of the pelvis and prostate. The visible structures (e.g. pelvis) are seen to be correctly aligned and the underlying prostate and seminal vesicles are visible in the augmented view.

4 Guidelines and Principles for the Clinical Introduction of Augmented Reality

As with all systems that aim to provide augmented reality surgical guidance, our intention is to have a clinically usable system that provides benefits for the surgeon and patient. Our experience in developing such systems has led to a number of guidelines that may be useful to other researchers.

4.1 The Three Stage Approach

We propose the introduction of AR in the following three phases.

1. Retrospective evaluation
2. Intraoperative evaluation
3. Initial clinical introduction

In the first stage, information preoperative imaging and intraoperative video data is gathered. Evaluation can then be performed after the operation. Identification of critical points in the procedure that could benefit from guidance is possible at this point and many different visualisation methods can be evaluated. The gathered data also enables testing of algorithms for registration. The result of this phase should be a protocol for both the software and the intraoperative workflow, identifying which anatomy or pathology should be shown and when.

In the second phase the system should be fully functional in-theatre. The surgeon can then view and evaluate the displays and provide vital feedback. At this point, however, the surgeon should only be evaluating the system and the guidance must not be used to influence surgical decision making. This enables the guidance methodology to be tested and developed in accordance with clinical requirements and should result in a stable system.

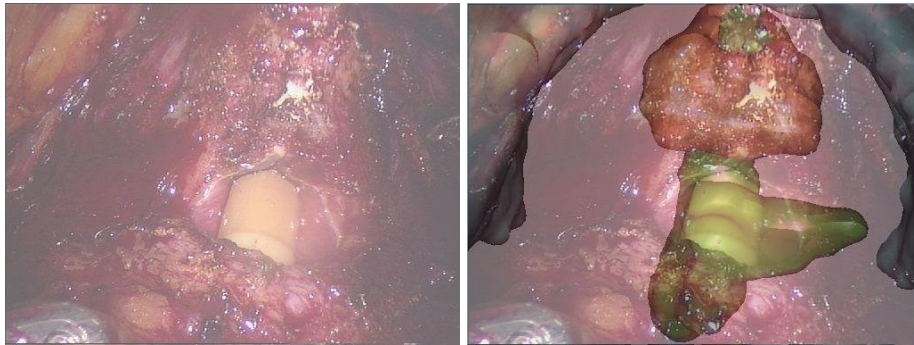


Fig. 5. An example overlay on a patient. Alignment is achieved using the pubic arch. The urethra is seen to match well (green). The position of the prostate before excision is shown in red.

The final phase is clinical evaluation where the surgeon can use the system to influence the procedure. Since the surgeon will be familiar with the system from the previous phase this reduces the risk of incorrect decision making, perhaps from inaccurate guidance or overestimation of the system accuracy.

Having these three clear phases give a simple and relatively safe process for the introduction to the operating theatre and can be useful when obtaining ethical approval.

4.2 General Principles for Clinical AR

As a result of our experience over many years, we have adopted the following principles that might be useful for other AR researchers to consider:

1. Ensure that there is a clinical need for guidance
2. Use the three stage approach (see above)
3. Use existing equipment wherever feasible
4. Introduce innovations one at a time (as far as possible)
5. Obtain and document feedback from clinicians
6. Minimise disruption to the normal clinical workflow
7. Ensure existing systems are available as a fallback
8. Do not allow clinical reliance on research systems until stage 3

Failure to follow these guidelines may lead to slow adoption of AR technology.

5 Discussion and Future Work

We have presented a system for augmented reality guidance of robotic prostactectomy. Though we are currently at the first phase of retrospective overlay,

the path to clinical implementation in the next two years is clear. We have described principles and guidelines for the adoption of AR into the clinical setting that other researchers should consider for their systems.

There are a number of technical developments in progress. The problem of accurate perception of depth has been noted by several previous authors and is an active area of our research [?,?] We are automating the segmentation and preoperative model building from MRI. We would like to have a live optical calibration that can be used during the operation. The principal technical issue for any guidance system is registration. We are working on automated rigid alignment to the stereoendoscope view and updated alignment using transrectal ultrasound to follow soft tissue deformation. It is expected that the overall system will lead to reduced rates of incontinence, impotence and disease recurrence to the benefit of prostate cancer patients.

References

1. Kaul, S., Savera, A., Badani, K., Fumo, M., Bhandari, A., Menon, M.: Functional outcomes and oncological efficacy of vattikuti institute prostatectomy with veil of aphrodite nerve-sparing: an analysis of 154 consecutive patients. *BJU Int.* **97** (2006) 467–472
2. Aquilina, K., Edwards, P.J., Strong, A.J.: Principles and practice of image-guided neurosurgery. In Moore, M.A., ed.: Springer Specialist Surgical Series: Neurosurgery (In Press). Springer Verlag (2003)
3. Wadley, J.P., Dorward, N.L., Breeuwer, M., Gerritsen, F.A., Kitchen, N.D., Thomas, D.G.T.: Neuronavigation in 210 cases: Further development of applications and full integration into contemporary neurosurgical practice. In Lemke, H., Vannier, M., Inamura, K., Farman, A., eds.: Proceedings of Computer-Assisted Radiology and Surgery 1998, Elsevier, Amsterdam (1998) 635–640
4. Edwards, P.J., King, A.P., Maurer, Jr., C.R., de Cunha, D.A., Hawkes, D.J., Hill, D.L.G., Gaston, R.P., Fenlon, M.R., Juszczak, A., Strong, A.J., Chandler, C.L., Gleeson, M.J.: Design and evaluation of a system for microscope-assisted guided interventions (MAGI). *IEEE Trans. Med. Imaging* **19**(11) (2000) 1082–1093
5. Birkfellner, W., Figl, M., Matula, C., Hummuel, J., Hanel, R., Imhof, H., Wanschitz, F., Wagner, A., Watzinger, F., Bergmann, H.: Computer-enhanced stereoscopic vision in a head-mounted operating binocular. *Phys. Med. Biol.* **48** (2003) N49–N57
6. Rosenthal, M., State, A., Lee, J., Hirota, G., Ackerman, J., Keller, K., Pisano, E.D., Jiroutek, M., Muller, K., Fuchs, H.: Augmented reality guidance for needle biopsies: An initial randomized, controlled trial in phantoms. *Med. Image Anal.* **6** (2002) 313–320
7. Herline, A.J., Herring, J.L., Stefansic, J.D., Chapman, W.C., Galloway, R.L., Dawant, B.M.: Surface registration for use in interactive, image-guided liver surgery. *Comput. Aided Surg.* **5**(1) (2000) 11–17
8. Penney, G.P., Blackall, J.M., Hamady, M.S., Sabharwal, T., Adam, A., Hawkes, D.J.: Registration of freehand 3D ultrasound and magnetic resonance liver images. *Med. Image Anal.* **8** (2004) 81–91
9. Fuchs, H., Livingston, M.A., Raskar, R., Colucci, D., Keller, K., State, A., Crawford, J.R., Rademacher, P., Drake, S.H., Meyer, A.A.: Augmented reality vi-

- sualization for laparoscopic surgery. In: Proc. Medical Image Computation and Computer-Assisted Intervention. (1998) 934–943
10. Marescaux, J., Rubino, F., Arenas, M., Mutter, D., Soler, L.: Augmented-reality assisted laparoscopic adrenalectomy. *J. Am. Med. Assoc.* **292**(18) (2004) 2214–2215
 11. Bouguet, P.: A camera calibration toolbox for matlab