

Developing new tool for automatic analysis of IVUS images: from border detection to plaque characterization

ARASH TAKI¹ (TAKI@CS.TUM.EDU), SARA AVANSARI², ALIREZA ROODAKI³, S.H REZATOFIGHI³, S.K.SETAREHDAN³, NASSIR NAVAB¹

¹ Department of Computer Aided Medical Procedures (CAMP) - TU Munich, Germany

² Faculty of Computer Science, University of Tehran, Iran

³ Faculty of Electrical and Computer Engineering, University of Tehran, Iran

Purpose:

One of the main causes of mortality is atherosclerosis which leads to sudden cardiac attack. Frequently the first symptom of coronary artery disease is acute coronary syndromes (ACS) which is mainly caused by the rupture of a coronary artery. Histopathological studies have revealed that generally atherosclerotic plaque rupture results in thrombi. Atherosclerosis components of clinical importance are calcium, fibrous, necrotic, and lipid rich tissue.

Size and pattern of each plaque component existing in the plaque area can define the nature of problem. Thus, precise characterization of plaque lesions provides physician with better understanding of the vessel disease situation to choose the appropriate treatment strategy and assessment of the therapy effectiveness too.

Grayscale intravascular ultrasound (IVUS) provides real-time and high-resolution tomography visualization of the coronary arteries. Lumen and vessel dimensions, and the distribution of different plaques can be analyzed through inspecting images driven by IVUS imaging modality. Moreover, intra luminal thrombus presence and plaque rupture assessment can be done by employing grayscale IVUS.

Applying the informative rich IVUS frames of each patient and performing manual analysis of cross section area (CSA) images is not only time consuming but also prone to the inter-observer and intra-observer variability. Furthermore, the clear identification of non-classified, i.e. fibrous or rich lipid, plaques are especially difficult. Thus, developing a device capable of characterizing plaque components by IVUS images automatically is of great importance.

Virtual Histology (VH) provides a colored coded plaque characterization technique using analysis and classification of the radio-frequency (RF) component of the backscattered ultrasound signal. For improving the longitudinal resolution of VH, it would be desirable to retain more of the data by collecting multiple frames per cycle, as long as they are captured when the heart and catheter are similarly oriented. Therefore, developing a new characterization technique might be of great value for complementing VH technology.

In this paper, a new tool capable of automatic IVUS image analysis is proposed. It has two main sections. One is the border detection, where the intima and the media-adventitia borders are detected. The other is plaque characterization in which the pixels in the plaque area are classified to different plaque types based on their textural behavior. In this study the number of classes was reduced to three classes instead of four, by combining the fibrous and lipid classes.

Method:

The intima and the media-adventitia borders are detected in IVUS images of the coronary arteries applying parametric deformable models (Snake). Then, the area between the intima and media-adventitia borders is considered as the plaque region. In the next step, textural features are extracted from the plaque region.

Here, three feature extraction methods were used for recognizing four substances (i.e. calcium, fibrous, necrotic core, and lipid core). One is Local Binary Pattern (LBP) and the other is discrete wavelet transform, energy and entropy of sub-images from different scales, and the third one is the Co-occurrence matrix. Here, images are swept by a 7*7 window. The wavelet decomposition level was set to 2.

After feature extraction step, feature vectors are then classified into the defined plaque types using a Support Vector Machine (SVM) classifier.

To obtain a standalone executable application, the program with a graphical user interface (GUI) was compiled by C++ compiler in Microsoft Visual Studio 2005 as shown in Figure 1.

Result:

Our study group is consisted of sequences of IVUS images acquired from five patients. These images with the digitized matrix size of 400*400 pixels were acquired using a 30-MHz transducer at a 0.5 mm/s pullback speed. Out of the frames in which all types of plaques were detected by the VH method, 20 frames were selected for each patient. The three mentioned methods were then applied on the set of 100 frames.

The area difference and average distance (AD) (mean \pm SD %) of the snake method in comparison with two experts for the intima and the media-adventitia areas have been computed. These measures were 7.54 \pm 4.62% (mm) and 0.3 \pm 0.25% for the intima border, respectively. The values for the media-adventitia were 6.12 \pm 1.8% and 0.3 \pm 0.01%, respectively.

The characterized IVUS images were validated by their corresponding VH images and the accuracy, sensitivity, and specificity parameters were calculated for each technique. The comparative results of three proposed methods were illustrated in Table 1.

Table 1. The comparative results of three proposed methods

	Calcium		Fibrolipid		Necrotic		Overall
	Sensitivity	Specificity	Sensitivity	Specificity	Sensitivity	Specificity	
LBP	60%	87%	77%	77%	41%	80%	62%
Co-occurrence	65%	88%	80%	77%	43%	81%	68%
Wavelet	63%	89%	85%	79%	47%	83%	70%

It can be inferred from the Table I that the 2D wavelet transform method has more capability for classifying fibrolipid and necrotic plaques in comparison with the other methods. In addition, the overall accuracy of the modified 2D wavelet transform is higher than the others. But, the co-occurrence method performs better in characterizing the calcified regions. For a typical frame the 2D wavelet transform method took approximately 37 seconds to characterize the pixels, whereas the LBP took 1.5 minutes and the co-occurrence took nearly 6 minutes on the same computer. Thus, in terms of time efficiency, the 2D wavelet transform method further outdoes the other two. The best method, 2D wavelet transform, was employed in the GUI for plaque classification.

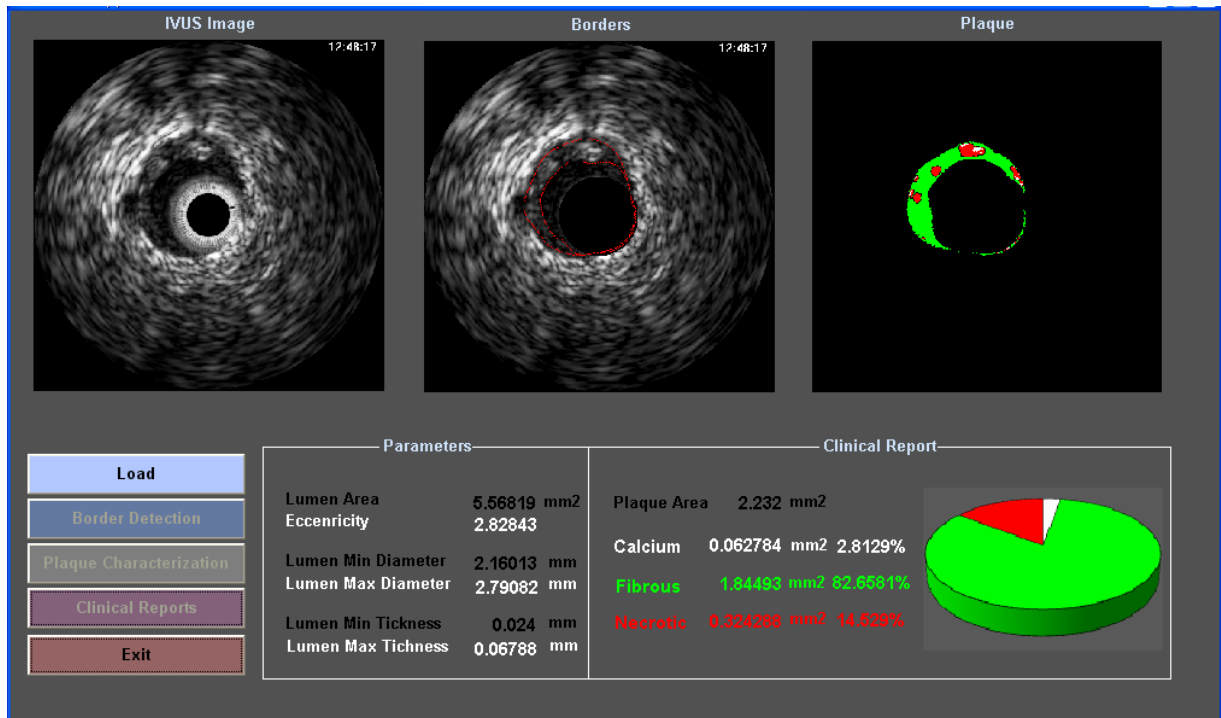


Figure 1: An example of the GUI window

Conclusion:

Here we proposed a precise tool for automatic IVUS image border detection and plaque characterization. According to the results of this study the modified 2D wavelet transform seems to be more powerful than the co-occurrence and the LBP methods in terms of both time efficiency and classification accuracy.

Moreover, this system provides physicians with some analytical parameters such as Lumen Area, Eccentricity, and min-max Lumen Thickness which can help them to accurately decide about the patient's disease.