

PSMA-PET/MRI-guided transrectal fusion biopsy for the detection of prostate cancer

Enno Storz¹, Amit Shah², Oliver Zettinig², Matthias Eiber³, Hans-Jürgen Wester⁴, Hubert Kübler¹, Jürgen E. Gschwend¹, Markus Schwaiger², Benjamin Frisch², Tobias Maurer¹
¹Department of Urology, ²Institute for Informatics, Computer Aided Medical Procedures, ³Department of Nuclear Medicine ⁴Department of Pharmaceutical Radiochemistry
 Klinikum rechts der Isar der TU München, Munich Germany

EAU #217

Introduction & Objectives

Despite its low sensitivity transrectal ultrasound (TRUS)-guided random biopsy (RB) represents still the gold standard for the diagnosis of prostate cancer (PCa). However, with the advent of modern fusion biopsy systems enabling fusion of preinterventional MR-imaging of the prostate to TRUS and thus targeting suspicious areas more accurately increased detection rates are reported. Recently, PET-imaging using a novel 68Gallium-labelled ligand of the prostate-specific membrane antigen (PSMA) has been introduced in the diagnostic work-up of PCa. Therefore, the aim of this initial study was to determine the accuracy of PCa detection by PSMA-PET/MR imaging using a newly established open source framework for fusion biopsy guidance.

Material & Methods

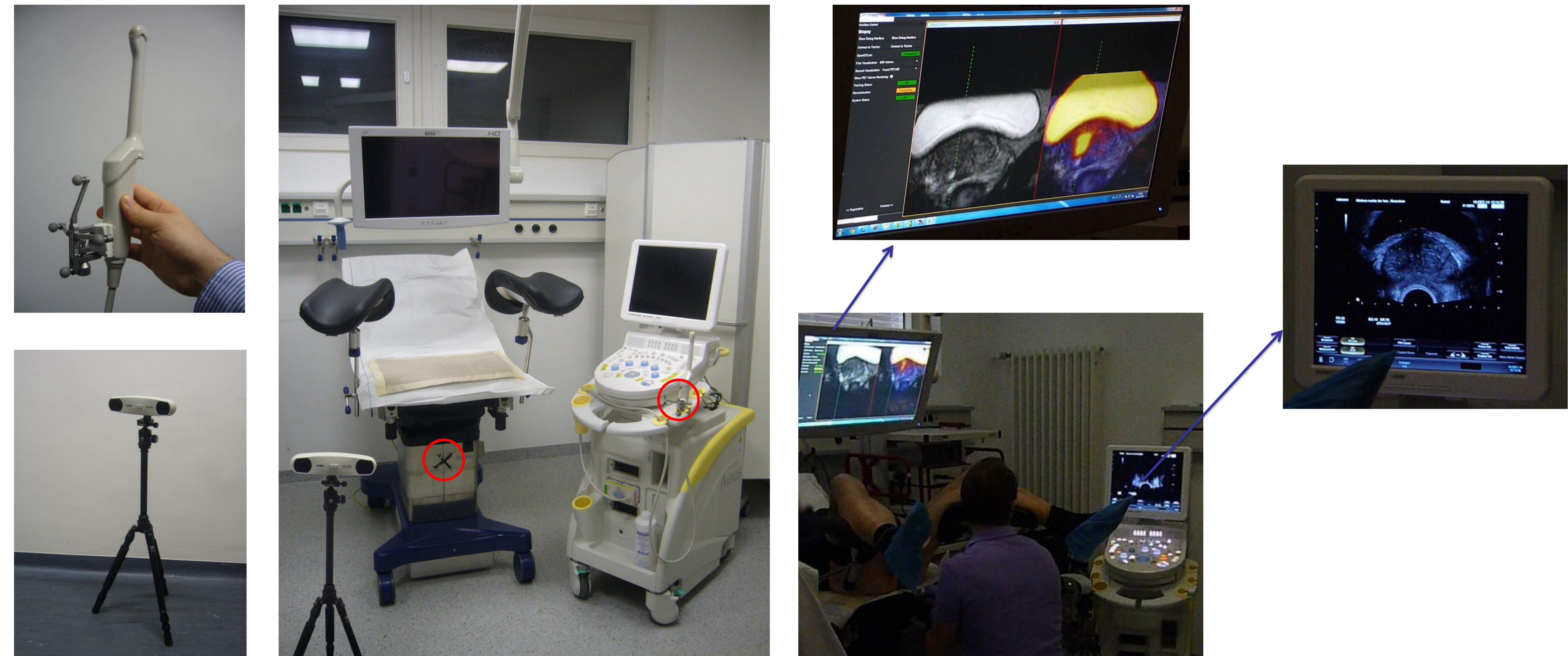
16 patients (age 45-75 years; median PSA 7.82 ng/ml (range 4.0 – 13.2 ng/ml)) who had at least one prior negative prostate biopsy were included in this study. Every patient underwent multiparametric PSMA-PET/MR imaging of the prostate. All patients received a systematic 10-core random biopsy as well as fusion-guided transrectal biopsy of suspicious lesions on PSMA-PET/MR in an outpatient setting. Results of imaging and histological analysis of prostate biopsies were compared per patient and per prostate sextant (apical, medial, basal).

Results

On PSMA-PET/MRI 44% (7/16) of the prostates revealed at least one PCa-suspicious lesion, 31% (5/16) were described as equivocal and in 25% (4/16) no suspicious lesion was present. The pathological analysis revealed PCa in 50% (8/16) of all patients – six patients with suspicious findings and two with equivocal findings on PSMA-PET/MRI. Of note, histological analysis did not show PCa in any of the patients with inconspicuous PSMA-PET/MRI. On a sextant basis, 23% (22/96) were suspicious on PSMA-PET/MRI. In 16% of all sextants (15/96) PCa was histologically proven. 80% (12/15) of these areas, where PCa was found, were also suspect on PSMA-PET/MRI.

Conclusions

In this initial analysis, PSMA-PET/MRI in the combination with a newly developed fusion biopsy system proved as valuable tool for the detection of PCa in patients after prior negative prostate biopsy. However, greater patient cohorts are necessary to establish the exact clinical role of PSMA-PET/MRI-guided fusion biopsy.



The transrectal PSMA-PET/MRI-guided fusion biopsy - Assembly and its visualization of the prostate during the biopsy

Left: On the top the handy optically trackable TRUS probe is demonstrated. Four reflecting tracking balls are fixed to the probe. The picture below shows the optical tracking camera.

Middle: The assembly of the biopsy-system with a commercially available ultrasound-system, the operation chair, the tracking camera and the additional screen. During the biopsy the tracking camera has to be focused on the tracking balls (red circled).

Right: Visualization of a biopsy. Using the optically tracked TRUS probe a complete ultrasound-based scan of the prostate has to be performed at the beginning. It is visualized on the ultrasound system and the connected external computer. The following overlay of the PSMA-PET/MRI- and ultrasound-datasets can be realized automatically within 3 minutes. During the biopsy the MRI- and the PSMA-PET/MRI datasets are visible on an additional screen and can be correlated with the ultrasound images all the time.

The lines of green dots on the magnified screens represent the guidance for the planned biopsy. The exact overlay of the images is offering a very good possibility to get a histological tissue sample of any suspicious area of the prostate – based on ultrasound, MRI or PSMA-PET imaging.

Histopathology \ PSMA-PET/MRI	PSMA-PET/MRI		Total (patients)
	Suspicious	Equivocal or unsuspecting	
PCa positive	6	2	8
PCa negative	1	7	8
Total (patients)	7	9	16

Histopathology \ PSMA-PET/MRI	PSMA-PET/MRI		Total (sextants)
	Suspicious	Equivocal or unsuspecting	
PCa positive	12	3	15
PCa negative	10	71	81
Total (sextants)	22	74	96

Comparison of the PSMA-PET/MR-imaging and the histopathological results of the biopsies.

The left table shows the comparison of the preinterventional imaging and the final histological results on patient level. Six of the PCa-positive patients had suspicious findings in their PSMA-PET/MRI, the other two patients had equivocal areas in their prostates. No cancer was found in PSMA-PET/MRI-negative patients.

The right table demonstrates the results on the sextant-level. Nearly all PSMA-PET/MRI-negative sextants were also negative in histology. 80% (12/15) of the histological PCa-positive sextants were also positive in the PSMA-PET/MRI.