

# Photon Attenuation Correction in Misaligned PET/CT Cardiac Perfusion Images

Axel Martinez-Möller<sup>1,2</sup>, Nassir Navab<sup>2</sup>, Markus Schwaiger<sup>1</sup>, Stephan G. Nekolla<sup>1</sup>

<sup>1</sup> Nuclear Medicine Department, Klinikum Rechts der Isar der TU München, Germany

<sup>2</sup> CAMP, Computer Science Department, TU München, Germany

## Abstract

The purpose of this work is to understand, quantify and minimize the impact of the emission-transmission misalignment which has been reported as a source of artefacts in cardiac PET/CT. A new and fully automatic correction algorithm is proposed to realign the  $\mu$ -map contour of the left ventricle to the measured PET. PET/CT  $\text{NH}_3$  rest/stress scans were acquired for 16 patients in order to evaluate the consequences of the misalignment and the uptake recovery achieved by the algorithm.

## 1 Introduction

Despite the use of combined PET/CT devices, misalignment between the CT (transmission scan) and the PET (emission scan) images has been reported [1]. The main reason is the different respiratory state in both modalities: CT is acquired in a few seconds showing a fraction of the respiratory cycle, whereas PET shows an image averaged over the whole respiratory cycle. Other reasons include patient motion and, in the case of rest-stress studies, an observed modification of the heart position caused by pharmacologically induced stress [2].

Since the photon attenuation correction is done using an attenuation map computed from the CT transmission scan [3], a mismatch between the two scans can have an impact on the reconstruction of the PET image. Therefore, artefacts can appear, especially if the misalignment happens at the interface between two body tissues with very different attenuation factors, like it is the case at the border between the heart and the left lung.

In this work, the impact of the emission-transmission misalignment on PET/CT  $\text{NH}_3$  cardiac perfusion imaging is quantitatively evaluated, and a new correction method to significantly reduce this impact is proposed and validated.

## 2 Methods

### 2.1 Protocol

16 patients were enrolled in this study. For each patient, a PET/CT  $\text{NH}_3$  rest/stress examination was performed. This protocol consisted of a low-dose CT (120kV, 26mA) performed in shallow breathing

followed by 2 PET scans, one in rest and one in pharmacologically induced stress achieved by a 6-min infusion of adenosine. Images were acquired using a Siemens Biograph 16 PET/CT.

With the fused images, the PET-CT misalignment for each of the scans was visually evaluated in 3 categories: aligned, mild misalignment, major misalignment. To validate the proposed correction algorithm, misalignment was artificially introduced in the aligned scans and the recovery achieved by the algorithm was quantitatively evaluated by measuring the average tracer uptake prior and after correction in 5 regions corresponding to the anterior, lateral, posterior and septal myocardial walls, and the apex.

### 2.2 Correction method

The correction algorithm consists in the following numerical operation: for each voxel belonging to the left ventricle in PET, it is evaluated whether the attenuation factor of this voxel belongs to the expected attenuation factor corresponding to the heart. If it is below, the factor is replaced by an average tissue value  $\mu$  computed as the mean of all other attenuation factors of the left ventricle from this scan belonging to the expected range. All voxels not belonging to the segmented left ventricle are not modified.

The segmentation of the left ventricle is based on a priori knowledge of the acquisition, assuming that the spatial centre of the left ventricle is placed in the intermediate axial plane and belongs to the left side of the body. Due to the large target to background ratio with  $\text{NH}_3$  perfusion imaging, a simple histogram thresholding on the approximate location

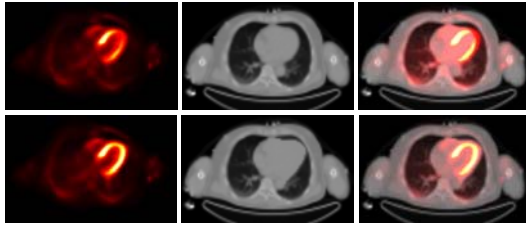
of the left ventricle yields excellent segmentation results. Once the left ventricle is segmented out of the PET image, the modification of the attenuation map is performed using the previously described procedure.

The execution time for the correction method including segmentation of the left ventricle and modification of the attenuation map was less than one second on standard PC hardware.

### 3 Results

From the 32 PET scans, 7 were classified as being perfectly aligned with the CT image, 16 having a mild misalignment, and 9 having a major misalignment. When introducing artificial misregistration to the initially aligned scans, artefacts were observed as local decrease of tracer uptake, especially in the anterior and lateral walls. The correction algorithm was able to recover an important part of the decrease.

When applied to all scans, the algorithm produced modifications in the tracer uptake which correlated well with the visual classification of the misalignment (see **Table 1**). An example of the correction in a patient with major misalignment is presented in **Fig 1**.



**Fig. 1** Effects of the correction in a patient with major misalignment: PET, CT-based attenuation map and fused PET/CT images before correction (first row) and after correction (second row). Observe the dark red aura in the fused image before correction corresponding to tracer uptake on which lung tissue was measured by CT and the corresponding attenuation factor was applied.

The results obtained suggest that the myocardial regions more prone to be affected by the misalignment are the anterior and lateral walls.

### 4 Discussion

Despite the use of combined imaging devices, patient respiration and motion cause significant emission-transmission misalignment which biases the photon attenuation correction and result in decreased uptake and false-positive findings, especially in the anterior and lateral walls. This fact should be taken into account by image readers in order to suspect of defects in these areas when no correction algorithm is used.

The proposed algorithm reduced significantly the impact of this misalignment improving the attenuation corrected cardiac images. It has the advantages of being fast and fully automatic, which make it easy to integrate in clinical routine.

### 5 Literature

- [1] Loghin, C.; Sdringola, S.; Gould, K.L.: Common Artifacts in PET Myocardial Perfusion Images Due to Attenuation-Emission Misregistration: Clinical Significance, Causes, and Solutions. *J Nucl Med*, Vol. 45, 2004, pp. 1029-1039
- [2] Friedman, J.; Van Train, K.; Maddahi, J. et al.: "Upward creep" of the heart: a frequent source of false-positive reversible defects during thallium-201 stress-redistribution SPECT. *J Nucl Med*, Vol. 30, 1989, pp 1718-1722
- [3] Kinahan, P.E.; Townsend, D.W.; Beyer, T.; Sashin, D.: Attenuation correction for a combined 3D PET/CT scanner. *Med Phys*, Vol. 25, 1998, pp. 2046-2053

**Table 1** Effects of the correction algorithm on the different myocardial walls for each of the groups. Results are expressed in percentage of the tracer uptake variation (mean $\pm$ SD)

	Perfectly aligned	Mild misalignment	Major misalignment
Anterior	6.07 $\pm$ 2.33	7.66 $\pm$ 5.53	25.00 $\pm$ 10.65
Septal	0.91 $\pm$ 0.68	1.45 $\pm$ 0.84	2.94 $\pm$ 1.63
Inferior	1.51 $\pm$ 0.65	2.81 $\pm$ 1.77	1.96 $\pm$ 0.81
Lateral	5.44 $\pm$ 1.13	9.28 $\pm$ 3.11	16.14 $\pm$ 5.59
Apex	1.72 $\pm$ 0.75	4.06 $\pm$ 2.62	8.66 $\pm$ 5.80