

Towards a Computer Aided Diagnosis System for Colon Motility Dysfunctions

Ben Glocker^a, Sonja Buhmann^b, Chlodwig Kirchhoff^c,
Thomas Mussack^c, Maximilian Reiser^b, and Nassir Navab^a

^aChair for Computer Aided Medical Procedures (CAMP),
Technische Universität München, Boltzmannstr. 3, 85748 Garching, Germany;

^bInstitut für Klinische Radiologie,
Klinikum der LMU - Grosshadern, Marchioninistraße 15, 81337 München, Germany;

^cChirurgische Klinik und Poliklinik,
Klinikum der LMU - Innenstadt, Nußbaumstraße 20, 80336 München, Germany

ABSTRACT

Colon motility disorders are a very common problem. A precise diagnosis with current methods is almost unachievable. This makes it extremely difficult for the clinical experts to decide for the right intervention such as colon resection. The use of cine MRI for visualizing the colon motility is a very promising technique. In addition, if image segmentation and qualitative motion analysis provide the necessary tools, it could provide the appropriate diagnostic solution. In this work we defined necessary steps in the image processing workflow to gain valuable measurements for a computer aided diagnosis of colon motility disorders. For each step, we developed methods to deal with the dynamic image data. There is need for compensating the breathing motion since no respiratory gating could be used. We segment the colon using a graph cuts approach in 2D and 3D for further analysis and visualization. The analysis of the large bowel motility is done by tracking the extension of the colon during a propagating peristaltic wave. The main objective of this work is to extract a motion model to define a clinical index that can be used in diagnosis of large bowel motility dysfunction. We aim at the classification and localization of such pathologies.

Keywords: *Methods:* pre-processing, quantitative image analysis, *Modalities:* magnetic resonance, *Diagnostic task:* diagnosis.

1. INTRODUCTION

Dysfunctions of large bowel motility presents a common problem in our society that may be attributable to a great variety of possible etiologies resulting most commonly in either constipation or diarrhea. Today's available diagnostic imaging techniques, such as bowel enema and the determination of the bowel transit time by the application of radiopaque markers, provide only snapshots of the dynamic large bowel motility. This gives only insufficient information concerning the reason for colon motility disorders. Thus, these examination techniques

Further author information: (Send correspondence to B.G.)

B.G.: E-mail: glocker@cs.tum.edu
S.B.: E-mail: sonja.buhmann@med.uni-muenchen.de
C.K.: E-mail: chlodwig.kirchhoff@med.uni-muenchen.de
T.M.: E-mail: thomas.mussack@med.uni-muenchen.de
M.R.: E-mail: maximilian.reiser@med.uni-muenchen.de
N.N.: E-mail: navab@cs.tum.edu

Copyright 2007 Society of Photo-Optical Instrumentation Engineers.

This paper was published in SPIE Medical Imaging and is made available as an electronic reprint with permission of SPIE. One print or electronic copy may be made for personal use only. Systematic or multiple reproduction, distribution to multiple locations via electronic or other means, duplication of any material in this paper for a fee or for commercial purposes, or modification of the content of the paper are prohibited.

cannot sufficiently demonstrate bowel movement and corresponding disorders in real-time. Up to date, only the pancolon manometry technique has been used to evaluate colonic motor function over either the entire length or limited segments of the human colon,^{1,2} but mostly in clinical settings and not widely used in daily routine. Manometry as well as the barostat technique present both scientifically established but very complicated methods with several drawbacks such as the invasive examination itself being very time intensive and inconvenient for the patients. Scintigraphic examinations are noninvasive, well-established and examiner independent methods allowing for the determination of the colonic transit time but with repeatedly exposing the patient to ionizing radiation.³ Thus, more or less classic imaging techniques are not suited to monitor large bowel motility with demand for other diagnostic imaging techniques, especially including newly available examination techniques such as biofeedback, electrical stimulation of intestinal pacemakers, or the administration of specific stimulating drugs.⁴ The ideal technique to visualize and quantify large bowel motility would allow for a fast and repeated imaging over larger time frames with a high temporal resolution reducing movement and respiratory artifacts. Magnetic resonance imaging allows noninvasive ultrafast dynamic imaging with a high soft tissue contrast permitting three-dimensional visualization. This potential of functional cine MRI for the visualization of the abdominal organs has been mentioned previously.⁵ Functional cine MRI appears very promising because it allows for the visualization of morphology and function of the large bowel at the same time, provided that fast image acquisition is used. Without any stimulation, the activity of the large bowel exhibits a broad range of individual differences, so that an examination within an acceptable time frame of approximately 30 minutes considering a future adoption into clinical routine is not possibly performed.^{5,6} Therefore, different prokinetic agents were used to achieve a predictable activity of the large bowel in previous studies by Buhmann *et al.*⁴ which lead to the achievement of the first visualization of the large bowel movement and its peristaltic wave. A further and detailed analysis of large bowel motility and its dysfunction provides an immense progress in diagnosis of the lower gastrointestinal tract also concerning an individual and more suitable therapeutical approach from surgical as well as the internal medical side.

However, to realize a future adoption into daily clinical routine the use of functional cine MRI with the resulting huge amount of imaging data, it is mandatory to develop computer based analysis approaches. Our main objective in this work is to model and quantify the activity of the large bowel hopefully providing the means to define the clinical significance of a variety of motility disorders in a wide range of patients. Necessary steps in the image processing workflow are defined, and technical approaches towards a computer aided diagnosis tool are proposed.

2. RELATED WORK

So far, not many studies concerning the analysis of colon motility using functional cine MRI exist. In the current literature only one MRI research group at the Kantonsspital Winterthur in Switzerland together with the radiology department of the university of Witten-Herdecke in Germany study small bowel motility using dynamic MRI. However, their work restricts to the basic approach of manually measuring the diameters of bowel.⁷ Buhmann *et al.* introduced this method to validate the effect of prokinetic agents on large bowel motility.

The compensation of motion in images is well studied in image processing also for Magnetic Resonance Imaging. However, techniques such as the use of navigator sequences⁸ or other gating methods during the image acquisition is not applicable in our approach. To be able to image the complex motion of the colon the achievement of the fastest possible frame rate is needed. The motion compensation has to be done in a post-processing step on to the images. Dubuisson-Jolly *et al.*⁹ propose a method to compensate for heart beating motion in coronary angiography. Their approach is to track the arteries and translate displaced pixels to stabilize the region of interest. Here, we cannot use the organ's, i.e. colon, pixels for compensation since any compensation of the colon motility itself has to be avoided. Image-based motion compensation relies mainly on the computation of the image Jacobian. Assuming the consistency of pixel intensities in an image series the Jacobian, which represents the image gradients, indicates the movement of pixel positions. In general, one can separate the existing motion tracking approaches in four groups: forward computation of the Jacobian and additive computation of the transformation as it is done by Lucas-Kanade,¹⁰ inverse and additive computation, where the Jacobian is only computed once proposed by Hager *et al.*,¹¹ forward and compositional computation proposed by Shum *et al.*¹² and finally inverse and compositional computation proposed by Baker *et al.*¹³ who also gives a detailed comparison of the different approaches. The motion compensation for our application is not constrained by any

real-time requirements but should be very precise such that referring to Baker¹³ forward computation was chosen. Colon segmentation is mainly known for the application of virtual colonoscopy. Therefore, many methods deal only with static 3D CT image data such as proposed by Chen *et al.*¹⁴ and Sadleir and Whelan.¹⁵ These are not directly applicable for 2D dynamic MRI series.

3. METHODS AND MATERIALS

3.1. Image acquisition

The volunteers undergo functional cine MRI. In the beginning the standardized functional cine MRI examination was performed at 6 AM after a minimum starving phase of 8 hours on 1.5-T system (SONATA, Siemens Medical Solutions) with 40 mT/m peak and 200 mT/ms rise time. The volunteers are examined in supine position using a multi array body coil. Neither premedication nor contrast agent is applied. The dynamic part of the examination consists of 2 blocks of repeated measurements covering the entire abdomen, using HASTE-sequences (TR 1130 milliseconds, TE 81 milliseconds, flip angle 150, matrix 256 x 207, FOV 400-mm, slice thickness 6 mm; 600 slices). Each block contains 3 stacks of 200 slices: The three sets of slices are orientated in coronal plane (whole abdomen, ascending, transverse and descending colon). Each stack of slices is most suitable adapted to the anatomic course of the corresponding colon-part. For respiratory gating a navigator technique for the suppression of breathing artifacts (FOV 95read/26phase, slice thickness 5 mm, 1 slice) is used by analyzing the movement of the right diaphragm in the sagittal orientation. The overall examination time for each block varied between 12 and 20 minutes, depending on the respiratory frequency of the volunteer. The time for the performance of a 3 image block consisting of 1 image of the ascending, transverse and the descending colon, was approximately 5 seconds. Between the 2 dynamic blocks of measurements the volunteers get a prokinetic agent to stimulate the colon motility. The image stacks are ordered by the part of the colon so finally three dynamic image series (ascending, transverse, and descending colon) before and after administering a prokinetic agent. Each series contains 200 slices. These acquired data sets were initially only used to compare the manual analysis method⁴ and our semi-automatic approach which is later described in detail. In some of the image blocks after administering a stimulation agent the peristaltic wave of colon was clearly visible. The colon motility is complex and the reduced information of a manually measured diameter through out the sequence is neither practical nor sufficient for defining a clinical index.

However, to be able to image the complex peristaltic wave motion over time the respiratory gating is not applicable. Therefore, the examination protocol was changed as follows: the MRI examination is now performed on 1.5-T system (AVANTO, Siemens Medical Solutions) using parallel imaging allowing for fast imaging with equal temporal resolution. No respiratory gating is applied to achieve the highest possible frame rate so that a frame rate between two following images of the same colon part of 1.4 seconds resulted, being fast enough to visualize the large bowel's motion. This leads to our first step of motion compensation within the image processing workflow. In the following, we use also the term "frame" for a single image according to the cine-like image series.

3.2. Motion compensation

As mentioned previously, no respiratory gating techniques are used in our approach. Thus, we are able to achieve the highest possible frame rate during image acquisition. However, there is need for compensating the resulting breathing motion afterwards. The breathing artifacts are visible in a vertical jumping of the abdominal organs effected by breathing motion such as liver, kidney, and of course the colon itself. In order to obtain a quantitative analysis of the region of interest, i.e. the colon, we want to stabilize the images in these parts. We propose a semi-automatic motion compensation method where a region in the image has to be selected. This part of the image has to represent the overall breathing motion but should not include any parts of the colon. So we can avoid to eventually compensate for colon motility. Within the selected region features are extracted which fulfill the Harris^{16,17} assumptions. The robust and fast implementation of Lucas-Kanade optical flow tracker¹⁸ is used to compute the displacement of each single feature in every frame in respect to a reference frame (i.e. the first frame of the image series). Afterwards we compute a mean displacement for every frame. The frames are then translated in vertical direction by the computed displacement. In practice, the image part around liver and right kidney turned out to be a good region for tracking the breathing motion (Fig. 1). These parts show a very similar

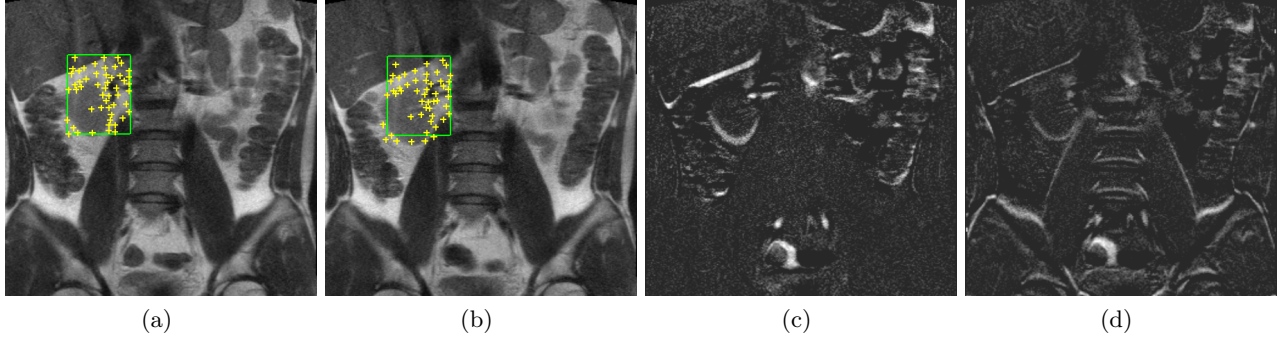


Figure 1. (a) Selected region and extracted feature points. (b) Tracked features in one of the following frames. (c) Difference image of reference frame and frame which has to be compensated (d) Difference image after motion compensation. The displacement at the livers lower edge has been almost eliminated.

breathing movement such as the colon itself. The result of the motion compensation shows a stabilization of all organs with similar displacements. Naturally, former stable parts (e.g. the spine) are consecutively jumping within the image series, However, this fact does not present a problem for the further processing.

3.3. Segmentation

The segmentation of the colon is crucial for our further analysis. Shape and extension have to be well preserved by the segmentation. The individual patient’s anatomy is particularly reflected in position and appearance of the large bowel. A segmentation method has to be highly flexible to handle the variety of individual manifestation of this organ. Since we are dealing with a dynamic image series each frame is showing a similar image of the patient’s abdomen with slightly moved, or in case of motility, extended bowel diameter. Our segmentation method should be able to extract the colon in all frames at once with a minimized user interaction. Therefore, we use the interactive graph cuts approach proposed by Boykov and Jolly.¹⁹ The segmentation is defined as an energy formulation

$$E(A) = R(A) + \lambda \cdot B(A) \quad (1)$$

where A indicates a segmentation of the pixels x of domain Ω of the image series I into two subsets \mathcal{O} (object pixels) and \mathcal{B} (background pixels) with

$$A_{x \in \Omega} = \begin{cases} \text{“obj”} & \text{if } x \in \mathcal{O} \\ \text{“bkg”} & \text{if } x \in \mathcal{B} \end{cases} \quad (2)$$

Here, the regional term R represents the knowledge given by the user. Interactively, the user sets so-called seed brushes for the object \mathcal{S}_{obj} that is considered to be segmented (i.e. the colon) and additionally, seeds for the background \mathcal{S}_{bkg} (Fig. 2a). The function R is then defined as

$$R(A) = \sum_{x \in \Omega} R_x(A_x) \quad (3)$$

where

$$R_x(A_x) = \begin{cases} \infty & \text{if } A_x = \text{“obj”} \wedge x \in \mathcal{S}_{bkg} \\ \infty & \text{if } A_x = \text{“bkg”} \wedge x \in \mathcal{S}_{obj} \\ 0 & \text{otherwise} \end{cases} \quad (4)$$

Intuitively, the regional term forces the pixels belonging to seed brushes to keep their assignment to the object respectively background segmentation subset. The second part B of the segmentation energy is the so-called boundary term. Here, it represents the energy for pairs of neighboring pixels $x, y \in \mathcal{N}$ to belong to the same segmentation subset and is defined as

$$B(A) = \sum_{x, y \in \mathcal{N}} B_{x, y} \cdot \delta(A_x, A_y) \quad (5)$$

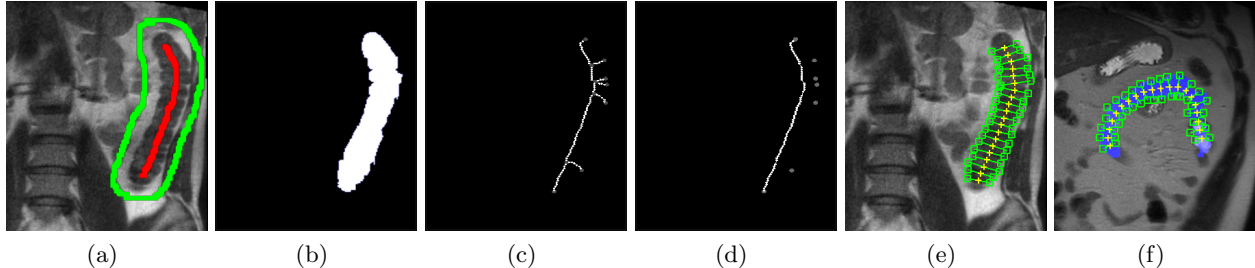


Figure 2. (a) Seed brushes in one frame of the dynamic image sequence. (b) Resulting segmentation of the descending colon. (c) Skeletonization of segmentation. (d) Extracted longest path which is used as centerline. (e) Diameter measurement at 20 sample points. (f) Degenerated colon. It is still possible to measure exactly the diameter of such a shape.

with

$$\delta(A_x, A_y) = \begin{cases} 1 & \text{if } A_x \neq A_y \\ 0 & \text{otherwise} \end{cases} \quad (6)$$

In our experiments, we use a simple boundary term based on intensity differences and is defined as a penalty function

$$B_{x,y} \propto \exp\left(-\frac{(I_x - I_y)^2}{2\sigma^2}\right) \cdot \frac{1}{\text{dist}(x,y)} \quad (7)$$

This function penalizes a lot for discontinuities between pixels of similar intensities. Additionally, the weighting λ controls the influence of the boundary term. We set this value to 0.01 which was determined empirically for our kind of image data. By computing the minimum energy of equation 1 using the graph-cuts method the segmentation of the colon can be achieved. Due to the motion compensation and thus a stabilization of the position of the colon within the image series it is mostly sufficient to set the seed brushes in only one frame. The object and background seeds can be copied and pasted to the following frames. The segmentation is computed globally for the whole series. Additionally, by setting the background seeds as a surrounding of the region of interest the seeds can be used to restrict the pixel space used for the graph-cut computation. Thus, a complete colon segmentation of one image series can be achieved in less than ten seconds.

3.4. Analysis

The measurement of the peristaltic wave is directly done on the segmented image (Fig. 2b). First we extract the skeleton in one frame of the segmented dynamic image series using a thinning algorithm proposed by Palagyi *et al.*²⁰ A graph is constructed out of the skeleton using a wave propagation approach presented by Zahlten *et al.*²¹ The resulting graph is a tree-like structure with many little branches as shown in Figure 2c. We can extract the longest path of such a tree using a simple two step algorithm. An arbitrarily graph node is selected as root node. The edges between the nodes are weighted by their length (e.g. by counting the sample points on each edge resulting from the wave propagation or creating a B-Spline and computing its length). The distances from the root node to all leaves are computed. The most distant leaf is identified and set as the new root node. Once again all distances to the new root are computed. The path between the root and the now most distant leaf describes the longest path in the tree (Fig. 2d). This path is used as the centerline of the colon segment and is represented by a B-Spline. The centerline is subdivided into a user-specified number of segments. At each segment the extension of the colon is calculated in perpendicular directions to the centerline (Fig. 2e). These diameters are measured in all frames of the image series using the extracted sample points of one frame.

The measurements give us an idea about the movement of the colon and the peristaltic wave presenting the opportunity to extract the variations on colon diameter at an arbitrarily number of sample points. Due to the measurements beginning at the centerline, we can also distinguish between changes in the two different perpendicular directions. This gives information about the symmetry of the motion. Several properties can be derived from the measured values. The minimum and maximum extension at each sample point and the tracking of the maximum extension over time, which is designated to compute the speed of the peristaltic wave's

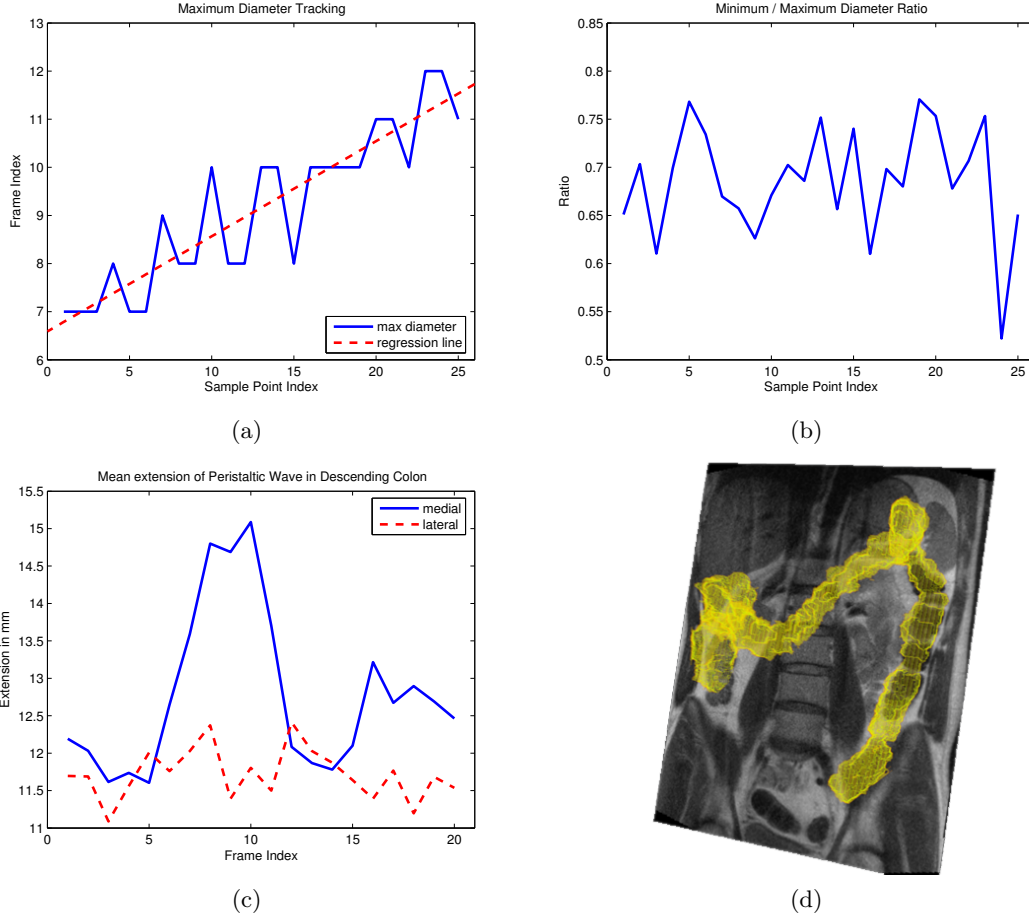


Figure 3. (a) The maximum diameter at each of the 25 sample points. The derivation of the regression line gives information about the speed of propagation. (b) Ratio of minimum and maximum diameter at each sample point gives information about the uniformity of the propagation. (c) The mean extension of the colon during a propagating peristaltic wave over 20 frames. The larger extension is clearly visible on the medial side. (d) Visualization of 2D dynamic image sequence and 3D segmentation of the colon. Slice to volume registration was done on the 2D dynamic image sequence and a 3D MRI scan.

propagation, are used to model the colon motion. The combination of the graph cuts segmentation and the graph extraction for computing the centerline makes our approach highly flexible. We are able to extract the variations in motion on arbitrarily shapes of the colon (Fig. 2f).

4. EXPERIMENTS AND RESULTS

Our approach for analyzing the colon motion is extending the idea of manual diameter measurement, which was proposed in⁴ to evaluate different prokinetic agents. Since the extraction of arbitrarily numbers of diameters semi-automatically is now possible by using our proposed image processing workflow, evaluations of new stimulation agents have been improved a lot.

We tested our method on 16 volunteers getting Senna tea as prokinetic agent and 15 volunteers getting Erythromycin. All data sets were evaluated in advance using the manually measurement of the diameters at five points in each frame with a ruler tool. We could achieve the same significant conclusions in a fraction of time that is reported in the literature.⁴ When applying our method on an image sequence showing the peristaltic wave, we are able to extract the necessary values to model the motion. Figure 3a shows a plot of the tracked maximum diameter at 25 sample points. A regression line is plotted on top. The derivation of this line is an estimation

for the speed of the wave propagation. A slow propagation indicates a disorder in motility. In figure 3b the ratio of minimum and maximum extension is plotted providing information on how uniform a wave propagates through the colon. If there occur ratios close to 1, this might present an indicator for dysfunctioning colon. A precise localization is possible by using the position of the corresponding sample points. Since we are able to distinguish between the different directions of the colon extension by measuring them separately, we could also show that the extension in general is not symmetric 3c. This is what clinical experts actually expected. However, up to now there did not exist any image based method to proof these assumptions. From these curves we are creating a statistical model representing colon motility of healthy probands. Whenever a patient is imaged and an abnormality occurs on any of our measured values, this would indicate a pathology and we are able to localize the defect part of the colon. Besides the quantitative analysis to support the diagnosis of colon motility disorders we aim at providing the physicians with a planning tool for surgical intervention in case of colon resection. The precise location of defect parts of the colon is crucial for a successful operation. Therefore we developed a new visualization of volume rendered 3D colon segmentation from MRI data of the abdomen in combination with the 2D dynamic image sequences (Fig. 3d). Such 3D scans are performed before the dynamic part of the examination is performed and is already implemented in the MR examination protocol.

5. DISCUSSION

Up to now, we are concentrating on the descending part of the colon. This is the part, which is most interesting for surgeons since it is suitable for minimally invasive surgery. For a model of the complete motion of the colon the ascending and transverse part will also be included. On the clinical side we are currently searching for a potent prokinetic agent, which will allow us to image to peristaltic wave on purpose. For the image processing we are going to improve our methods to minimize the user interaction. For instance the region selection for motion compensation could be done fully-automatically by template matching. We are testing different cost functions for the segmentation to reduce the drawing of seed brushes.

6. CONCLUSION

A computer aided diagnosis tool is extremely valuable for the complex and difficult diagnosis of colon motility disorders. A precise diagnosis using the existing methods is almost unachievable. With our new approach, it is possible for the first time to gain precise quantitative measurements of the complex colon's motion. In this paper we defined necessary steps for image processing workflow of functional cine MRI data. We presented approaches to gain significant values for a motion model of the peristaltic wave. We aim at providing a reliable clinical index for pathologies of the large bowel achieved by using noninvasive cine MRI. This novel approach will provide immensely valuable information for diagnosis and therapeutical intervention. In collaboration with our clinical partners we are going to fully integrate the surgical planning tool within the image processing workflow. Once a pathological part of the colon is detected by our analysis it will be highlighted automatically in the 2D-3D visualization and quantitative measures will provide detailed diagnostic values.

REFERENCES

1. M. Hansen, "Small intestinal manometry," *Physiol Res.* **51**, pp. 541–556, 2002.
2. R. Hagger, D. Kumar, M. Benson, and et al, "Periodic colonic motor activity identified by 24-h pancolonc ambulatory manometry in humans," *Neurogastroenterol Motil.* , pp. 271–278, 2002.
3. E. Bonapace, A. Maurer, S. Davidoff, and et al, "Whole gut transit scintigraphy in the clinical evaluation of patients with upper and lower gastrointestinal symptoms," *Am J Gastroenterol.* **95**, pp. 2838–2847, 2000.
4. S. Buhmann, C. Kirchhoff, and et al, "Assessment of large bowel motility by cine magnetic resonance imaging using two different prokinetic agents," *Investigative Radiology* **40**, **11**, pp. 689–694, 2005.
5. A. Lienemann, D. Sprenger, H. Steitz, and et al, "Detection and mapping of intraabdominal adhesions by using functional cine mr imaging: preliminary results," *Radiology* **217**, pp. 421–425, 2000.
6. S. Buhmann, C. Kirchhoff, and et al, "Visualization and quantification of large bowel motility with functional cine-mri," *Fortschritte auf dem Gebiet der Roentgenstrahlen und der bildgebenden Verfahren (RoeFo)* **177**, pp. 35–40, 2005.

7. M. Froehlich, M. Patak, C. von Weymarn, and et al, "Small bowel motility assessment with magnetic resonance imaging," *Journal of Magnetic Resonance Imaging* **21**, **4**, pp. 370–375, 2005.
8. Y. M. Kadah, A. A. Abaza, A. S. Fahmy, and et al, "Floating navigator echo (fnav) for in-plane 2d translational motion estimation," *Magnetic Resonance in Medicine* **51**, pp. 403–407, 2004.
9. M.-P. Dubuisson-Jolly, C.-C. Liang, and A. Gupta, "Optimal polyline tracking for artery motion compensation in coronary angiography," in *ICCV '98: Proceedings of the Sixth International Conference on Computer Vision*, p. 414, IEEE Computer Society, (Washington, DC, USA), 1998.
10. B. Lucas and T. Kanade, "An iterative image registration technique with an application to stereo vision," in *Proceedings of the 7th International Joint Conference on Artificial Intelligence (IJCAI)*, pp. 674–679, 1981.
11. G. Hager and P. Belhumeur, "Efficient region tracking with parametric models of geometry and illumination," *IEEE Trans. on Pattern Analysis and Machine Intelligence* **20**(10), pp. 1025–1039, 1998.
12. H. Shum and R. Szeliski, "Construction of panoramic image mosaics with global and local alignment," *IEEE Journal of Computer Vision* **16**(1), pp. 63–84, 2000.
13. S. Baker and I. Matthews, "Lucas-kanade 20 years on: a unifying framework," *International Journal of Computer Vision* **56**, pp. 221–255, February 2004.
14. D. Chen, Z. Liang, M. Wax, and et al, "A novel approach to extract colon lumen from ct images for virtual colonoscopy," in *IEEE Transactions on Medical Imaging*, **19**, **12**, pp. 1220–1226, 2000.
15. R. J. Sadleir and P. F. Whelan, "Colon centreline calculation for ct colonography using optimised 3d topological thinning," in *First International Symposium on 3D Data Processing Visualization and Transmission (3DPVT'02)*, p. p.800, 2002.
16. C. Harris and M. Stephens, "A combined corner and edge detector," in *Proc. Alvey Vision Conf.*, pp. 147–151, 1988.
17. J. Shi and C. Tomasi, "Good features to track," in *IEEE Conference on Computer Vision and Pattern Recognition (CVPR'94)*, pp. 593–600, 1994.
18. J.-Y. Bouguet, *Pyramidal Implementation of the Lucas-Kanade Feature Tracker*. OpenCV Documentation, Microprocessor Research Labs, Intel Corporation, 1999.
19. Y. Boykov and M.-P. Jolly, "Interactive graph cuts for optimal boundary & region segmentation of objects in n-d images," in *Proc. International Conference on Computer Vision (ICCV)*, **I**, pp. 105–112, 2001.
20. K. Palágyi, E. Sorantin, E. Balogh, A. Kuba, C. Halmaj, B. Erdöhelyi, and K. Hausegger, "A sequential 3d thinning algorithm and its medical applications," in *Proc. Int'l Conf. Information Processing in Medical Imaging (IPMI), Lecture Notes in Computer Science* **2028**, pp. 409–415, Springer, 2001.
21. C. Zahlten, H. Jürgens, and H.-O. Peitgen, "Reconstruction of branching blood vessels from ct-data," in *Eurographics Workshop of Visualization in Scientific Computing*, pp. 161–168, Springer, 1994.