

# Adaptive Model Based Pulmonary Artery Segmentation in 3-D Chest CT

Marco Feuerstein<sup>a</sup>, Takayuki Kitasaka<sup>b,c</sup>, Kensaku Mori<sup>a,c,d</sup>

<sup>a</sup> Graduate School of Information Science, Nagoya University

<sup>b</sup> Faculty of Information Science, Aichi Institute of Technology

<sup>c</sup> MEXT Innovation Center for Preventive Medical Engineering, Nagoya University

<sup>d</sup> Information Planning Office, Information and Communications Headquarters, Nagoya University

## 1. Introduction

- Development of a method for automatic pulmonary artery (PA) extraction to reduce the physicians' workload during diagnosis and treatment of lung disease
- Method should work:
  - In both contrast enhanced and non-contrast CT
  - In case of imaging artifacts caused by cardiac motion/calcifications
  - For adjacent (seemingly merging) vasculature

## 2. Problems of Previous Approaches

- Only work on contrast enhanced data [sebbe2005, linguraru2008, vitanovski2009]
- Tested on a very limited number of (6-8) cases [kitasaka2002, sebbe2005, linguraru2008]
- Require user interaction [sebbe2005, linguraru2008]
- Do not work robust enough [kitasaka2002, taeparasitsit2009]

## 3. Method

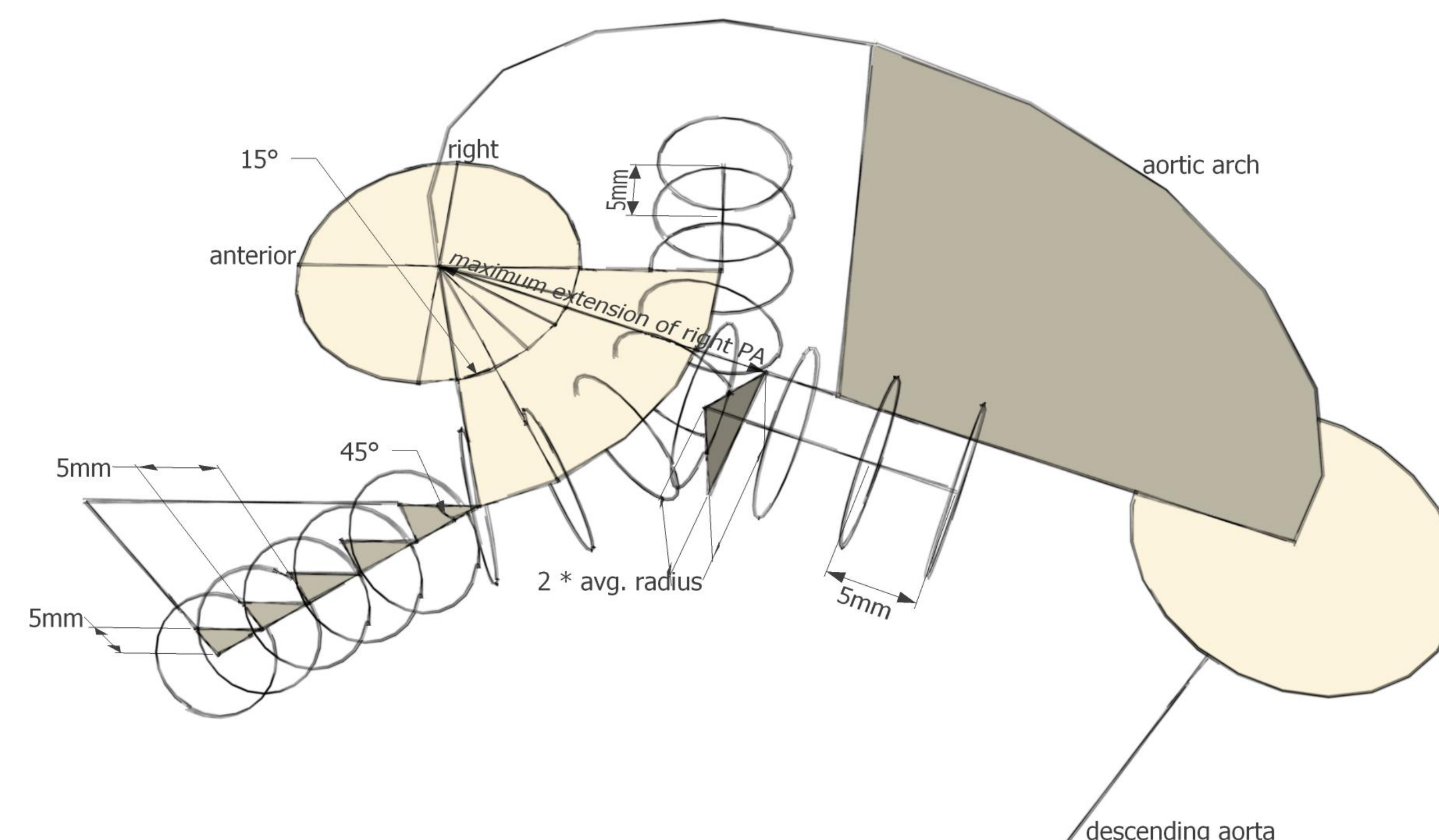
- Preprocessing: Segmentation of the aortic arch [feuerstein2009] and exclusion of its voxels from all following processing steps
- Adaptive model based Hough transform to generate a patient-specific approximate centerline of the pulmonary artery (cf. 3.1)
- Creation of nonuniform rational B-spline (NURBS) curves from the centerline and fitting to a likelihood image (Euclidean distance to possible pulmonary artery edges) (cf. 3.2)
- Reverse Euclidean distance transform to recover the lumen

### 3.1. Hough Transform

- Adaption of our model to the dimensions of the aorta and pulmonary artery, mainly according to two key slices, one enclosing the aortic arch and another one orthogonal to it and adjacent to the maximum extension of the right PA
- Creation of oblique 2-D slices according to the model
- Circular Hough transform inside the slices
- Selection of the circle and its centerpoint most likely corresponding to the pulmonary artery by

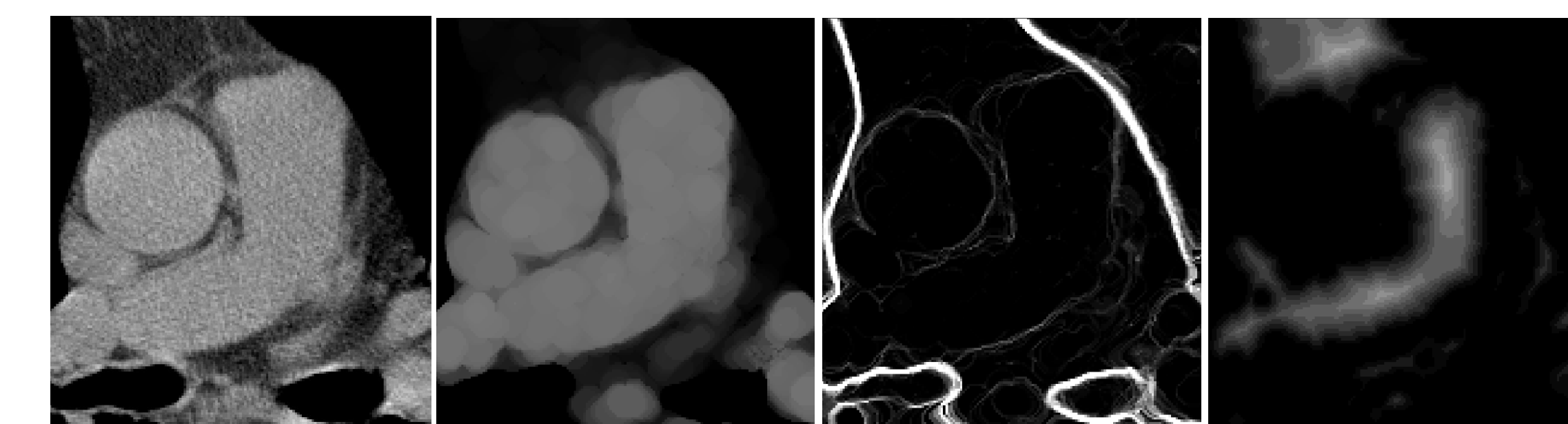
$$p = \arg \max_{i=1..n} \left( \frac{h(x_i)}{\max_{i=1..n} (h(x_i))} \cdot \frac{r(x_i)}{\max_{i=1..n} (r(x_i))} \cdot \frac{d_{cen\_max} - d_{cen}(x_i)}{d_{cen\_max}} \right)$$

where  $h(x_i)$  is the value in the Hough map corresponding to circle  $i$ ,  $r(x_i)$  is the radius of this circle,  $d_{cen}(x_i)$  is the Euclidean distance of the circle center to the slice center, and  $d_{cen\_max}$  is half the side length of the slice.



### 3.2. Spline Fitting

- Approximation of 3 NURBS curves to the centerline points, one each for the pulmonary trunk, left, and right pulmonary artery
- Creation of a likelihood image representing the likelihood of a voxel to be the centerline of the pulmonary artery by morphological opening, computation of the gradient magnitude, and Euclidean distance transform to high gradients



- Fitting of the curves to the likelihood image by

$$\arg \max_{\mathbf{P}_i} \left( \sum_{c=1}^3 \sum_{j=1}^{m_c} d_L^2 \left( N_c \left( \frac{j}{m_c} \right) \right) - \max^2 \left( 0, r_{\min} - r \left( N_c \left( \frac{j}{m_c} \right) \right) \right) \right)$$

where  $d_L(\mathbf{X})$  is the Euclidean distance value of voxel  $\mathbf{X}$  in the likelihood image,  $N_c(u) = \sum_{i=1}^k R_{i,p_c} \mathbf{P}_{i,c}$  is one of the 3 NURBS curves with  $R_{i,p_c}$  being its rational basis functions (of degree  $p = 3$  in our case) and  $\mathbf{P}_{i,c} = (x_{i,c}, y_{i,c}, z_{i,c})^T$  its  $i = 1..k$  control points,  $m_c$  is the number of sampling points along the curve (we sample every millimeter),  $r(N_c(u)) = \|N_c'(u)\| / \|N_c''(u)\|$  is the radius of curvature at  $u$ , and  $r_{\min}$  is the minimum pulmonary artery radius found during Hough transform.

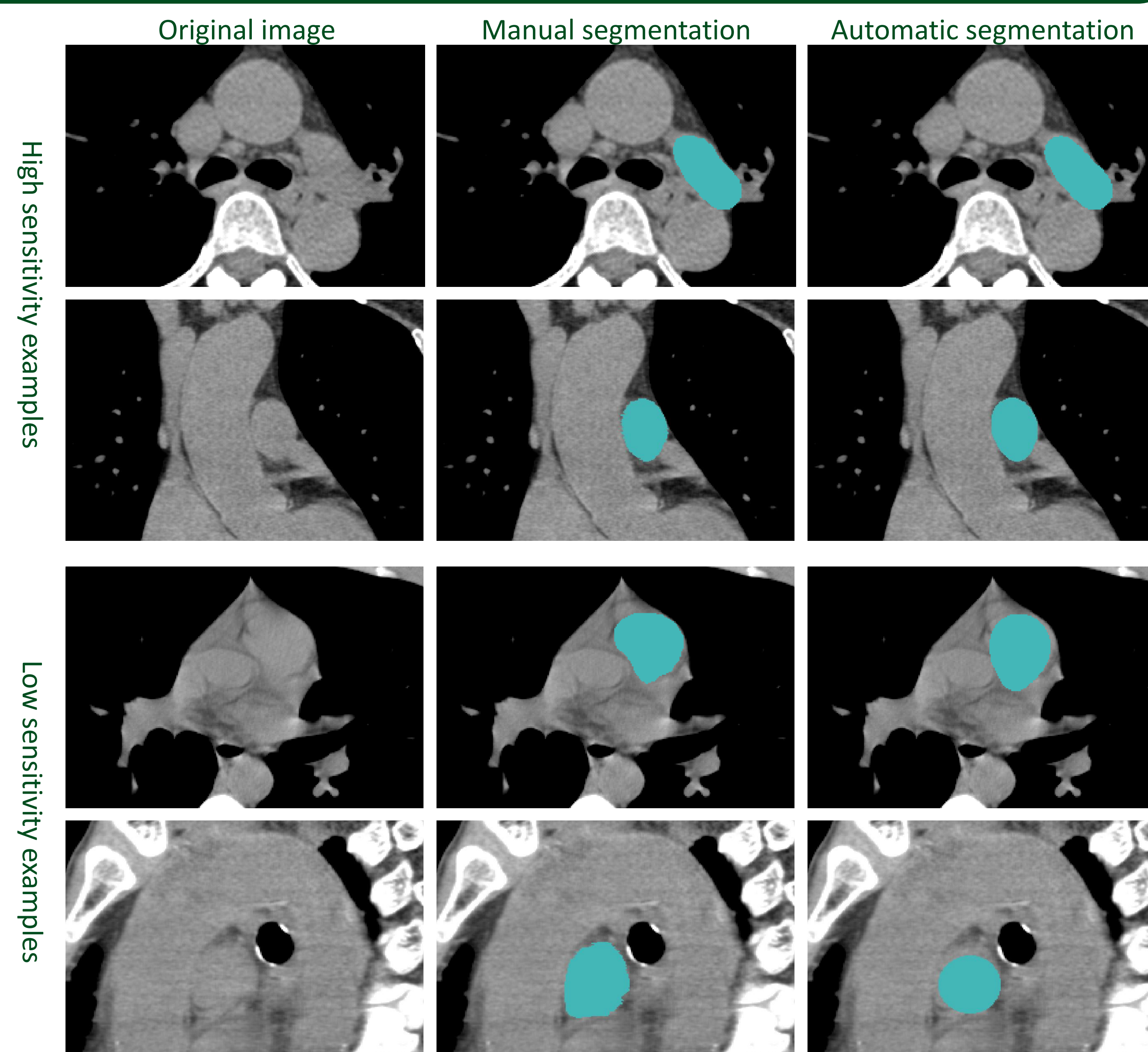
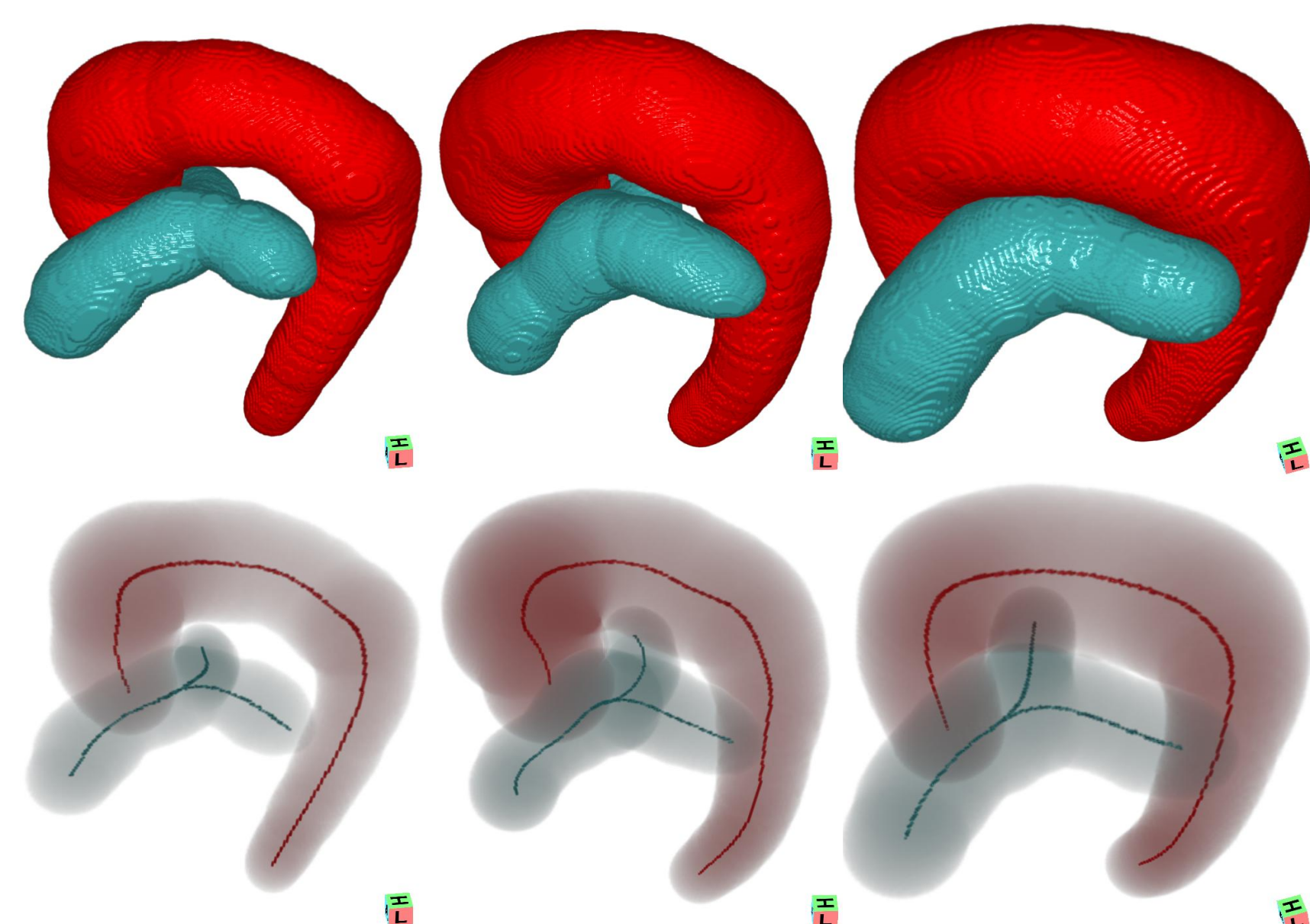
## 5. Discussion and Conclusion

- Currently fixed inter-slice distance and number of slices
- Non-circularity of pulmonary artery due to pressure from surrounding vasculature or the bronchial tree
- Method works robust on a large number of non-contrast and contrast enhanced cases and improves the current state of the art

## 4. Experiments and Results

- 10 contrast enhanced and 30 non-contrast data sets (99-838 slices spaced 0.4-1.5 mm, 512x512 pixels of size 0.5-0.665 mm)
- Successful extraction in all 40 data sets
- Additional quantitative evaluation on the first 25 data sets using manual segmentations

Sensitivity	Specificity	Jaccard Index
$0.93 \pm 0.05 \geq 0.76$	$0.98 \pm 0.01 \geq 0.95$	$0.87 \pm 0.04 \geq 0.75$
Mean MD (mm)	SD MD (mm)	Max MD (mm)
$0.5 \pm 0.2 \leq 0.9$	$0.7 \pm 0.2 \leq 1.2$	$5.3 \pm 1.3 \leq 8.2$



## References

- [feuerstein2009] Feuerstein, M., Kitasaka, T., and Mori, K., Automated anatomical likelihood driven extraction and branching detection of aortic arch in 3-D chest CT, in [Second International Workshop on Pulmonary Image Analysis], (2009).
- [kitasaka2002] Kitasaka, T., Mori, K., Hasegawa, J., Toriwaki, J., and Katada, K., Automated extraction of aorta and pulmonary artery in mediastinum from 3D chest X-ray CT images without contrast medium, in [SPIE Medical Imaging], (2002).
- [linguraru2008] Linguraru, M. G., Mukherjee, N., Uitert, R. L. V., Summers, R. M., Gladwin, M. T., Machado, R. F., and Wood, B. J., Pulmonary artery segmentation and quantification in sickle cell associated pulmonary hypertension, in [SPIE Medical Imaging], (2008).
- [sebbe2005] Sebbe, R., Gosselin, B., Coche, E., and Macq, B., Segmentation of opacified thorax vessels using model-driven active contour, in [IEEE Engineering in Medicine and Biology], 2535-2538 (2005).
- [taeparasitsit2009] Taeparasitsit, P. and Higgins, W. E., System for definition of the central-chest vasculature, in [SPIE Medical Imaging], (2009).
- [vitanovski2009] Vitanovski, D., Ionasec, R. I., Georgescu, B., Huber, M., Taylor, A. M., Hornegger, J., and Comaniciu, D., Personalized pulmonary trunk modeling for intervention planning and valve assessment estimated from CT data, in [Medical Image Computing and Computer Assisted Intervention], (2009).

**Acknowledgements:** This work was supported in part by the JSPS postdoctoral fellowship program for foreign researchers, by a Grant-in-Aid for Science Research funded by MEXT and JSPS, and by a Grant-in-Aid for Cancer Research funded by the Ministry of Health, Labour and Welfare, Japan.