

Case Report: Image-guided resection of paraganglioma

I. Einspieler¹, A. Okur¹, A.R. Novotny², M.E. Martignoni², K. Scheidhauer¹

¹Klinikum rechts der Isar, Nuclear Medicine, Munich, Germany

²Klinikum rechts der Isar, Surgery, Munich, Germany

BACKGROUND

Intraoperative localization of small focal uptakes as visualized in preoperative SPECT or PET imaging can be very difficult and time-consuming. Intraoperative imaging modalities like freehand SPECT may help to guide resection during surgery.

MATERIAL AND METHODS

32 year old male patient with suspicion of recurrent paraganglioma showed 2 focal uptakes of I123 MIBG (173 MBq) next to left renal vein in a diagnostic scan (planar images and abdominal SPECT/CT) confirming the indication for open resection. 2 days before surgery a dose of I123 MIBG (105 MBq) was applied. Freehand SPECT images were acquired during the operation using declipseSPECT (SurgicEye). The freehand SPECT system combines a gamma probe with an infrared optical spatial localization system using infrared referencing markers attached to the probe and the patient. A data processing unit generates a real time 3D image in the operating room based on the readings of the probe and its position. The region of interest (area of the expected paragangliomas) was scanned moving the gamma probe in different angles and directions. Then the freehand SPECT image was generated and image visualization parameters were set to visualize hottest uptake.

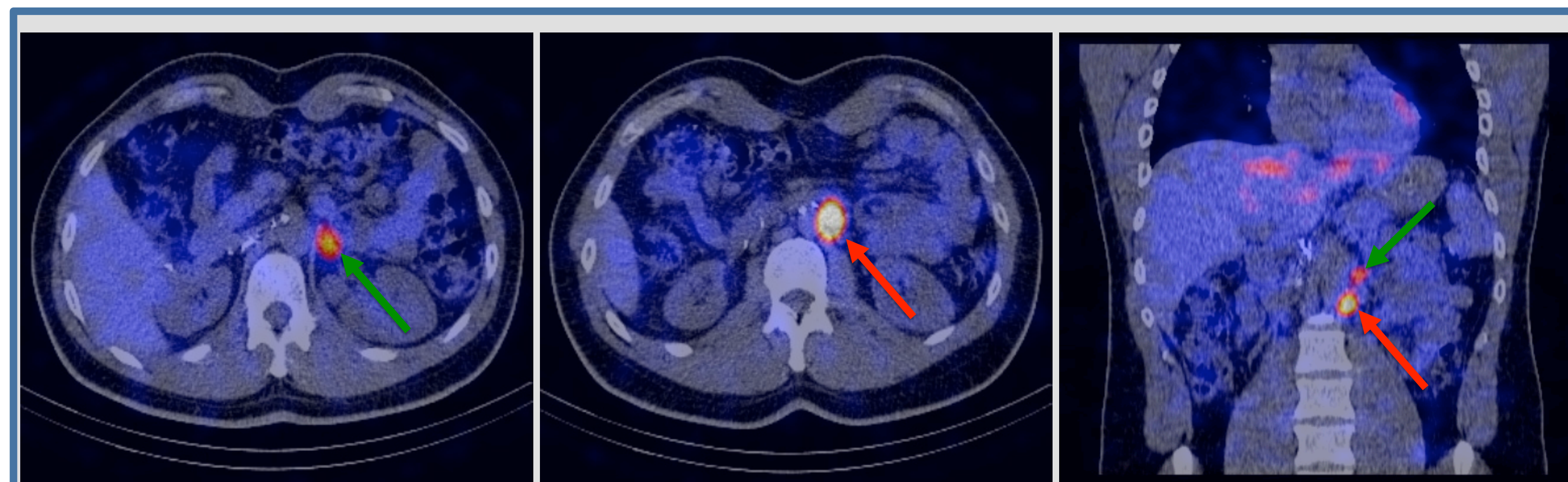


Figure 1: Images show axial and coronal slices of 3D-reconstructed fused I123-MIBG-SPECT/CT images with 2 pathologic focal uptakes next to left renal vein, marked by green and red arrows.

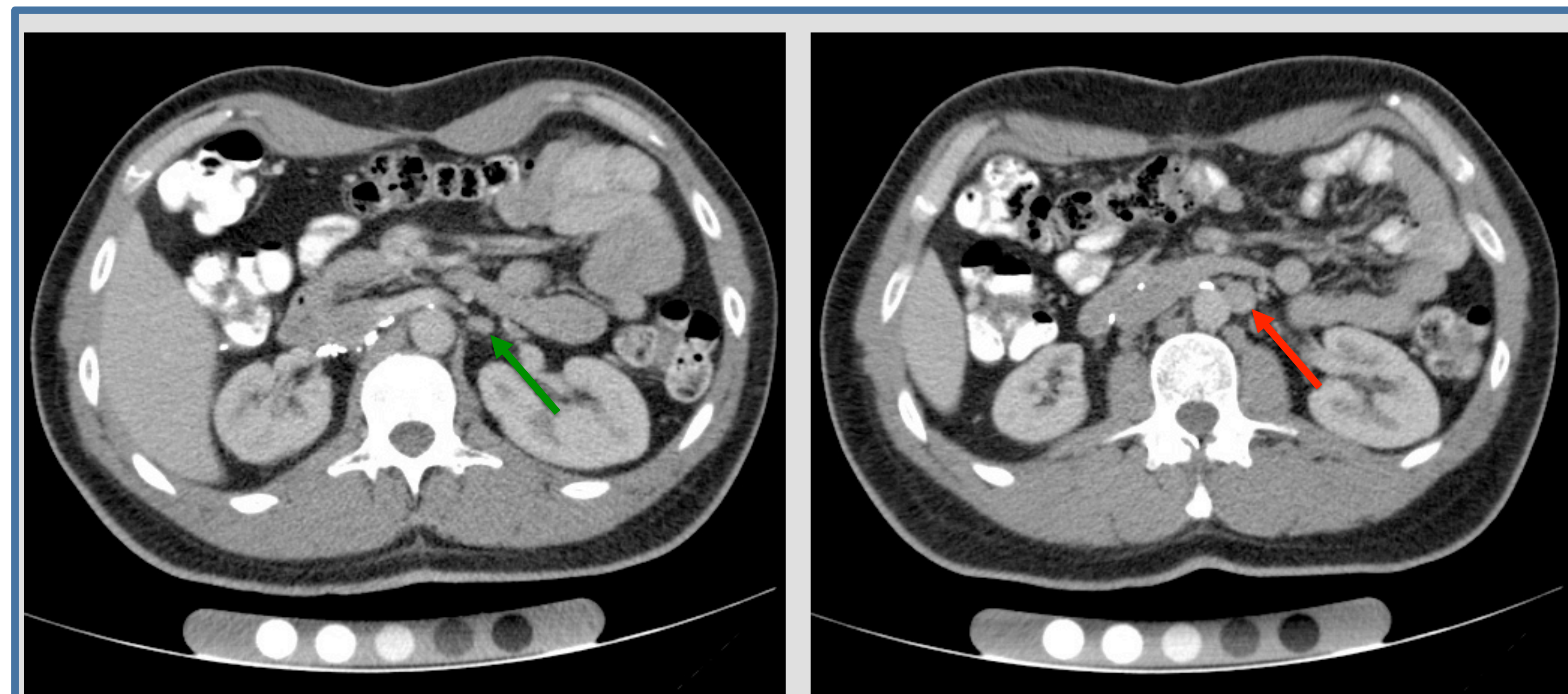


Figure 2: In the CT-scan of the abdomen green and red arrows mark the paragangliomas in both images, according to the focal uptakes of I123-MIBG in figure 1.

RESULTS

At the operating room and using the freehand SPECT system (61s scan), one lesion (max. 17 mm) was found. The other lesion (max. 11 mm) was also visualized, but could only be tracked with the gamma probe due to strong breathing motion. Both lesions were successfully resected, confirmed to be radioactive and identified as paragangliomas by histology. The freehand SPECT system was of additional value in planning the operative access to the region of interest, since the lesions were located retroperitoneal and in determining the depth of the first lesion for precise and faster exstirpation.

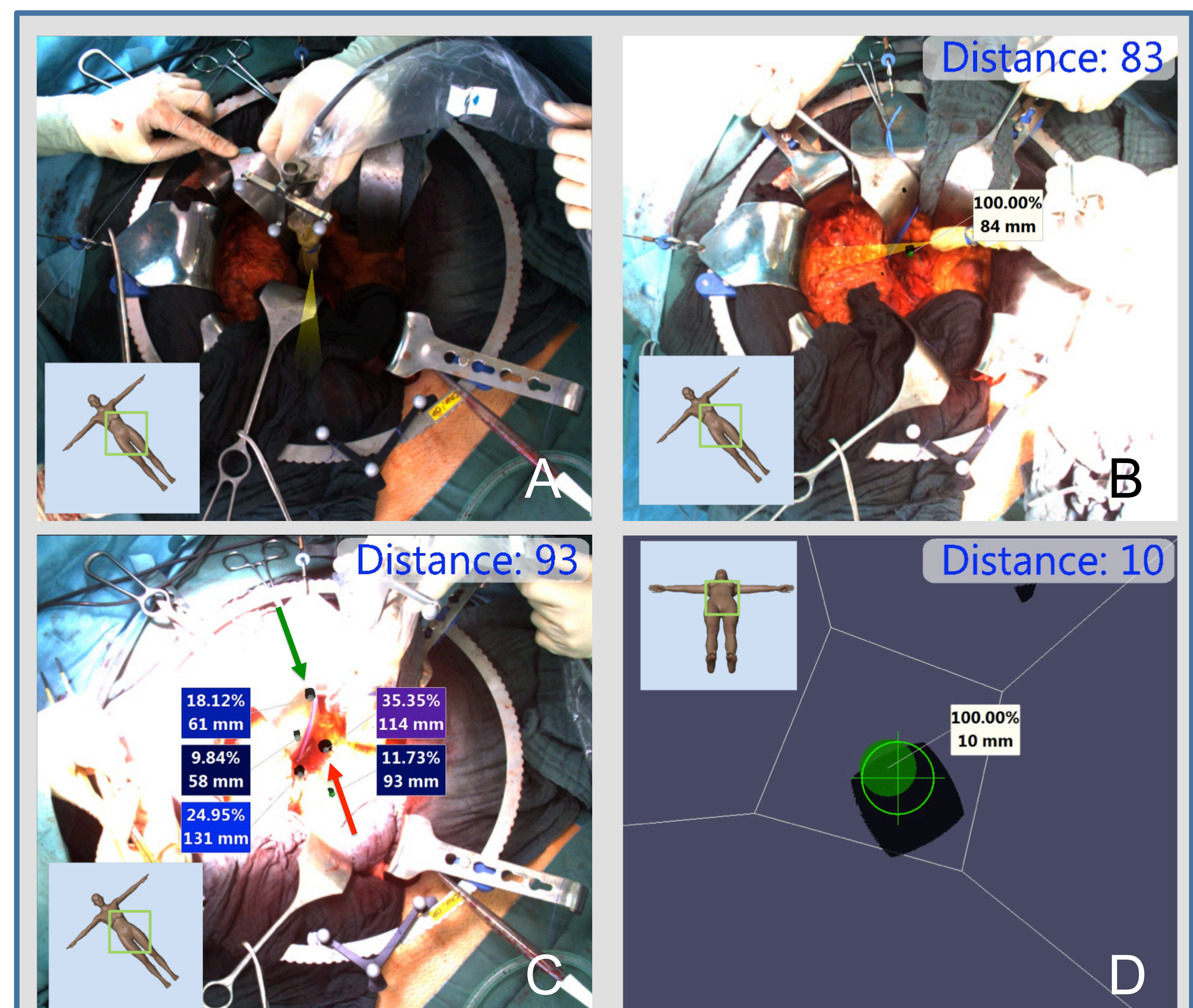


Figure 3: Scanning the abdomen during the operation moving the gamma probe in different angles and directions (A). Freehand SPECT with video overlay in the region of interest (B-C), showing the paragangliomas in image C (marked by green and red arrows). 3D view of the bigger paraganglioma from the perspective of the gamma probe. (D).

CONCLUSION

Freehand SPECT may be of benefit in planning the operative access to the region of interest, in determining the depth of lesions for precise and faster exstirpation and in controlling the area of operation for residues. In summary freehand SPECT has high potential to optimize surgical procedures.